



SCOLIOSIS RESEARCH SOCIETY

43rd Annual Meeting & Course
Reaching New Heights in 2008!

FINAL PROGRAM

September 10-13, 2008

Grand America Hotel • Salt Lake City, Utah, USA

Extraordinary Support Matters



As pioneers in spine surgery, our comprehensive range of products have been the most trusted and respected in the world for years. Yet our experience shows that what matters goes far beyond the technologies we produce.

Today, DePuy Spine leads the way into the future of spine surgery with programs and details that matter to you. Conducting clinical trials to characterize the effectiveness

and safety of our products so you can make more evidence-based decisions. Leading initiatives to improve access for more patients. And advancing spinal technology, research, and education by partnering with those who care most about taking spine care to the next level.

DePuy Spine is more than a spine implant company. We're here to help you provide the best care possible.

DePuySpine
a *Johnson & Johnson* company

pioneering what matters

www.depuyspine.com



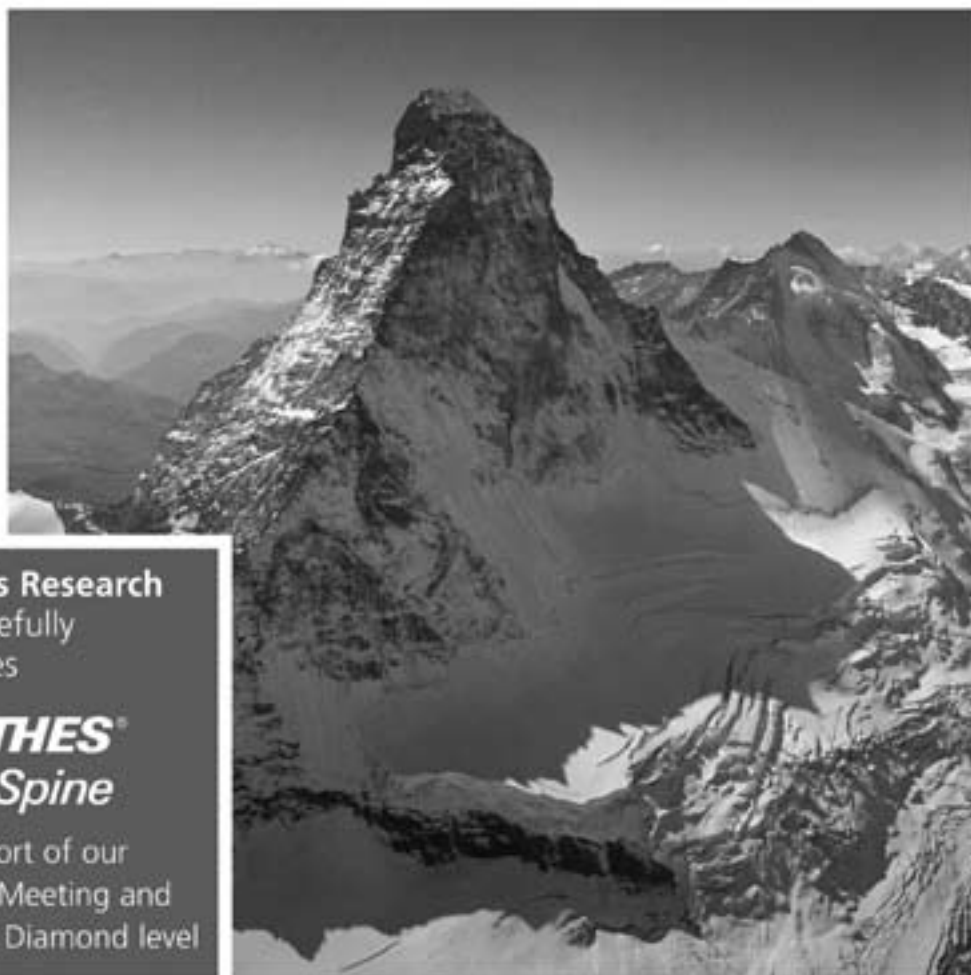comprehensive surgical solutions

reimbursement

surgeon education

patient access

clinical evidence



The **Scoliosis Research Society** gratefully acknowledges



for their support of our 2008 Annual Meeting and Course at the Diamond level

Synthes Spine is a leading international spinal device company, specializing in the development, manufacturing, and marketing of technologies for the surgical treatment of spinal disorders. Synthes Spine features a comprehensive and diverse portfolio of products for fusion and non-fusion surgical techniques with the objective of providing the patient with the best possible outcome. Close collaboration with many surgeons, including the AO Foundation, allows Synthes Spine to provide the highest quality products and services to our customers and the patient.





COMPLEX SPINE **INNOVATIONS**

SRS
DIAMOND
CORPORATE
PARTNER

K2M has one focus, the spine. Our commitment to achieve the highest level of excellence in treating complex spinal pathologies continues with the formation of the Complex Spine Study Group (CSSG). The CSSG is comprised of a team of surgeons dedicated to the collaborative advancement of science through research and the development of innovative technologies.

The CSSG focuses on five primary fields of spinal deformity disorders, including:

- Adult Complex Spine
- Adolescent/Kyphosis
- Growing Spine
- Minimally Invasive Complex Spine
- Tumor/Trauma Complex Spine



ComplexSpine
STUDY GROUP




For more information, visit www.K2M.com, or call 866.K2M.4171



43rd Annual Meeting & Course

Reaching New Heights in 2008!



Scoliosis Research Society

555 East Wells Street
Suite 1100
Milwaukee, Wisconsin, 53202-3823 USA
Phone: 1-414-289-9107
Fax: 1-414-276-3349
E-mail: info@srs.org
Web site: www.srs.org

SRS Mission Statement

The purpose of the Scoliosis Research Society is to foster the optimal care of all patients with spinal deformities.

Future SRS Educational Events

Annual Meetings

September 23- 26, 2009 – San Antonio, Texas, USA
September 22- 25, 2010 – Kyoto, Japan
September 21-24, 2011 – Louisville, Kentucky, USA

International Meeting on Advanced Spine Techniques (IMAST)

July 15-18, 2009 – Vienna, Austria
July 21-24, 2010 – Toronto, Canada

Worldwide Regional Meetings

September 24-25, 2008 – Cordoba, Argentina
– In conjunction with the Argentine Spine Society
October 2-4, 2008 – New Delhi, India
– In cooperation with the Association of Spine Surgeons of India (ASSI) and the Delhi Spine Society

TABLE OF CONTENTS

SRS Contact Information	3
Future Educational Events	3
President’s Message	4
Board of Directors	5
SRS Annual Meeting Committees.....	8
CME Information.....	9
Disclaimer.....	10
General Meeting Information.....	11
Venue Floor Plan	14
City Map.....	16
Meeting Outline.....	17
Guest Lecturers	20
Educational Events.....	21
Social Events & Optional Tours	23
Presenter Disclosures.....	25
Scientific Program	41
Glossary of Spinal Deformity Biomechanical Terms ..	52
Scientific Program Abstracts	55
Traditional Poster Abstracts	177
Electronic Poster Abstracts.....	205
Papers Read By Title	269
Goals and Mission Statement	340
Founding Fellows	341
Past Presidents.....	342
Past Officers & Meeting Locations.....	343
SRS Committees.....	348
Previous SRS Award & Research Grant Recipients...	355
SRS Bylaws	365
SRS Fellowship Directory	
Geographic Fellowship List.....	
In Memoriam	
Participants List.....	
Members Change of Address Form	
Meeting at a Glance	Back Cover



Dear Fellows, Guests, and Friends of the Scoliosis Research Society:

Welcome to Salt Lake City and the 43rd Annual Meeting of the Scoliosis Research Society (SRS) from your Board of Directors, the Local Hosts Committee, and myself. This should be another outstanding scientific meeting.

Our society has had another very successful academic year. The 2007 Annual Meeting in Edinburgh, Scotland was one of the largest ever. It was also one of the most festive with the wearing of kilts and whiskey tasting. In May 2008, we participated, for the first time, in Spine Week in Geneva, Switzerland. It was a very successful meeting. Our two half-day sessions drew an attendance of approximately 400 participants each. In July, we had an outstanding International Meeting on Advanced Spine

Techniques (IMAST) in Hong Kong. We had the largest attendance ever with over 900 participants. Just prior to the Annual Meeting, we held our second meeting in conjunction with SICOT. This also was in Hong Kong. The SRS is now the provider of educational activities on spinal deformities for SICOT. I would like to thank everyone on Worldwide Conference Committee (WWC) and IMAST Committees for their outstanding efforts and success in 2007 - 2008.

This fall, we will have two regional courses that were developed by the WWC. The first in Cordoba, Argentina in September and the other in New Delhi, India in October. These courses have been very successful in extending the educational activities of SRS and promoting membership to surgeons outside North America.

There will be a permanent change in the format of the Annual Meeting beginning this year. The Presidential Guest Lecturer has been replaced by a Lifetime Achievement Award. This will be awarded to an individual or individuals who have made outstanding contributions to SRS throughout the course of their careers. The presentation of this award will be followed by a short address by the recipients. This year there will be two recipients – Dr. John E. Hall and Dr. Jacqueline Perry. Both will give a short lecture after receiving their awards.

The 2008 Steel Lecturer will be Scott Sampson, PhD, from the Utah Museum of Natural History. His lecture will be "New Views on Ancient Bones." This year's Harrington Guest Lecturer will be by Dr. Marc Asher. Dr. Asher was the SRS President in 1997 and has had a long and distinguished career in the management of spinal deformities. He established the Harrington Archives at the University of Kansas Medical Center in Kansas City, KS, USA.

The scientific program was derived from over 1,000 abstracts submitted. The Program and Education Committees, under the leadership of Dr. Paul Sponseller and Dr. Jay Cummings, worked extremely hard to create an outstanding Pre-Meeting Course, concurrent sessions on Thursday afternoon, lunch programs, and the regular scientific sessions.

I would like to offer my special thanks to Dr. Jim Ogilvie, our local host, as well as the Local Host Committee for organizing this very exciting meeting. We are anticipating outstanding scientific sessions and memorable social events.

This has also been a very positive year financially for SRS. I would like to thank our Corporate Partners, especially those at the Double Diamond and Diamond Levels, for their support of the Annual Meeting and other SRS activities. I would also like to thank all other members of Industry who contributed to make this meeting and year an outstanding success.

I personally want to extend a special thanks to Tressa Goulding and her staff at EDI for all their hard work. Their collective efforts continue to make the Scoliosis Research Society one of the most effective and productive orthopaedic societies in the world today.

Finally, I want to thank you, the members of SRS, for allowing me the honor to serve as your President for a second year. Your support has been greatly appreciated, and I look forward to sharing the events of this meeting with you.



George H. Thompson, MD
President, Scoliosis Research Society



43rd Annual Meeting & Course

Reaching New Heights in 2008!

SCOLIOSIS RESEARCH SOCIETY

2007-2008 BOARD OF DIRECTORS 5



George H. Thompson, MD
President



Oheneba Boachie-Adjei, MD
President-Elect



Richard E. McCarthy, MD
Vice President



Steven M. Mardjetko, MD, FAAP
Treasurer



David W. Polly, Jr., MD
Secretary



Behrooz A. Akbarnia, MD
Past President, 2006



Randal R. Betz, MD
Past President, 2005



James W. Ogilvie, MD
Past President, 2004



Lawrence G. Lenke, MD
Director



B. Stephens Richards, III, MD
Director



Azmi Hamzaoglu, MD
Director



James W. Roach, MD
Director

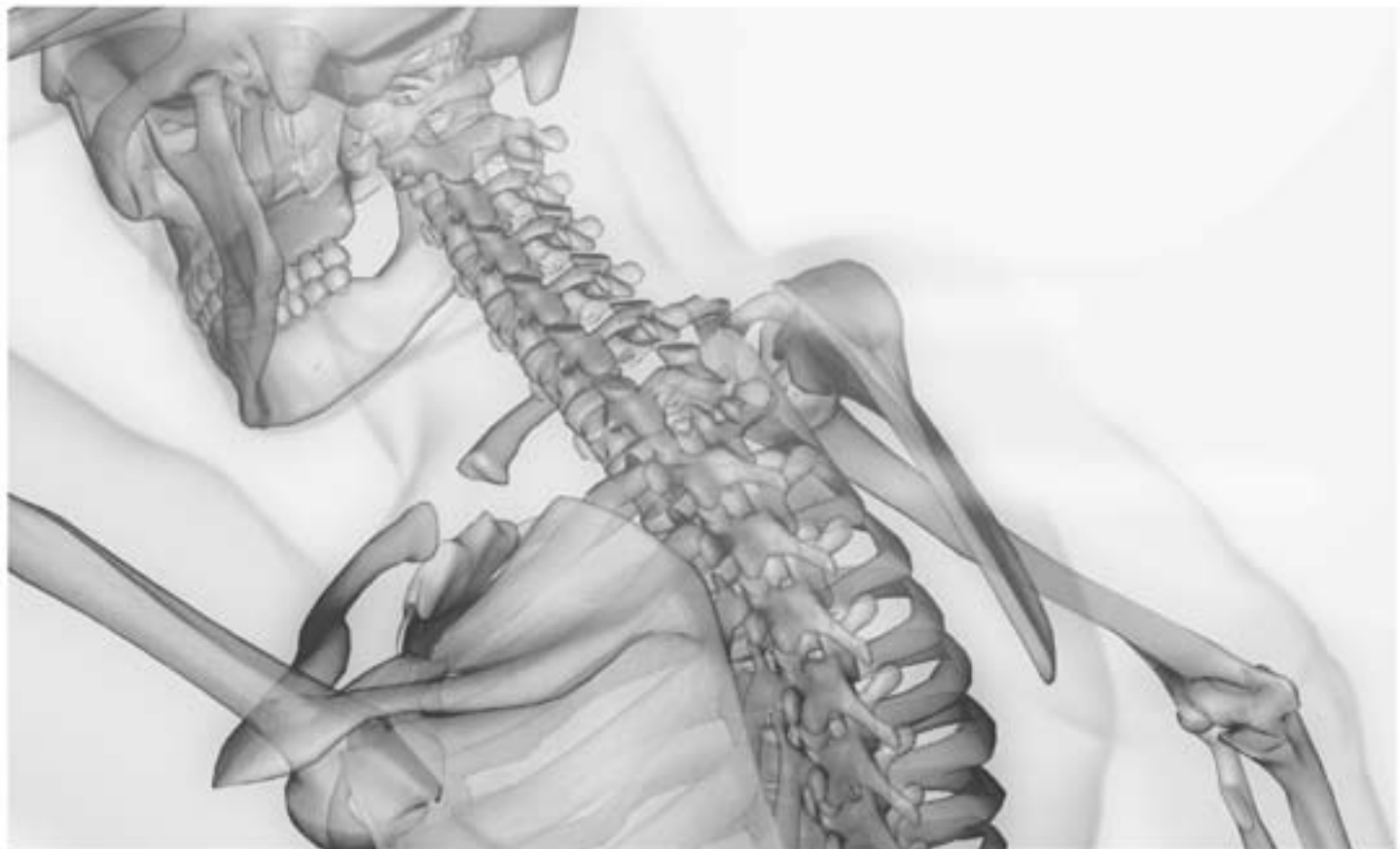

Every five seconds we help
improve another life.

To learn more about Medtronic call (800) 876-3133
or (901) 396-3133 or visit www.sofamordanek.com

IRN6352/028





The Human Spine

We Understand Every Angle.

Since our founding in 1939, Stryker has worked side-by-side with surgeons in the operating room. As medicine has evolved, so have we.

Now, everywhere you look, Stryker Spine is helping people lead active, more comfortable lives. Thanks to our relentless pursuit to design and develop implants for procedural innovations, we can provide neurosurgeon and orthopedic surgeon customers with the tools they need to help their patients.

Stryker has been setting standards within the healthcare industry for years. Stryker Spine continues in that tradition by joining together with surgeons to create new perspectives on spinal health.

stryker[®]

Spine

www.stryker.com

2008 SRS President

George H. Thompson, MD

2008 Local Host Committee

James W. Ogilvie, MD

James W. Roach, MD

2008 Program Committee

Paul D. Sponseller, MD, Chair

David L. Skaggs, MD, Past Chair

Sanford E. Emery, MD

Muharrem Yazici, MD

James T. Guille, MD

Lawrence G. Lenke, MD, IMAST Chair

Douglas C. Burton, MD

Peter O. Newton, MD, Chair-Elect

Andrew G. King, MD

Todd J. Albert, MD, IMAST Chair-Elect

Patrick J. Connolly, MD

Noriaka Kawakami, MD, 2010 Co-Chair

Michael J. Yaszemski, MD, PhD, 2010 Co-Chair

2008 Program Reviewers

Ahmet Alanay, MD

Eric Buchl, MD

Mohammad Diab, MD

Michael Daubs, MD

Federico Girardi, MD

Azmi Hamzaoglu, MD

Timothy Kuklo, MD

Stanley Lee, MD

Isadore H. Lieberman, MD, MBA, FRCSC

Amir Mehbod, MD

Charles T. Mehlman, DO, MPH

Yutaka Nohara, MD

Stephen Ondra, MD

B. Stephens Richards, III, MD

Anthony Rinella, MD

Michael Ruf, MD

Vishwas Talwalker, MD

Carlos Tello, MD

Clifford Tribus, MD

2008 Education Committee

R. Jay Cummings, MD, Chair

Laurel C. Blakemore, MD, Past Chair

Reginald Q. Knight, MD

Paul D. Sponseller, MD, Program Chair

R. Shay Bess, MD

Kuniyoshi Abumi, MD

Allen W. Carl, MD, Chair Elect

Lawrence L. Haber, MD

Joseph H. Perra, MD

Ahmet Alanay, MD

Kamal N. Ibrahim, MD, FRCS(c), MA



Biomet Spine is a proud
Gold Sponsor of the
Scoliosis Research Society

Biomet Spine
is committed
to providing
innovative
solutions that
help surgeons
improve each
patient's quality
of life.

BIOMET
SPINE

Biologics • Bracing • Microfixation • Orthopedics • Osteobiologics • Spine • Sports Medicine • Trauma • 3D

biometspine.com • 800-526-2579

BIOMET

©2008 Biomet, Inc. All trademarks are the property of Biomet, Inc. or its subsidiaries unless otherwise indicated.



Meeting Description

The Scoliosis Research Society Annual Meeting & Course is a forum for the realization of the Society's mission and goals, the improvement of patient care for those with spinal deformities. Presentations at the Annual Meeting & Course are given by leading experts in the field and have value for health care professionals who treat spinal deformities at all levels and in all ages. Over 100 papers will be presented on an array of topics, including adolescent idiopathic scoliosis, growing spine, kyphosis, adult deformity, trauma, neuromuscular scoliosis and tumors.

Learning Objectives

At the conclusion of the SRS Annual Meeting and Course, participants should be able to:

1. Recognize the potential for complications related to particular surgical techniques that allow them to take steps to avoid or minimize them.
 - Accurately estimate the risks of infection, neurologic damage and failure of fixation after spinal surgery.
 - Discuss at least two methods to minimize blood loss during spinal surgery.
 - Optimize selection of proximal and distal fusion levels in AIS and adult deformity.
 - Discuss revision rates after deformity surgery and their predictors.
2. Analyze emerging options for treatment of different spinal deformities and related conditions.
 - Analyze the role of casts, growing rods, VEPTR and stapling in early-onset spinal deformity.
3. Assess the role of genetic testing in predicting the course of spinal deformity in children and adolescents.
 - List three theories of etiology of "idiopathic" scoliosis and discuss evidence.
4. Accurately describe classifications for AIS and how they guide treatment.
 - Discuss how to predict and quantify the effect of spinal osteotomies.
5. Analyze treatment options and complications for both primary and metastatic spinal tumors.
6. Discuss current research on optimizing recovery after spinal cord injury.
7. Discuss treatment and results of treatments for degenerative scoliosis.
8. Understand outcomes assessment methods for spinal deformity.

Target Audience

Presentations at the SRS Annual Meeting and Course will have value for physicians and allied health personnel who treat spinal deformities at all levels and in all ages of patients. Medical students, residents, fellows and researchers with an interest in spinal deformities will also benefit from the materials presented.

Continuing Medical Education Credit Designation

Medical Education Resources designates this educational activity for a maximum of 16.5 *AMA PRA Category 1 Credits*[™]. Physicians should only claim credit commensurate with the extent of their participation in the activity.

CME Certificates

In order to obtain your CME certificate, you must sign in daily at the Registration Desk, as well as return your completed Annual Meeting evaluation form to the Registration Desk or mail directly to: Medical Education Resources, 1500 West Canal Court, Littleton, Colorado, 80120-5615, USA.

FDA Statement

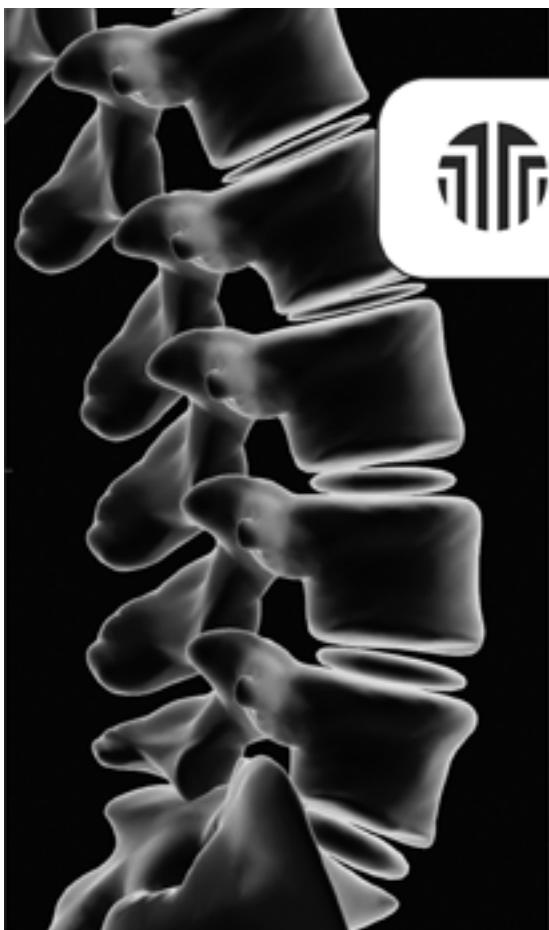
All drugs and medical devices used in the United States are administered in accordance with Food and Drug Administration (FDA) regulations. These regulations vary depending on the risks associated with the drug or medical device, the similarity of the drug or medical device to products already on the market, and the quality and scope of clinical data available.

Some drugs and medical devices demonstrated in Scoliosis Research Society meetings or described in Scoliosis Research Society print publications have FDA clearance for use for specific purposes or for use only in restricted research settings. The FDA has stated that it is the responsibility of the physician to determine the FDA status of each drug or device he or she wishes to use in clinical practice, and to use the products with appropriate patient consent and in compliance with applicable law.

Disclaimer

The material presented at the SRS Annual Meeting & Course has been made available by the Scoliosis Research Society for educational purposes only. This material is not intended to represent the only, nor necessarily best, method or procedure appropriate for the medical situations discussed, but rather is intended to present an approach, view, statement or opinion of the presenter which may be helpful to others who face similar situations.

SRS disclaims any and all liability for injury or other damages resulting to any individuals attending a session for all claims which may arise out of the use of the techniques demonstrated there in by such individuals, whether these claims shall be asserted by a physician or other party.



Osteotech, a global leader in OsteoBiologics, is a proud sponsor of the Scoliosis Research Society and its mission to provide an educational forum to advance the treatment of patients with spinal deformities.





Abstract Volume

All abstracts accepted for presentation at the 43rd Annual Meeting have been published in the Final Program (pages 56-267). Each attendee will receive one copy of the program along with their registration materials. Abstracts have also been posted online at www.srs.org.

Accompanying Persons Hospitality Room

Location: Savoy

Spouses, partners, and friends of SRS meeting attendees are welcome to meet and plan their days over a continental breakfast. The Hospitality Room is open Thursday, September 11 through Saturday, September 13 from 7:00 – 10:00 am. Accompanying persons must be registered with SRS to access the Hospitality Room.

Admission to Sessions

Official name badges will be required for admission to all SRS sessions. All Annual Meeting attendees receive a name badge with their registration materials. Name badges should be worn at all times inside the Grand America Hotel, as badges will be used to control access to sessions and activities. Attendees are cautioned against wearing their name badges while away from the hotel as badges draw unwanted attention to your status as visitors to Salt Lake City.

Admission by Tickets

Instructional Course Lectures require tickets for admission. Tickets for these sessions are not included in the meeting's regular registration fees, but are an additional \$25. Tickets will be collected at the door by ushers. There may still be a limited number of tickets available at the Registration Desk.

In addition, tickets will be required for admission to the Welcome and Farewell Receptions. One ticket for each social event is included in the cost of registration for all delegates and accompanying persons, but tickets must have been requested at the time of registration. If you pre-registered, tickets may be found in your registration packets. There may still be a limited number of tickets available at the Registration Desk.

Tickets are required for optional tours, and the cost of tour tickets is in addition to the delegate or Accompanying Person registration fee. If you pre-registered for a tour, tickets may be found in your registration packet. There may be a limited number of tickets for tours available at the Registration Desk, in the event a delegate or guest has chosen not to attend a tour.

Area Attractions

- Utah Olympic Park
- The Gateway– Open-air shopping, dining, and entertainment at over 115 shops and restaurants.
- Discovery Gateway– Located downtown Salt Lake, Utah's premier children's museum, motivates families to imagine, discover, explore.

- Clark Planetarium and IMAX®
- Historic Temple Square– A 10-acre plot in the heart of downtown featuring the 6-spired Salt Lake Temple and the domed Tabernacle, home of the world-famous Mormon Tabernacle Choir. The public is invited to the Tabernacle Choir rehearsals on Thursdays from 8:00-9:30 pm.
- Beehive House– Official residence of Brigham Young, built in 1854.
- Family History Library– The largest repository of genealogical records in the world.
- Daughters of Utah Pioneers, Pioneer Memorial Museum
- Shops and Services at Library Square– Inside Salt Lake's magnificent Main Library is a distinctive collection of shops and services.
- This Is The Place Heritage Park
- Utah Museum of Fine Arts
- Red Butte Garden– Botanical Gardens, gift shop, orangerie indoor garden, outdoor concert series, and children's garden.

More information about Salt Lake City is available at the hotel concierge desk.

ATM

ATM machines are available at both the lobbies of the Grand and Little America hotels. Both are MetaBank ATM's and charge a \$3.00 fee per transaction.

Attire

Business (suits) or business casual (polo or dress shirts, sport coats) are appropriate for meeting sessions. Casual attire is fine for the Welcome and Farewell Receptions (please, no shorts).

Business Center

The Business Center in the Grand America Hotel is located down the hall from the Women's Shop and the haberdashery, it is open 7 days a week from 7:00 am – 7:00 pm. Services include printing, copying, faxing, shipping, etc.

Cell Phone Protocol

Please ensure that cell phone ringers are turned off during all sessions.

Childcare

Childcare may be arranged through the concierge at the Grand America Hotel. Costs begin at \$20 per hour and may increase, depending on the number of children. The concierge is available 7 days a week from 7:00 am – 11:00 pm. Ample notice is suggested when making childcare arrangements.

Climate

Average temperatures in September in Salt Lake City reach highs of 78° F (25.5° C) and evening lows of 57° F (14° C). However, mountain areas may be as much as 20° cooler.



Continuing Medical Education

Medical Education Resources (MER) is an approved provider of Continuing Medical Education credits by the Accreditation Council for Continuing Medical Education (ACCME). Complete information regarding the Annual Meeting & Course learning objectives and credit designation, please see page ##. To receive CME credit, you must complete the evaluation form and submit to the Registration Desk or send it to MER at the contact information listed on the form. Attendees must also sign in everyday at the Registration Desk. MER will send out CME certificates approximately 4-6 weeks after the meeting.

Concierge Service

The Grand America Hotel concierge is available 7 days a week from 7:00 am – 11:00 pm.

Emergency & First Aid

The Grand America Hotel is fully prepared to handle emergency requests and first aid. Pick up any house phone for immediate assistance and contact an SRS staff person for support. Remember to note all emergency exits within the hotel.

Evaluations

Please take time to complete the evaluation form provided for each session you attend. Your input and comments are essential in planning future Annual Meetings. When completed, evaluations may be returned to the evaluation drop box located near the general session room or to the SRS Registration Desk.

Getting Around

Utah Transit Authority (UTA) provides over 100 bus routes throughout an 1,800 square-mile area. UTA also provides light-rail service, airport transportation, service to ski resorts in winter, and door-to-door transportation for disabled passengers. Fares within the valley are \$1.50 for two hours or \$4.00 for an all-day pass. A free fare zone is available downtown.

Guest Attendance

Adults and children over the age of 10 may register as guests to attend the social events (Welcome and Farewell Receptions) at a cost of \$350.00 per guest. Tickets for the Welcome and Farewell Receptions are included in this registration fee, but must be requested at the time of registration. For those guests who have pre-registered and requested social event tickets, these tickets can be found in the delegate's registration packet. Guests may register and request social event tickets at the Registration Desk. Registered guests are also able to participate in optional tours, at an additional fee, although pre-registration for tours is required. There may be a limited number of tour tickets available at the Registration Desk, in the event a delegate or guest has chosen not to attend a tour.

Hotel Information

The Grand America Hotel is the headquarters hotel for the 43rd Annual Meeting & Course:

555 South Main Street
Salt Lake City, UT 84111
Phone: 801-258-6000
Fax: 801-258-6911
www.grandamerica.com/

Delegates may also be staying at the Little America Hotel:

500 South Main Street
Salt Lake City, UT 84101
Phone: 801-596-5700
Fax: 801-596-5911
www.littleamerica.com/slc/

Internet Café

*Location: Murano (Tuesday – Friday)
Grand Ballroom Conference Registration Area (Saturday)*

Attendees may access the Internet and check their e-mail at the Internet Café.

Hours:

Tuesday, September 9 2:00 – 6:00 pm
Wednesday, September 10 6:30 am – 5:00 pm
Thursday, September 11 6:30 am – 4:00 pm
Friday, September 12 6:30 am – 5:15 pm
Saturday, September 13 6:30 am – 1:00 pm

Language

English is the official language of the SRS Annual Meeting & Course.

Lost & Found

Please feel free to stop by the SRS Registration Desk if you have lost or found an item during the course of the Annual Meeting. You may also wish to check with hotel security regarding lost items.

Members Business Meetings & Breakfast

Location: Imperial Ballroom A

All SRS members are invited to the Member's Business Meetings on Thursday, September 11 through Saturday, September 13 from 6:30 am – 7:40 am in Imperial Ballroom A. Committee Chairs will share their reports, as well as reports from the SRS Traveling Fellows and Edgar Dawson Scholarship recipients. A hot breakfast buffet will be served.



Member Hospitality Room

Location: Envoy

SRS Members are invited to use the Member Hospitality Room in Envoy. This is a room where members may relax or hold small meetings. Wireless Internet will be available for use with your personal laptop.

Hours:

Wednesday, September 10..... 6:30 am – 5:00 pm
 Thursday, September 11..... 6:30 am – 4:00 pm
 Friday, September 12..... 6:30 am – 5:15 pm
 Saturday, September 13..... 6:30 am – 1:00 pm

Messages

A self-service message board (non-electronic) will be available in the Registration Area for attendees to post notes or leave messages for other attendees. Please remember to check for any messages that may be left for you.

No Smoking Policy

Smoking is not permitted during any meeting activity or event.

Non-Members Continental Breakfast

Location: Grand Ballroom Reception

All non-members are invited to meet with their colleagues and network over coffee and a continental breakfast on Thursday, September 11 through Saturday, September 13 from 6:30 – 7:40 am in the Grand Ballroom Reception area.

Parking

Valet parking at the Grand America Hotel is \$15 for overnight/full day parking and self parking is \$10 maximum (\$1 per hour up to \$10 max). Self-parking at the Little America is complimentary, and valet is \$6.

Photography Policy

The SRS has arranged for a photographer to be present throughout the Annual Meeting & Course. SRS will use these photos in publications and to produce related literature and products for public release. Individuals photographed will not receive compensation for the use and release of these photos and will be deemed to have consented to the use and release of photos in which they appear. If you are opposed to being photographed, please immediately notify the photographer or an SRS staff member if your picture is taken. Thank you for your cooperation.

Cameras are not permitted in any Annual Meeting & Course educational session or in the poster area.

Poster Hall Location & Hours

Location: Grand Ballroom Reception

Hours:

Wednesday, September 10..... 6:30 am – 5:00 pm
 Thursday, September 11..... 6:30 am – 4:00 pm
 Friday, September 12..... 6:30 am – 5:15 pm
 Saturday, September 13..... 6:30 am – 1:00 pm

Registration Desk Location & Hours

Location: Murano (Tuesday – Friday)

Grand Ballroom Conference Registration Area (Saturday)

Hours:

Tuesday, September 9..... 2:00 – 6:00 pm
 Wednesday, September 10..... 6:30 am – 5:00 pm
 Thursday, September 11..... 6:30 am – 4:00 pm
 Friday, September 12..... 6:30 am – 5:15 pm
 Saturday, September 13..... 6:30 am – 1:00 pm

Speaker Lounge and Speaker Ready Room

Location: Tuscany (Speaker Lounge)

Grand Ballroom (Speaker Ready Room)

Speakers may feel free to use the Speaker Lounge upon arrival after picking up their registration materials. Equipment will be available for all speakers to review their presentations and make any last minute changes. Speakers should plan to upload their presentations in the Speaker Ready Room located in the back of the Grand Ballroom.

Hours:

Tuesday, September 9..... 2:00 – 6:00 pm
 Wednesday, September 10..... 6:30 am – 5:00 pm
 Thursday, September 11..... 6:30 am – 4:00 pm
 Friday, September 12..... 6:30 am – 5:15 pm
 Saturday, September 13..... 6:30 am – 1:00 pm

Special Needs

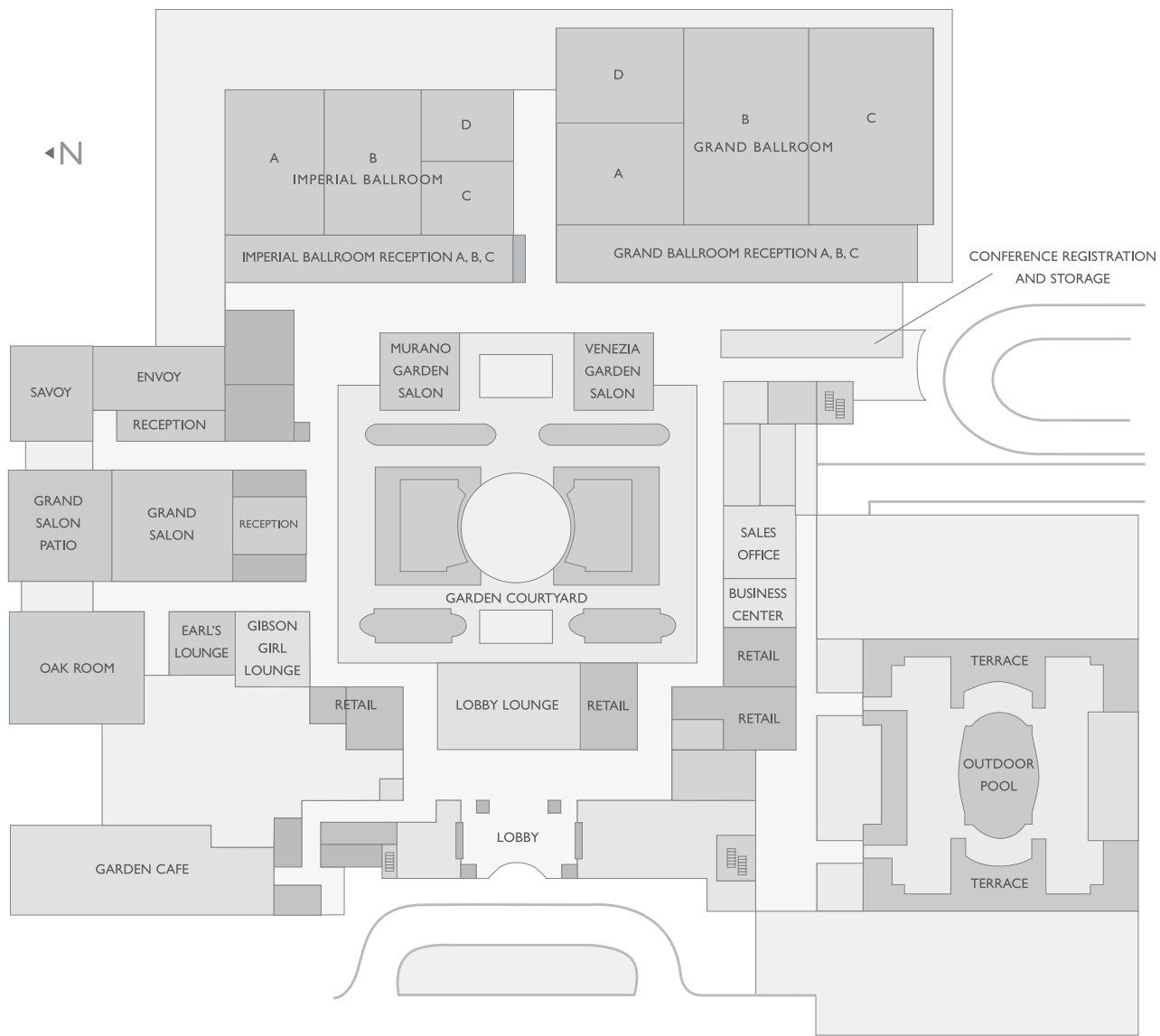
If you have any health issues for which you may require special accommodations or assistance, please contact the SRS office. We will make every effort to accommodate any special needs.

Tour Information

Delegates and Accompanying Persons, including adults and children ages 10 and up, are able to attend optional tours. Tickets are required to participate in the tours and must have been requested at the time of pre-registration. Any tour tickets purchased will be included with the delegate's registration packet. Additional tour tickets may be available at the Registration Desk, in the event a delegate or guest has chosen not to attend a tour.

For more information on tours, including a complete schedule, please see page 23 and 24.

The Grand America Hotel — First Floor

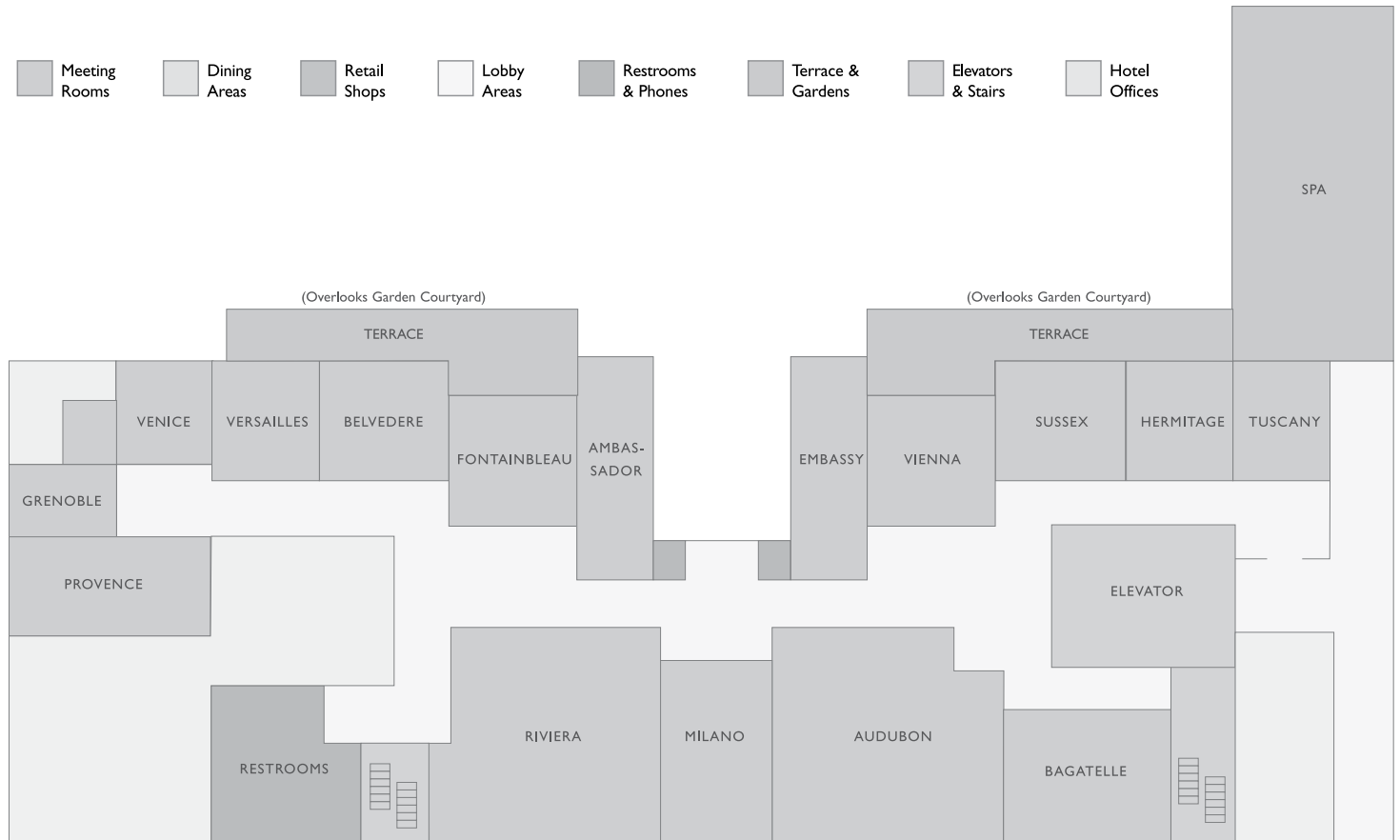

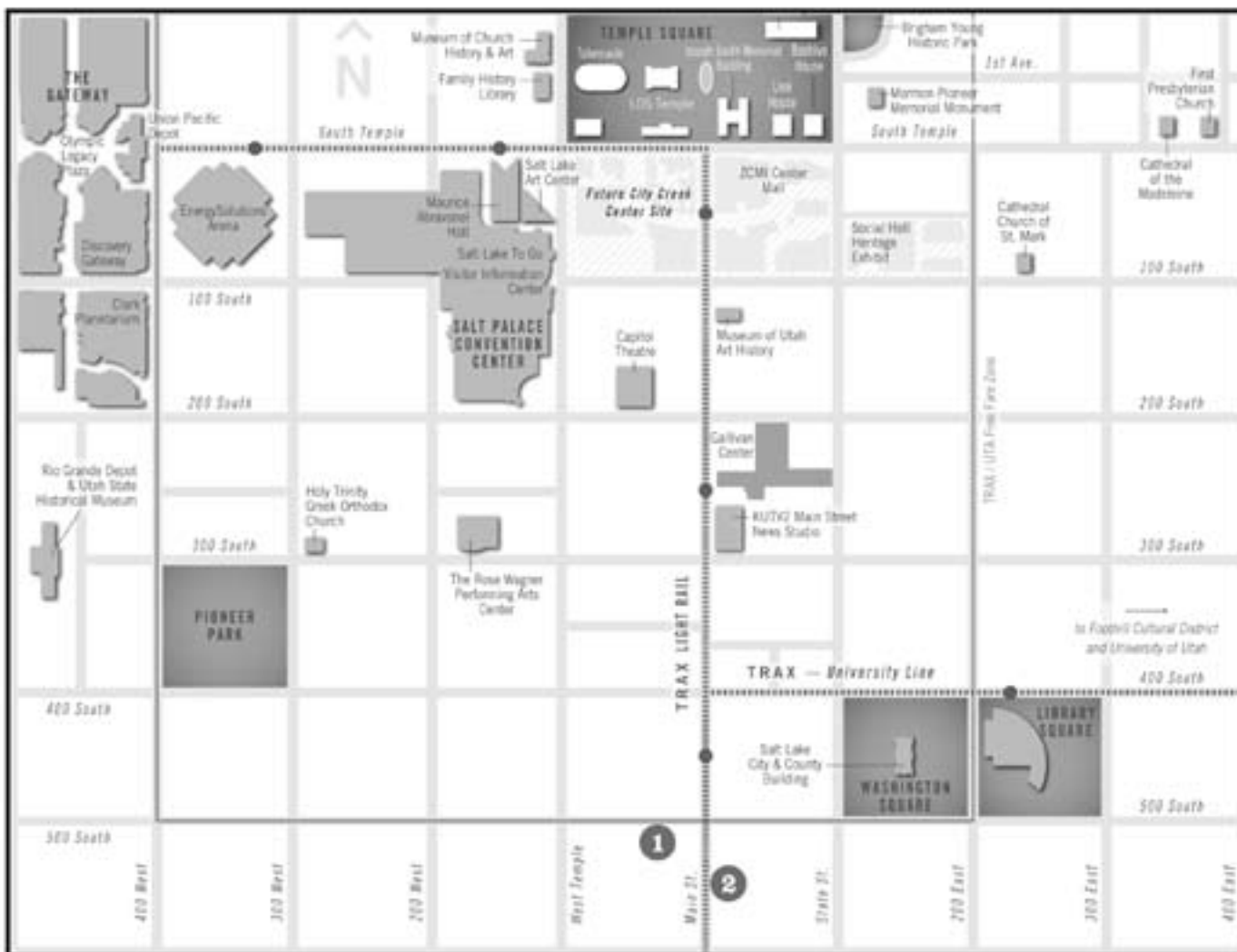
- Meeting Rooms
- Dining Areas
- Retail Shops
- Lobby Areas
- Restrooms & Phones
- Terrace & Gardens
- Elevators & Stairs
- Hotel Offices



The Grand America Hotel — Third Floor

- Meeting Rooms
- Dining Areas
- Retail Shops
- Lobby Areas
- Restrooms & Phones
- Terrace & Gardens
- Elevators & Stairs
- Hotel Offices





Scoliosis Research Society

September 10–13, 2008

- 1 Little America Hotel
- 2 The Grand America Hotel



43rd Annual Meeting & Course

Reaching New Heights in 2008!

Monday, September 8, 2008

7:00 am – 5:00 pm Board of Directors Meeting – *Riviera*

Tuesday, September 9, 2008

7:00 am – 5:00 pm SRS Committee Meetings – *Belvedere, Embassy, Fontainebleau, Hermitage, Sussex, Tuscany, Vienna*

2:00 – 6:00 pm Poster Set-Up – *Grand Ballroom Reception*

2:00 – 6:00 pm Registration Open – *Murano*

2:00 – 6:00 pm Internet Café – *Murano*

7:00 – 10:00 pm SRS Leadership Dinner (by invitation only) – *McCune Mansion*
Buses begin loading at 6:30 pm at 600 South Porte Cochere – Grand America Hotel

Wednesday, September 10, 2008

6:30 am – 5:00 pm Registration Open – *Murano*

6:30 am – 5:00 pm Internet Café Open – *Murano*

6:30 am – 5:00 pm SRS Member Hospitality Room Open – *Envoy*

6:30 am – 5:00 pm Speaker Lounge Open – *Tuscany*

6:30 am – 5:00 pm Poster & E-Poster Exhibits – *Grand Ballroom Reception*

7:00 – 10:00 am Accompanying Person Hospitality Room Open – *Savoy*
(Must be registered)

7:30 – 11:30 am Pre-Meeting Course: Osteobiologics – *Grand Ballroom*
(Additional registration fee required)

11:30 am – 12:30 pm Lunch Break – *Center Courtyard* (*Rain Backup: Imperial Ballroom BCD*)

11:30 am – 12:30 pm New Member Lunch – *Grand Salon*

11:30 am – 12:30 pm Educational Symposium - Understanding the SRS Roadmap to Financial Success – *Imperial Ballroom A*

12:30 – 5:30 pm Pre-Meeting Course – Hibbs Society Meeting – Osteotomies – *Grand Ballroom*
(Additional registration fee required)

7:00 – 8:00 pm Opening Ceremonies – *Grand Ballroom*

8:00 – 9:30 pm Welcome Reception – *Center Courtyard*
(Rain Backup: Imperial Ballroom)

Optional Tours

All motorcoach tours depart from the Grand America at 600 South Porte Cochere (near the ballrooms).

All walking tours depart from the Grand America Lobby.

8:00 am – 12:00 pm Historic City Tour

1:30 – 4:30 pm Shaking the Family Tree Tour



Thursday, September 11, 2008

- 6:30 am – 4:00 pm Registration Open – *Murano*
- 6:30 am – 4:00 pm Internet Café Open – *Murano*
- 6:30 am – 4:00 pm SRS Member Hospitality Room Open – *Envoy*
- 6:30 am – 4:00 pm Speaker Lounge Open – *Tuscany*
- 6:30 am – 4:00 pm Poster & E-Poster Exhibits – *Grand Ballroom Reception*
- 6:30 – 7:40 am Members Business Meeting – *Imperial Ballroom A*
- 6:30 – 7:40 am Non-Members Continental Breakfast – *Grand Ballroom Reception*
- 7:00 – 10:00 am Accompanying Person Hospitality Room Open – *Savoy (Must be registered)*
- 7:55 – 10:11 am Scientific Program – *Grand Ballroom*
- 10:11 – 10:31 am Break – *Grand Ballroom Reception*
- 10:31 am – 12:10 pm Scientific Program – *Grand Ballroom*
- 1:00 – 4:00 pm Instructional Course Lecture: 3D Scoliosis Evaluation and Classification – *Imperial Ballroom A (additional fee required)*
- 1:00 – 4:00 pm Instructional Course Lecture: Experimental Background of Growth Modulation on the Treatment of Growing Spine Deformities – *Grand Ballroom (additional fee required)*
- 1:00 – 4:00 pm Instructional Course Lecture: AAOS Communication Skills – *Savoy (additional fee required)*

Optional Tours & Sports

All motorcoach tours/sports depart from the Grand America at 600 South Porte Cochere (near the ballrooms).

All walking tours depart from the Grand America Lobby.

- 12:30 pm Edgar Dawson Memorial Golf Tournament – *Thanksgiving Point Golf Club*
- 12:30 – 5:30 pm Hike the Hills of Park City
- 12:30 – 5:30 pm Rails to Trails
- 12:30 – 6:00 pm Fly Fishing
- 1:30 – 4:30 pm Shaking the Family Tree Tour
- 1:30 – 4:30 pm Doubles Tennis Tournament
- 1:30 – 5:30 pm Historic City Tour
- 1:30 – 5:30 pm Red Butte Garden and This Is The Place Heritage Park
- 5:30 pm – 9:30 pm Supper & Song

Friday, September 12, 2008

- 6:30 am – 5:15 pm Registration Open – *Murano*
- 6:30 am – 5:15 pm Internet Café Open – *Murano*
- 6:30 am – 5:15 pm SRS Member Hospitality Room Open – *Envoy*
- 6:30 am – 5:15 pm Speaker Lounge Open – *Tuscany*
- 6:30 am – 5:15 pm Poster & E-Poster Exhibits – *Grand Ballroom Reception*
- 6:30 – 7:40 am Members Business Meeting – *Imperial Ballroom A*
- 6:30 – 7:40 am Non-Members Continental Breakfast – *Grand Ballroom Reception*
- 7:00 – 10:00 am Accompanying Person Hospitality Room Open – *Savoy (Must be registered)*
- 7:55 – 10:11 am Scientific Program – *Grand Ballroom*
- 10:11 – 10:31 am Break – *Grand Ballroom Reception*
- 10:31 am – 12:23 pm Scientific Program – *Grand Ballroom*
- 12:23 – 1:20 pm Lunch Break – *Center Courtyard (Rain Backup: Imperial Ballroom BCD)*
- 12:23 – 1:20 pm Educational Symposium
Global Outreach Program:
Tuberculosis – Infections of the Spine – *Imperial Ballroom A*
- 1:20 – 5:05 pm Scientific Program – *Grand Ballroom*
- 3:13 – 3:37 pm Break – *Grand Ballroom Reception*
- 5:45 – 6:45 pm President's Reception (by invitation only) – *Grand Salon*
- 7:00 – 10:00 pm Farewell Reception – *Clark Planetarium & IMAX®*
Buses begin loading at 6:30 pm at 600 South Porte Cochere – Grand America

Optional Tours

All motorcoach tours depart from the Grand America at 600 South Porte Cochere (near the ballrooms).

- 9:00 am – 12:00 pm Thanksgiving Point & Gardner Village
- 1:30 – 5:30 pm Violins & Chocolate



43rd Annual Meeting & Course

Reaching New Heights in 2008!

SCOLIOSIS RESEARCH SOCIETY

MEETING OUTLINE 19

Saturday, September 13, 2008

- 6:30 am – 1:00 pm Registration Open – *Grand Ballroom
Conference Registration Area*
- 6:30 – 10:00 am Internet Café Open – *Grand Ballroom
Conference Registration Area*
- 6:30 am – 1:00 pm SRS Member Hospitality Room Open
– *Envoy*
- 6:30 am – 1:00 pm Speaker Lounge Open – *Tuscany*
- 6:30 am – 1:00 pm Poster & E-Poster Exhibits – *Grand
Ballroom Reception*
- 6:30 – 7:40 am Members Business Meeting – *Imperial
Ballroom A*
- 6:30 – 7:40 am Non-Members Continental Breakfast
– *Grand Ballroom Reception*
- 7:00 – 10:00 am Accompanying Person Hospitality
Room Open – *Savoy (Must be registered)*
- 7:55 am – 12:47 pm Scientific Program - *Grand Ballroom*
- 10:07 – 10:27 am Break – *Grand Ballroom Reception*
- 12:47 pm Meeting Adjourns
- 1:00 – 5:00 pm Board of Directors Meeting - *Audubon*

Optional Tour

*All motorcoach tours depart from the Grand America at 600 South
Porte Cochere (near the ballrooms).*

- 8:45 am – 12:45 pm Red Butte Garden and This Is The
Place Heritage Park

HOWARD STEEL LECTURER



Scott D. Sampson, PhD

Dinosaurs: New Views on Ancient Bones by Scott Sampson, PhD will be this year's Howard Steel Lecture. Dr. Sampson is a Research Associate Professor of Geology & Geophysics and Research Curator at the Utah Museum of Natural History. The Steel Lecture will take place on Wednesday, September 10, 2008, during the Opening Ceremonies.

HARRINGTON LECTURER



Marc A. Asher, MD

This year's Harrington Guest Lecture, the thirty-fourth since its inception in 1975, will be presented by Marc A. Asher, MD. The title of his lecture is *Harrington's Contributions in Perspective*.

Paul R. Harrington (1911-1980) requested that following his death his professional materials be housed in the archives of his alma mater, the University of Kansas Medical

Center in Kansas City, Kansas, USA. Materials from the Harrington Archives will be used in the lecture to illustrate his contributions. These include researching and developing the first successful spinal implant system, pioneering medical innovator-industrial relationships, initiating technique specific education of surgeons, very early computer patient data basing to track patients' follow-up, designing and using pedicle screws (paving the way for later FDA pedicle screw reclassification), and an unfailing commitment to learning the biological basis of idiopathic scoliosis.

The lecture will be presented on Thursday, September 11 at 11:45 am.

LIFETIME ACHIEVEMENT AWARDS

The 2008 Lifetime Achievement Award Lectures will be presented on Saturday, September 13, 2008. The Lifetime Achievement Award recipients were chosen from among the SRS membership, based on long and distinguished service to the Society and to spinal deformity research and care. This year's winners are: John E. Hall, MD and Jacqueline Perry, MD, DSc



John E. Hall, MD

John E. Hall, MD, founding fellow and Past President of SRS, graduated from McGill University in 1952, after a short career as a bomber pilot in World War II. He completed his post-graduate education in Toronto, Canada and London, England. In 1971, he moved to Boston, MA, USA as clinical chief of staff at Boston Children's Hospital and a Professor of Orthopaedics at

Harvard Medical School. His work with John Moe, Joe Risser, and many others has revolutionized spinal deformity care. He has trained many fellows and residents who have gone on to be leaders in the specialty.



Jacqueline Perry, MD, DSc

Dr. Jacquelin Perry, founding member of SRS, entered the health field with a B. Ed in physical education at UCLA, then a year of physical therapy training at Walter Reed Army Hospital and service during World War II. After the war, she attended medical school at the University of California-San Francisco where she also completed her orthopaedic residency.

Subsequently, her preference for reconstructive surgery led her to Rancho Los Amigos in Southern California. During the span of her career, she helped design the halo for three-dimensional positioning of paralyzed necks and has co-authored more than 300 peer-reviewed papers, 38 chapters and 1 book. The 2nd edition of the text *Gait Analysis, Normal, and Pathological Function* is currently on press.



Pre-registration is required for Educational Events and space is limited. Instructional Course Lectures require tickets for admission. Tickets for these sessions are not included in the meeting's regular registration fees, but are an additional \$25. Tickets will be collected at the door by ushers. There may still be a limited number of tickets available at the Registration Desk.

Wednesday, September 10, 2008

Educational Symposium: Understanding the Roadmap to Financial Success

11:30 am – 12:30 pm

Location: Imperial Ballroom A

11:30 am – 12:00 pm The Scoliosis Research Society's
Financial Status: Past, Present and
Future
Jeffery L. Stambough, MD, MBA
Chairman of the SRS Endowment
Committee 2009

12:00 – 12:30 pm Question & Answer
Jeffery L. Stambough, MD, MBA
Ed Hoover, OREF
Gene Wurth, OREF

Thursday, September 11, 2008

Instructional Course Lecture: 3D Scoliosis Evaluation and Classification

1:00 – 3:15 pm

Location: Imperial Ballroom A

Presented by the SRS 3D Classification Committee

1:00 – 1:05 pm Welcome and Introduction
Lawrence G. Lenke, MD

1:06 – 1:16 pm 3D Terminology
Ian A.F. Stokes, PhD

1:17 – 1:27 pm Central Sacral Vertical Line (CSVL) vs
Central Hip Vertical Axis (CHVA)
Roger P. Jackson, MD

1:28 – 1:35 pm Discussion

1:36 – 1:51 pm 3D Visualization and Presentation
of a New Concept to Report 3D
Spinal Deformities: The Da-Vinci
Representation
Carl-Eric Aubin, PhD

1:52 – 1:57 pm Discussion

1:58 – 2:08 pm "Plan d'election" and Apical Lordosis
Peter O. Newton, MD

2:09 – 2:19 pm Case Presentation & Clinical
Relevance of 3D Analysis
Lawrence G. Lenke, MD

2:20 – 2:28 pm Discussion

2:29 – 2:44 pm 3D Classification & Future Direction
Hubert Labelle, MD

2:45 – 2:55 pm General Discussion

2:56 – 3:15 pm Survey to Test the Understanding of
the DaVinci Representation
Carl-Eric Aubin, PhD & Hubert Labelle,
MD

Instructional Course Lecture: Experimental Background of Growth-Modulation on the Treatment of Growing Spine Deformities

1:00 – 4:00 pm

Location: Grand Ballroom

Presented by the SRS Growing Spine Committee

1:00 – 1:04 pm Introduction
George H. Thompson, MD

1:05 – 1:14 pm Growing Spine Deformities: Current
Problems. What we know, where we
are...
Charles E. Johnston, MD

1:15 – 2:16 pm Long-Term Effect of Early
Instrumentation and Fusion

1:15 – 1:24 pm Pedicle Screw and Spinal Growth: Risky
Daniel Sucato, MD, MS

Thursday, September 11, 2008

1:25 – 1:34 pm	Pedicle Screw and Spinal Growth: Safe <i>Michael Ruf, MD</i>
1:35 – 1:40 pm	Question & Answer
1:41 – 1:50 pm	The Effect of Early Spine Fusion on the Thoracic Cavity Growth <i>Alain Dimeglio, MD</i>
1:51 – 1:58 pm	The Effect of Early Anterior Fusion on the Spinal Canal Growth <i>Muharrem Yazici, MD</i>
1:59 – 2:04 pm	Question & Answer
2:05 – 2:14 pm	How Does Thoracic Expansion Affect Pulmonary Growth and Function <i>Bryan D. Snyder, MD, PhD</i>
2:15 – 2:17 pm	Question & Answer
2:18 – 3:42 pm	Growth Modulation
2:18 – 2:27 pm	How Can We Produce the Best Experimental Model for Scoliosis? <i>Eric J. Wall, MD</i>
2:28 – 2:35 pm	Anterior Modulation <i>John T. Braun, MD</i>
2:36 – 2:43 pm	Can Spinal Growth be Modulated from Back? <i>John T. Braun, MD</i>
2:44 – 2:52 pm	Question & Answer
2:53 – 3:02 pm	Biomechanical Background of Growth Modulation <i>Ian A.F. Stokes, PhD</i>
3:03 – 3:12 pm	Biomechanical Comparison of Different Fusionless Concepts Using Finite Element Modeling <i>Carl-Eric Aubin, PhD</i>
3:13 – 3:18 pm	Question & Answer
3:19 – 3:28 pm	Rib Cage and Spinal Growth Modulation <i>Carl-Eric Aubin, PhD</i>
3:29 – 3:36 pm	Vertebral Growth Stimulation: Fact or Fiction? <i>Muharrem Yazici, MD</i>
3:37 – 3:42 pm	Question & Answer
3:43 – 3:57 pm	Summary and Future Direction <i>Behrooz A. Akbarnia, MD</i>
3:58 – 4:00 pm	Closing Remarks

Instructional Course Lecture: Communication Skills

1:00 – 4:00 pm	Location: Envoy <i>Presented by AAOS</i>
1:00 – 1:10 pm	Introduction of Participants <i>Vicki Kalen, MD</i>
1:10 – 1:30 pm	Premises <i>Vicki Kalen, MD</i>
1:30 – 1:55 pm	Frustration Exercise <i>Robert Eilert, MD</i>
1:55 – 2:15 pm	Engagement/Empathy <i>Frances A. Farley, MD</i>
2:15 – 2:30 pm	Break
2:30 – 2:55 pm	Dialogue Exercise <i>Vicki Kalen, MD</i>
2:55 – 3:15 pm	Educate/Enlistment <i>Robert Eilert, MD</i>
3:15 – 3:40 pm	Monologue Exercise <i>Frances Farley, MD</i>
3:40 – 3:50 pm	Summary/Application/Assessment <i>Vicki Kalen, MD</i>
3:50 – 4:00 pm	Questions/Discussion

Friday, September 12

Educational Symposium

Global Outreach Program: Tuberculosis—Infections of the Spine

Location: Imperial Ballroom A

12:23 – 1:20 pm

Guest speakers will discuss tuberculosis in developing areas. Dr. Isador Lieberman will present “Integrating Clinical Care with Education” based on his experience with his Uganda mission.



Wednesday, September 10, 2008

7:00 - 8:00 pm

Opening Ceremonies & Welcome Reception

Opening Ceremonies: Grand Ballroom

Welcome Reception – Center Courtyard (Rain back up: Imperial Ballroom)

Open to all registered delegates and their registered guests at no additional fee. Name badges are required.

The Annual Meeting will officially begin with Opening Ceremonies and this year's Howard Steel Lecture, presented by Scott Sampson, PhD, who will speak on "Dinosaurs: New Views on Ancient Bones." The evening will include an introduction of the SRS Officers and honored Presidents from other spine societies. All guests/partners are invited and encouraged to attend the Opening Ceremonies. Following the Opening Ceremonies, we'll move to a hosted reception featuring heavy hors d'oeuvres, cocktails, and plenty of lively conversation and reunions with colleagues and friends.

Thursday, September 11, 2008

12:30 pm

Edgar Dawson Memorial Golf Tournament

Thanksgiving Point Golf Club

Buses Depart at 12:30 pm

This year's tournament will be held at the Thanksgiving Point Golf Club, the largest golf club in the state and ranked the number one public course in Utah by *Golf Digest*. Players will compete in a shotgun start for a variety of prizes.

Golf clubs can be dropped off at the Grand America Hall Bell Desk any time prior to 9:00 am on Thursday, September 11. Golf clubs will then be transferred to Thanksgiving Point Golf Club prior to your arrival. Golf clubs may also be stored at the Bell Desk for the duration of your visit.

Friday, September 12, 2008

7:00 - 10:00 pm

Farewell Reception

Clark Planetarium & IMAX®

Shuttles begin at 6:30 pm

Open to all registered delegates and their registered guests at no additional fee. Name badges are required.

The 43rd Annual Meeting culminates with a spirited evening at the Clark Planetarium. The Planetarium is a state-of-the-art facility located on the Gateway Mall that includes an observatory, an IMAX® theater, and dozens of exhibits on science and astronomy. SRS delegates and their guests may take in one of three IMAX® shows playing that evening, explore the hands-on exhibits, or simply enjoy the refreshments and company of their colleagues.

Tour Information & Cancellation Policy

Delegates and Accompanying Persons, including adults and children ages 10 and up, are able to attend optional tours. Tickets are required to participate in the tours and must have been requested at the time of pre-registration. Any tour tickets purchased will be included with the delegate's registration packet. Additional tour tickets may be available at the Registration Desk, in the event a delegate or guest has chosen not to attend a tour.

All motorcoach tours depart from the 600 South Porte Cochere at the Grand America Hotel (near the ballrooms). Walking tours will meet in the lobby of the Grand America on Main Street. Please arrive about 10 – 15 minutes before your tour begins. Tours depart promptly at the times listed. Tours will "go" – rain or shine.

SRS has contracted with a local company called MeetingsAmerica to provide the tours in Salt Lake City. If you have any questions regarding the tours, please see the Registration Desk or call 1-800-297-6854 and ask for Melinda.

Written notification was required prior to Aug. 20 to receive refunds for cancelled tours. Absolutely no refunds will be given for tours or sporting events after Aug. 20. We will attempt to resell tickets, with payment to the original purchaser.

In the event of a natural disaster (including, but not limited to, fire, flood, severe weather, and earthquake) that makes attendance to tours impossible, SRS will grant full refunds. Requests for refunds must be received within 15 business days of the event.



Tour Schedule

Wednesday, Sept. 10	Thursday, Sept. 11	Friday, Sept. 12	Saturday, Sept. 13
Historic City Tour 8:00 am – 12:00 pm	Edgar Dawson Memorial Golf Tournament 12:30 pm	Thanksgiving Point & Gardner Village 9:00 am – 2:00 pm	Red Butte Garden & This is the Place Heritage Park 8:45 am – 2:45 pm
Shaking the Family Tree 1:30 – 4:30 pm	Hike the Hills of Park City 12:30 – 5:30 pm	Violins & Chocolate 1:30 – 5:30 pm	
	Rails to Trails 12:30 – 5:30 pm		
	Fly Fishing 12:30 – 6:00 pm		
	Shaking the Family Tree 1:30 – 4:30 pm		
	Doubles Tennis Tournament 1:30 – 4:30 pm		
	Historic City Tour 1:30 – 5:30 pm		
	Red Butte Garden & This is the Place Heritage Park 1:30 – 5:30 pm		
	Supper & Song 5:30 – 9:30 pm		



It is the policy of Medical Education Resources (MER) and Scoliosis Research Society to ensure balance, independence, objectivity, and scientific rigor in all its educational activities. All faculty participating in our programs are expected to disclose any relationships they may have with commercial companies whose products or services may be mentioned so that participants may evaluate the objectivity of the presentations. In addition, any discussion of off-label, experimental, or investigational use of drugs or devices will be disclosed by each of the faculty members. The options to disclose are as follows:

- a. Grants/Research Support
- b. Consultant
- c. Stock/Shareholder
- d. Speakers' Bureau
- e. Other Financial Support
- f. Over \$10,000 or more

The Scoliosis Research Society does not view the existence of these disclosed interests or commitments as necessarily implying bias or decreasing the value of the author's participation in the Annual Meeting & Course.

Presenter	Country	Relationship Disclosure
Abel, Mark	USA	None
Acaroglu, Emre	Turkey	(b) DePuy Spine; Synthes, AO Spine
Aarwal, Anand	United Kingdom	None
Agrawal, Kshitij	India	None
Ahier, Janet	Canada	None
Akbarnia, Behrooz	USA	(a) DePuy Spine, Nuvasive (b) Nuvasive, DePuy Spine (d) Nuvasive, DePuy Spine, Stryker (e) K2M (Advisory Board)
Akel, Ibrahim	Turkey	None
Alanay, Ahmet	Turkey	None
Alvarez, Ignacio		None
Amaral, Terry	USA	None
Antonacci, M. Darryl	USA	None
Ariño, Vicente		None
Arlet, VInc.ent	USA	None
Arriaga, Francisco	USA	None
Asghar, JahanGir	USA	(b) DePuy Spine, Inc.; SpineVision, Inc.
Asher, Marc	USA	(e) Royalties
Aubin, Carl-Éric	Canada	None
Auerbach, Joshua	USA	None
Aydogan, Mehmet	Turkey	None
Ayhan, Selim	USA	None
Azeddine, Bouziane	Canada	None
Bacon, Sarah	Canada	None
Badura, Jeffrey	USA	(c) Employee of Medtronic (e) Employee of Medtronic
Bae, Hyun	USA	(a) Medtronic (b) Stryker (c) Orthovita (d) Synthes
Bagnall, Keith	Canada	None
Bakaloudis, Georgios	Italy	None
Baldassarri, Stephen	USA	None
Baldus, Christine	USA	None
Bansal, Supriya	USA	None



Presenter	Country	Relationship Disclosure
Bapat, Mihir	India	None
Barrios, Carlos	Spain	None
Bas, Paloma	USA	None
Bas, Teresa	Spain	None
Bastrom, Tracey	USA	(a) DePuy, Inc.
Beausejour, Marie	Canada	None
Beckstead, Jason	USA	None
Bedigrew, Katherine	USA	None
Belanger, Lise	Canada	None
Belessine, Larissa	Brazil	None
Belkoff, Stephen	USA	(e) Stryker
Berenholtz, Sean	USA	(a) NIH/NHLBI K 23 Award
Beria, Jasmine	USA	None
Bernardo, Arlene	Canada	None
Berthonnaud, Eric	France	None
Berven, Sigurd	USA	(a) Medtronic; DePuy; Kyphon (b) Medtronic; Stryker Biologics
Bess, Shay	USA	None
Betz, Randal	USA	(b) DePuy Spine, Inc.; Medtronic, Inc.; SpineVision, Inc.; Synthes Spine, Inc.; Osteotech, Inc.
Bilsky, Mark	USA	None
Blamoutier, Arnaud	France	None
Blanke, Kathy	USA	(b) Medtronics
Boachie-Adjei, Oheneba	USA	(b) K2M; Osteotech; DePuy Spine (c) K2M
Boland, Patrick	USA	None
Bonete, Daniel	USA	None
Borkhuu, Battugs	USA	None
Borowski, Andrzej	Poland	None
Bowen, Richard	USA	None
Boyd, Michael	Canada	None
Bozkurt, Gokhan	Turkey	None
Bradford, David	USA	None
Brant, Jason	USA	None
Bridwell, Keith	USA	(a) Medtronic (b) Medtronic; DePuy
Brodke, Darrel	USA	(a) DePuy Spine (b) DePuy Spine; Amedica (c) Syndicom; (e) DePuy Spine
Brown, Courtney	USA	(b) Kyphon; Globus; Archus (c) Archus; Globus (d) Globus
Bruce, Brandon	USA	None
Bruce, Robert	USA	None
Buchowski, Jacob	USA	(a) Medtronic, Inc. (b) Stryker, Inc.
Burch, Shane	USA	None



Presenter	Country	Relationship Disclosure
Burgos, Jesus	Spain	None
Burke, Stephen	USA	None
Burton, Douglas	USA	(a) DePuy Spine, Inc. (b) DePuy Spine, Inc.
Cachon, Thibault	France	None
Cahill, Patrick	USA	None
Caird, Michelle	USA	None
Cameron, Danielle	USA	None
Campbell, Robert	USA	None
Canale, Sarah	USA	None
Canavese, Bartolomeo	Italy	None
Canavese, Federico	USA	None
Cardoso, Mario	USA	None
Carlson, Brandon	USA	None
Carpio, Nelly	Spain	None
Casey, Adrian	United Kingdom	None
Cavalli, Fabio	Italy	None
Celerin, Lubica		None
Chafetz, Ross	USA	None
Chambers, Reid	USA	(a) DePuy Spine
Chan, Donna	Canada	None
Chan, Chun wai	China	None
Charosky, Sebastien	France	(b) Medtronic
Chau, Edouard		None
Chaudhary, Kshitij	India	None
Cheh, Gene	South Korea	None
Chen, Tina	USA	None
Cheng, Jack Chun Yiu	China	None
Chettier, Rakesh	USA	None
Chikuda, Hirotaka	Japan	None
Cho, Kyu-Jung	South Korea	None
Chopin, Daniel	France	(e) Medtronic
Chow, Daniel Hung-kay	China	None
Christensen, Christen	USA	None
Chu, Winnie	China	None
Chung, Rack-Yong		None
Clarke, Raymond	Australia	None
Clasey, Jody	USA	None
Clement, Jean-Luc	France	(b) Medicea
Clements, David	USA	None
Cloyd, Jordan	USA	None
Cohen, David	USA	None
Cooper, Patrick	USA	None
Cowgill, Ian	USA	None
Cramer, Dennis	USA	None
Crandall, Dennis	USA	(a) Medtronic (b) Medtronic
Crawford, Alvin	USA	None
Crippa, Grasiela	Brazil	None

Presenter	Country	Relationship Disclosure
Cunningham, Matthew	USA	None
Czerwein, John	USA	None
Dabke, Harshad		None
Dabney, Kirk	USA	None
D'Andrea, Linda	USA	None
Danielsson, Aina	Sweden	None
Darbee, Joan	USA	None
Darras, Basil	USA	None
Daubs, Michael	USA	None
de Guise, Jacques	Canada	(a) Biospace Med
de Klerk, Luuk	Netherlands	None
De La Rubia, Javier		None
de Lind van Wijngaarden, Roderick	Netherlands	None
Dean, Laura	USA	None
Dear, Jameson	USA	None
Debnath, Ujjwal	United Kingdom	None
Defino, Helton	Brazil	None
Demirkiran, Gokhan	Turkey	None
Denis, Francis	USA	None
Deviren, Vedat	USA	None
DeWald, Christopher	USA	(b) DePuy Spine (c) Medtronic; Allez Spine
Dhall, Sanjay	USA	None
Di Silvestre, Mario	Italy	None
Diab, Mohammad	USA	None
Dimeglio, Alain	France	None
Diwan, Ashish	Australia	None
Dmitriev, Anton	USA	(a) DePuy Spine
Dobbs, Matthew	USA	None
Domenech, Pedro	Spain	None
Donnai, Dian		None
Dorman, Todd	USA	None
Dormans, John	USA	None
Dozono, Sho	Japan	None
Drummond, Denis	USA	None
Dryer, Joseph	USA	None
Durrani, Salim	USA	None
Dvorak, Marcel	Canada	None
Dykes, Daryll	USA	None
Eagan, Michael	USA	None
Edwards, Charles	USA	None
Eichhorn, Torsten		None
ElMiligui, Yasser	Egypt	None
Elsebaie, Hazem	Egypt	None
Emans, John	USA	(a) Medtronics (b) Synthes
Enercan, Meric	Turkey	None
Entezari, Vahid	USA	None



Presenter	Country	Relationship Disclosure
Erickson, Mark	USA	None
Erkan, Serkan	USA	None
Errico, Thomas	USA	(a) Synthes; Stryker; EBI (b) Stryker (e) Medtronic; Synthes; DePuy
Escribá, Ismael	USA	None
Estelita, Carlos F	Brazil	None
Estreicher, Michael	USA	None
Fang, Zhi Ming	Australia	None
Farcy, Jean-Pierre	USA	None
Farley, Frances	USA	(c) Medtronic
Farmery, Andrew	United Kingdom	None
Farnsworth, Christine	USA	(a) DePuy Spine, Inc.
Faulkner, Nathan	USA	None
Ferguson, John	New Zealand	None
Festen, Dederieke	Netherlands	None
Firkins, Paul	Switzerland	(e) DePuy Spine SARL Employee
Fischer, Itzhak	USA	None
Fisher, Charles	Canada	None
Flynn, Jennifer	USA	None
Flynn, John	USA	None
Forcier, Martin	Canada	None
Franco, Anita	Canada	None
Freedman, Brett	USA	None
Freeman, Brian	United Kingdom	None
Fu, Eric	USA	None
Fu, Kai-Ming	USA	None
Gardner, Stephen	USA	None
Garg, Sumeet	USA	None
Garrett-Mayer, Elizabeth	USA	None
Garvey, Timothy	USA	None
Gaughan, John	USA	(b) SpineVision
Geck, Matthew	USA	None
Gholve, Purushottam	USA	None
Giffin, Mitch	Canada	None
Gill, Norman		None
Giuffrida, Michael	USA	None
Glassman, Steven	USA	(a) Medtronic Sofamor Danek (b) Medtronic Sofamor Danek (e) Medtronic Sofamor Danek
Glattes, Rudolph	USA	(b) Stryker (e) Seaspine
Gok, Beril	USA	None
Gokaslan, Ziya	USA	(a) Medtronics; DePuy; AO North America (c) US Spine; Spinal Kinetics
Gonzales, Ricardo	USA	None
Good, Christopher	USA	None
Gournay, José	Switzerland	None
Green, Daniel	USA	(a) DePuy Spine



Presenter	Country	Relationship Disclosure
Grewal, Harsh	USA	None
Griffith, Terri	USA	None
Grimard, Guy	Canada	None
Gu, Jie	USA	(c) Axial Biotech
Guigui, Pierre	France	None
Guille, James	USA	(a) DePuy Spine-Harms Study Group
Gupta, Munish	USA	(a) Medtronic (b) DePuy Spine (c) Pioneer
Gutierrez, Pedro	Spain	None
Ha, Kee-Yong		None
Haid, Regis	USA	(e) Medtronic Sofamor Danek
Hamasaki, Takahiko	USA	None
Hamill, Christopher	USA	None
Hammerberg, Kim	USA	(b) DePuy Spine
Hamzaoglu, Azmi	Turkey	None
Hanover, Andrew	USA	None
Hanover, Andrew	USA	None
Harding, Ian	United Kingdom	None
Harimaya, Katsumi	USA	None
Harms, Jürgen	Germany	(f) DePuy Spine
Harrast, John	USA	None
Harrison, David	United Kingdom	None
Harshavardhana, Nanjundappa	United Kingdom	None
Hart, Robert	USA	(a) Medtronic; Medtronic: DePuy; Seaspine (d) DePuy; Medtronic; Kyphon
Hasserijs, Ralph	Sweden	None
Hawkinson, Nicola	USA	None
Hawthorne, Dana	USA	None
Hayashi, Katsuhiro	USA	None
Hayward, Melissa	USA	None
Helenius, Ilkka	Finland	(a) Foundation for Paediatric Research (b) Medtronic International
Helgeson, Melvin	USA	None
Hensley, Marsha		None
Henson, MeLeah	USA	(e) Employee of Medtronic Spinal and Biologics
Hepler, Matthew	USA	(a) Synthes
Herrero, Carlos	Brazil	None
Hevia, Eduardo	Spain	None
Hill, Douglas	Canada	None
Hilton, Joan	USA	None
Hilton, Emma		None
Hokken-Koelega, Anita	Netherlands	None
Hong, Eui Pyo		None
Hori, Satoshi	United Kingdom	None
Horton, William	USA	(b) Medtronic
Hosalkar, Harish	USA	None
Hosogane, Naobumi	Japan	None



Presenter	Country	Relationship Disclosure
Hostin, Richard	USA	(a) DePuy
Howard, Emma		None
Hsieh, Patrick	USA	None
Hsu, Brian	USA	None
Hu, Serena	USA	(a) Medtronic; DePuy (b) Pioneer (d) Synthes
Hu, Yun Yu	China	None
Hui, Celine Fan Fong	China	None
Hung, Vivian	China	None
Hutton, William	USA	None
Hwang, Dae-Woo	South Korea	None
Inui, Yoshihiro	Japan	None
Ito, Yasuo	Japan	None
Iwinski, Henry	USA	None
Jackson, Andrew	USA	None
Jackson, Roger	USA	None
Jagannathan, Jay	USA	None
Jalanko, Tuomas	Finland	(a) Orthopedics and Traumatology Research Foundation
Jayakumar, Prakash	United Kingdom	None
Jensen, Rubens	USA	(b) DePuy
Johnson, Phillip	USA	None
Johnston, Charles	USA	(a) Medtronic Sofamor Danek (b) Medtronic Sofamor Danek (c) Medtronic Sofamor Danek
Jolivet, Erwan	France	None
Joncas, Julie	Canada	None
Kadokia, Rishi	USA	None
Kajino, Tomomichi		None
Kamerlink, Jonathan	USA	None
Karlin, Lawrence	USA	(b) DePuy/Acromed
Kawade, Manish	India	None
Kawakami, Noriaki	Japan	None
Kean, Kristin	USA	None
Kebaish, Khaled	USA	(a) DePuy Spine (d) DePuy Spine
Keeler, Kathryn	USA	None
Khan, Shahid	United Kingdom	None
Kim, Hyung-suk	South Korea	None
Kim, JinHwan	USA	None
Kim, Yongjung	USA	None
Kim, Youngbae	South Korea	None
Kim, Jin-Soo		None
Kim, Ki-Tack	South Korea	None
Kim, Young Woo		None
Kirby, Cassie	USA	None
Klatt, Joshua	USA	None
Kocak, Ozgur	Turkey	None



Presenter	Country	Relationship Disclosure
Koester, Linda	USA	None
Koptan, Wael	Egypt	None
Koski, Tyler	USA	(a) Medtronic (b) Medtronic
Kostial, Patricia	USA	None
Kostuik, John	USA	(c) K2M
Kuklo, Timothy	USA	(a) Medtronic (b) Medtronic
Kummer, Frederick	USA	None
Kuntz, Charles	USA	(a) Synthes Spine; AO Spine; Medtronic Spine; Stryker Spine; BioAxone
Kwok, Hoi Kei, Rachel	China	None
Kwon, Brian	Canada	(a) Medtronic (b) Medtronic
Labelle, Hubert	Canada	(a) Medtronic Sofamor Danek
Lacroix, Ginette	Canada	None
Lafage, Virginie	USA	(c) Nemaris, LLC
Laheri, Vinod	India	None
Lam, Tsz-ping	China	None
LaMotta, Ivan	USA	None
Larouche, Ginette	Canada	None
Laufer, Ilya	USA	None
Lautenschlager, Eugene	USA	None
Lawhorne, Thomas	USA	None
Lee, Kwong Man		None
Lee, Michael	USA	None
Lee, Jae	Canada	None
Lee, June Kyu		None
Lee, Jung-Hee	South Korea	None
Lee, Kwong Man		None
Lee, Sang-Hun	South Korea	None
Lehman, Ronald	USA	None
Lenke, Lawrence	USA	(a) Medtronic; DePuy/AcroMed (b) Medtronic (c) Medtronic
Letko, Lynn	Germany	(a) DePuy
Lewis, Stephen	Canada	(b) Stryker; Medtronic
Li, Gang	USA	None
Li, Guoan	USA	None
Lieberman, Isador	USA	(a) Trans1; Merlot; Mazor; Kyphon; Medtronic; Orthovita (b) Trans1; Crosstrees; Axiomed; Merlot; Mazor; Kyphon (c) Trans1; Crosstrees; Axiomed; Merlot; Mazor (e) Trans1; Crosstrees; Axiomed; Merlot; DePuy
Lis, Eric	USA	None
Littleton, Aaron	USA	None
Liu, Jie	Canada	None
Liu, XueCheng	USA	None
Lolli, Francesco	Italy	None



Presenter	Country	Relationship Disclosure
Lonner, Baron	USA	(a) DePuy Spine (b) DePuy Spine (d) DePuy Spine (e) DePuy Spine
Lonstein, John	USA	None
Lou, Edmond	Canada	None
Lowe, Thomas	USA	(a) DePuy Spine; Medtronic Sofamor Danek
Lubicky, John	USA	(a) Medtronic (d) DePuy Spine
Luhmann, Scott	USA	(a) Medtronic (d) Stryker Spine; Medtronic
Macagno, Angel	USA	None
Mac-Thiong, Jean-Marc	Canada	None
Maeda, Takeshi	USA	None
Maeno, Takafumi	Japan	None
Mahar, Andrew	USA	None
Maher, P. Colby	USA	None
Mahood, James	Canada	None
Malass, Michael		None
Man, Chi Wai Gene	China	None
Mann, Cody	Canada	None
Manna, Barbara	USA	None
Manson, Forbes		None
Marawar, Satyajit	USA	None
Marcucio, Ralph	USA	None
Mardjetko, Steven	USA	None
Marks, Michelle	USA	(a) DePuy Spine
Marks, David	United Kingdom	(e) DePuy Spine
Martus, Jeffrey	USA	None
Maruenda, José	Spain	None
Maruyama, Toru	Japan	None
Matsuda, Hideki	Japan	None
Matsumura, Akira	Japan	None
McCarthy, James	USA	None
McCarthy, Kathryn		None
McCarthy, Richard	USA	(b) Medtronic
McClelland, Walter	USA	None
McClendon, Jamal		None
McClung, Anna	USA	None
McCullough, Frances	USA	None
McCutcheon, Brandon	USA	None
McGaughran, Julie	Australia	None
Medtronic, Spinal Deformity Study Group		None
Megumi, Naoatsu	Japan	None
Mehbod, Amir	USA	None
Mehdian, Hossein	United Kingdom	None
Mehlman, Charles	USA	None
Mehta, Hemal	USA	(a) Scoliosis Research Society (a) Chest Wall and Spine Deformity Foundation

Presenter	Country	Relationship Disclosure
Merk, Harry	Germany	None
Metkar, Umesh	USA	None
Meyer, Laura	USA	None
Mezentsev, Andriy	Ukraine	None
Milbrandt, Todd	USA	None
Milby, Andrew	USA	None
Miller, Freeman	USA	None
Mintz, Douglas	USA	None
Mishiro, Takuya	USA	None
Miyamoto, Hiroshi	Japan	None
Miyasaka, Kazuyoshi	Japan	None
Mohamed, Ahmed	USA	None
Mok, James	USA	None
Monson, David	USA	None
Moreau, Marc	Canada	None
Moreau, Alain	Canada	(a) Paradigm Spine (b) Paradigm Spine
Moridaira, Hiroshi	Japan	None
Moscardó, Federico	Spain	None
Moser, Richard	USA	None
Mroz, Thomas	USA	None
Mulcahey, Mary Jane	USA	None
Mulconrey, Daniel	USA	None
Mummaneni, Praveen	USA	(a) DePuy Spine; Medtronic (b) DePuy Spine; Medtronic (c) DePuy Spine
Nachemson, Alf	Sweden	None
Nakamura, Hiroaki	Japan	None
Nakamura, Kozo	Japan	None
Nakashita, Ken	Japan	None
Nasr, Fadi	USA	None
Nelson, Clarke	USA	None
Nelson, Lesa	USA	(c) Axial Biotech, Inc.
Neuhuber, Birgit	USA	None
Newton, Peter	USA	(a) DePuy Spine; Biospace (b) DePuy Spine (c) DePuy Spine
Ng, Bobby Kin-wah	China	None
Nnadi, Colin	United Kingdom	None
Nohara, Ayato	Japan	None
Nohara, Yutaka	Japan	None
Nomoto, Tomohisa	Japan	None
Nurenberg, Pamela	USA	None
Nydick, Jason	USA	None
O'Brien, Joseph	USA	(b) DePuy; Stryker
O'Brien, Michael	USA	(a) Johnson and Johnson (b) Johnson and Johnson; Medtronic; Osteotech (c) Johnson and Johnson; Medtronic



43rd Annual Meeting & Course

Reaching New Heights in 2008!

Presenter	Country	Relationship Disclosure
Oda, Hiromi	Japan	None
Odent, Thierry	France	(a) Medtronic
Ogilvie, James	USA	(b) Axial Biotech, Inc.; Ortho Development, Inc. (c) Axial Biotech, Inc.
Ohara, Tetsuya	Japan	None
Ohlin, Acke	Sweden	None
Okada, Yoshiyuki	Japan	None
Okubadejo, Gbolahan	USA	None
O'Leary, Patrick	USA	None
Ondra, Stephen	USA	(a) Medtronic (b) Medtronic (e) Medtronic
Ono, Takashi	Japan	None
O'Shaughnessy, Brian	USA	None
Oswald, Timothy	USA	None
Otten, Bart	Netherlands	None
Ouellet, Jean	Canada	(a) Synthes Canada
Ozturk, Cagatay	Turkey	None
Padberg, Anne	USA	None
Pan, Wei min	China	None
Paquette, Scott	Canada	None
Parent, Eric	Canada	None
Parent, Stefan	Canada	(a) Fonds de Recherche en Santé du Québec (a) Canadian Institutes of Health Research (a) Scoliosis Research Society (b) Spinevision
Parisini, Patrizio	Italy	None
Passias, Peter	USA	None
Passuti, Norbert	France	None
Pateder, Dhruv	USA	None
Patel, Nipun	USA	None
Patel, Vikas	USA	(c) Medtronic
Patel, Alpesh	USA	(a) DePuy Spine, AO Spine (d) Stryker Spine
Patel, Ashish	USA	None
Paul, Courtney	USA	None
Paulino, Carl	USA	None
Pawelek, Jeff	USA	None
Payo, Jorge	Spain	None
Pekmezci, Murat	USA	None
Peltonen, Jari		None
Peng, Chan	USA	None
Perl, John	USA	None
Perra, Joseph	USA	None
Petcharaporn, Maty	USA	None
Petrenko, Dmytro	Ukraine	None
Pettigrew, David	USA	None
Peultier, Bertrand	Switzerland	None



Presenter	Country	Relationship Disclosure
Pflugmacher, Robert	Germany	None
Pham, Julius		None
Pichelmann, Mark	USA	None
Pinto, Manuel	USA	None
Piper, Samantha	USA	None
Pittioni, Eugenio	Italy	None
Piza, Gabriel		None
Poe-Kochert, Connie	USA	None
Postras, Benoît	Canada	None
Polly, David	USA	(b) Medtronic
Potzman, Jennifer	USA	None
Poussa, Mikko	Finland	None
Pradhan, Ben	USA	(b) Synthes Spine; SpineWave; Abbott Spine; Zimmer Spine
Pronovost, Peter	USA	None
Qin, Ling	China	None
Qiu, Xing	USA	None
Qiu, Yong	China	None
Quirno, Martin	USA	None
Ramirez-Garnica, Gabriela	USA	None
Ranade, Ashish	USA	(a) DePuy Spine, Inc.
Raptis, Dimitri	United Kingdom	None
Raso, Jim	Canada	None
Rathjen, Karl	USA	None
Rawlins, Bernard	USA	None
Recarte, Enrique	Spain	None
Remes, Ville	Finland	None
Revella, Jan	USA	None
Ricchetti, Eric	USA	None
Richards, B Stephens	USA	(a) Medtronic
Riew, K. Daniel	USA	(a) Medtronic Sofamor Danek (b) Medtronic Sofamor Danek - paid to Washington U. (c) Osprey
Rinella, Anthony	USA	None
Riquelme-García, Oscar	Spain	None
Rivard, Charles-Hilaire	Canada	(b) No
Roach, James	USA	None
Robinson, Malaya	USA	None
Roig, Monica	USA	None
Rompré, Pierre	Canada	None
Rosa, Adalberto L	Brazil	None
Rose, Peter	USA	None
Rosner, Michael	USA	None
Roussouly, Pierre	France	(c) Optimage
Roy-Beaudry, Marjolaine	Canada	None
Ruf, Michael	Germany	None
Salari, Pooria	USA	None
Samdani, Amer	USA	(a) Synthes Spine, Inc. (b) DePuy Spine, Inc.; SpineVision, Inc.



Presenter	Country	Relationship Disclosure
Sampera, Ignasi	Spain	None
Sanchez Perez-Grueso, Francisco	Spain	None
Sanders, James	USA	None
Sangole, Archana	Canada	None
Sanz, Jaime	Spain	None
Sanz, Miguel	Spain	None
Sarwahi, Vishal	USA	None
Sarwark, John	USA	None
Scaduto, Anthony	USA	None
Schlechter, John	USA	None
Schootman, Mario	USA	None
Schwab, Frank	USA	(a) Medtronic Sofamor Danek; DePuy (b) Medtronic Sofamor Danek; DePuy (c) Nemaris
Schwend, Richard	USA	None
Schwender, James	USA	None
Sciubba, Daniel	USA	None
Segal, Lee		None
Seim, Howard	USA	None
Sengupta, Dilip	USA	(b) Globus Medical Inc. (c) Globus Medical Inc. (e) Abbott Spine Inc.
Shaffrey, Christopher	USA	(a) AO (b) DePuy; Medtronic Sofamor Danek (d) Synthes Spine
Shah, Suken	USA	(a) DePuy Spine, Inc. (b) DePuy Spine, Inc. (e) DePuy Spine, Inc.
Shainline, Michael	USA	None
Shanti, Nael	USA	None
Shapiro, Frederic	USA	None
Sharan, Alok	USA	None
Shelokov, Alexis	USA	(a) DePuy Spine (b) Osteotech; K2M
Shirado, Osamu	Japan	None
Shoda, Naoki	Japan	None
Shootman, Mario		None
Shufflebarger, Harry	USA	(a) DePuy Spine (b) DePuy Spine (e) DePuy Spine
Shuler, Michael	USA	None
Shum, Lai-fong Sandra	China	None
Sides, Brenda	USA	None
Siemionow, Krzysztof	USA	(a) Mazor Surgical Technologies
Sin, Sai-wing	China	None
Skaggs, David	USA	(a) Medtronic, Stryker Spine, Acromed (b) Medtronic, Stryker Spine; Acromed (d) Medtronic, Stryker Spine; Acromed
Skolasky, Richard	USA	None



Presenter	Country	Relationship Disclosure
Slivka, Michael	USA	(c) Johnson & Johnson (e) DePuy Spine
Smith, Jason	USA	None
Smith, Justin	USA	None
Smith-Berry, Therese	USA	(b) Axial Biotech
Snyder, Brian	USA	None
Song, Ho sup		None
Son-Hing, Jochen	USA	None
Spinal Deformity, Study Group	USA	None
Spivak, Jeffrey	USA	(e) Synthes Spine
Sponseller, Paul	USA	(a) DePuy Spine (b) Globus
Srivastava, Sudhir	India	None
SRS 3-D Classification Committee,	Canada	(a) Scoliosis Research Society
St. Hilaire, Tricia	USA	(a) Synthes Spine
Stammers, Anthea	Canada	None
Stanton, Robert		None
Stauff, Michael	USA	None
Stokes, Ian	USA	None
Street, John	Canada	None
Chest Wall and Spine Deformity Study Group,	USA	(a) Synthes Spine; AOSNA
Harms Study Group	USA	None
Spinal Deformity Study Group	USA	(e) Medtronic
Sturm, Peter	USA	(b) DePuy Spine; Pioneer Surgical (c) Pioneer Surgical
Sucato, Daniel	USA	None
Suda, Kota	Japan	None
Suk, Se-Il	South Korea	None
Suk, Kyung-Soo	South Korea	None
Suzuki, Akinobu	Japan	None
Tadokoro, Ko	Japan	None
Taichi, Tsuji	Japan	None
Takahashi, Keisuke	Japan	None
Takaoka, Kunio	Japan	None
Takayama, Kazushi	Japan	None
Takeshita, Katsushi	Japan	None
Talwalkar, Vishwas	USA	None
Taneichi, Hiroshi	Japan	None
Tang, Nelson	China	None
Tantorski, Mark	USA	None
Tassabehji, May		None
Taylor, Ben	United Kingdom	None
Tebi, Sina	USA	None
Teli, Marco	Italy	None
Terai, Hidetomi	Japan	None
Tetzlaff, Wolfram	Canada	None



Presenter	Country	Relationship Disclosure
Tezer, Mehmet	Turkey	None
Thometz, John	USA	None
Thompson, George	USA	(d) Synthes Spine; DePuy Spine
Thornhill, Beverly	USA	None
Thuet, Earl	USA	None
Tomlinson, Tucker	USA	(a) DePuy Spine Inc.
Tompkins, Bryan	USA	None
Topp, Raymond	USA	None
Toth, Jeffrey	USA	(a) Medtronic; DePuy; Kyphon; Cytori/MacroPore (b) Medtronic
Transfeldt, Ensor	USA	None
Tripi, Paul	USA	None
Tsujio, Tadao	Japan	None
Tsutsui, Shunji	Japan	(a) DePuy Spine, Inc.
Turgeon, Isabelle	Canada	None
Turner, A. Simon	USA	None
Turner, Joseph	USA	(e) Medtronic
Umedaly, Hamed	Canada	None
Uno, Koki	Japan	None
Upasani, Vidyadhar	USA	(a) DePuy Spine
Vallade, Marie-José		None
Vanderhave, Kelly	USA	None
Vare, Bruno	France	None
Vialle, Raphael	France	None
Viguiet, Eric	France	None
Vogel, Lawrence	USA	None
Volpatti, Donatella	Italy	None
Voros, Gabor		None
Walick, Kristina	USA	None
Walker, Matthew	Canada	None
Walker, Janet	USA	None
Wang, Zhi	Canada	None
Wang, Wei Jun	China	None
Ward, Kenneth	USA	(c) Axial Biotech, Inc.
Warnick, Drew	USA	None
Watanabe, Kei	Japan	None
Webb, John	United Kingdom	None
Widmann, Roger	USA	None
Wijkstrom, Martin	USA	None
Will, Ryan	USA	None
Wilson-MacDonald, James	United Kingdom	None
Winscher, Jacquelyn	USA	None
Winter, Robert	USA	None
Wolinsky, Jean-Paul	USA	None
Wollowick, Adam	USA	None
Won, Man-Hee	South Korea	None
Wong, Daniel	Canada	None



Presenter	Country	Relationship Disclosure
Wong, Man-sang	China	None
Wood, Kirkham	USA	None
Wootten, David	USA	(e) Medtronic
Wu, Chunhui	USA	None
Yamada, Yoshiya	USA	(d) Varian Medical Systems
Yamashita, Takayuki	USA	None
Yang, Jun-Young	South Korea	None
Yang, Justin	USA	None
Yaszay, Burt	USA	None
Yazici, Muharrem	Turkey	(b) DePuy J&J
Ye, Gang	USA	None
Yeung, Hiu Yan	China	None
Ying, Jun	USA	None
Yoon, Seung Hwan	South Korea	None
Zaarour, Christian	Canada	None
Zebala, Lukas	USA	None
Zhang, Hong	USA	None
Zhao, Zhongming	USA	None
Zimmerman, Ryan	USA	None
Zurakowski, David	USA	None



Thursday, September 11, 2008

7:55-8:00

Welcome
Announcements

SESSION I

Moderators:

Vernon T. Tolo, MD
Laurel C. Blakemore, MD

Adolescent Idiopathic Scoliosis

8:00 - 8:04 am

Paper #1

Risk Factors for Distal Adding-on Identified: What to Watch Out For
John Schlechter, DO; Peter O. Newton, MD; Vidyadhar V. Upasani, MD; Burt Yaszay, MD; Lawrence G. Lenke, MD; Randal R. Betz, MD; Thomas G. Lowe, MD; Harms Study Group

8:04 - 8:08 am

Paper #2

***Accelerated Disc Degeneration below Posterior Spinal Fusion for Idiopathic Scoliosis: A Long-Term MRI and Clinical Follow-Up.**

Thomas Lawhorne, MD; Daniel W. Green, MD, FACS; Douglas N. Mintz, MD; Bernard A. Rawlins, MD; Stephen W. Burke, MD; Roger F. Widmann, MD; Oheneba Boachie-Adjei, MD

8:08 - 8:12 am

Paper #3

Subjacent Disc Wedging after Anterior Spinal Fusion for Adolescent Idiopathic Scoliosis: The Fate of the "Jacked" Lumbar Disc

Kathryn A. Keeler, MD; Keith H. Bridwell, MD; Lawrence G. Lenke, MD; Jennifer Flynn, BS

8:12 - 8:21 am

Discussion

8:22 - 8:26 am

Paper #4

Genetic Profile Predicts Curve Progression in Adolescent Idiopathic Scoliosis

Kenneth Ward, MD; Lesa M. Nelson, BS; Rakesh Chettier, MS; John T. Braun, MD; James W. Ogilvie, MD

8:26 - 8:30 am

Paper #5

Genetic Association Study of Collagen Ia2 Gene in Adolescent Idiopathic Scoliosis - A Study of 520-Cases

Hui Yan Yeung, PhD; Prof. Nelson L. Tang; Ms. Vivian W. Hung; Ms. Rachel Kwok; Kwong Man Lee, PhD; Ling Qin; Bobby Kinwah Ng, MD; Yong, Qui, MD; Jack Chun Yiu Cheng, MD

8:30 - 8:34 am

Paper #6

Predicting Brace-Resistant Adolescent Idiopathic Scoliosis
James W. Ogilvie, MD; Lesa M. Nelson, BS; Rakesh Chettier, MS; Ms. Therese Smith-Berry; Kenneth Ward, MD

8:34 - 8:43 am

Discussion

8:44 - 8:48 am

Paper #7

Revision Surgery after 1057 Primary Spine Fusions for Idiopathic Scoliosis over 19 Years: Identification of Causative Factors

Scott J. Luhmann, MD; Lawrence G. Lenke, MD; Keith H. Bridwell, MD

8:48 - 8:52 am

Paper #8

Multiple Level Simultaneous Front and Back Osteotomies of the Fusion Mass for Correction of Rigid Idiopathic Scoliosis with Failed Instrumentation

Yasser ElMiligui, MD, FRCS; Wael Koptan, MD; Hazem B. Elsebaie, FRCS, MD

8:52 - 8:56 am

Paper #9

Posterior Vertebral Column Resection (VCR) for Severe Pediatric Deformity: Minimum 2-year Follow-up on 29 Consecutive Patients

Lawrence G. Lenke, MD; Patrick T. O'Leary, MD; Brenda A. Sides, MA; Ms. Linda Koester; Ms. Marsha Hensley; Keith H. Bridwell, MD

8:56 - 9:05 am

Discussion

9:06 - 9:10 am

Paper #10

Increase Patient Satisfaction after Fusion for Adolescent Idiopathic Scoliosis by Minimizing the Deformity-Flexibility Quotient

Vidyadhar V. Upasani, MD; Peter O. Newton, MD; Jeff B. Pawelek, BS; Tracey P. Bastrom, MA; Lawrence G. Lenke, MD; Thomas G. Lowe, MD; David H. Clements, III, MD; Baron S. Lonner, MD; Randal R. Betz, MD; Harms Study Group

9:10 - 9:14 am

Paper #11

Selective Thoracic Fusion in Adolescent Idiopathic Scoliosis with Lenke Type 1C, 3C Or King Type 2 Lumbar Curves of More than 50 Degrees in Magnitude

Cagatay Ozturk, MD; Azmi Hamzaoglu, MD; Marco G. Teli, MD FGBOT; Mehmet Tezer, MD; Mehmet Aydogan, MD; Meric Enercan

9:14 - 9:18 am

Paper #12

5-Year Clinical and Radiographic Results of Selective Thoracic Fusion with Lumbar Curve >40 degrees.

Paul D. Sponseller, MD; Peter O. Newton, MD; Randal R. Betz, MD; David H. Clements, III, MD; Alvin H. Crauford, MD; Michael F. O'Brien, MD; Michelle C. Marks, PT, MA; Tracey P. Bastrom, MA

9:18 - 9:22 am

Paper #13

Backfilling of Iliac Crest Defects with Hydroxyapatite-Calcium Triphosphate Biphasic Compound: A Prospective, Randomized, Single-Blind CT And Patient-Based Analysis

Douglas C. Burton, MD; Barbara Manna, RN; Brandon B. Carlson, BS; Phillip Johnson, MD; Rudolph C. Glattes, MD

* Russell A. Hibbs Award Nominee for Best Clinical Presentation

** Russell A. Hibbs Award Nominee for Best Basic Science Presentation

Thursday, September 11, 2008 (continued)

9:22 - 9:34 am	Discussion
Early Onset Scoliosis	
9:35 - 9:39 am <i>Paper #14</i>	Complications in 910 Growing Rod Surgeries: Use of Dual Rods and Submuscular Placement of Rods Decreases Complications <i>R. Shay Bess, MD; Behrooz A. Akbarnia, MD; George H. Thompson, MD; Paul D. Sponseller, MD; David L. Skaggs, MD; Suken A. Shah, MD; Hazem B. Elsebaie, FRCS, MD; Oheneba Boachie-Adjei, MD; Lawrence I. Karlin, MD; Sarah K. Canale, BS; Connie Poe-Kochert, RN, BSN, CNP; Growing Spine Study Group</i>
9:39 - 9:43 am <i>Paper #15</i>	Neurologic Risk in Growing Rod Surgery in Children: Is Neuromonitoring Necessary in All Cases? <i>David L. Skaggs, MD; John B. Emans, MD; David S. Marks, FRCS; John P. Dormans, MD; George H. Thompson, MD; Suken A. Shah, MD; Paul D. Sponseller, MD; Behrooz A. Akbarnia, MD; Study Group Growing Spine</i>
9:43 - 9:49 am	Discussion
9:50 - 9:54 am <i>Paper #16</i>	Is Definitive Spinal Fusion, or VEPTR Removal, Needed after VEPTR Expansions Are Over? An Analysis of the 39 "VEPTR Graduates" <i>John M. Flynn, MD; Tricia St. Hilaire, BS; John B. Emans, MD; Randal R. Betz, MD; Robert M. Campbell, Jr., MD; John T. Smith, MD; Danielle Cameron, BA; Chest Wall and Spine Deformity Study Group</i>
9:54 - 9:58 am <i>Paper #17</i>	Vertebral Body Stapling: A Treatment Option for the Growing Child with Scoliosis <i>Randal Betz, MD; Ashish Ranade, MD; Amer F. Samdani, MD; Ross Chafetz, DPT, MPH; Linda P. D'Andrea, MD; Mr. John P. Gaughan; JahanGir Asghar, MD; Mr. Harsh Grewal; Ms. Mary Jane Mulcahey</i>
9:58 - 10:02 am <i>Paper #18</i>	Clinical Significance of a Corrective Cast/Brace in the Era of Non-Fusion Surgery (Treatment for Early Onset Scoliosis with A Corrective Cast) <i>Tsuji Taichi, MD; Noriaki Kawakami, MD; Kazuyoshi Miyasaka, MD; Tetsuya Ohara, MD; Ayato Nohara, MD</i>
10:02 - 10:11 am	Discussion
10:11 - 10:31 am	Break

SESSION II

Moderators: Sigurd H. Berven, MD
Khaled Kebaish, MD

Adult Spinal Deformity

10:32 - 10:36 am <i>Paper #19</i>	*Revision Rates Following Primary Adult Spinal Deformity Surgery: 667 Consecutive Patients Followed Up to 21 Years Postoperatively. <i>Mark Pichelmann, MD; Lawrence G. Lenke, MD; Christopher R. Good, MD; Patrick T. O'Leary, MD; Keith H. Bridwell, MD; Brenda A. Sides, MA</i>
10:36 - 10:40 am <i>Paper #20</i>	Survivorship of Primary Fusion for Adult Spinal Deformity: Rate, Reason, and Time of Reoperation <i>James M. Mok, MD; Mr. Jordan M. Cloyd; David S. Bradford, MD; Serena S. Hu, MD; Vedat Deviren, MD; Jason Smith, MD; Sigurd H. Berven, MD</i>
10:40 - 10:44 am <i>Paper #21</i>	Selection of Proximal Fusion Level for Degenerative Lumbar Scoliosis <i>Kyu-Jung Cho, MD; Se-Il Suk, MD; Kee-Yong Ha, MD; Rack-Yong Chung, MD; Man-Hee Won, MD; Hyung-suk Kim, MD</i>
10:44 - 10:53 am	Discussion
10:54 - 10:58 am <i>Paper #22</i>	Comparative Analysis of Two Hybrid Instrumentation Techniques for Adult Lumbar Scoliosis from the Thoracolumbar Spine to L5 or S1 <i>Yongjung J. Kim, MD; Oheneba Boachie-Adjei, MD; Keith H. Bridwell, MD; Lawrence G. Lenke, MD; Youngbae B. Kim, MD; Thomas W. Lawhorne, MD</i>
10:58 - 11:02 am <i>Paper #23</i>	Etiology and Revision Surgical Strategies in Failed Lumbosacral Fixation of Adult Spinal Deformity Constructs <i>Katsumi Harimaya, MD; Lawrence G. Lenke, MD; Keith H. Bridwell, MD; Takuya Mishiro, PhD, MD; Ms. Linda Koester; Brenda A. Sides, MA</i>
11:02 - 11:06 am <i>Paper #24</i>	Fusions to the Sacrum for Adult Spinal Deformity: How High Do you Go? (T2-4 vs T10-L1) The Effect on Sagittal Alignment and Outcomes. <i>Charles C. Edwards, II, MD; Keith H. Bridwell, MD; Michael R. Shainline, MS; William C. Horton, III, MD; Sigurd H. Berven, MD; Christopher I. Shaffrey, MD; Steven D. Glassman, MD; Christopher L. Hamill, MD; Stephen L. Ondra, MD</i>
11:06 - 11:15 am	Discussion

* Russell A. Hibbs Award Nominee for Best Clinical Presentation

** Russell A. Hibbs Award Nominee for Best Basic Science Presentation



11:16 - 11:20 am **Extension of Fusion to Sacrum in Patients who had Previous Thoracolumbar Fusions to L5: Is it Simple or Complex Surgery?**
Paper #25
Murat Pekmezci, MD; Vedat Deviren, MD; Sigurd H. Berven, MD; Ms. Erin Boyd; Ganesh Swamy, MD; David S. Bradford, MD; Serena S. Hu, MD

11:20 - 11:24 am ***A Matched Cohort Study of Long Adult Spinal Deformity Surgery to the Sacrum/ Ilium Using rhBMP-2 versus Autogenous Iliac Crest Bone Graft**
Paper #26
Takeshi Maeda, MD; Jacob M. Buchowski, MD, MS; Keith H. Bridwell, MD; Ms. Linda Koester

11:24 - 11:30 am Discussion

11:31 - 11:35 am **Operative versus Non-Operative Treatment of Leg Pain in Adults with Scoliosis: A Retrospective Review of a Prospective Multicenter Database with Two-Year Follow-Up**
Paper #27
Justin S. Smith, MD, PhD; Christopher I. Shaffrey, MD; Sigurd H. Berven, MD; Steven D. Glassman, MD; Christopher L. Hamill, MD; William C. Horton, III, MD; Stephen L. Ondra, MD; Frank J. Schwab, MD; Kai-Ming Fu, MD, PhD; Keith H. Bridwell, MD

11:35 - 11:39 am **“Surgical Outcomes of Decompression, Decompression with Limited Fusion and Decompression with Full Curve Fusion for Degenerative Scoliosis with Radiculopathy”**
Paper #28
Raymond Topp, MD; Ensor E. Transfeldt, MD; Amir A. Mehdod, MD; Robert B. Winter, MD

11:39 - 11:45 am Discussion

11:45 - 11:50 am **Harrington Lecture Introduction**

11:51 am -12:11 pm **Harrington Lecture**
Marc A. Asher, MD

8:04 - 8:08 am **Sagittal Spino-Pelvic Alignment in Developmental Spondylolisthesis and its Potential Relevance for Reduction**
Paper #30
Jean-Marc Mac-Thiong, MD, PhD; Zhi Wang, MD; Jacques A. de Guise, PhD; Hubert Labelle, MD

8:08 - 8:12 am **Radiological Assessment of L4-L5 Segment and Sacral Position after Surgical Reduction of L5-S1 Severe Spondylolisthesis and Spondyloptosis Throughout a Single Posterior Approach.**
Paper #31
Jesus Burgos, MD; Prof. Carlos Barrios; Ignasi Sampera, MD; Eduardo Hevia, MD; Pedro Domenech, MD; Pedro R. Gutierrez, MD, PhD; Gabriel Piza, MD; Oscar G. Riquelme-García, MD, PhD; Ignacio Alvarez, MD; José I. Maruenda, MD; Enrique Recarte, MD

8:12 - 8:16 am **The Relationship between Pelvic Balance and a Dome-Shaped Sacrum in L5-S1 Developmental Spondylolisthesis**
Paper #32
Pierre Roussouly, MD; Hubert Labelle, MD; Eric Berthonnaud, PhD; Serena S. Hu, MD; Courtney W. Brown, MD

8:16 - 8:28 am Discussion

Cervical Reconstruction

8:29 - 8:33 am **Stand-Alone Anterior Reconstruction in Cervical Kyphosis: A Prospective Analysis**
Paper #33
Mihir R. Bapat, MS; Nanjundappa S. Harshavardhana, MS(Orth), Dip. SICOT; Kshitij S. Chaudhary, MS, DNB; Umesh S. Metkar, MS; Satyajit V. Marawar, MD; Prof. Vinod J. Laheri

8:33 - 8:37 am **Circumferential Correction of Cervical Kyphosis Results in Improved Outcomes**
Paper #34
Sanjay S. Dhall, MD; Regis W. Haid, MD; Praveen V. Mummaneni, MD

8:37 - 8:43 am Discussion

Tumors

8:44 - 8:48 am **Involvement of the Spine in Patients with Multiple Hereditary Exostosis (MHE)**
Paper #35
James W. Roach, MD; Joshua B. Klatt, MD; Nathan D. Faulkner, MS

8:48 - 8:52 am **Posterior Stabilization Following Oncologic Resection of the Cervicothoracic Junction: A Review of 90 Consecutive Cases**
Paper #36
Peter S. Rose, MD; Ilya Laufer, MD; Jasmine Beria, MPH; Andrew R. Hanover, BA; Mark Bilsky, MD; Patrick Boland, MD

Friday, September 12, 2008

7:55-8:00 am Announcements

SESSION III
Moderators: *Serena S. Hu, MD; Noriaki Kawakami, MD*

Spondylolisthesis

8:00 - 8:04 am **Effects of Early Correction in High Grade Developmental Spondylolisthesis L5/S1 on Sagittal Profile and Clinical Outcome**
Paper #29
Michael Ruf, MD; Rubens Jensen, MD; Prof. Harry R. Merk; Torsten Eichhorn, MD; Prof. Jürgen Harms, MD

* Russell A. Hibbs Award Nominee for Best Clinical Presentation

** Russell A. Hibbs Award Nominee for Best Basic Science Presentation

Friday, September 12, 2008 (continued)

8:52 - 8:56 am
Paper #37
Long Term Clinical Outcomes Following Attempted en bloc Resections for Malignant Primary Sacral Tumors
Patrick C. Hsieh, MD; Risheng Xu, BS; Matthew Megirt, MD; Daniel M. Sciubba, MD; Clarke Nelson, BS; Jean-Paul Wolinsky, MD; Ziya L. Gokaslan, MD

8:56 - 9:00 am
Paper #38
Risk Factors for Vertebral Fracture Following Single Fraction Intensity Modulated Radiation Therapy for Spinal Metastases
Peter S. Rose, MD; Ilya Laufer, MD; Andrew R. Hanover, BA; Eric Lis, MD; Yoshiya Yamada, MD; Mark Bilsky, MD; Patrick Boland, MD

9:00 - 9:12 am
Discussion

Neuromuscular Scoliosis

9:13 - 9:17 am
Paper #39
5-Year Radiographic Results of Long Scoliosis Fusion in Juvenile Spinal Muscular Atrophy Patients: Crankshaft and Ultimate Correction
Lukas P. Zebala, MD; Keith H. Bridwell, MD; Christine Baldus, RN, MHS; B. Stephens Richards, III, MD; John P. Dormans, MD; Lawrence G. Lenke, MD; Joshua D. Auerbach, MD

9:17 - 9:21 am
Paper #40
Spinal Fusion for Spastic Neuromuscular Scoliosis (NMS): Is Anterior Releasing Necessary When Intraoperative Halo-Femoral Traction is Used
Kathryn A. Keeler, MD; Scott J. Luhmann, MD; Lawrence G. Lenke, MD; Christopher R. Good, MD; Brenda A. Sides, MA; Mario Shootman, PhD; Keith H. Bridwell, MD

9:21 - 9:25 am
Paper #41
30 Years of Experience with Infections in Pediatric Neuromuscular Spinal Deformity Surgery
Patrick J. Cahill, MD; Drew E. Warnick, MD; Michael J. Lee, MD; Lawrence C. Vogel, MD; Kim W. Hammerberg, MD; Peter F. Sturm, MD

9:25 - 9:34 am
Discussion

9:35 - 9:39 am
Paper #42
Progression of Scoliosis in Non Ambulatory Duchenne Muscular Dystrophy Patients
Frederic Shapiro, MD; David Zurakowski, PhD; Basil T. Darras, MD

9:39 - 9:43 am
Paper #43

9:43 - 9:49 am

Lumbar Deformity

9:50 - 9:54 am
Paper #44

9:54 - 9:58 am
Paper #45

9:58 - 10:02 am
Paper #46

10:02 - 10:11

10:11 - 10:31

SESSION IV

Moderators:

Innovative Methods

10:32 - 10:36 am
Paper #47

10:36 - 10:40 am
Paper #48

Spinal Deformity Correction in Duchenne Muscular Dystrophy: Sublaminar Wiring Fixation versus Pedicle Screw Instrumentation
Ujjwal K. Debnath, FRCS, FRCS; Hossein Mehdian FRCS, MD; Harshad Dabke, FRCS; A.S. Hoakazemi; Nanjundappa S. Harshavardhana, MS(Orth), Dip. SICOT; Brian J. Freeman, MD; John K. Webb, MBBS, FRCS

Discussion

Spondylolysis Repair with Rigid Fixation: A Prospective Clinical and Radiographic Outcome Study
Matthew D. Hepler, MD; Mr. Matthew Walker; Eugene P. Lautenschlager, PhD

Dynamic Stabilization and Laminectomy in Degenerative Lumbar Scoliosis of Elderly Patients
Mario Di Silvestre, MD; Georgios Bakaloudis, MD; Francesco Lolli, MD; Patrizio Parisini, MD

TLIF vs ALIF as an Adjunct to Posterior Instrumented Correction of Degenerative Lumbar Scoliosis: 3 Year Clinical and Radiographic Outcomes
Dennis Crandall, MD; Jan Revella, RN

Discussion

Break

*Bernard A. Rawlins, MD
B. Stephens Richards, III, MD*

Use of Vertebroplasty to Prevent Proximal Junctional Kyphosis in Adult Spinal Deformity Surgery: A Biomechanical Cadaveric Study.
Ivan E. LaMotta, MD; Gabor Voros, MD; Joseph R. O'Brien, MD; Stephen Belkoff, MD; Khaled Kebaish, MD

Preoperative Inferior Vena Cava Filters for Major Spinal Reconstruction in Adults
Timothy R. Kuklo, MD, JD; Michael Rosner, MD; Stephen L. Ondra, MD; Brian A. O'Shaughnessy, MD; Jamal McClendon, MD

* Russell A. Hibbs Award Nominee for Best Clinical Presentation

** Russell A. Hibbs Award Nominee for Best Basic Science Presentation



10:40 - 10:44 am
Paper #49

CT and Biomechanical Evaluation of Screw Fixation Options at the Cervicothoracic Junction: Intralaminar vs. Intrapedicular Techniques
Mario J. Cardoso, MD, DC; Anton E. Dmitriev, MSc; Ronald A. Lehman, MD; Melvin D. Helgeson, MD; Patrick B. Cooper, MD; Michael Rosner, MD

10:44 - 10:48 am
Paper #50

Shilla Growth Enhancing System for the Treatment of Scoliosis in Children: Greater than Two Year Follow-Up
Richard E. McCarthy, MD; France L. McCullough, MNSc; Scott J. Luhman, MD; Lawrence G. Lenke, MD

10:48 - 11:00 am Discussion

Other

11:01 - 11:06 am
Paper #51

Treatment of Spinal Deformities in Patients with Diastrophic Dysplasia (DD) - A Long-Term, Retrospective, Nationwide Study
Tuomas Jalanko, MS; Ville Remes, MD, PhD; Jari Peltonen, MD; Asst. Prof. Mikko S. Poussa; Ilkka Helenius, MD

11:06 - 11:10 am
Paper #52

Scoliosis and the Effects of Growth Hormone Treatment in Children with Prader-Willi Syndrome
Roderick F. de Lind van Wijngaarden, MSc; Luuk W. de Klerk, MD, PhD; Dederieke A. Festen, MD, PhD; Barto J. Otten, MD, PhD; Anita C. Hokken-Koelega, MD PhD

11:10 - 11:14 am
Paper #53

Lumbar Plexus Nerve Root Position within the Psoas Muscle: An Anatomic Study
Carl Paulino, MD; Nael Shanti, MD; Martin Quirno, MD; Jeffrey M. Spivak, MD

11:14 - 11:23 am Discussion

Adult Spinal Deformity

11:24 - 11:28 am
Paper #54

***Does Treatment (Nonoperative and Operative) Help Patients with Adult Symptomatic Lumbar Scoliosis: A Prospective Multicenter Evidence-Based Medicine Study**
Lukas P. Zebala, MD; Keith H. Bridwell, MD; Steven D. Glassman, MD; William C. Horton, III, MD; Christopher I. Shaffrey, MD; Frank J. Schwab, MD; Joan F. Hilton, ScD; Michael R. Shainline, MS; Christine Baldus, RN, MHS; David Wootten, PhD

11:28 - 11:32 am
Paper #55

Functional Outcomes and Complications Following Primary Spinal Surgery for Scoliosis in Adults Age 40 Years and Older: A Prospective Study with a Minimum 2-Year Follow-Up
Ryan M. Zimmerman, BS; Khaled Kebbish, MD; Ahmed S. Mohamed, M.B.B.Ch., MSc Ortho.; Richard Skolasky, ScD; Malaya Robinson, RN, BSN, RNFA

11:32 - 11:36 am
Paper #56

Pedicle Subtraction versus Smith Petersen Osteotomies for Correction of Fixed Sagittal Plane Deformities: Clinical and Radiographic Outcomes in 151 Patients
Brian Hsu, MB BS, FRACS; Amir A. Mehbod, MD; Prof. Serkan Erkan; Ensor E. Transfeldt, MD; Joseph H. Perra, MD; Francis Denis, MD; Timothy Garvey, MD; Manuel R. Pinto, MD; James D. Schwender, MD; Daryll C. Dykes, MD, PhD; John E. Lonstein, MD; Robert B. Winter, MD

11:36 - 11:45 am Discussion

11:46 - 11:49 am 2009 IMAST Preview

11:50 - 11:53 am 2009 Annual Meeting Preview

11:54 - 11:57 am Worldwide Regional Meeting Preview

11:57 am - 12:02 pm Introduction of President

12:03 - 12:23 pm Presidential Address

12:23 - 1:20 pm Lunch

SESSION V

*Moderators: Ian A. Stokes, PhD
John M. Flynn, MD*

Trauma/Adult Deformity

1:20 - 1:24 pm
Paper #57

Early Complications of Methylprednisolone Sodium Succinate (MPSS) in the Treatment of Acute Cervical Spinal Cord Injury
Yasuo Ito, MD, PhD; Y. Sugimoto, MD

1:24 - 1:28
Paper #58

Inflammatory Cytokine Expression and the Development of Injury-Severity Biomarkers after Human Spinal Cord Injury
Anthea M. Stammers, MSc; Lise Belanger, RN, BSN, MSN; Donna Chan, RN; Arlene Bernardo, RN; Hamed Umedaly, MD; Wolfram Tetzlaff, MD, PhD; Mitch Giffin, MD; Scott C. Paquette, MD; Michael C. Boyd, MD, MSc; John Street, MD; Charles Fisher, BSc, MHSc, MD, FRCSC; Marcel F. Dvorak, MD; Brian K. Kwon, MD, PhD

* Russell A. Hibbs Award Nominee for Best Clinical Presentation
** Russell A. Hibbs Award Nominee for Best Basic Science Presentation

Friday, September 12, 2008 (continued)

- 1:28 - 1:32 pm
Paper #59
Magnesium in a Polyethylene Glycol Formulation Provides Neuroprotection after Acute Spinal Cord Injury
Brian K. Kwon, MD, PhD; Josee Roy, PhD; Jae H. Lee, BSc; Jie Liu, MD; Anthea M. Stammers, MSc; Jeffrey Marx, PhD
- 1:32 - 1:41 pm
Discussion
- 1:42 - 1:46 pm
Paper #60
Increasing Lumbar Lordosis of Adult Spinal Deformity Patients via Intraoperative Prone Positioning
Katsumi Harimaya, MD; Takuya Mishiro, PhD, MD; Lawrence G. Lenke, MD; Keith H. Bridwell, MD; Ms. Linda Koester; Brenda A. Sides, MA
- 1:46 - 1:50 pm
Paper #61
A New Way of Assessing Sagittal Balance: A Radiologic Study of 232 Asymptomatic Individuals
Sebastien Charosky, MD; Ian J. Harding, BA, FRCS (Orth); Raphael Vialle, MD, PhD; Eric Berthonnaud, PhD; Pierre Roussouly, MD; Daniel Chopin, MD
- 1:50 - 1:54 pm
Paper #62
Long Term Clinico-Radiological Outcomes after Surgical Treatment of Scheuermann's Kyphosis (SK): A UK Experience of 35 Cases with a Average Follow-up of 9 Years
Nanjundappa S. Harshavardhana, MS(Orth), Dip. SICOT; Hossein Mehdian FRCS, MD; Harshad Dabke, FRCS; Ujjwal K. Debnath, FRCS; John K. Webb, MBBS, FRCS
- 1:54 - 2:03 pm
Discussion
- 2:04 - 2:08 pm
Paper #63
Increasing Pain and Disability, Rather than Deformity, Determine Treatment Modality for Older Patients with Adult Scoliosis
Oheneba Boachie-Adjei, MD; R. Shay Bess, MD; Matthew E. Cunningham, MSc; Douglas C. Burton, MD; Christopher I. Shaffrey, MD; Alexis P. Shelokov, MD; Richard A. Hostin, MD; Frank J. Schwab, MD; Kirkham Wood, MD; Munish C. Gupta, MD; Behrooz A. Akbarnia, MD, International Spine Study Group
- 2:08 - 2:12 pm
Paper #64
***Clinical Instinct versus Standardized Questionnaire: The Spinal Surgeons Ability to Detect Psychological Distress.**
Michael D. Daubs, MD; Alpesh Patel, MD; Darrel S. Brodke, MD
- 2:12 - 2:18 pm
Discussion
- 2:19 - 2:23 pm
Paper #65
RT-PCR and Microarray Experimental Study for the Impact of Methylprednisolone and Sodium Channel Blocker on Axonal Growth after Acute Spinal Cord Injury in Rats
Jun-Young Yang, MD, PhD; Prof. June Kyu Lee; Ho sup Song, MD; Eui Pyo Hong, MD
- 2:23 - 2:27 pm
Paper #66
Transplantation of Human Marrow Stromal Cells and Mono-Nuclear Bone Marrow Cells into the Injured Spinal Cord: A Comparative Study
Amer F. Samdani, MD; Courtney Paul, BS; Birgit Neuhuber, PhD; Randal R. Betz, MD; Itzhak Fischer, PhD
- 2:27 - 2:33 pm
Discussion
- Basic Science**
(Russell A. Hibbs Award Nominees for Best Basic Science Presentation)
- 2:34 - 2:38 pm
Paper #67
****VEPTR Improves Pulmonary Hypoplasia in a Postnatal Rabbit Model of Thoracic Insufficiency Syndrome**
Hemal P. Mehta, MSc.; Brian D. Snyder, MD, PhD; Stephen R. Baldassarri, BA; Melissa J. Hayward, MD; Michael J. Giuffrida, MD; Supriya P. Bansal, BS; Vahid Entezari, MD; Nipun D. Patel, MS; Andrew C. Jackson, PhD
- 2:38 - 2:42 pm
Paper #68
****Transient Short Term Local Bone Remodeling Effects of High-Doses of rhBMP-2 in a Novel Preclinical Interbody Spine Fusion Model**
Hyun Bae, MD; Ben B. Pradhan, MD, MSE; Vikas V. Patel, MA, MD; Jeffrey M. Toth, PhD; Jeffrey M. Badura, MS; Howard B. Seim, DVM; A. Simon Turner, BVSc, MS, Dipl. ACVS
- 2:42 - 2:46 pm
Paper #69
****Porcine Scoliosis Model Based on Animal Growth Created with Minimal Invasive Off-Set Tethering**
Thierry Odent, MD; Thibault Cachon, MV; Mr. Bertrand Peultier; Mr. José Gournay; Mr. Erwan Jolivet; Prof. Eric Viguiier
- 2:46 - 2:55 pm
Discussion
- 2:56 - 3:00 pm
Paper #70
****The Effect of Calmodulin Antagonists on The Incidence and Magnitude of Scoliosis in Pinealectomized Chicken and Bipedal C57BL/6 Mice**
Ibrahim Akel, MD; Gokhan H. Demirkiran, MD; Ahmet Alanay, MD; Ralph Marcucio, MD; Emre R. Acaroglu, MD

* Russell A. Hibbs Award Nominee for Best Clinical Presentation

** Russell A. Hibbs Award Nominee for Best Basic Science Presentation



3:00 - 3:04 pm <i>Paper #71</i>	**Effect of Teriparatide [rhPTH(1,34)] and Calcitonin on Intertransverse Process Fusion in a Rabbit Model <i>Ronald A. Lehman, Jr., MD; Anton E. Dmitriev, MSc; Mario J. Cardoso, MD, DC; Christen Christensen; Melvin D. Helgeson, MD; Timothy R. Kuklo, MD, JD; K. Daniel Riew, MD</i>	4:00 - 4:04 pm <i>Paper #76</i>	Elevated Plasma Factor P is Involved in AIS Onset and Curve Progression <i>Alain Moreau, PhD; Anita Franco, MSc; Bouziane Azeddine, MSc; Pierre H. Rompré, MSc; Isabelle Turgeon, BSc; Keith M. Bagnall, PhD; Benoît Poitras, MD; Hubert Labelle, MD; Charles-Hilaire Rivard, MD; Guy Grimard, MD; Jean Ouellet, MD; Stefan Parent, MD, PhD; Mrs. Ginette Larouche; Mrs. Ginette Lacroix</i>
3:04 - 3:08 pm <i>Paper #72</i>	**Sacral-Pelvic Fixation: A Biomechanical Comparison Between Constructs Ending with S2 Bicortical Bitriangulated (BCBT) Screws and Iliac Screws <i>William C. Horton, III, MD; JinHwan Kim, MD, PhD; Takahiko Hamasaki, MD; Brett A. Freedman, MD; William C. Hutton, DSc</i>	4:04 - 4:08 pm <i>Paper #77</i>	Pre-Operative CT Does Not Appear to Improve Accuracy of Pedicle Screw Placement and Exposes the Patient to Increased Quantities of Radiation. <i>John K. Czerwejn, MD; Terry Amaral, MD; Adam L. Wollowick, MD; Alok D. Sharan; Beverly Thornhill, MD; Vishal Sarwahi, MD</i>
3:08 - 3:17 pm	Discussion	4:08 - 4:12 pm <i>Paper #78</i>	New Parameters to Represent the Position of the Aorta Relative to the Spine for Pedicle Screw Placement <i>Katsushi Takeshita, MD; Toru Maruyama, MD; Hirotaka Chikuda, MD; Takashi Ono, MD; Naoki Shoda, MD; Kozo Nakamura, MD</i>
3:17 - 3:37 pm	Break		Discussion
SESSION VI			
Moderators:	<i>Muharrem Yazici, MD Michael F. O'Brien, MD</i>		
Adolescent Idiopathic Scoliosis			
3:38 - 3:42 pm <i>Paper #73</i>	Thoracic Pedicle Screw Instrumentation The Learning Curve in Adolescent Idiopathic Scoliosis <i>Baron S. Lomner, MD; Joshua D. Auerbach, MD; Michael B. Estreicher, BA; Kristin E. Kean, BA</i>	4:12 - 4:21 pm	Discussion
		4:22 - 4:26 pm <i>Paper #79</i>	Intrathecal Morphine Administration for Preemptive Analgesia in Children Undergoing Posterior Spinal Instrumentation and Fusion for Idiopathic Scoliosis <i>Jochen P. Son-Hing, MD, FRCSC; Paul A. Tripi, MD; Jennifer M. Potzman, MD; Connie Poe-Kochert, RN, BSN, CNP; George H. Thompson, MD</i>
3:42 - 3:46 pm <i>Paper #74</i>	The Majority of Initial Coronal Imbalance Following Fusion Surgery for AIS Improves within Six Months <i>JahanGir Asghar, MD; Daniel M. Sciubba, MD; Amer F. Samdani, MD; Patrick J. Cahill, MD; David H. Clements, III, MD; M. Darryl Antonacci, MD, FACS; Randal R. Betz, MD; Harms Study Group</i>	4:26 - 4:30 pm <i>Paper #80</i>	Halo-Gravity Traction in Severe Pediatric Spinal Deformity <i>Kristina Walick, MD; Anna McClung, RN; Daniel J. Sucato, MD, MS; Charles E. Johnston, MD</i>
3:46 - 3:50 pm <i>Paper #75</i>	Significance of Intraoperative Thoracic Kyphosis Increase to Prevent the Proximal Junctional Kyphosis in Adolescent Idiopathic Scoliosis Following Posterior Segmental Spinal Instrumentation And Fusion: A Multicenter Analysis of 518 Cases <i>Yongjung J. Kim, MD; Lawrence G. Lenke, MD; Keith H. Bridwell, MD; Oheneba Boachie-Adjei, MD; Naobumi Hosogane, MD; Youngbae B. Kim, MD</i>	4:30 - 4:34 pm <i>Paper #81</i>	Is Extended Preoperative Halo Traction Safe and Effective for Severe Pediatric Spinal Deformity? Critical Review of 62 Pediatric Patients <i>Timothy R. Kuklo, MD, JD; Kathryn A. Keeler, MD; Laura A. Meyer, MA; Scott J. Luhmann, MD; Keith H. Bridwell, MD; Lawrence G. Lenke, MD</i>
3:50 - 3:59 pm	Discussion	4:34 - 4:43 pm	Discussion
		4:44 - 4:48 pm <i>Paper #82</i>	A 13-14 Year Follow Up of Outcome for Fusions in Idiopathic Scoliosis <i>Colin Nnadi, FRCS(Orth); Prakash Jayakumar, MRCS; Satoshi Hori B.Sc, MB BS, MRCS; Mr. Adrian Casey; David Harrison, FRCS; Mr. Ben Taylor; Dimitri A. Raptis, MRCS</i>

* Russell A. Hibbs Award Nominee for Best Clinical Presentation

** Russell A. Hibbs Award Nominee for Best Basic Science Presentation

Friday, September 12, 2008 (continued)

- 4:48 - 4:52 pm
Paper #83
- Fixation Points Within the Main Thoracic Curve: Does More Instrumentation Produce Greater Curve Correction?**
James O. Sanders, MD; Mohammad Diab, MD; B. Stephens Richards, III, MD; Lawrence G. Lenke, MD; Charles E. Johnston, MD; John B. Emans, MD; Daniel J. Sucato, MD, MS; Mark A. Erickson, MD; Keith H. Bridwell, MD; Richard E. McCarthy, MD; John F. Sarwark, MD; John P. Dormans, MD; Timothy R. Kuklo, MD, JD; Michael R. Shainline, MS; Spinal Deformity Study Group
- 4:52 - 4:56 pm
Paper #84
- 'Don't End your Fusion at T12 in Idiopathic Scoliosis': Wisdom or Myth?**
John M. Flynn, MD; Tracey P. Bastrom, MA; Peter O. Newton, MD; Lawrence G. Lenke, MD; Alvin H. Crawford, MD; Thomas G. Lowe, MD; Randal R. Betz, MD; David H. Clements, III, MD; Baron S. Lonner, MD; Michelle C. Marks, PT, MA; Harms Study Group
- 4:56 - 5:05 pm
Discussion

Saturday, September 13, 2008

- 7:55 - 8:00 am
Announcements
- SESSION VII**
Moderators: Lori A. Karol, MD; David L. Skaggs, MD
- Adolescent Idiopathic Scoliosis**
- 8:00 - 8:04 am
Paper #85
- Quality of Life in Adult AIS Patients - Comparison Between Untreated and Brace Treated Patients**
Aina J. Danielsson, MD, PhD; Ralph Hasserius, PhD; Acke Ohlin, MD, PhD; Alf Nachemson, MD, PhD
- 8:04 - 8:08 am
Paper #86
- The Association between the SRS-22 and Scoliosis Severity Changes at a Clinically Relevant Threshold**
Eric C. Parent, PT, MSc, PhD; Mr. Daniel L. Wong; Douglas L. Hill, P.Eng, MBA; James Mahood, MD; Marc Moreau, MD, FRCS(C); Jim Raso, MASC; Edmond Lou, PhD
- 8:08 - 8:12 am
Paper #87
- Hospital Costs Associated with Surgical Treatment of Adolescent Idiopathic Scoliosis**
Charles T. Mehlman; DO, MPH; Jun Ying, PhD; Cassie L. Kirby, BA
- 8:12 - 8:21 am
Discussion

8:22 - 8:26 am
Paper #88

Change in Thoracic Sagittal Alignment Following Posterior Instrumentation for Lenke 1A and B Curves
James O. Sanders, MD; John P. Dormans, MD; Timothy R. Kuklo, MD, JD; Lawrence G. Lenke, MD; B. Stephens Richards, III, MD; Charles E. Johnston, MD; Daniel J. Sucato, MD, MS; John B. Emans, MD; Mohammad Diab, MD; Michael R. Shainline, MS; Spinal Deformity Study Group

8:26 - 8:30 am
Paper #89

Preservation of Thoracic Kyphosis: A Critical Component to Maintaining Post-Operative Lumbar Lordosis during the Surgical Treatment of Adolescent Idiopathic Scoliosis
Vidyadhar V. Upasani, MD; Peter O. Newton, MD; Jeff B. Pawelek, BS; Tracey P. Bastrom, MA; Lawrence G. Lenke, MD; Thomas G. Lowe, MD; Alvin H. Crawford, MD; Randal R. Betz, MD; Baron S. Lonner, MD; Harms Study Group

8:30 - 8:34 am
Paper #90

3D Sub-Classification of Lenke 1 Curves
Archana P. Sangole, PhD; Carl-Éric Aubin, PhD, P.Eng; Hubert Labelle, MD; Lawrence G. Lenke, MD; Ian A. Stokes, PhD; Peter O. Newton, MD; Roger P. Jackson, MD

8:34 - 8:43 am

Discussion

8:44 - 8:48 am
Paper #91

Treatment Outcome and Patient's Acceptance of a Dynamic Corrective Brace vs Rigid Bracing System for AIS Girls - A Randomized Controlled Trial with Follow Up Till Skeletal Maturity
Tsz-ping Lam; MB, BS; Man-sang Wong, PhD; Bobby Kin-wah Ng, MD; Mr. Sai-wing Sin; Ms. Hoi-kei Rachel Kwok; Ms. Lai-fong Sandra Shum; Prof. Daniel Hung-kay Chow; Jack Chun Yiu Cheng, MD

8:48 - 8:52 am
Paper #92

Relative Contributions of Discal and Vertebral Wedging to Cobb Angle Progression During the Adolescent Growth Spurt
Ryan Will, MD; Ian A. Stokes, PhD; Xing Qiu, MD; Mr. Matthew Walker; James O. Sanders, MD

8:52 - 8:56 am
Paper #93

Post Operative Trunk Flexibility Loss is Modest but Incremental as the Fusion Progresses Distally
Peter O. Newton, MD; Michelle C. Marks, PT, MA; Tracey P. Bastrom, MA; Randal R. Betz, MD; David H. Clements, III, MD; Baron S. Lonner, MD; Alvin H. Crawford, MD; Lynn Letko, MD; Harry L. Shufflebarger, MD; Michael F. O'Brien, MD

8:56 - 9:05 am

Discussion

* Russell A. Hibbs Award Nominee for Best Clinical Presentation

** Russell A. Hibbs Award Nominee for Best Basic Science Presentation



<p>9:06 - 9:10 am <i>Paper #94</i></p>	<p>Postoperative Left Shoulder Elevation (LSE): An Unexpected Consequence of Surgical Correction of Lenke 1 Main Thoracic Curves <i>Michael F. O'Brien, MD; Harry L. Shufflebarger, MD; Angel Macagno, MD; Michelle C. Marks, PT, MA; Tracey P. Bastrom, MA; Randal R. Betz, MD; Peter O. Newton, MD; Baron S. Lonner, MD; Alvin H. Crawford, MD; Suken A. Shah, MD; Harms Study Group</i></p>	<p>10:32 - 10:36 am <i>Paper #98</i></p>	<p>Can We Safely Reduce Blood Loss During Lumbar Pedicle Subtraction Osteotomy Procedures using Tranexamic Acid or Aprotinin? A Comparative Study with Controls. <i>Christine Baldus, RN MHS; Keith H. Bridwell, MD; Gbolahan O. Okubadejo, MD; Lawrence G. Lenke, MD</i></p>
<p>9:10 - 9:14 <i>Paper #95</i></p>	<p>Surgeon Reliability for Assessing Shoulder Height in AIS Patients with Double Thoracic Curves <i>Bryan Tompkins, MD; Daniel J. Sucato, MD, MS; Anna McClung, RN</i></p>	<p>10:36 - 10:40 am <i>Paper #99</i></p>	<p>Epsilon Aminocaproic Acid (EACA) Reduces Postoperative Red-Cell Transfusion Requirements in Patients Undergoing Major Spinal Surgery: A Prospective, Randomized, Placebo-Controlled Trial in 182 Patients. <i>Sean Berenholtz, MD, MHS, FCCM; Khaled Kebaish, MD; Julius Pham, MD; Elizabeth Garrett-Mayer, PhD; David B. Cohen, MD; John Kostuik, MD; Peter J. Pronovost, MD, PhD, FCCM; Todd Dorman, MD</i></p>
<p>9:14 - 9:18 am <i>Paper #96</i></p>	<p>Impact of Idiopathic Scoliosis and its Surgical Treatment on Appearance in Children. <i>Mohammad Diab, MD; Timothy R. Kuklo, MD, JD; James O. Sanders; Lawrence G. Lenke, MD; Daniel J. Sucato, MD, MS, Spinal Deformity Group</i></p>	<p>10:40 - 10:44 am <i>Paper #100</i></p>	<p>Efficacy of Intraoperative Cell Salvage Machines in Pediatric Spinal Deformity Surgery <i>Richard E. Bowen, MD; Stephen Gardner, BS; Anthony A. Scaduto, MD; Michael J. Eagan, MD; Jason Beckstead, MD</i></p>
<p>9:18 - 9:27 am</p>	<p>Discussion</p>	<p>10:44 - 10:56 am</p>	<p>Discussion</p>
<p>9:28 - 9:32 am</p>	<p>Transfer of Presidency</p>	<p>10:57-11:01 am <i>Paper #101</i></p>	<p>Prevention of Surgical Site Infection Following Spinal Instrumentation Surgery. Is Postoperative Antimicrobial Prophylaxis Indispensable? <i>Hiroshi Taneichi, MD; Kota Suda, MD; Tomomichi Kajino, MD; Hiroshi Moridaira, MD; Yutaka Nohara, MD</i></p>
<p>9:32 - 10:07 am</p>	<p>Awards Presentation Russell A. Hibbs Awards Louis A. Goldstein Award John H. Moe Award Blount Award • <i>Behrooz A. Akbarnia, MD</i> Lifetime Achievement Award • <i>John E. Hall, MD</i> • <i>Jacqueline Perry, MD, DSc</i></p>	<p>11:01-11:05 am <i>Paper #102</i></p>	<p>Major Perioperative Neurologic Deficits in Pediatric and Adult Spine Surgery Patients: Incidence; Etiology and Outcomes over a Fourteen Year Period at One Institution <i>Christopher R. Good, MD; Keith H. Bridwell, MD; Patrick T. O'Leary, MD; Mark Pichelmann, MD; Lawrence G. Lenke, MD; K. Daniel Riew, MD; Scott J. Luhmann, MD; Timothy R. Kuklo, MD, JD; Jacob M. Buchowski, MD, MS; Jennifer Flynn, BS</i></p>
<p>10:07 - 10:27 am</p>	<p>Break</p>		<p>Discussion</p>
<p>SESSION VIII</p>			
<p>Moderators:</p>	<p><i>Behrooz A. Akbarnia, MD</i> <i>Steven M. Mardjetko, MD, FAAP</i></p>		
<p>Complications</p>			
<p>10:28 - 10:32 am <i>Paper #97</i></p>	<p>Is Hypotensive Anesthesia Effective at Reducing Blood Loss During Pediatric Spine Fusion? <i>Richard E. Bowen, MD; Stephen Gardner, BS; Anthony A. Scaduto, MD; Michael J. Eagan, MD; Jason Beckstead, MD</i></p>	<p>11:05-11:11 am</p>	<p>Discussion</p>

* Russell A. Hibbs Award Nominee for Best Clinical Presentation
** Russell A. Hibbs Award Nominee for Best Basic Science Presentation

Saturday, September 13, 2008 (continued)

Adult Spinal Deformity

11:12-11:16 am
Paper #103
What Radiographic Sagittal Parameters Correlate with Improved SRS Self-Image Scores Postoperatively in Patients with Sagittal Imbalance: An Analysis of 102 Lumbar Pedicle Subtraction Osteotomy Patients
Yongjung J. Kim, MD; Keith H. Bridwell, MD; Lawrence G. Lenke, MD; Oheneba Boachie-Adjei, MD; Youngbae B. Kim, MD; Jacob M. Buchowski, MD, MS

11:16-11:20 am
Paper #104
Does Vertebral Level of Pedicle Subtraction Osteotomy Correlate with Degree of Spino-Pelvic Parameter Correction?
Frank J. Schwab, MD; Virginie Lafage, PhD; Ashish Patel, MD; Robert A. Hart, MD; Douglas C. Burton, MD; Oheneba Boachie-Adjei, MD; Alexis P. Shelokov, MD; Richard A. Hostin, MD; Christopher I. Shaffrey, MD; Munish C. Gupta, MD; Behrooz A. Akbarnia, MD; R. Shay Bess, MD

11:20-11:24 am
Paper #105
Sagittal Spinopelvic Alignment Change after Lumbar Pedicle Subtraction Osteotomy: A Multicenter Analysis of 113 Patients with a Minimum 2 years Follow-Up
Yongjung J. Kim, MD; Keith H. Bridwell, MD; Lawrence G. Lenke, MD; Oheneba Boachie-Adjei, MD; Christopher L. Hamill, MD; Youngbae B. Kim, MD

11:24-11:33 am
Discussion

11:34-11:38 am
Paper #106
Normative SRS-QOL Data to Allow Age and Gender Specific Comparisons to Adult Deformity Patients. An Analysis of 1346 Unaffected Subjects.
Christine Baldus, RN, MHS; Keith H. Bridwell, MD; Mr. John Harrast; Christopher I. Shaffrey, MD; Stephen L. Ondra, MD; Lawrence G. Lenke, MD; Frank J. Schwab, MD; Steven M. Mardjetko, MD, FAAP; Steven D. Glassman, MD; Charles C. Edwards, II, MD; Christopher J. DeWald, MD; Thomas G. Lowe, MD; William C. Horton, III, MD; David W. Polly, Jr., MD

11:38-11:42 am
Paper #107
Do One Year Outcomes Predict Two Year Outcomes in Adult Deformity Surgery?
Steven D. Glassman, MD; Frank J. Schwab, MD; Keith H. Bridwell, MD; Christopher I. Shaffrey, MD; William C. Horton, III, MD; Serena S. Hu, MD

11:42-11:46 am
Paper #108
Operative vs. Non-Operative Outcomes: Adult Scoliosis Patients Age over 65 at Two Year Follow-Up
Gang Li, MD; Eric Fu, BA; Peter G. Passias, MD; Guoan Li, PhD; Kirkham Wood, MD

11:46-11:55 am
Discussion

11:56 am-12:00 pm
Paper #109
The Changing Practice of Adult Spinal Deformity Surgery: An Emerging New Paradigm for Surgical Approach, Staged Procedures and Fusion Levels.
Charles C. Edwards, II, MD; Keith H. Bridwell, MD; Michael R. Shainline, MS; Sigurd H. Berven, MD; Stephen L. Ondra, MD; William C. Horton, III, MD; Steven D. Glassman, MD; Christopher I. Shaffrey, MD; Christopher L. Hamill, MD; Frank J. Schwab, MD

12:00-12:04 pm
Paper #110
Can Posterior Only Surgery Replace Combined Anterior (Thoracotomy/Thoracoabdominal)/Posterior Approaches for Adult Scoliosis?
Christopher R. Good, MD; Lawrence G. Lenke, MD; Patrick T. O'Leary, MD; Mark Pichelmann, MD; Kathryn A. Keeler, MD; Keith H. Bridwell, MD; Christine Baldus, RN, MHS; Ms. Linda Koester

12:04-12:08 pm
Paper #111
Does Correction of Preoperative Coronal Imbalance Make a Difference in Outcomes of Adult Deformity Patients?
Michael D. Daubs, MD; Lawrence G. Lenke, MD; Yongjung J. Kim, MD; Gene Cheh, MD; Keith H. Bridwell, MD

12:08-12:17 pm
Discussion

12:18-12:22 pm
Paper #112
Risk Factors and Outcomes for Catastrophic Failures at the Top of Long Pedicle Screw Constructs (FPSC): A Matched Cohort Analysis Performed at a Single Center
Patrick T. O'Leary, MD; Keith H. Bridwell, MD; Christopher R. Good, MD; Lawrence G. Lenke, MD; Jacob M. Buchowski, MD, MS; Yongjung J. Kim, MD; Jennifer Flynn, BS

12:22-12:26 pm
Paper #113
Pelvic Tilt Shows Correlation with Health Related Quality of Life Measures and Truncal Inclination
Ashish Patel, MD; Frank J. Schwab, MD; Virginie Lafage, PhD; Nicola Hawkinson, BSN, MA, NP; Jean-Pierre Farcy, MD

12:26-12:32 pm
Discussion

* Russell A. Hibbs Award Nominee for Best Clinical Presentation
** Russell A. Hibbs Award Nominee for Best Basic Science Presentation



12:33-12:37 pm
Paper #114

Low Back Pain in Patients Treated Surgically for Scoliosis – Longer than 15 Year Follow-Up

Kazushi Takayama, MD; Hiroaki Nakamura, MD; Hidetomi Terai, MD, PhD; Tadao Tsujio, MD; Akira Matsumura, MD, PhD; Akinobu Suzuki, MD, PhD; Takafumi Maeno, MD; Sho Dohzono; Hideki Matsuda, MD; Prof. Kunio Takaoka

12:37-12:41 pm
Paper #115

Predicting Surgical Outcome by Change in Critical Parameters of Thoracolumbar/Lumbar Spinal Deformity in Adults

Frank J. Schwab, MD; Virginie Lafage, PhD; Ashish Patel, MD; Jean-Pierre Farcy, MD; Keith H. Bridwell, MD; Steven D. Glassman, MD; Michael R. Shainline, MS

12:41-12:47 pm

Discussion

12:47 pm

Meeting Adjourn

GLOSSARY OF SPINAL DEFORMITY BIOMECHANICAL TERMS

(Selected and adapted from White and Panjabi: Clinical Biomechanics of the Spine. Philadelphia: J. B. Lippincott, 1978)

Proposed by SRS Terminology Committee, 1999

Axes systems, etc. (See diagram)

Local, regional (spinal) and global axis systems (See Figure 1)

Vector - A quantity that possesses both a magnitude and a direction (e.g. force; velocity; displacement).

Loading

Force - An action that causes a body to displace or deform. (SI Unit of measure = Newton, i.e., N)

Tension Force - A force that tends to elongate a structure of material.

Compression Force - A force that tends to shorten a structure or material.

Moment or Torque - The sum of the forces applied to a structure multiplied by their perpendicular distance from a reference point or axis. (SI Unit of measure = Newton-metre, i.e., Nm)

Bending Moment at a point within a structure. (See Figure 2). The moment that tends to bend a structure. It is usually the sum of the moments due to several forces.

Couple - Two equal non-collinear forces producing a torque.

3-Point Bending (See Figure 3) - A structure is loaded in 3-point bending when a single force is applied on one side and two forces are applied on the other side acting in opposite directions.

4-Point Bending - (See Figure 3) - A long structure is loaded in 4-point bending when two transverse forces are applied on one side and two on the other.

Stress - The force per unit area of a structure and a measurement of the intensity of force (SI Units are Newtons/m²=Pascals. Hence 1 N/m² = 106 N/mm² = 1 MPa).

Normal Stress - The intensity of force perpendicular to the surface on which it acts.

Shear Stress - The intensity of force parallel to the surface on which it acts.

Compressive Stress - A normal stress that tends to shorten a material.

Tensile Stress - A normal stress that tends to elongate a material.

Principal Stresses - The stresses normal to the principal planes of a material are called principal stresses.

Stress Concentration - A site of stress that is high compared to that of nearby sites in a structure or material. It is often caused by a sharp change in shape.

Center of Gravity - The point in a body in which the body mass is centered.

Displacement/Deformation

Absolute Motion - Motion of a rigid body relative to the global axis system.

Relative Motion - Motion of a rigid body relative to the local axis system of an adjacent body.

Rotation (Figure 4) - Motion of a rigid body in which a certain straight line within or adjacent to the body remains motionless. (That straight line is the axis of rotation)

Translation (Figure 4) - Motion of a rigid body in which a straight line in the body always remains parallel to itself.

Plane Motion - A motion of a rigid body in which the body moves in a single plane.

Degrees of Freedom (Figure 5) - The number of independent displacements that can occur in a mechanism (e.g. the spine and instrumentation) - total of possible displacements and rotations at all of the joints.

Instantaneous Axis of Rotation (Figure 5) - When a rigid body moves at every instant there is a line in the body or some hypothetical extension of it that does not move. For plane motion the axis of rotation becomes the center of rotation. Note: This applies to absolute motion of a single body, also to the relative motion of two bodies such as two vertebrae.

Bending - Deformation of a structure in response to a bending moment.

Neutral Axis - Line or axis within a beam or other structure about which bending occurs.

Strain - (Figure 6) Deformation divided by original length or thickness.

Normal Strain is defined as the change in length divided by the original length. Normal strain can be tensile or compressive.

Shear Strain - Shear deformation divided by the thickness perpendicular to the shear.

Plastic Deformation (Figure 7) - Deformation that remains after the deforming load is removed.

Load-Displacement, Stress-Strain Relationships Elastic Behavior:

Stiffness - Relationship between load and deformation – the force applied divided by the deformation it produces.

Modulus of Elasticity - Relationship between stress and strain. (e.g., Young's modulus = normal stress divided by normal strain)

Torsional Rigidity - The applied moment or torque divided by the rotational deformation (torsion) that it produces.

Time Dependent Behavior:

Creep - Time dependent deformation of a material resulting from the application of a constant load.

Viscoelasticity - Material behavior in which the resistance to deformation depends on the amount of deformation (elastic) and the rate of deformation (viscous).

Failure

Yield Stress - (Figure 7) Magnitude of stress on the stress-strain curve at which appreciable deformation takes place without any appreciable increase in the stress.

Ductility - Property of a material in which there is a large amount of deformation possible after the yield point. This implies that a large amount of deformation energy is absorbed by the material before failure. (opposite of brittle)

Fatigue - Eventual failure after repeated cycles of sub-failure loading. This usually occurs as a result of the process of the growth of cracks in structures subjected to repetitive load cycles.

Equilibrium - State of a system in which all forces and moments are balanced, hence it does not displace.

Free Body Analysis (Figure 8) - Equilibrium analysis in which a system is split into real or imagined components (free bodies), in order to check that each part is in equilibrium. It is also used for determining the internal stresses in a structure subjected to external loads.

Statics - The branch of mechanics that deals with the equilibrium of bodies at rest or in motion with zero acceleration.

Dynamics - The branch of mechanics that deals with motion of systems in which the accelerations of masses have significant effect.

Kinematics - The branch of mechanics that deals with motion.

Stability - Behavior of a system whereby it returns to its equilibrium position after being disturbed.

Buckling - A kind of instability in which a structure suddenly bends and collapses when a certain critical load is applied. The stable equilibrium position is a position of minimum potential energy – any displacement of the structure requires a net input of energy. Although stiffness or rigidity of a structure can contribute to its stability, stiffness and stability are not the same thing. When referring to the rigidity of, for example an instrumentation construct, use the term stiffness or rigidity, not stability.

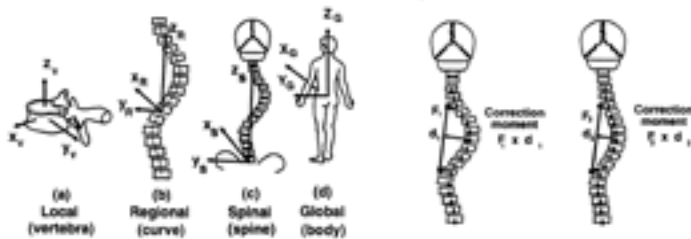


Figure 1. Local, regional (spinal) and global axis systems. Note: these are Cartesian systems, defined by three mutually perpendicular lines (axes).

Figure 2. Bending moment (produced here by the force in a Harrington rod) is the force multiplied by its perpendicular distance from a point in the structure (spine).

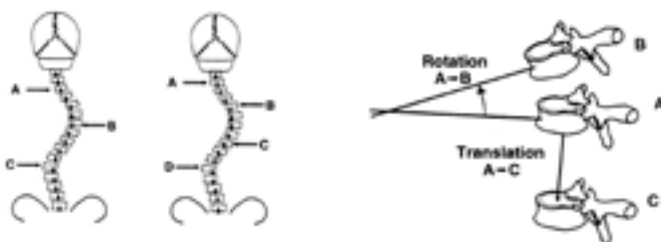


Figure 3. 3 and 4 point bending. For 3 point bending, the maximum bending moment is at point 'B'. For 4 point bending with four equal forces, the bending moment between forces 'B' and 'C' is uniform (constant).

Figure 4. Rotation and translation motion. The motion from A to B is a pure rotation, with an axis of rotation lying outside the vertebra. The motion from A to C is a pure translation.

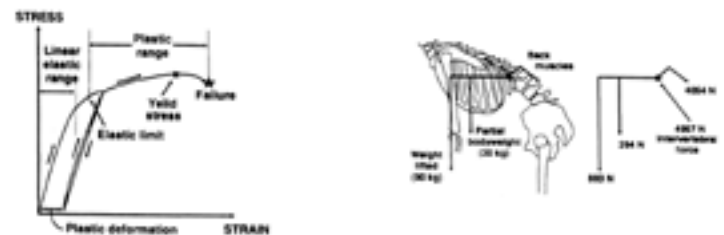

Figure 5. A motion segment has six degrees of freedom (i.e., six possible relative displacements of one vertebrae relative to its neighbor). The motion at any instant can be described as a translation along and a rotation about an instantaneous axis rotation.

Figure 6. Stress is the standardized measure of loading (force/unit area) and strain is the standardized measure of deformation (deformation divided by original length). (a) Normal stress and strain. (b) Shear stress and strain.

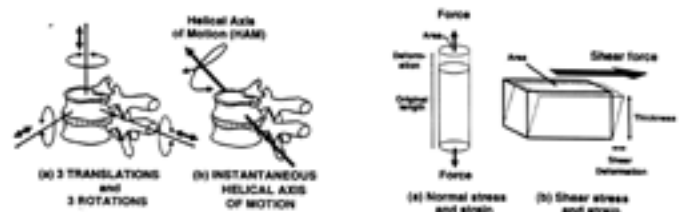


Figure 7. Stress-strain graph of a typical material. A sample was loaded past its elastic limit, unloaded to demonstrate plastic deformation, then loaded again to failure.

Figure 8. Simple static analysis (no motion occurring) of lifting mechanics to determine forces at the thoracolumbar junction. Here a free-body analysis is used. All forces acting on the upper part of the body must be in equilibrium (i.e., no net force or moment acting on the upper body) – otherwise it would be forced to accelerate.

SCIENTIFIC PROGRAM ABSTRACTS



SCOLIOSIS RESEARCH SOCIETY



Paper #1

Risk Factors for Distal Adding-on Identified: What to Watch Out For

John Schlechter, DO (Rady Children's Hospital and Health Center); Peter O. Newton, MD; Vidyadhar V. Upasani, MD; Burt Yaszay, MD; Lawrence G. Lenke, MD; Randal R. Betz, MD; Thomas G. Lowe, MD; Harms Study Group

Introduction: Considerable research has focused on the selection of fusion levels in the surgical treatment of adolescent idiopathic scoliosis (AIS); however selecting the lowest instrumented vertebra (LIV) continues to be controversial. In some cases, the scoliosis “adds-on” post-operatively (distal primary curve extension). The purpose of this study was to identify the pre-operative curve characteristics that predispose a spinal fusion to add-on.

Methods: A multi-center, retrospective analysis of pre-op, first-erect, and 2-year post-op radiographs and clinical data was performed. Inclusion criteria were: AIS patients with a Lenke type 1 spinal deformity, minimum 2-year follow-up, and a LIV of L2 or proximal. Distal adding-on was defined as progression of the primary Cobb below the level of instrumentation due to either an increase in the number of vertebra included within the Cobb, or an increase in disc angulation distal to the instrumentation. Spearman’s correlation and logistic regression analyses ($p < 0.05$) were used to identify pre-op variables associated with adding-on. ANOVA ($p < 0.05$) was used to compare 2-yr radiographic data between patients who experienced adding-on, and those who did not.

Results: 52 out of 407 patients reviewed (13%) met the definition for adding-on at 2-years post-op, and experienced a significantly greater change in thoracic Cobb from first erect ($7.4^{\circ} \pm 8.8^{\circ}$ vs. $3.6^{\circ} \pm 5.5^{\circ}$; $p < 0.001$). 5 pre-operative variables were found to be significant independent predictors of adding-on: age ($p = 0.04$), Risser stage ($p = 0.02$), weight ($p = 0.03$), lowest instrumented vertebra (LIV) translation from the center sacral vertical line (CSVL) ($p = 0.001$), and the number of levels between the stable vertebra and LIV ($p = 0.03$) (Table 1).

Conclusion: Less mature patients (younger chronologic age, lower Risser stage, and lower weight) are more likely to experience adding on. In addition, when the LIV is more proximal and with greater deviation from the CSVL the chance of adding on also increases. When in doubt, including an extra distal level in the fusion may reduce the risk of adding on especially in younger patients.

Table 1: Pre-operative variables found to correlate significantly with adding-on

	Adding-on	No Adding-on	Correlation
Age	14 ± 2 years	15 ± 2 years	$r = -0.13$ ($p = 0.01$)
Risser stage	2 ± 2	3 ± 2	$r = -0.16$ ($p \leq 0.001$)
Weight	48 ± 10 kg	53 ± 12 kg	$r = -0.14$ ($p = 0.01$)
LIV to CSVL	2.1 ± 1.6 cm	1.5 ± 1.0 cm	$r = -0.18$ ($p \leq 0.001$)
Stable to LIV	2 ± 2 vertebral levels	1 ± 2 vertebral levels	$r = -0.19$ ($p \leq 0.001$)



Paper #2

**RUSSELL A. HIBBS AWARD NOMINEE FOR BEST CLINICAL PRESENTATION

Accelerated Disc Degeneration below Posterior Spinal Fusion for Idiopathic Scoliosis: A Long-Term MRI and Clinical Follow-Up.

Thomas W. Lawhorne, MD; Daniel W. Green, MD, FACS (Hospital for Special Surgery), Douglas N. Mintz, MD; Bernard A. Rawlins, MD; Stephen W. Burke, MD; Roger F. Widmann, MD; Oheneba Boachie-Adjei, MD

Introduction: No prior studies compare pre-operative and 10-year post-operative MRI's after posterior fusion for AIS.

Methods: This is a retrospective chart and radiograph review of AIS patients treated between 1991 and 1997 with thoracic posterior fusion and segmental instrumentation. Inclusion criteria include: (1) posterior spinal fusion of idiopathic scoliosis, (2) fusion level ending at T12 to L3, (3) availability of patients and pre-op films. Patients volunteered for a ten-year follow-up exam, SRS questionnaire, XR, and MRI. The results of these studies were scored for evidence of degeneration of lumbar discs below the level of the fusion.

Results: 50 patients fulfilled the inclusion criteria, and of this number, 25 were located and 20 (17 female/3 male) were able to participate in the study. Of these patients, a total of 90 discs beneath fusion were evaluated. The average follow-up was 11.8 years since the index procedure. The major curve averaged 55±11 degrees preoperatively and was corrected to 25±10 degrees at follow-up. No patient required extension of the fusion, and three have undergone elective implant removal. Follow-up MRI demonstrated new disc pathology in 85% of patients. Only one patient demonstrated significant DDD at the junctional level, whereas most pathology was seen at the L5-S1 disc. Only one patient showed severe (Pfirmann 3 or 4) degeneration at the junctional level. Of the 90 total discs evaluated beneath the fusion, 59 (66%) had mild to severe degenerative scores. The greatest degree of degeneration was seen at the L5-S1 disk space where average degenerative scores increased from 1.2 pre-op to 2.3 post-op (45% had severe changes). Three patients with severe disc disease were taking NSAIDs for pain, but no narcotics. Only mild SRS and Oswestry changes were noted in this severe degeneration group. (see Table 1)

Conclusion: Despite demonstrating an accelerated rate of L5-S1 disc degeneration, our study group has good functional scores and maintenance of correction over ten years post-fusion. In this long-term MRI follow-up study, disc degeneration was found remote to the lowest instrumented vertebra.

Significance: In this long-term MRI follow-up study, disc degeneration was found remote to the lowest instrumented vertebra.

Table 1: Pfirmann Disk Scores of Unfused Disks

		<u>T12-L1</u>	<u>L1-L2</u>	<u>L2-L3</u>	<u>L3-L4</u>	<u>L4-L5</u>	<u>L5-S1</u>	<u>S1-2</u>
Pre-op	N	20	20	20	20	20	20	1
	Score	1.1	1.0	1.1	1.1	1.1	1.2	1.0
10-year	N	3	12	14	20	20	20	1
	Score	2.0	1.8	1.7	1.8	1.7	2.3	2.0

* The FDA has not cleared a drug and/or medical device in use described in this presentation (i.e., the drug or medical device is being discussed in an off-label use). For full information see page 10.

Paper #3

Subjacent Disc Wedging after Anterior Spinal Fusion for Adolescent Idiopathic Scoliosis: The Fate of the “Jacked” Lumbar Disc

Kathryn A. Keeler, MD; Keith H. Bridwell, MD; Lawrence G. Lenke, MD; Jennifer Flynn, BS (Washington University)

Introduction: While anterior spinal fusion (ASF) for adolescent idiopathic scoliosis (AIS) has the advantage of allowing for fusion of fewer motion segments, the concentration of corrective forces on the lowest instrumented vertebra (LIV) may lead to subjacent disc wedging (SDW) of the segment below the ASF, resulting in poorer outcomes. Few authors have evaluated the effect of SDW on radiographic and clinical outcomes beyond 2-year follow-up measured by SRS scores.

Methods: 92 patients with thoracolumbar/lumbar (TL/L) AIS treated with ASF alone at one institution were studied. LIV was L3 (n=79) or L4 (n=13). Average age at surgery was 14.3 years. All patients had a minimum 2-year follow-up (mean 4.9 yrs, range 2-20.5 yrs). LIV was the lower end vertebra (LEV) in 70 patients, 1 level cephalad to the LEV in 12 patients, 2 levels cephalad to the LEV in 2 patients and 1 level caudad to the LEV in 3 patients. Radiographic SDW and clinical (SRS scores) outcomes were analyzed at postop (PO), 2-year (2Yr), 5-year (5Yr), and >10 year (10Yr) follow-up. SDW was defined as disc angle 10° open toward the curve convexity.

Results: The average TL/L curve measured 48.4° (preop) and corrected to 13.8° (PO). SDW 10° was noted in 19 patients PO and in 21 patients at final follow-up (FFU). There was no significant difference in subjacent disc angles PO and at FFU ($p=0.31$). SRS scores were available for 57 patients (12 SDW) at 2Yr. There were no significant statistical differences in SRS pain or subscore between patients with and without SDW ($p=0.69, 0.51$, respectively). SRS scores were available for 36 patients (5 SDW) at 5Yr. There were no significant statistical differences in pain or subscore between patients with and without SDW ($p=0.96, 0.36$, respectively).

Conclusion: SDW did not significantly increase from immediate PO to 5 years PO. SDW did not have a significant effect on clinical outcomes at 2Yr and 5Yr based on the SRS-QOL.

Significance: SDW did not have a significant effect on radiographic or clinical outcomes after ASF at 2 and 5 years PO.

Paper #4

Genetic Profile Predicts Curve Progression in Adolescent Idiopathic Scoliosis

Kenneth Ward, MD (Axial Biotech, Inc.); Lesa M. Nelson, BS; Rakesh Chettier, MS; John T. Braun, MD; James W. Ogilvie, MD

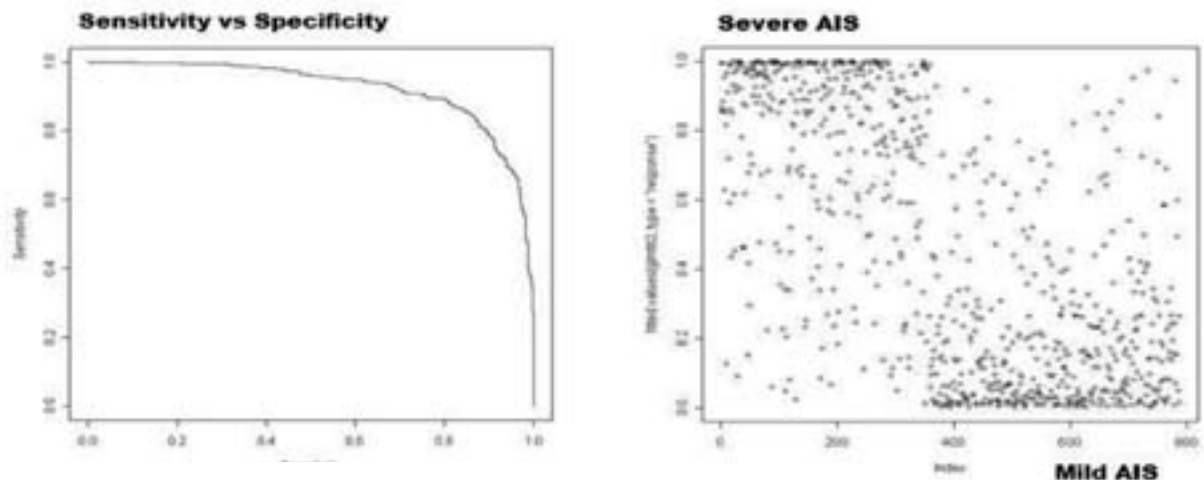
Introduction: Recent linkage studies have identified regions of the genome that may contribute to AIS. This study is the first high-density, genome-wide mapping study ever conducted focused on progression to severe scoliosis.

Methods: A genome wide association study using AffymetrixHuSNP 6.0 microarrays compared 1,200 unrelated Caucasian patients with severe idiopathic scoliosis and 1,500 controls. Ethnicities were matched using reported grandparental ethnicity and confirmed using the EIGENSTRAT software. Progression of AIS was documented as part of normal clinical care. One spine surgeon reviewed every patient's x-rays and medical records for Cobb angle, Lenke classification, and Risser score prior to genotyping the DNA samples. Progression to a severe curve was defined per usual clinical criteria (progression to a >40° curve in an individual still growing or progression to a >50° curve in an adult). Female patients were considered skeletally mature at age 16 and male patients were considered skeletally mature at age 18. Patients were excluded if their scoliosis was secondary (i.e. related to cerebral palsy), syndromic (Marfan, NF), traumatic, paralytic, myopathic, degenerative, or congenital.

Results: A total of 202 genetic markers were discovered to have significant association with progression to a mild curve. After examining linkage disequilibrium, confirming genotypes on a second genotyping platform, and testing additional mild and severe AIS cohorts, 30 markers have been identified as the most useful prognostic markers as indicated on the following charts:

Conclusion: Using a 30-marker genetic panel, we can now predict which patients are likely to progress to a severe scoliosis at the time of initial clinical evaluation.

Significance: We have discovered gene-based, prognostic markers that are able to predict progression of AIS early in the course of the disease.



Paper #5

Genetic Association Study of Collagen I α 2 Gene in Adolescent Idiopathic Scoliosis - A Study of 520 Cases

Hiu Yan Yeung, PhD; Prof. Nelson L. Tang (The Chinese University of Hong Kong); Vivian W. Hung; Rachel Kwok; Kwong Man Lee, PhD; Ling Qin; Bobby Kin-wah Ng, MD; Jack Chun Yiu Cheng, MD

Introduction: Patients with adolescent idiopathic scoliosis (AIS) were shown to be taller and slender during peri-pubertal period. Their bone mineral density (BMD) was lower than their peers. Type I collagen (COL1) plays an important role in bone mineralization. Study showed that polymorphisms of COL1 alpha 2 (COL1A2) gene was associated with the spine BMD of adolescent girls. In this study we hypothesize that COL1A2 gene may be associated with AIS and its related phenotypes such as BMD and anthropometry. The COL1A2 gene polymorphism in AIS girls was studied and compared with controls. The association of the polymorphism of COL1A2 gene with the anthropometry and BMD of AIS patients was tested.

Methods: Girls with AIS (n=522) and health control (n=250) at age 12-16 years were recruited. The anthropometric data were recorded. The genotype of PvuII polymorphism of COL1A2 gene was characterized by PCR-RFLP. The spinal and femoral neck BMD by dual energy x-ray absorptiometry (DXA). As previously shown that spinal BMC is more representative of bone mineral status than BMD in AIS patients due to rotation of the spine, spinal BMC was used. The association of the gene polymorphism to the occurrence of AIS was tested by Chi-square. Anthropometric parameters and BMD of AIS patients were standardized as z-score with age- and sex-matched controls and compared between genotypes.

Results: The genotype frequency of PP, Pp, and pp in AIS patients were 6.1%, 40.2%, and 53.6%, respectively. The distribution was significantly different from that of the controls (p=0.033). The spinal BMC and bone area of AIS girls with pp was significantly lower and smaller than patients with at least one P allele (p=0.008). Moreover, the non-dominant femoral neck (NDFN) BMD of AIS girls with pp was also significantly lower than AIS girls carrying P allele (p=0.048). The BMI of the AIS girls with pp genotypes had significantly lower BMI than others (p=0.035).

Conclusion: AIS girls with pp genotype were shown to associate with AIS and also had significantly lower BMI, spinal BMC, and NDFN BMD.

Significance: It is suggested that COL1A2 gene might play an important role in the development of scoliosis acting through its role as a modifier gene in bone mineralization and growth of AIS girls.



Paper #6

Predicting Brace-Resistant Adolescent Idiopathic Scoliosis

James W. Ogilvie, MD (Axial Biotech, Inc.); Lesa M. Nelson, BS; Rakesh Chettier, MS; Therese Smith-Berry; Kenneth Ward, MD

Introduction: Brace treatment for adolescent idiopathic scoliosis (AIS) is commonly prescribed for skeletally immature patients with curves in the 25-40° range. One-third of patients Risser 0, 1 with curves 20-29° will not progress if left untreated and approximately 20% will fail brace treatment and have surgery. We tested prognostic genetic markers in brace-resistant AIS patients who were brace compliant.

Methods: 57 Caucasian female patients with AIS who wore a brace for at least one year, but progressed to surgery had genotype analysis with a panel of 30 genetic markers. Brace compliance was determined through medical record review and by patient interview.

Results: Ninety five percent of the brace failure patients (54/57) had a calculated probability of progression over 0.35 based upon their genetic profile alone. Only 9% of 500 mild AIS patients who did not progress beyond 25° by skeletal maturity had a genetic risk profile of >0.35. Fully 100% of study patients who wore a brace without efficacy were classified as having a high risk of progression when the predictive algorithm considers age and Cobb angle at first clinical presentation as well as the genetic markers.

Conclusion: Using a 30 marker genetic panel, we may be able to predict which patients are likely to be brace-resistant. Additional cohorts of brace-resistant and brace-responsive AIS patients are being tested, and these data will be available for presentation at the annual meeting.

Significance: A gene-based prognostic test may allow evidence-based decisions on the appropriateness of brace treatment in AIS.

Paper #7

Revision Surgery after 1057 Primary Spine Fusions for Idiopathic Scoliosis over 19 Years: Identification of Causative Factors

Scott J. Luhmann, MD (Washington University School of Medicine); Lawrence G. Lenke, MD; Keith H. Bridwell, MD

Introduction: The purpose of this study was to review the overall prevalence of, and indications for, re-operations at our medical center.

Methods: A database search at our center identified all primary spine fusions performed for idiopathic scoliosis (1985-2003). 1057 patients were identified (8-22 years, mean age 14.4 years) with minimum 2 year follow-up.

Results: Of the 1057 primary spinal fusions for idiopathic scoliosis, 41 (3.9%) underwent re-operation. Mean age of the study cohort at index procedure was 13.9 years. In addition, there were no differences in age at the time of index procedure between the different surgical approaches [Posterior spine fusions (PSF) 13.9 years, Anterior spine fusion (ASF) 14.2 years, Anterior/Posterior spine fusion (APSF) 13.6 years]. Primary surgeries were: 11 ASF, 25 PSF, and 5 APSF. The reoperation rates for the three index procedure groups being similar: 4.3% (11 of 258 patients) for ASF, 3.7% (25 of 677 patients) for PSF, and 3.9% (5 of 122 patients) for APSF. 47 additional procedures were performed at an average of 26 months after index procedure (1 week to 73 months): 20 (43%) were revision spinal fusions (for pseudarthroses, curve progression or junctional kyphosis), 16 (34%) because of infections (4 acute, 12 chronic), 7 (15%) for implant removals due to pain a/o prominence (4 complete, 3 partial), 2 (4%) were revision of loosened implants, and 2 (4%) were elective thoracoplasties. Only 2 revision surgeries differed between the 3 subgroups: 3.1% of ASF index surgeries underwent reinstrumentation +/- osteotomy (PSF 1.5% and APSF 1.6%) and 2.5% of APSF index surgeries had an acute postoperative infection (PSF 0.3% and ASF 0%).

Conclusion: This study documented a 3.9% overall re-operation rate at our medical center, a three-fold lower re-operation rate than the previously reported 13.8%. At the time of primary spine fusion for AIS the risk of infection in this study was 1.1%, pseudarthrosis 1.1%, and painful/prominent implants 0.7%.

Significance: Multiple patient, surgeon, and institutional factors are likely to account for marked differences in the re-operation rates after primary spinal fusion for idiopathic scoliosis at various medical centers (3.9% vs. 13.8%).

Paper #8

Multiple Level Simultaneous Front and Back Osteotomies of the Fusion Mass for Correction of Rigid Idiopathic Scoliosis with Failed Instrumentation

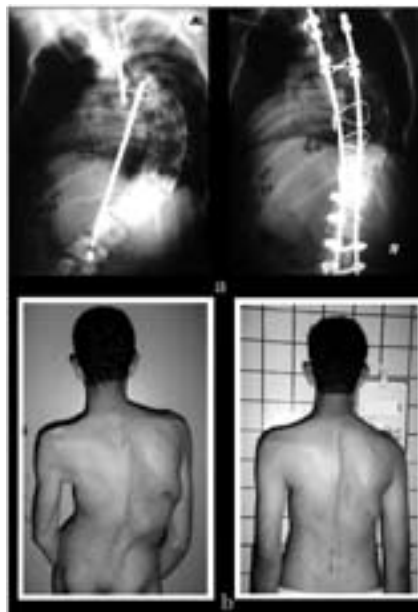
Yasser El Miligui, MD, FRCS (Cairo University); Wael Koptan, MD; Hazem B. Elsebaie, FRCS, MD

Introduction: Rigid, unbalanced spinal deformities in the coronal and sagittal planes secondary to previous failed instrumentation and fusion are a major challenge to deformity surgeons. **Study Design:** A retrospective clinical study. **Objectives:** To study the technique of multiple level simultaneous front and back fusion mass osteotomies for revision of unorthodox surgeries for scoliosis patients presenting with failure of instrumentation, marked deformity and a solid fusion mass.

Methods: Seventeen patients who had previous anterior fusions and posterior instrumented fusions to correct their spinal deformities. The instrumentation placed at the index surgery was unorthodox and consequently failed. All patients had significant, disabling pain that interfered with daily activities. The age at surgery had an average of 18 years. The dorsal curves averaged 57.2 degrees (range 38 degrees to 96 degrees) while the lumbar curves averaged 38.5 degrees (range 24 degrees to 70 degrees). All patients had a single staged procedure; first anterior multiple level apical osteotomies were performed followed by removal of the failed posterior implants and correction was achieved by multiple level V-shaped osteotomies in the fusion mass. The patients were re-instrumented, corrected and regrafted.

Results: Patients were followed for a minimum of three years at which the curves were corrected to an average of 31.6 degrees and 28.4 degrees respectively. The average number of osteotomies performed anteriorly was 3.2 levels (range, 1-5) and the average number of osteotomies posteriorly was 4.1 levels (range, 2-7). The average blood loss was 1750cc and the average operative time was 9.5h. Overall, there was no postoperative neurological deficit and the complications were acceptable.

Conclusion: Circumferential fusion mass osteotomies appear to be both safe and efficient in obtaining a good correction of these demanding deformities. Performing them at the same session results in a satisfactory clinical and radiological outcome.



Paper #9

Posterior Vertebral Column Resection (VCR) for Severe Pediatric Deformity: Minimum 2-year Follow-Up on 29 Consecutive Patients

Lawrence G. Lenke, MD (Washington University); Patrick T. O'Leary, MD; Brenda A. Sides, MA; Linda Koester; Marsha Hensley; Keith H. Bridwell, MD

Introduction: The ability to treat severe pediatric spinal deformity through an all-posterior vertebral column resection (VCR) approach has obviated the need for a circumferential approach in both primary and revision settings. We examined indications, correction rates, and complications of these challenging procedures in the pediatric population.

Methods: Between 2000 & 2005, 29 consecutive patients underwent a posterior-only VCR by one of two surgeons at a single institution. Patients were divided into 5 diagnostic categories: 1) severe scoliosis (S) (n=2, mean 96°, range 80-112°, average flexibility 22%); 2) global kyphosis (GK) (n=3, mean 110°, range 105-113°, average flexibility 22%); 3) angular kyphosis (AK) (n=8, mean 74°, range 45-135°, average flexibility 23%); 4) kyphoscoliosis (KS) (n=5, mean kyphosis 98°/scoliosis 81°, mean combined 179°, range 104-237°); 5) congenital scoliosis (CK) (n=11, mean 42°, range 23-69°, average flexibility 20%). There were 19 primary and 10 revision surgeries. There were 21 one-level, 6 two-level, and 2 three-level resections.

Results: Major curve correction averaged 70° (71%) in group S, 58° (57%) in group GK, 45° (59%) in group AK, 93° (52%) in group KS, and 70° (58%) in group CS. The average OR time was 448 mins (range 210-822), with an average EBL of 570 mL (range 125-1000). There were no spinal cord-related complications; however, 3 patients (11%) lost intraoperative NMEP data during correction with data returning to baseline following prompt surgical intervention. Two patients had transient nerve root palsies (unilateral quad deficit in a revision L2 & L3 VCR resolved by 6 months postop, and unilateral partial foot drop in a revision resolved by 1 week postop). One patient presented with a delayed deep wound infection at 6 months postop requiring I&D with wound closure over drains.

Conclusion: Treating severe pediatric spinal deformity through an all-posterior VCR approach has obviated the need for a circumferential approach in primary and revision settings. Intraoperative SCM (especially motor-evoked potentials) is mandatory to prevent spinal cord-related neurologic complications. Although technically challenging, a single stage approach offers dramatic correction of severe spinal deformities.

Paper #10

Increase Patient Satisfaction after Fusion for Adolescent Idiopathic Scoliosis by Minimizing the Deformity-Flexibility Quotient

Vidyardhar V. Upasani, MD (University of California San Diego); Peter O. Newton, MD; Jeff B. Pawelek, BS; Tracey P. Bastrom, MA; Lawrence G. Lenke, MD; Thomas G. Lowe, MD; David H. Clements, III, MD; Baron S. Lonner, MD; Randal R. Betz, MD; Harms Study Group

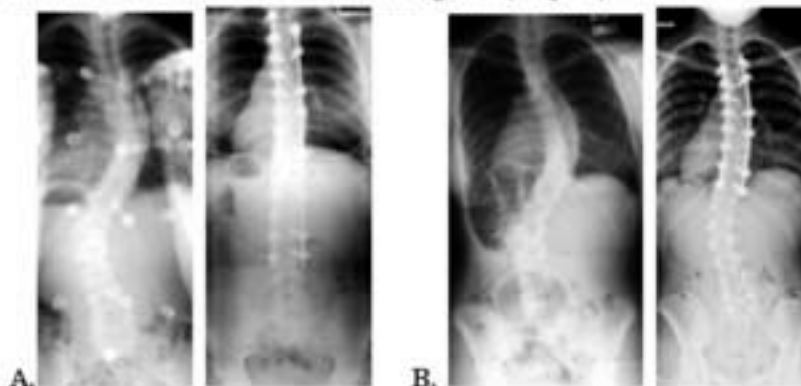Introduction: It is unclear whether a selective thoracic fusion which may leave a residual lumbar deformity is preferred to a longer spinal fusion which may improve deformity correction at the expense of lumbar motion. The purpose of this study was to use the SRS-24 questionnaire to determine patient preference between a longer, straighter fusion versus a shorter fusion with a residual lumbar deformity.

Methods: Peri-op, x-ray, and SRS-24 data were retrospectively reviewed from a consecutively enrolled series. All AIS patients with a Lenke type 1B/C deformity and minimum 2-yr follow-up were analyzed. The DFQ was calculated for each patient by dividing the residual coronal lumbar deformity at 2-yrs post-op by the number of distal unfused motion segments (Fig 1). Spearman’s rho test was used to perform a correlation analysis between the DFQ and SRS-24 scores ($p < 0.05$). The 2-year coronal lumbar curve deformity and the number of unfused motion segments were also assessed for independent correlation with SRS-24 scores ($p < 0.05$).

Results: 155 AIS patients met the inclusion criteria. The average pre-op thoracic and lumbar Cobb angles were $52.3^{\circ} \pm 9.2^{\circ}$ and $37.8^{\circ} \pm 8.2^{\circ}$; decreasing to $22.4^{\circ} \pm 9.8^{\circ}$ and $20.1^{\circ} \pm 8.8^{\circ}$, respectively at 2-yrs post-op. The average number of distal unfused motion segments was 5.8 ± 1.4 and the average DFQ was 3.6 ± 1.9 (range: 0.2-12.3). Residual lumbar deformity and SRS-24 scores were not significantly correlated at 2-yrs post-op ($p > 0.14$); however the number of unfused motion segments did correlate with Functional Level ($r = 0.16$, $p = 0.04$). Additionally, the DFQ was significantly correlated with Patient Satisfaction ($r = -0.16$, $p = 0.04$), and a trend towards a correlation was found with Self Image after Surgery ($r = -0.15$, $p = 0.06$).

Conclusion: Selective thoracic fusions that preserve motion in the lumbar spine are often associated with a residual lumbar deformity. The current data suggest that despite patients’ focus on radiographic correction, residual lumbar deformity by itself did not correlate with SRS-24 scores at 2-yrs post-op. A greater number of unfused lumbar motion segments did correlate with greater function, and a lower DFQ (less deformity and more motion segments of the lumbar spine) correlated with higher 2-year post-op patient satisfaction.

Figure 1: A) Pre-op and 2-yr post-op PA radiographs: 14° residual lumbar curve with 3 unfused motion segments (DFQ=4.7). B) Pre-op and 2-yr post-op PA radiographs: 34° residual lumbar curve with 7 unfused motion segments (DFQ=4.9).



Paper #11

Selective Thoracic Fusion in Adolescent Idiopathic Scoliosis with Lenke Type 1C, 3C or King Type 2 Lumbar Curves of More than 50 Degrees in Magnitude

Cagatay Ozturk, MD (Istanbul Bilim University, Istanbul Spine Center); Azmi Hamzaoglu, MD; Marco G. Teli, MD FGBOT; Mehmet Tezer, MD; Mehmet Aydogan, MD; Meric Enercan

Introduction: The aim of this retrospective clinical study was to evaluate the outcome of selective thoracic fusion for adolescent idiopathic scoliosis in the presence of compensatory lumbar curve of more than 50 degrees.

Methods: Between the years of 1991 and 2000, 29 of 122 patients undergoing selective thoracic fusion have been documented as having preoperative lumbar compensatory curve of more than 50 degrees. The Cobb angles of both thoracic and compensatory lumbar curves and translation of the lumbar apical vertebra from midline were measured pre and postoperatively. All patients underwent selective thoracic fusion by posterior approach. Postoperative standing posteroanterior and lateral direct radiographies of the spine were examined to evaluate spontaneous correction and decompensation in lumbar curves.

Results: The mean postoperative follow-up was 12 (7-16) years. All patients were female and the average age was 16.5 years. The mean preoperative Cobb angle of thoracic curve was 65 degrees and of lumbar curve was 55 degrees. The flexibility was 60% in thoracic curves and 76% in lumbar curves. Postoperatively, 61% correction in thoracic curve and 50% correction in lumbar curve were achieved. The mean preoperative apical lumbar vertebra displacement was 3.1 cm and it declined to 1.8 cm. The lowest level of instrumentation and fusion was the stable vertebra (same as neutral vertebra) or the neutral vertebra if it is one level cephalad to stable vertebra in 20 patients. In the remaining patients, fusion and instrumentation was stopped at stable vertebra although neutral vertebra was one level above. The spontaneous correction in the lumbar curve was 56% in former group and 40% in later group. There were neither decompensation seen during follow-up period nor re-operations applied in the patient group.

Conclusion: Posterior selective thoracic fusion works in Lenke type 1C, 3C or King type II curves with more than 50 degrees lumbar curves if the flexibility of lumbar curve is more than 50%. If the neutral vertebra and the stable vertebra is not the same vertebra, it is better to stop instrumentation and fusion distally at the neutral vertebra to obtain better spontaneous compensatory lumbar curve correction.



Paper #12

5-Year Clinical and Radiographic Results of Selective Thoracic Fusion with Lumbar Curve >40 Degrees.

Paul D. Sponseller, MD (Johns Hopkins Hospital); Peter O. Newton, MD; Randal R. Betz, MD; David H. Clements, III, MD; Alvin H. Crawford, MD; Michael F. O'Brien, MD; Michelle C. Marks, PT, MA; Tracey P. Bastrom, MA; Harms Study Group

Introduction: Selective Thoracic Fusion is often employed for motion preservation. This study tested the intermediate-term compensation and clinical benefit in larger lumbar curves.

Methods: Lenke 1-4 curves with a lumbar curve >40 degrees having >5 year follow up were analyzed. Those with LIV > L1 were compared to those fused lower. SRS outcome scores were compared.

Results: 42 patients fused selectively (S) and 33 fused nonselectively (N) were followed to 5 years. Lumbar modifiers for S were 29C and 13B. There was no difference in preop main thoracic curve (57° N vs. 56° S, p<0.08) but lumbar curve was greater in N (55° vs 44°, p<0.01). The most common operation for S was ASF (28/42) while for N it was PSF (23/33). The pattern of change from FE to 5 years was different, with thoracic curves increasing more in S (4° vs 9°, p=0.002) and lumbar curves improving more in S (-1° vs 3° p=0.01). At 5 years the N patients had smaller thoracic curves (20° vs 31°, p=0.01) and lumbar curves (20° NS, 25° S, p=0.04). Reoperation was needed in 6/42 S and 1/33 N (p=0.13). However, four of the 6 revisions in S were for deformity vs. none in N. The SRS subscores and total scores were not different. Sub-analysis of patients fused posteriorly (12S, 23 N) revealed greater increase in the thoracic curve in S (10° vs 4°, p=0.02) and a difference in the evolution of the lumbar curve (N increased 4° in N, S decreased 1°). There were no differences in T:L correction ratios or reoperation in Lenke B vs C curves. The C-modifier curves had more left-shift of C7-CSVL (-6.2 vs 1.9mm).

Conclusion: Selective fusion preserves motion at expense of deformity correction. Selective patients have less correction of the thoracic curve at 5 years, with greater loss of thoracic correction even when fused posteriorly, as if to achieve balance. More selective patients required revision for deformity. SRS scores are not demonstrably better at 5 years in the selective patients. Further study is required to perfect this strategy and define its role.

Significance: Further study is required to perfect this strategy and define its role.

Paper #13

Backfilling of Iliac Crest Defects with Hydroxyapatite-Calcium Triphosphate Biphasic Compound: A Prospective, Randomized, Single-Blind CT and Patient-Based Analysis

Douglas C. Burton, MD (University of Kansas School of Medicine); Barbara Manna, RN; Brandon B. Carlson, BS; Phillip Johnson, MD; R. Christopher Glattes, MD

Introduction: Hydroxyapatite-calcium triphosphate (HCT) biphasic compounds are known to be efficacious in filling bone voids. No study to date has assessed their radiographic efficacy in iliac crest voids with computed tomography (CT) analysis. The purpose of this study was to assess whether backfilling iliac crest defects with HCT biphasic (Mastergraft®) compound decreases donor site pain and what effect backfilling has on CT appearance of the donor ilium.

Methods: This prospective, randomized, single-blind study followed patients requiring non-structural posterior iliac crest harvest as part of spinal disorder treatment for 2 years. Harvest technique preserved both cortical tables and their periosteum. All patients were randomized to backfill of HCT or no backfill (control). All patients had CT of the pelvis immediate post-operative and at 2 year follow-up. CT analysis was performed by a board-certified radiologist. Analysis included qualitative assessment of the ilia appearance and defect density quantified in Hounsfield Units (HU). All patients completed a Visual Analog Scale (VAS) of their donor site pain (0-10; low-high) at 6 weeks and 2 years postoperatively.

Results: 37 of 40 (17 F; 20 M) subjects returned for mean 23.9 month follow-up (22-29 mos). Average age was 51.7 yrs (27-79 yrs). 18 patients were in the backfill group (BF) and 19 were in the control group (C). There was no statistically significant difference in pain at 6 weeks or 2 years between the two groups. Bone density significantly decreased from post-op to 2 yr in BF (implying resorption of HCT and replacement with host bone) and significantly increased in C (implying formation of host bone). Both groups had similar cortical defect repair. BF had significantly better medullary defect repair ($p < 0.01$, Fisher's Exact).

Conclusion: Backfilling iliac crest voids with hydroxyapatite-calcium triphosphate biphasic compound does not significantly decrease donor site pain. Both the backfilled and control defects reformed bone over the two year period, with the backfill group having significantly less medullary defects than control.

Significance: Backfilling of iliac crest defects increases formation of host bone, potentially enabling reharvest of bone graft or placement of iliac anchors.

Paper #14

***Complications in 910 Growing Rod Surgeries: Use of Dual Rods and Submuscular Placement of Rods Decreases Complications**

R. Shay Bess, MD (San Diego Center for Spinal Disorders); Behrooz A. Akbarnia, MD; George H. Thompson, MD; Paul D. Sponseller, MD; David L. Skaggs, MD; Suken A. Shah, MD; Hazem B. Elsebaie, FRCS, MD; Oheneba Boachie-Adjei, MD; Lawrence I. Karlin, MD; Sarah K. Canale, BS; Connie Poe-Kochert, RN, BSN, CNP; Growing Spine Study Group

Introduction: Scoliosis treatment in the growing spine remains challenging. Previous reports indicate that growing rod use (GR) may have unacceptably high complication rates. The purpose of this study is to evaluate complications of GR treatment for scoliosis

Methods: Multi-center, retrospective review of clinical and radiographic complications in 143 patients (pts) undergoing 910 GR surgeries, minimum 2 yr follow-up. Treatment groups divided into single (SI; n=73 pts) or dual rod (DU; n=70 pts), and position of GR implants; subcutaneous (SQ; n=54 pts) or submuscular (MU; n=89 pts). Complications categorized into wound, implant, alignment, and medical problems. Surgical procedures divided into planned (PLAN) and unplanned (UNPLAN). PLAN = anticipated surgery due to routine GR treatment. UNPLAN = surgery due to complications.

Results: SI and DU showed no difference total instrumented levels, total procedures, total PLAN, and total UNPLAN (Table 1). SI had longer follow up (65 vs. 54 mo; p<0.05) than DU. DU had younger age at GR insertion (67 vs. 79 mo; P<0.05) than SI. There were 177 complications in 81 pts. Complication rate per surgery was <20%. SI and DU showed no difference in total complications, or complications due to wound, alignment, or medical problems (Table 1). Fewer DU pts received implant related UNPLAN than SI (7 vs. 19; p<0.05) and there were fewer total implant related UNPLAN in DU than SI (10 vs. 28; p<0.05). SQ had more complications per pt (1.6 vs. 0.99; p<0.05) and more wound problems than MUS (13 vs. 9; p<0.05). SQ placement of DU had more complications per pt (1.6 vs. 0.8; p<0.05), more pts with wound complications (11 vs. 4; p<0.05), more pts with prominent implants (4 vs. 0; p<0.05), and more pts undergoing implant related UNPLAN (6 vs. 1; p<0.05) than MUSC placement of DU.

Conclusion: Complication rates per GR procedure are comparable to other surgical treatments for scoliosis. Complication analysis of GR indicates that complications are likely due to multiple procedures per patient. Dual rod reduces unplanned surgery due to implant complications. SM placement of GR decreases complication rates and wound problems, and reduces unplanned surgery.

Table-1 Complications Single vs. Dual Growing Rod

	Single Rod (n=73)	Dual Rod (n=70)	Total (n=143)
Age, months; avg (range)	79.2* (29-138)	67 (19.5-144)	73.2 (19.5-144)
Total f/u, months; avg (range)	64.8* (24-166)	53.8 (24.7-125.6)	59.4 (24-166)
Total levels instrumented; avg (range)	12.8 (7-18)	13.9 (9-18)	13.3 (7-18)
Total surgeries; avg (range)	447: 6.1 (3-13)	463: 6.6 (2-15)	910: 6.4 (2-15)
Total planned surgeries	405	431	836
Total lengthening; average (range)	4* (0-11)	4.9 (1-13)	4.5 (0-13)
Final fusion preformed (n)	38*	15	53
Total unplanned surgeries	42	32	74
Total complications	94	83	177
Total pts ≥ 1 complication	43	38	81
Complications per surgery	0.21	0.18	0.19
Unplanned surgery per complication	0.45	0.38	0.42
Wound complications (pts:number:surgery)	8:9:10	15:21:19	23:30:29
Implant complications (pts:number:surgery)	34:64:28*	29:42:10	63:106:38
Alignment complications (pts:number:surgery)	4:4:3	6:7:3	10:11:6
Medical complications (pts:number)	11:15	6:11	17:26

*= p<0.05; Single vs. Dual

* The FDA has not cleared a drug and/or medical device in use described in this presentation (i.e., the drug or medical device is being discussed in an off-label use). For full information see page 10.

Paper #15

Neurologic Risk in Growing Rod Surgery in Children: Is Neuromonitoring Necessary in All Cases?

David L. Skaggs, MD (Childrens Hospital Los Angeles); John B. Emans, MD; David S. Marks, FRCS; John P. Dormans, MD; George H. Thompson, MD; Suken A. Shah, MD; Paul D. Sponseller, MD; Behrooz A. Akbarnia, MD; Growing Spine Study Group

Introduction: The incidence of neurologic events during primary growing rod surgeries, implant exchanges, and implant lengthenings is unknown. The purpose of this study is to evaluate the risk of neurologic injury during growing rod surgeries and to determine whether intra-operative neuromonitoring is necessary for all growing rod procedures.

Methods: We reviewed data from 252 patients who underwent growing rod surgeries. Any constructs with rib attachments were excluded from the study. A questionnaire was sent to all surgeons contributing cases requesting detailed information about all neurologic events associated with any growing rod surgery.

Results: There were 782 growing rod surgeries performed on 252 patients including 252 primary growing rod implantations, 168 implant exchanges, and 362 lengthenings. There were two cases with neuromonitoring changes during primary implant surgeries (0.8% - 2/252), one neuromonitoring change and clinical injury during implant exchanges (0.6% - 1/168), and one neuromonitoring change during lengthenings (0.3% - 1/362). The single neuromonitoring change that occurred during a lengthening was in a child with an intra-canal tumor who also had a change during the primary surgery. All neurologic events involved the lower extremities. Only one of the neuromonitoring changes, which occurred during implant exchange, resulted in a clinical deficit, which resolved within 3 months.

Conclusion: This is the largest reported series of growing rod surgeries. There were no permanent neurologic injuries in 782 growing rod surgeries, with a 0.1% rate of temporary neurologic injury. The rate of neuromonitoring changes during primary growing rod implantation (0.8%) and exchange (0.6%) justifies the use of intra-operative neuromonitoring during these surgeries. As there were no neurologic events in all 361 lengthenings in patients with no previous events, intra-operative neuromonitoring may not be necessary for lengthenings in these cases, though the sample size may not be sufficient to make definitive recommendations.

	Neuromonitoring Change	Transient Neurologic Deficit	Permanent Neurologic Deficit
Primary Implants	0.8%	0%	0%
Implant Exchanges	0.6%	0.6%	0%
Implant Lengthenings	0.3%	0%	0%

Paper #16

Is Definitive Spinal Fusion, or VEPTR Removal, Needed after VEPTR Expansions are Over? An Analysis of the 39 “VEPTR Graduates”

John M. Flynn, MD (Children’s Hospital of Philadelphia); Tricia St. Hilaire, BS; John B. Emans, MD; Randal R. Betz, MD; Robert M. Campbell, Jr., MD; John T. Smith, MD; Danielle Cameron, BA Chest Wall and Spine Deformity Study Group

Introduction: VEPTR has gained wide acceptance to treat thoracic insufficiency and early onset scoliosis. Many in the original VEPTR treatment cohort are reaching skeletal maturity. This study analyzes current patient status (particularly need for fusion and VEPTR removal) as this unique treatment cohort completes the expansion phase of VEPTR management.

Methods: Using the VEPTR FDA Feasibility and IDE study database, we captured every VEPTR patient who has had either: 1) a final fusion or 2) no expansions for the past 2 yrs. Patients were assigned to a category: “fused” (had spinal fusion, with or without VEPTR removal), “VEPTR only” (no spinal fusion planned) or “undetermined” (not actively expanding, may or may not have fusion in future). We evaluated demographic data, diagnosis, age at last expansion, last surgery, plans for fusion and the device-related complication.

Results: The 39 VEPTR graduates are now 12-25 y/o (mean 16.6 y/o); 18 had a spinal fusion, 11 will have only VEPTR treatment, and 10 are undetermined. 68% of the patients with congenital scoliosis/fused ribs or progressive scoliosis have had a fusion, while only 16% with hypoplastic or flail chest have been fused. The VEPTR devices were retained in 10/18 “fusion” and 9/11 “VEPTR-only” patients. 2 patients had device failure (hook or sleeve breakage) waiting for their fusion. According to their surgeon, only 3/10 “undetermined” patients are likely to have a future spinal fusion; thus, most of the “undetermined” group probably will become “VEPTR only” in the future.

Conclusion: VEPTR endpoint management varies by underlying diagnosis. VEPTR can be the definitive treatment for children with hypoplastic or flail chest, but most children initially treated with VEPTR for congenital scoliosis, or progressive scoliosis without fused ribs, will have a definitive spinal fusion after expansions are complete. Regardless, most VEPTR devices are not removed at the end of treatment.

Significance: This is the first report of “endpoint” management for children treated with VEPTR. Results of this initial cohort are useful in guiding surgeons and families who are currently in the early stages of VEPTR treatment.

Status	# of patients	Congenital scoli/fused ribs	Progressive scoliosis without fused ribs	Hypoplastic Chest	Flail Chest	VEPTR still in	VEPTR removed
Fused	18	8	7	2	1	10	8
VEPTR only	11	3	1	3	4	9	2
Undetermined	10	3	0	7	0	10	0

* The FDA has not cleared a drug and/or medical device in use described in this presentation (i.e., the drug or medical device is being discussed in an off-label use). For full information see page 10.

Paper #17

***Vertebral Body Stapling: A Treatment Option for the Growing Child with Scoliosis**

Randal R. Betz, MD (Shriners Hospitals for Children, Philadelphia); Ashish Ranade, MD; Amer F. Samdani, MD; Ross Chafetz, DPT, MPH; Linda P. D'Andrea, MD; John P. Gaughan; JahanGir Asghar, MD; Harsh Grewal; Mary Jane Mulcahey

Introduction: Bracing for IS is only moderately successful in preventing curve progression and has associated psychosocial ramifications. We report the results of VBS in growing children with IS.

Methods: This is a retrospective review of a cohort of patients having had VBS and meeting the following inclusion criteria: 1) idiopathic scoliosis; 2) Risser 0 or 1; 3) curves 20 to 45°; 4) proportional staples (since 2002); 5) minimum 2-year follow-up. All the chart and radiographic data were specifically reviewed under an IRB approval by two independent observers.

Results: 29 patients met the inclusion criteria, of whom 28 (96.6%) were available for this study. There were 41 curves (26 thoracic, 15 lumbar). 13 patients had both curves stapled. The average age was 9.4 years. Success was defined as 'improved' (more than 10° less than pre-op curve measurement) or 'no change' (within 10° of their pre-op measurement.) Thoracic curves measuring <35° had a 79% success rate. Curves measuring <20° on first erect radiograph had an 86% success rate. In patients with thoracic curves >35°, 6 of 8 progressed past 50°. Logistic regression analysis for successful outcome showed percent bend correction pre-op to be a strong positive predictor (p=.009). 71% of patients with hypokyphosis showed improvement to a normal sagittal profile. Only one patient demonstrated worsening of kyphosis associated with coronal progression. Lumbar curves had an overall 87% success rate, with only 1 patient with a pre-op curve of 40° progressing to 50°. Five patients lost >10° of lordosis, but their final lumbar lordosis remained in the normal range. There were no infections or neurologic injuries. There was one atelectasis requiring bronchoscopy and one superior mesenteric artery syndrome. Blood loss averaged 212 ml.

Conclusion: This paper suggests a trend of success following VBS in high-risk idiopathic curves. Best results were seen in all lumbar curves and in thoracic curves <35° or where they were flexible, and with the measurement on first erect radiograph <20°.



Paper #18

Clinical Significance of a Corrective Cast/Brace in the Era of Non-Fusion Surgery (Treatment for Early Onset Scoliosis with a Corrective Cast)

Tsuji Taichi, MD (Meijo Hospital); Noriaki Kawakami, MD; Kazuyoshi Miyasaka, MD; Tetsuya Ohara, MD; Ayato Nohara, MD

Introduction: It is difficult and still controversial to treat early onset scoliosis (EOS). Recently, non-fusion surgery have become very popular as one of the standard treatments of spinal deformity in young children. However, as many complications have been reported. Although treatment with a corrective cast has been reported an adverse constrictive effect for the thorax, it may be possible to postpone the time of surgical treatment through its use.

Methods: We have performed cast treatment for 36 EOS patients. The diagnoses were syndromic scoliosis in 21 patients, idiopathic in 10, congenital in 5. The mean age was 3.3 years. All patients were conscious or sleeping during the application of the cast. The patients were placed onto a Risser-table, which provided head and leg traction and was molded with a plaster cast. After applying the cast for 2 to 4 weeks, we switched from the cast to an active corrective brace. According to their scoliosis angle we planned to repeat application of the cast after an interval of several months followed by reapplication of the brace.

Results: The Cobb angle was 55.6° (34-114) prior to casting and 22.9° (5-49) during casting. Application of the cast was performed an average 2.6 times for each patient. Surgery was performed in 12 of 31 cases. In a group of patients who underwent surgery, the average age at the time of operation was 6.1 years and the duration from the first casting to the operation was 2.4 years. Preoperative Cobb's angle was 72.2° and increased by 13.6° from the time of first admission for the cast. Postoperative Cobb's angle was 21°. The overall complication rate was 10%. Three patients exhibited a complication of skin sloughing. In a patient with funnel chest who had undergone surgery for application of a chest bar, we had to cease the cast treatment because of skin infection at the site of hardware prominence.

Conclusion: A corrective cast is safe and effective for the treatment of EOS. We were able to control EOS using a corrective cast and a brace. We conclude that a corrective cast is one of the options for EOS treatment and is worthwhile attempting, because it may inhibit the progression of scoliosis and allow a few years until it is time to proceed to surgical treatment in an older child.

Paper #19

**RUSSELL A. HIBBS AWARD NOMINEE FOR BEST CLINICAL PRESENTATION

Revision Rates Following Primary Adult Spinal Deformity Surgery: 667 Consecutive Patients Followed Up to 21 Years Postoperatively.

Mark Pichelmann, MD (Washington University); Lawrence G. Lenke, MD; Christopher R. Good, MD; Patrick T. O'Leary, MD; Keith H. Bridwell, MD; Brenda A. Sides, MA

Introduction: No studies exist to define the frequency of repeat surgical intervention following definitive spinal fusion for adult deformity over a long time period of evaluation. The objective of this study is to report the rate of unanticipated repeat surgery for any cause in this population at a single institution.

Methods: This is a retrospective review of all patients presenting for primary instrumented spinal fusion with a diagnosis of adult deformity at a single institution from 1985 to 2007. All surgical patients with instrumented fusion of 5 or more levels using hooks, hybrid or screw only constructs were identified using a prospectively collected database. Patient charts and radiographs were reviewed to provide information as to the indication for initial and revision surgery. A total of 667 patients underwent primary instrumented fusion for a diagnosis of adult idiopathic scoliosis (n=465), de novo degenerative scoliosis (n=105), or kyphotic disease (n=97) were evaluated. The mean age was 41.1 years (range 18-77) and mean follow-up was 7.8 years (range 1-21 years).

Results: 58 patients (8.7%) underwent at least one revision surgery and 14 of the 667 (2.1%) had more than one revision (mean 1.3, range 1-3). The mean time to the first revision was 4.0 years (range 1 week - 19.7 years). Of the 58 patients, the most common reasons for revision were pseudarthrosis (25/667 = 3.7%; 25/58 = 43.1%), curve progression (13/667 = 1.9%; 13/58 = 22.4%), infection (9/667 = 1.3%; 9/58 = 15.5%) and painful or prominent implants (4/667 = 0.6%; 4/58 = 6.9%). More rare reasons consisted of adjacent segment degeneration (3), implant failure (2), neurologic deficit (1) and coronal imbalance (1). Revision rates over the follow-up period were: 0-2 years (26/58 = 44.8%), 2-5 years (17/58 = 29.3%), 5-10 years (7/58 = 12.1%), > 10 years (8/58 = 13.8%).

Conclusion: Repeat surgical intervention following definitive spinal instrumented fusion for primary adult deformity occurs at a relatively low rate of 8.7%. The most common reasons for revision are predictable and include pseudarthrosis, proximal/distal curve progression and infection.

Significance: These findings demonstrate that adult deformity surgery has a low rate of unanticipated revisions.

Paper #20

Survivorship of Primary Fusion for Adult Spinal Deformity: Rate, Reason, and Time of Reoperation

James M. Mok, MD (University of California, San Francisco); Jordan M. Cloyd; David S. Bradford, MD; Serena S. Hu, MD; Vedat Deviren, MD; Jason Smith, MD; Sigurd Berven, MD

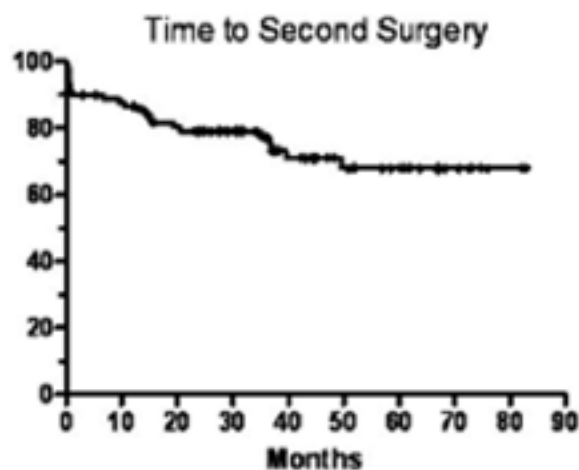
Introduction: Compared to the adolescent population, surgery for adult deformity is often more complex and technically difficult, contributing to a high reported rate of complications that can result in the need for reoperation. Reported rates vary widely due to differences in surgical technique, instrumentation, patient population, and criteria used to define reoperation.

Methods: From 1999 to 2004, all patients who underwent primary instrumented fusion for non-paralytic adult spinal deformity at a single center were included. Inclusion criteria included minimum age at surgery of 20 years and minimum fusion length of 4 motion segments. Surgical, demographic, and co-morbidity data were obtained retrospectively by chart review. Reoperation was defined as any additional surgery involving levels of the spine operated on during the index procedure. Kaplan-Meier method was used to calculate cumulative probability for reoperation. Comparisons were performed between the reoperation group and patients who did not have reoperation.

Results: 89 patients met inclusion criteria. Endpoint (minimum 2 years follow-up or reoperation) was reached for 91%. Mean follow-up was 3.8 years (range, 2-6.9). Cumulative reoperation rate was 25.8%. Survival was 86.4% at 1 year, 77.2% at 2 years, and 75.2% at 3 years. Reasons for reoperation included infection (n=8), pseudarthrosis (n=3), adjacent segment problems (n=5), implant failure (n=4), and removal of painful implants (n=3). ASA class and smoking status were significantly higher in the reoperation group. Subgroup analysis revealed diabetes, age, surgeon experience, and hypothyroidism as significant risk factors for reoperation for infection.

Conclusion: Utilizing a strict definition of reoperation for a well-defined cohort, in the presence of relevant risk factors, many patients undergoing primary fusion for adult spinal deformity required reoperation. The results indicate that complex medical and surgical factors contribute to the treatment challenges posed by patients with adult spinal deformity.

Significance: This represents the largest cohort reported to date of patients undergoing primary fusion using third-generation instrumentation techniques.



Paper #21

Selection of Proximal Fusion Level for Degenerative Lumbar Scoliosis

Kyu-Jung Cho, MD (Inha University Hospital); Se-Il Suk, MD; Kee-Yong Ha, MD; Rack-Yong Chung, MD; Man-Hee Won, MD; Hyung-Suk Kim, MD

Introduction: It has been known that the most horizontal vertebra should be chosen for upper instrumented vertebra in the patient with degenerative lumbar scoliosis. Extension of instrumentation to T10 or proximal may have some benefit to prevent junctional problems. The purpose of this study was to determine the optimal proximal fusion level.

Methods: Fifty-one degenerative lumbar scoliosis patients (mean age 64.6) who underwent posterior spinal instrumentation were analyzed with a minimum 2-year follow-up. The average number of levels fused was 5.9 segments (range 3-9). All patients had the fusion to L5 or S1. In terms of upper instrumented vertebra (UIV), the patients were divided into three groups; Group 1: UIV is horizontal vertebra (HV) or above, Group 2: UIV is between HV and upper end vertebra (UEV), Group 3: UIV is UEV or below. The three groups were compared by their Cobb angle, thoracic kyphosis, lumbar lordosis, T10-L2 angle, sagittal C7 plumb, coronal C7 plumb, proximal kyphotic angle, and UIV tilt. We also analyzed patients with an UIV at T9-T10, T11-T12, or L1-L2 separately focusing on proximal adjacent segment disease (ASD).

Results: There were 21 patients in group 1, 16 in group 2, and 14 in group 3. UEV ranged mainly from T12 to L2, and HV from T10 to T12. The UIV ranged from T9 to L2. Proximal ASD developed in 13 (25%) of 51 patients, including proximal junctional kyphosis (n=7), compression fracture (n=4), and severe disc collapse (n=2). Of the patients, UIV was T10 in 2 patients, T11 in 1, T12 in 1, L1 in 4 and L2 in 5. Group 1 had 2 cases (9.5%) of ASD, group 2 had 3 cases (18.7%) of ASD, and group 3 had 8 cases (57%) of ASD (P=0.004). The average age and follow-up periods were similar in the three groups. The Cobb angle was not different in the groups. Thoracic kyphosis and lumbar lordosis were also not different in the groups. The T10-L2 angle was aggravated in group 3 after surgery with a statistical difference. (See the table)

Conclusion: Proximal ASD developed more frequently when the fusion stopped at UEV or below. Stopping fusion at T11-T12 was relatively acceptable when UIV was above UEV. To prevent a proximal junctional problem, arthrodesis should be extended to the level above UEV for degenerative lumbar scoliosis.

(See table next page)



	Group 1 (UIV=HV or above)	Group 2 (UIV=HV-UEV)	Group 3 (UIV= UEV or below)	P-value
Age (years)	64.1 ± 8.3	64.4 ± 4.8	65.5 ± 4.9	0.84
Follow-up periods (mo)	58.4 ± 28.2	51.3 ± 31.4	62.2 ± 26.9	0.53
No of fused vertebra	7.1 ± 1.1	5.4 ± 1.5	4.5 ± 1.5	0.001
Cobb angle (degree)				
Preop	23.2 ± 7.5	21.8 ± 8.6	20.9 ± 7.9	0.67
Final	5.9 ± 5.0	6.6 ± 5.3	9.9 ± 7.7	0.15
Change	17.3 ± 7.1	15.2 ± 10.2	11.0 ± 6.4	0.08
T5-T12 angle (degree)				
Preop	13.9 ± 16.2	10.4 ± 12.6	13.9 ± 11.5	0.72
Final	15.8 ± 9.7	9.1 ± 10.4	16.7 ± 7.4	0.08
Change	1.5 ± 8.8	-0.4 ± 10.3	0.3 ± 17.1	0.89
Lumbar lordosis (degree)				
Preop	26.0 ± 14.6	24.8 ± 15.7	26.4 ± 12.1	0.96
Final	21.6 ± 9.6	21.1 ± 10.8	24.8 ± 14.1	0.63
Change	-4.5 ± 12.1	-3.8 ± 10.6	-1.6 ± 12.3	0.77
T10-L2 angle (degree)				
Preop	7.3 ± 5.8	6.1 ± 3.9	8.8 ± 7.7	0.64
Final	5.7 ± 7.0	7.5 ± 7.4	17.8 ± 12.8	0.001
Change	-1.8 ± 9.2	1.7 ± 8.5	11.6 ± 13.5	0.01
Sagittal C7 plumb (mm)				
Preop	55.8 ± 35.9	46.2 ± 24.3	45.0 ± 38.9	0.59
Final	83.3 ± 42.4	81.0 ± 43.9	66.5 ± 37.4	0.57
Change	-28.5 ± 35.9	-31.5 ± 27.7	-15.8 ± 36.4	0.51
Coronal C7 plumb (mm)				
Preop	16.1 ± 13.2	14.9 ± 10.7	18.4 ± 20.3	0.18
Final	13.9 ± 9.4	18.3 ± 14.4	14.3 ± 8.1	0.74
Change	2.0 ± 16.8	-3.1 ± 19.5	3.8 ± 22.4	0.49
Proximal junctional angle				
Preop	2.3 ± 3.7	3.4 ± 3.6	3.0 ± 8.5	0.88
Final	5.1 ± 6.7	7.3 ± 7.4	10.5 ± 14.2	0.28
Change	2.8 ± 6.4	4.7 ± 7.1	6.2 ± 12.5	0.59
UIV tilt (degree)				
Preop	2.9 ± 2.4	7.4 ± 4.5	7.1 ± 5.2	0.01
Final	3.1 ± 2.2	2.4 ± 2.2	4.2 ± 3.1	0.19
Change	0.1 ± 3.8	3.4 ± 4.8	2.7 ± 3.7	0.87
Lateral translation (mm)				
Preop	6.7 ± 2.3	5.2 ± 2.2	3.9 ± 2.5	0.01
Final	2.9 ± 2.2	2.8 ± 1.7	2.4 ± 2.2	0.77
Change	3.9 ± 2.9	2.5 ± 1.9	1.5 ± 1.6	0.03

Paper #22

***Comparative Analysis of Two Hybrid Instrumentation Techniques for Adult Lumbar Scoliosis from the Thoracolumbar Spine to L5 or S1**

Yongjung J. Kim, MD; Oheneba Boachie-Adjei, MD (Hospital for Special Surgery); Keith H. Bridwell, MD; Lawrence G. Lenke, MD; Youngbae B. Kim, MD; Thomas W. Lawhorne, MD

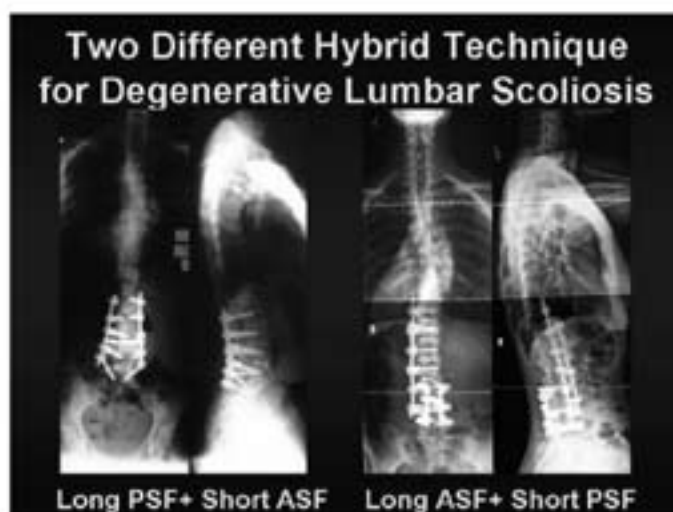Introduction: to compare the postoperative radiographic and clinical outcomes according to the two different approaches (Novel long anterior and short distal posterior instrumented fusion vs. conventional long posterior instrumented fusion with anterior spinal fusion) following adult lumbar scoliosis primary instrumented fusion from T9-L2 to L5-S1.

Methods: A clinical and radiographic assessment of 57 adult lumbar scoliosis patients (average age 53.5 years) who underwent primary long (average 7.8 vertebrae) segmental spinal instrumented fusion from the thoracolumbar spine to the L5-S1 with a minimum 2-year follow up (2-9.5 year follow-up) were compared according to conventional long posterior instrumentation with anterior spinal fusion (Group 1, n=30) vs. long anterior and short distal posterior instrumentation (Group 2, n=27).

Results: Both groups did not demonstrate any differences in age at surgery, follow-up period, total number of fused vertebra, lowest instrumented vertebrae, and pre/postop sagittal vertical axis ($p>0.18$). Group 2 (long anterior and short distal posterior) demonstrated significantly smaller increase in proximal junctional angle (4 vs. 12 degree), thoracic kyphosis angle (6 vs. 13 degree), less prevalence of proximal junctional kyphosis at ultimate follow-up (4/27 vs. 15/30) ($p=0.001$, $p=0.003$, and <0.001) and a significantly larger blood loss (2219 vs. 1054 cc, $p<0.0001$). SRS outcome scores did not demonstrate a significant difference between two groups except self-image subscale score (3.3 in Group 1 vs. 4.1 in Group 2, $p=0.002$).

Conclusion: Long anterior and short distal posterior instrumented hybrid fusions demonstrated significantly smaller postoperative increase in proximal junctional angle despite the larger blood loss. SRS self-image subscale was significantly better in long anterior group.

Significance: Anterior spinal instrumentation and fusion instead of posterior spinal instrumentation and fusion at the TL junction for adult lumbar scoliosis would lessen proximal junctional change/kyphosis at least in the short term.





Paper #23

*Etiology and Revision Surgical Strategies in Failed Lumbosacral Fixation of Adult Spinal Deformity Constructs

Katsumi Harimaya, MD (Washington University); Lawrence G. Lenke, MD; Keith H. Bridwell, MD; Takuya Mishihiro, PhD, MD; Linda Koester; Brenda A. Sides, MA

Introduction: When extending a long spinal fusion down to the sacrum, the lumbosacral (L-S) junction is a common site for implant problems and pseudarthrosis. Our purpose was to evaluate the etiology and salvage strategies of failed L-S fixation in adult spinal deformity patients.

Methods: Clinical and radiographic results of 32 patients (25 females, 7 males, ave. age 53.3 yrs, range 22-73) diagnosed and treated for L-S fixation failure between 1995 and 2004 were reviewed. 21/32 patients underwent revision surgery at one institution for these failures and were followed postoperatively for more than 2 years (ave. 50.5 mos).

Results: (See table). 27/32 patients had 2 sacral screws, 3 patients 1 sacral screw, and 2 patients zero. Bicortical sacral screws were placed in 17 patients, and only 12/32 patients had distal fixation to the sacral screws (bilateral iliac screws, n=9; others, n=3). 16/18 patients without distal fixation to the screws had screw loosening or pullout at L5 or S1. Anteriorly at L5-S1: 4/6 bone grafts collapsed, 5/14 intervertebral discs without anterior column support collapsed, and 2/12 titanium cages subsided into the endplates. Rod breakage between L5 and S1 (n=8) was noted only in patients with distal fixation to the sacral screws. In 21 revision surgeries, 17 patients received distal fusion to bicortical sacral screws consisting of bilateral iliac screws, and 15 patients had anterior column support placed. 16/21 revision patients achieved solid fusion at ultimate follow-up; however, 6 cases had additional rod breakage or dislodgement at the L-S junction, 2 of which occurred when BMP-2 was used for the fusion.

Conclusion: With long fusions to the sacrum in the treatment of spinal deformity, the use of bilateral S1 screws alone may allow for screw loosening/pullout and/or L5-S1 cage/graft collapse/subsidence. Adding bilateral iliac screws will protect the S1 screws, but may still allow L5-S1 rod breakage/dislodgement due to lumbosacral pseudarthrosis even with BMP-2 used in revision surgery.

Paper #24

Fusions to the Sacrum for Adult Spinal Deformity: How High Do You Go? (T2-4 vs T10-L1) The Effect on Sagittal Alignment and Outcomes.

Charles C. Edwards, II, MD (The Maryland Spine Center); Keith H. Bridwell, MD; Michael R. Shainline, MS; William C. Horton, III, MD; Sigurd Berven, MD; Christopher I. Shaffrey, MD; Steven D. Glassman, MD; Christopher L. Hamill, MD; Stephen L. Ondra, MD

Introduction: The published literature provides little guidance to surgeons in the selection of the optimal proximal fusion level for adult spinal deformity. The purpose of this study was to evaluate the outcomes of adult spinal deformity fusions from the sacrum to either the thoraco-lumbar junction (TL) versus the upper thoracic spine (UT). A matched cohort analysis using a multicenter prospective database allowed for the comparison of radiographic results, complications and functional outcomes at 2-year follow-up.

Methods: 40 patients (15 UT/ 25-TL) with 2-year minimum complete prospective radiographic and functional outcomes data were matched into two cohorts according to preoperative global sagittal alignment (UT:+59mm/TL:+58mm), revision status(UT:67%/TL:64%) and preoperative SRS total score (UT:3.0/TL:2.9). The cohorts were very similar in terms of age:(51 UT/ 59 TL), and the use of staged procedures :(13% UT/ 16% TL)

Results: Global sagittal balance deteriorated in the TL cohort from postop to 2-years (+1.6 cm, sd: 2.1 cm), whereas it actually improved for patients fused to the UT spine (-2.0cm, sd 2.6cm; p=0.001). The percentage of patients with complications was similar for the two cohorts (UT:48%, TL:44%; p=0.16). Outcomes were nearly identical for the two cohorts at two years in terms of pain (Oswesty @ 2-years; UT:26.7; TL: 25.8), and total SRS scores (preop→2 yrs; UT: 3.0→3.6, Δ0.6; TL: 2.9→ 3.8, Δ0.9). Satisfaction was nearly identical for the two cohorts: (2 yr SRS satisfaction subset score: UT:4.0; TL: 4.1). Improvement in the SRS activity subset score was superior for patients fused to the TL junction (preop. 2yr: UT: 3.1 →3.3, Δ0.2; TL: 2.8→ 3.5, Δ0.7; p=0.00002).

Conclusion: Long adult deformity fusions from either the UT or TL junction to the sacrum result in a similar rates of complications, and yield nearly identical improvements in pain, SRS total scores, and satisfaction at two years. Although patients fused to the TL junction experienced superior improvement in their activity at 2 years, this came at the expense of a postoperative forward shift in global sagittal alignment compared to patients fused to the UT spine.

Significance: This is the first study to use a matched cohort analysis to compare the UT and TL regions as an upper fusion level for long adult deformity fusions to the sacrum. Both cohorts had similar functional outcomes and complications with the exception of a superior improvement in activity and a tendency towards loss of global sagittal alignment among patients fused to the TL junction.



Paper #25

Extension of Fusion to Sacrum in Patients who had Previous Thoracolumbar Fusions to L5: Is it Simple or Complex Surgery?

Murat Pekmezci, MD (University of California San Francisco); Vedat Deviren, MD; Sigurd Berven, MD; Erin Boyd; Ganesh Swamy, MD; David S. Bradford, MD; Serena S. Hu, MD

Introduction: There is still debate about the distal fusion level for long thoracolumbar fusion in patients with a healthy L5-S1 disc. Fusion to S1 eliminates a potential revision surgery at L5-S1 junction but is associated with more complications. Although fusion to L5 is less morbid, it puts the patients at risk for a degeneration at L5-S1. An important question to be answered is the magnitude of the revision surgery when extending the fusion to S1. This study is designed to evaluate the patients who were revised to S1 following long thoracolumbar fusions to L5.

Methods: Adult deformity patients who had extension of their fusion to S1 between 1993 and 2005 were reviewed. The inclusion criteria were prior fusion from thoracic spine to L5 after the age of 18, having revision surgery to extend the fusion to sacrum, minimum 2 year follow-up, and absence of neuromuscular disease. Radiographic and chart review was performed to collect radiographic parameters, age, gender, revision procedure, complications, blood loss, surgical time, further revision procedures.

Results: Eleven patients met the inclusion criteria. The average time to revision was 68 months (5-240). The average age at revision was 57 (38-73). All but 3 patients appeared to have originally been fused with sagittal and coronal balance. The average follow-up was 63 months. Eight patients had Smith-Peterson osteotomies (SPO) and 3 patients had pedicle subtraction osteotomies (PSO) during the index revision procedure. All patients had circumferential fusion. Three patients who were initially treated with SPO later required PSO secondary to progressive sagittal and coronal decompensation. Two patients had revision surgery for pseudarthrosis at L5-S1 junction. Overall 5 patients required a total of 6 further revision surgeries.

Conclusion: Conversion of previous long fusion to L5 to sacrum may necessitate osteotomies to correct imbalance. Forty-five percent of patients required further revision surgeries and 55 percent of our cohort required major procedures as PSO.

Significance: This is the first report to date that specifically evaluates the extension of fusion to sacrum in patients who were previously fused to L5 and demonstrates the need to restore the patient's truncal balance when performing these procedures.

Paper #26

***A Matched Cohort Study of Long Adult Spinal Deformity Surgery to the Sacrum/Ilium Using rhBMP-2 versus Autogenous Iliac Crest Bone Graft**

Takeshi Maeda, MD; Jacob M. Buchowski, MD, MS (Washington University in St. Louis); Keith H. Bridwell, MD; Linda Koester

Introduction: Only a few studies have been reported on the efficacy of rhBMP-2 in the multilevel adult spinal deformity surgery. The purpose of this retrospective matched cohort study was to compare the results of surgery with either rhBMP-2 without iliac crest bone graft (BMP group) or ICBG without BMP (ICBG group).

Methods: To obtain relatively uniform background, we selected patients with adult degenerative spinal deformity who underwent primary fusion from at least T12 to the sacrum/ilium and had a minimum 2-year follow-up. All patients had both anterior and posterior surgeries, except for one patient in BMP group who did not undergo the planned anterior surgery due to acute renal failure following the posterior procedure. Patients with neuromuscular deformity, ankylosing spondylitis, and patients who received both ICBG and BMP were excluded from this study. The two groups were matched for age, gender (all females), smoking history, comorbidity, BMI, number of vertebrae fused, and the degree of deformity (measured using the Cobb angle).

Results: There were 15 patients in BMP group and 17 in ICBG group (Table 1). Of the 17 patients in the ICBG group, 12 patients (70.6%) achieved a solid fusion, while all 15 patients (100%) in the BMP group achieved a solid fusion (with the caveat that the follow-up period was shorter in the latter group (average 4.9 vs. 2.7 years). Both groups were similar in terms of deformity correction. No BMP-related complications were observed.

Conclusion: The pseudarthrosis rate in the BMP groups compares favorably to pseudarthrosis rate in the ICBG group.

Significance: This study clearly demonstrates that the use of BMP leads to a high fusion rate in adult spinal deformity surgery to the sacrum/ilium with no pseudarthroses across the thoracolumbar or lumbosacral junctions noted in this study, all the while avoiding ICBG harvest site morbidity.



Paper #27

Operative versus Non-Operative Treatment of Leg Pain in Adults with Scoliosis: A Retrospective Review of a Prospective Multicenter Database with Two-Year Follow-Up

Justin S. Smith, MD, PhD (University of Virginia); Christopher I. Shaffrey, MD; Sigurd Berven, MD; Steven D. Glassman, MD; Christopher L. Hamill, MD; William C. Horton, III, MD; Stephen L. Ondra, MD; Frank J. Schwab, MD; Kai-Ming Fu, MD; Keith H. Bridwell, MD

Introduction: Patients with adult scoliosis characteristically present with significant disability, including neural symptoms and leg pain. The presence of leg pain is an independent predictor of a patient's choice for operative over non-operative care. The purpose of this study was to assess whether surgery offers significant and durable improvement of leg pain compared with non-operative management.

Methods: This study is a retrospective review of a prospective multicenter database of adults with spinal deformity. At enrollment and follow-up, patients complete standardized questionnaires, including Oswestry Disability Index (ODI) and specific assessment of leg pain using the visual analog score (VAS). Initial plan for surgical or conservative treatment was made by the patient and surgeon at the time of enrollment.

Results: 329 patients with adult scoliosis were included. 211 (64%) had leg pain (VAS>0) at presentation (mean VAS=4.7). 98 patients with leg pain (46%) were managed surgically, and 113 (54%) were treated with non-operative care. The operative group had higher baseline mean VAS for leg pain (5.4 vs 4.1, P<0.001) and higher mean ODI (41 vs 30, P<0.001). At two-year follow-up, non-operative patients did not have significant change in ODI (P=0.5) or VAS for leg pain (P=0.2). In contrast, at two-year follow-up surgically treated patients had significant improvement in mean VAS for leg pain (5.4 to 2.2, P<0.001) and ODI (41 to 24, P<0.001). Compared with non-operatively treated patients, at two-year follow-up operative patients had lower mean VAS for leg pain (2.2 vs 3.8, P<0.001) and ODI (24 vs 31, P=0.005).

Conclusion: Despite having started with significantly greater leg pain and disability, surgically treated patients at two-year follow-up had significantly less leg pain and disability than non-operatively treated patients. Careful assessment and consideration of leg pain should be included in decision making in adults with scoliosis.

Significance: Compared with conservative treatment, surgery offers significant improvement of leg pain for adults with scoliosis.

Paper #28

Surgical Outcomes of Decompression, Decompression with Limited Fusion and Decompression with Full Curve Fusion for Degenerative Scoliosis with Radiculopathy

Raymond Topp, MD (Brooke Army Medical Center); Ensor E. Transfeldt, MD; Amir A. Mehbod, MD; Robert B. Winter, MD

Introduction: Degenerative scoliosis is often associated with radiculopathy. Surgical treatments involve decompression with or without instrumented fusions however no consensus for surgical management exists.

Methods: A chart review of 177 patients surgically managed over 7 years by a multisurgeon spine center was performed. 148 patients were included and were analyzed in three groups: decompression alone (D), decompression with limited fusion (D-LF) and decompression with full curve fusion (D-FF). Success was defined as >25% improvement in ODI, as well as, the patient's report of success from a questionnaire. For each group, logistic regression analysis was utilized to examine the probability of a success with regards to specific surgical variables.

Results: 104/148 (70.2%) patients were available for 5 year follow-up after surgery. Pre- and postoperative Cobb angles were similar in the D and D-LF groups and there was no significant change in pre- to postoperative angles in these two groups. Patients in the D-FF group had a higher mean preoperative angle of 39.4 degrees and a significant change was seen in this group to 19.4 degrees postoperatively. Mean blood loss in the D-FF group was 1538cc while the D-LF and D groups, mean blood loss were 450 and 107.5cc, respectively. Complications were highest in fused patients with no impact on success. 75% of patients in the D-FF group reported successful surgery while 73.9% and 63.6% felt the same in the D-LF and D groups, respectively. Regression analysis revealed the probability of surgical success was significantly decreased with sacral to apical curve fusions and with postoperative positive sagittal balance.

Conclusion: The treatment for degenerative scoliosis presenting radiculopathy remains a challenge for the spine surgeon. Patients may be treated effectively with either decompression alone or decompression with fusion. Choice of the procedure depends on the levels requiring decompression as they relate to the curve apex and sagittal balance.

Significance: No prior study examines the outcomes of surgery for degenerative scoliosis with radiculopathy. By analyzing outcomes, this study assists in standardizing surgical treatments and defines pitfalls that are associated with poor outcomes.



Paper #29

Effects of Early Correction in High-Grade Developmental Spondylolisthesis L5/S1 on Sagittal Profile and Clinical Outcome

Michael Ruf, MD (Zentralklinikum Suhl); Rubens Jensen, MD; Prof. Harry R. Merk; Torsten Eichhorn, MD; Prof. Jürgen Harms

Introduction: Developmental spondylolisthesis L5/S1 affects the overall spinal profile. Lumbosacral kyphosis with retroversion of the sacrum results in the development of lumbar hyperlordosis and anterior shift of the spinal gravity line. This retrospective study shows the effect of early correction with reduction and monosegmental fusion L5/S1 on the overall sagittal profile and clinical outcome.

Methods: Thirty-three patients with severe developmental spondylolisthesis L5/S1 (Meyerding grade 3 to 5) were operated on between February 1997 and July 2002. Monosegmental fusion L5/S1 was performed; reduction was achieved by temporary instrumentation of L4. Statistical comparison of two groups was performed. Group 1: age 9 to 14 yrs (average 12+9 yrs); group 2: age 15 to 28 yrs (average 19+2 yrs); radiological evaluation preop./ postop./ min. 2 yrs follow-up, SRS30 outcome score at follow-up.

Results: The overall sagittal profile improved dramatically in both groups. In group 1 the average slippage was 79.8% preop., 7.8% postop., and 7.0% at follow-up, segmental kyphosis L5/S1 +21.7°, -7.4°, and -7.9°. In group 2 slippage averaged 72.6% preop., 12.8% postop., and 12.7% at follow-up, segmental kyphosis +19.4°, -7.0°, and -7.1°. The anterior shift of the gravity line in group 1 improved from 50.9 mm to 35.3 mm (fu. 29.5 mm). Improvement was less in group 2: 59.8 mm preop., 50.7 mm postop., and 47.6 mm at follow-up. SRS30 outcome score: (group 1/ group 2): Pain 4.57/ 4.18, function 4.32/ 3.90, self image 4.35/ 4.06, mental health 4.13/ 3.68, satisfaction 4.75/ 4.29.

Conclusion: Reduction of segmental kyphosis and slippage in developmental spondylolisthesis is of high importance for the overall sagittal profile of the spine. In younger patients a better correction of slippage L5/S1 and lumbosacral kyphosis could be achieved. This allowed for the development of a more balanced sagittal profile with better positioning of the gravity line. Clinical outcome score showed better results in the younger patients group; risk of L5 root lesion was lower in this group as well.

Significance: The results suggest early operative intervention in high grade developmental spondylolisthesis.

Paper #30

Sagittal Spino-Pelvic Alignment in Developmental Spondylolisthesis and its Potential Relevance for Reduction

Jean-Marc Mac-Thiong, MD (CHU Sainte-Justine); Zhi Wang, MD; Jacques A. de Guise, PhD; Hubert Labelle, MD

Introduction: In normal subjects, the sagittal spino-pelvic alignment is such that the shape and orientation of each successive anatomical segment are closely related and influence the adjacent segment. However, the relationships between parameters of sagittal spino-pelvic alignment in developmental spondylolisthesis are still unclear.

Methods: Radiographs of 120 control subjects and 131 subjects with developmental spondylolisthesis (91 low-grade, 40 high-grade) were reviewed. Subjects with high-grade spondylolisthesis were divided according to their sacro-pelvic balance: balanced vs. unbalanced sacro-pelvis. Parameters of the sacro-pelvis (pelvic incidence, pelvic tilt, sacral slope), lumbosacral region (lumbosacral angle, slip percentage), lumbar spine (lumbar lordosis, lumbar tilt, L5 inferior slope), thoracic spine (thoracic kyphosis, thoracic tilt), and global balance (spinal tilt, sagittal spino-pelvic offset between C7 and femoral heads) were assessed. Parameters were compared between all groups and a correlation study was performed between all parameters.

Results: Significant differences in all parameters are found between all groups, except for sagittal spino-pelvic offset. The pattern and strength of correlations is similar between normal and low-grade subjects, showing interdependence between sacro-pelvic, lumbosacral, lumbar and thoracic regions. The pattern of relationships was altered in high-grade spondylolisthesis, especially for subjects with a unbalanced sacro-pelvis for which correlations between pelvic incidence and pelvic tilt, and between the sacro-pelvic unit and lumbar spine geometry are lost.

Conclusion: Children and adolescents stand with a relatively constant global sagittal balance, regardless of the local lumbosacral deformity. A relatively normal spino-pelvic alignment is maintained in low-grade spondylolisthesis and in high-grade spondylolisthesis with a balanced sacro-pelvis. Spino-pelvic alignment is abnormal in high-grade spondylolisthesis associated with an unbalanced sacro-pelvis.

Significance: The results of this study suggest that surgical reduction of the local lumbosacral deformity might be attempted to restore a normal spino-pelvic alignment in high-grade spondylolisthesis associated with an unbalanced sacro-pelvis.

Table I.86 Mean, standard deviation and ANOVA results for the comparison between the normal, low-grade and high-grade spondylolisthesis groups.

Anatomical region	Parameter	Normal group (n=120)	Low-grade group (N=91)	High-grade group (n=40)	P value (ANOVA)
Thoracic spine	Thoracic kyphosis (°)	41.0±11.2	41.7±9.7	30.4±13.6	<10 ⁻⁷
	Thoracic tilt (°)	-1.5±5.9	-0.2±5.3	-5.1±7.3	<10 ⁻⁴
Lumbar spine	Lumbar lordosis (°)	-45.5±13.3	-54.7±14.5	-86.4±16.2	<10 ⁻³⁷
	Lumbar tilt (°)	-6.7±5.9	-4.1±6.3	17.9±10.5	<10 ⁻⁵⁰
	L5 inferior slope (°)	29.2±9.0	39.8±13.4	77.5±11.5	<10 ⁻⁶³
Lumbosacral spine	Slip percentage (%)	0	14.7±9.1	78.8±20.2	<10 ⁻⁹⁸
	Lumbosacral angle (°)	-13.4±5.8	-11.5±7.5	36.6±24.0	<10 ⁻⁶⁸
Sacro-pelvis	Sacral slope (°)	42.8±8.5	51.3±12.1	45.1±15.3	<10 ⁻⁶
	Pelvic tilt (°)	5.5±7.9	11.9±8.2	32.2±10.4	<10 ⁻⁴²
	Pelvic incidence (°)	48.2±11.4	63.2±13.6	77.3±13.0	<10 ⁻²⁹
Global spine	Spinal tilt (°)	92.7±4.3	90.2±3.7	85.3±6.2	<10 ⁻¹⁵
	Sagittal offset (°)	-2.8±3.8	-2.3±3.3	-3.0±4.5	0.50

* The FDA has not cleared a drug and/or medical device in use described in this presentation (i.e., the drug or medical device is being discussed in an off-label use). For full information see page 10.



Paper #31

Radiological Assessment of L4-L5 Segment and Sacral Position after Surgical Reduction of L5-S1 Severe Spondylolisthesis and Spondyloptosis Throughout a Single Posterior Approach.

Jesus Burgos, MD; Prof. Carlos Barrios; Ignasi Sampera, MD (Hospital Ramón y Cajal); Eduardo Hevia, MD; Pedro Domenech, MD; Pedro R. Gutierrez, MD; Gabriel Piza, MD; Oscar G. Riquelme-García, MD, PhD; Ignacio Alvarez, MD; José I. Maruenda, MD; Enrique Recarte, MD

Introduction: Surgical reduction of L5-S1 severe spondylolisthesis is aimed at restoring vertebral sagittal balance, improving the transmission of axial loading to adjacent segments. There are very few studies in the literature addressing sagittal balance of L4-L5 segment in relation to sacral position after surgical correction of L5-S1 severe spondylolisthesis.

Methods: A group of 23 patients with L5-S1 severe spondylolisthesis (Meyerding grade III-IV) (n, 20) and L5-S1 spondyloptosis (n, 3) were operated on by a single posterior approach. Surgical technique included placement of L5 and S1 pedicle screws under direct vision, L5-S1 discectomy, removal of sacral dome and reduction of the deformity by applying bending forces on the bars with the help of sublaminar hooks. Intersomatic and posterolateral fusion were performed in a conventional manner using disc spacers. X-rays of the whole spine in standing position were taken preoperatively and 2 years after surgery. Different radiological parameters were analyzed including L5-S1 slippage, sacral inclination, sagittal angulation of L4-L5, sagittal rotation angle (SRA) y sagittal balance.

Results: Mean L5-S1 slippage improves from 71% (range, 50-100) to 18% (range, 0-43) after surgery. Preoperative sacral inclination had a mean value of 28 degrees (range, 12-43), and 33 degrees (range, 12-58) after surgery. Mean sagittal angulation of the L4-L5 disc moves from -16.3 degrees to -2.4 after surgery. Ten cases (43%) showed L4-L5 kyphosis. Preoperative SRA has a mean value of 19.1 degrees (range, 5-36), and +6.5 (range, +25 to -7) after surgery. In 7 cases, RSA became negative showing all L4-L5 kyphosis. The plumb line from center of C7 to the upper posterior edge of S1 did not change significantly (63.2 mm pre-op to 64.1 mm post-op).

Conclusion: Reduction of severe L5-S1 spondylolisthesis conditioning negative RSA should be avoided. Negative RSA induces kyphosis at the L4-L5 segment which might presumably entail long term poor prognosis.

Significance: Important recommendations are given in this paper concerning L5-S1 reduction of severe L5-S1 spondylolisthesis. Kyphosis of the L4-L5 segment became apparent in cases with a negative SRA after surgery and should be avoided in order to prevent adjacent disc degeneration.

Paper #32

The Relationship Between Pelvic Balance and a Dome-Shaped Sacrum in L5-S1 Developmental Spondylolisthesis

Pierre Roussouly, MD; Hubert Labelle, MD (Sainte-Justine University Center Hospital); Eric Berthonnaud, PhD; Serena S. Hu, MD; Courtney Brown, MD

Introduction: Goal was to analyze the differences in sagittal alignment between the flat and dome-shaped sacrum in high grade spondylolisthesis (HGS) and determine whether it should affect surgical decision-making.

Methods: Lateral standing X-rays of 582 subjects (mean age 17.6±10) with grade 1 to 5 spondylolisthesis were analysed with a custom software allowing the calculation of the following parameters: pelvic incidence (PI), L5 incidence (IL5), sacral slope (SS), pelvic tilt (PT), lumbar lordosis (LL), thoracic kyphosis (TK), grade (%) and C7 plumbline. Three sub-groups were analysed: flat sacrum with slip <35% (N=293) and HGS with slipping >35% with flat (N=215) or dome shaped sacrum (N=74), determined using the criteria proposed by the Spinal Deformity Study Group. In addition, each HGS was classified as balanced or unbalanced (retroverted) pelvis, using the criteria of Hresko et al.

Results: No significant differences in age or gender were found in the 3 sub-groups. Regarding the orientation of L5 superior endplate, the two groups with a flat sacrum had small differences of IL5 (28° vs 46°), while subjects with a domed sacrum had significantly higher values (71°). C7 had the same position in the three groups, but subjects with a dome shaped sacrum stood with a much higher PT (32°) compared to both flat sacrum groups (14° vs 21°), and with a higher LL and more vertebrae in the lordotic curve, smaller TK, and fewer vertebrae in the kyphotic curve. In HGS, subjects with domed sacrum were much more likely to stand with an unbalanced retroverted pelvis and a forward tilt of LL.

Conclusion: Subjects with a dome shaped sacrum stand with a spino-pelvic alignment different from those with a flat sacrum. Differences in IL5 in the 2 groups with flat sacrum suggest that in HGS, the orientation of L5 endplate slippage compared to S1 is slightly tilted, while doming of the sacrum induces a rotational slip which dramatically increases the tilt of L5, increases lumbo-sacral kyphosis and is compensated by an retroverted pelvic posture, despite an increasing lordosis.

Significance: The presence of sacral doming should alert the surgeon to the risk of an impaired spino-pelvic alignment and to the possible need for surgical reduction to correct pelvic balance.

Paper #33**Stand-Alone Anterior Reconstruction in Cervical Kyphosis: A Prospective Analysis**

Mihir R. Bapat, MD, DN; Nanjundappa S. Harshavardhana, MS(Orth), Dip. SICOT; Kshitij S. Chaudhary, MS, DNB; Umesh S. Methkar, MS (Harvard University); Satyajit V. Marawar, MD; Prof. Vinod J. Laheri

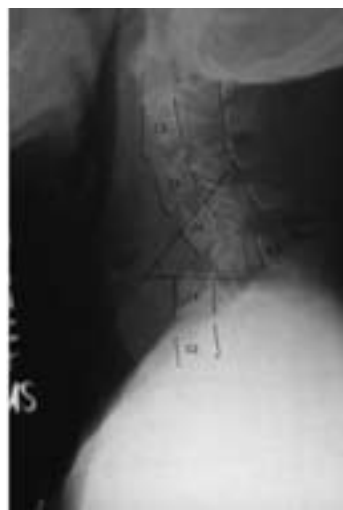Introduction: Prospective analysis of stand-alone anterior reconstruction in cervical kyphosis which would otherwise require staged anterior and posterior surgeries is sparse. Our aims and objectives were hence to evaluate outcome of the same and analyse post-op complications.

Methods: 45 consecutive patients aged 6-71yrs (mean 34.2yrs) who had a kyphosis of >10 measured from lower end-plate of C2 and C7 and underwent anterior surgery alone for cervical kyphosis over 6 yrs (2000-05) formed the study group. The minimum follow-up was 2yrs (mean f/u 3.92yrs). The mean pre-op kyphosis was 22.63 (10-73). Etiologies were tuberculosis (27), dysplasia (6), trauma (7) and tumors (5) respectively. 41 of the 45 patients had myelopathic signs. Mean pre-op JOA score was 7.8 (0-12). A left anterior cervical approach was used in most of the cases. Modified manubriotomy was required in 7 cases to instrument the caudal vertebra. Tricortical iliac crest strut graft was used in 41 and cylindrical mesh cage in 4 cases respectively. Post-operatively all patients wore cervical orthosis for 3 months.

Results: 44 patients were available for analysis at the end of 2 yrs. The mean number of corpectomies required were 2.4 (1-4) and the mean anterior column defect reconstructed was 26.8mm (19-44mm). The average graft subsidence was 4mm (0-11mm). 3 patients required revision surgery within 6 weeks for implant/graft failure. Fusion occurred in rest of 42 patients. No further graft subsidence was noticed at 4 years in 19 patients. Spontaneous fusion at 5 months was seen in normal adjacent cranial segment due to plate overlapping in 3 instances. The average correction achieved was 17.85 (-4 to -73). The mortality rate was 2.22% (1 case). The post-op adverse events were oesophageal perforation (1), transient hypoglossal nerve paresis (1) and recurrent laryngeal nerve palsy (2). The mean post-operative JOA score was 13.8 (9-17). There were 1 deep and 2 superficial infections.

Conclusion: Stand-alone anterior decompression and reconstruction with instrumentation facilitates neurological recovery and restores alignment.

Significance: Stand-alone anterior surgery may obviate the need for both anterior/posterior reconstruction in selective group of patients with cervical kyphosis.



Paper #34

Circumferential Correction of Cervical Kyphosis Results in Improved Outcomes

Sanjay S. Dhall, MD; Regis W. Haid, MD; Praveen V. Mummaneni, MD (UCSF)

Introduction: Few prior reports of cervical kyphosis correction have examined combined anterior/posterior correction methods. Fusion rates and standardized neurological functional measurements are rarely cited in literature examining these techniques. We present our results with cervical kyphosis correction.

Methods: 25 patients underwent surgery for cervical kyphotic deformity. Etiologies included degenerative (10), fracture (10), osteomyelitis (2), and oncologic (3). Anterior procedures included discectomies and corpectomies on one or more levels. Posterior operations included lateral mass and pedicle fixation with decompression and/or osteotomies. Preoperative and postoperative Ishihara kyphosis indices, modified JOA scores, and Nurick grades were assigned. Fusion was assessed via dynamic radiographs (CT scans were used in questionable cases).

Results: All but one patient had follow-up. Five patients died during the follow up period. Two died within 3 months of surgery (aspiration pneumonia and ARDS), and the remaining three died of unrelated causes 1-2 years after surgery. The follow up for the remaining 19 patients ranged from 24-77 months (Mean 37 mo). Ishihara indices improved from preop mean of -14 to postop mean of +10. The mean Nurick grade improved from 2.8 preop to 1 postop. The mean modified JOA score improved from 12 preop to 16 postop. All patients fused except one with renal failure and osteoporosis (96% fusion rate). Other complications include one wound infection (treated with debridement and IV antibiotics) and two patients with postoperative dysphagia (requiring PEG).

Conclusion: In cervical kyphosis cases, management with decompression, osteotomies, and stabilization from both anterior and posterior approaches can restore cervical lordosis. Such techniques can provide measurable improvements in neurological function (Nurick grades and modified JOA scores) and achieve high fusion rates, but are associated with postoperative morbidity and mortality.

Significance: This is one of the first reports of cervical kyphosis correction to report standardized outcomes measures with long term radiographic follow up.



Paper #35

Involvement of the Spine in Patients with Multiple Hereditary Exostosis (MHE)

James W. Roach, MD (Intermountain Shrine Hospital); Joshua B. Klatt, MD; Nathan D. Faulkner, MS

Introduction: Extension of a vertebral exostosis into the spinal canal is rare, but many isolated cases have been reported in the literature. Two MHE patients presented with neurologic findings and exostoses in their spinal canals. This led us to perform an MRI in all MHE patients in our institution.

Methods: 38 patients in our institution had MHE. 36 had spinal MRIs to look for spinal column involvement, 2 are pending.

Results: 25 of the 36 had exostoses arising from the spinal column. Of the 36 patients with MRIs, 30 also had plain film radiographs but only 4 of the plain radiographs accurately identified the lesions and another 4 mistakenly identified lesions which were not confirmed by MRI. 9 of the 25 had encroachment into the spinal canal with varying degrees of compromise; 6 had lesions arising from the lamina, 5 cervical and 1 thoracic. 3 patients had lesions arising from their posterior vertebral bodies, 2 cervical and 1 thoracic. Two patients had two encroaching lesions, one with two cervical lamina lesions and the other with a lesion of the cervical lamina and another lesion coming from a rib head which grew through the T3-T4 neural foramen. Of the 9 patients with lesions in the spinal canal 5 had plain radiographs that did not demonstrate the lesion. 4 of the 9 patients had an excision of the lesion. The other 5 patients have lesions that are being observed. After excision, the two patients with neurologic findings improved, one completely and one partially.

Conclusion: In our series of MHE patients 69% had exostoses arising from the spinal elements and 25% of the patients in the series had lesions which encroached into the spinal canal. Patients with intra-canal lesions were typically asymptomatic and neurologically normal with plain radiographs that did not demonstrate the lesion. Only CT and MRI scans accurately identified the lesions.

Significance: The risk of a patient with MHE having a lesion within the spinal canal is much higher than previously suspected and since the potential exists for serious neurologic injury to occur, an accurate evaluation with MRI or CT should be provided to all patients.

Paper #36

Posterior Stabilization Following Oncologic Resection of the Cervicothoracic Junction: A Review of 90 Consecutive Cases

Peter S. Rose, MD (Memorial Sloan Kettering Cancer Center); Ilya Laufer, MD; Jasmine Beria, MPH; Andrew R. Hanover, BA; Mark Bilsky, MD; Patrick Boland, MD

Introduction: Limited data exist on reconstruction of the cervicothoracic junction following oncologic resection. Associated vertebral body destruction, chest wall resection, and radiation therapy complicate the treatment of these patients compared to traditional degenerative, traumatic, or deformity populations.

Methods: We reviewed 90 consecutive patients treated from 1996 to 2006 with tumor resection at the cervicothoracic junction and instrumented posterior reconstruction. All underwent laminectomy and facetectomy(ies); 49% underwent vertebral body resection, and 79% had adjuvant radiotherapy. Median survival was 12 months. Median follow-up of the surviving 24 patients is 37.5 months.

Results: Surgical techniques evolved during the study. Patients with C6 or C7 decompression were initially treated with lateral mass plate systems (LMP, n=7) and later with lateral mass screw/rod systems (LMSRS, n=8). Reconstruction of upper thoracic resections (T1-T3) evolved from sublaminar hook/rod systems (SHRS, n=48) to pedicle screw systems (PSS, n=27). Surgical complication rate was 19%; fixation failure occurred in 11 patients (12%) with 6 reoperations. Fixation failure rates for cervical decompressions decreased from 2/7 (29%) in the LMP group to 0/8 in the LMSRS group (p=0.2). Failure rates for upper thoracic decompressions decreased from 7/48 (15%) using SHRS to 2/27 (6%) in the PSS group (p=0.47). ASIA scores improved or remained stable in 88/90 patients. ECOG performance status was improved or stable in 85/90. Pain scores improved in 57 patients, were stable in 30, and worsened in 3. Median survival of patients with primary tumors (n=20) was significantly longer than for metastatic disease (n=70; 33 months vs 10 months, p=0.01).

Conclusion: Posterior instrumentation strategies can successfully reconstruct the cervicothoracic junction following tumor resection. Complications are common, however fixation failure is rare using current techniques of lateral mass or pedicle screw/rod systems.

Significance: This represents the largest reported series of cervicothoracic reconstructions, complications, and outcomes following oncologic resections. These results may guide surgeons in implant selection, expected patient survival, functional and oncologic outcome.

Paper #37

Long Term Clinical Outcomes Following Attempted en bloc Resections for Malignant Primary Sacral Tumors

Patrick C. Hsieh, MD (Johns Hopkins University School of Medicine); Risheng Xu, BS; Matthew McGirt, MD; Daniel M. Sciubba, MD; Clarke Nelson, BS; Jean-Paul Wolinsky, MD; Ziya L. Gokaslan, MD

Introduction: Chordomas and chondrosarcomas are two of the most common malignant primary tumors of the sacrum in adults. To date, only a few large clinical series with en bloc resection of these tumors exist. We present our experience of twenty patients with en bloc sacrectomy for chordomas and chondrosarcoma from 2002 to 2006.

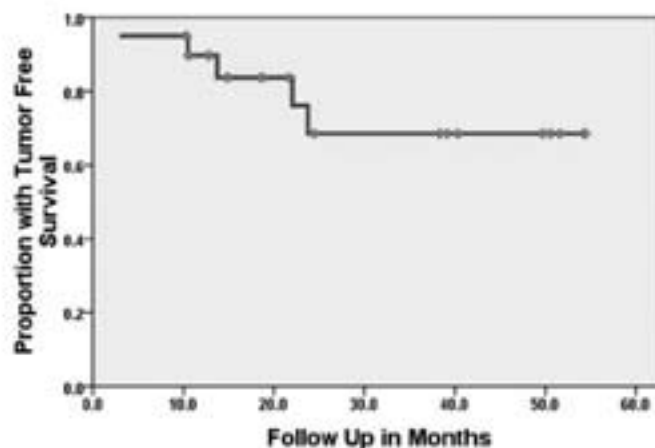
Methods: The medical records of twenty patients that underwent attempted en bloc sacrectomy for chordomas and chondrosarcomas were retrospectively reviewed. Surgical margin, peri-operative complications, and post-operative functional status were recorded. Tumor free survival and overall survival were analyzed using the Kaplan-Meier method.

Results: The study cohort included 8 males and 12 females, and the average age of diagnosis was 53.5 years. Mean follow-up for this group was 35.8 months. All patients underwent en bloc sacrectomy through posterior only approach. Wide or marginal en bloc resection was achieved in 14 patients (70%). In the other 6 patients (30%), tumor was identified at the surgical margins, and they were considered intralesional resections. 30-day peri-operative morbidity included one death from pulmonary embolism and nine wound complications. 40% of patients had normal bladder and bowel functions, while 60% of patients had partial or complete bladder or bowel dysfunction. Mean estimate Kaplan-Meier disease-free survival was 42.3 months, and mean estimated Kaplan-Meier overall survival was 55.5 months.

Conclusion: En bloc resections of sacral chordoma and chondrosarcoma result in improved disease-free survival with acceptable peri-operative morbidity.

Significance: Wide or marginal en bloc sacrectomy is the surgical technique of choice for the management of primary malignant sacral tumors.

Kaplan Meier Curve for Tumor Free Survival



* The FDA has not cleared a drug and/or medical device in use described in this presentation (i.e., the drug or medical device is being discussed in an off-label use). For full information see page 10.

Paper #38

Risk Factors for Vertebral Fracture Following Single Fraction Intensity Modulated Radiation Therapy for Spinal Metastases

Peter S. Rose, MD (Memorial Sloan Kettering Cancer Center); Ilya Laufer, MD; Andrew R. Hanover, BA; Eric Lis, MD; Yoshiya Yamada, MD; Mark Bilsky, MD; Patrick Boland, MD

Introduction: Single fraction intensity modulated radiation therapy (IMRT) is a new technique which allows for tumoricidal doses of radiation to be delivered to traditionally radio-resistant cancers while sparing critical adjacent structures. The risk of vertebral fracture following IMRT for spinal metastases has not been defined.

Methods: All patients undergoing single fraction IMRT for metastatic spinal lesions were reviewed. Treatment dose ranged from 1800-2500 cGy (mean 2300).

Results: Sixty-two patients underwent treatment at 71 sites. Twenty-eight died of disease at mean 10 months post-treatment; 34 were alive with mean 21 month follow-up. Twenty patients had baseline endplate or mild compression fractures. Following treatment, 27 patients (39%) had new or progressive fractures. Lytic metastases ($p=0.04$), thoracolumbar or lumbar location ($p=0.04$), and percent vertebral body involvement ($p=0.02$) correlated with increased fracture risk. Obesity, posterior element involvement, and local kyphosis did not confer increased risk. Pretreatment endplate fracture or mild compression did not correlate with new fracture development or progression. Fracture progression led to surgery ($n=2$), kyphoplasty ($n=1$), or significant pain ($n=9$) in 12 patients. Although difficult to ascertain with certainty, the majority of fractures did not appear to result from disease progression.

Conclusion: Vertebral fracture is common following single fraction IMRT for metastatic lesions of the spine. Patients with lytic disease involving more than 40% of their vertebral bodies are at high risk for fracture, particularly for lesions located in the thoracolumbar or lumbar spine.

Significance: This is the first study to report the risk of fracture following single fraction IMRT for spinal metastases. These risk factors may be used to select patients for prophylactic vertebro- or kyphoplasty.



Paper #39

5-Year Radiographic Results of Long Scoliosis Fusion in Juvenile Spinal Muscular Atrophy Patients: Crankshaft and Ultimate Correction

Lukas P. Zebala, MD (Washington University in St. Louis); Keith H. Bridwell, MD; Christine Baldus, RN, MHS; B. Stephens Richards, III, MD; John P. Dormans, MD; Lawrence G. Lenke, MD; Joshua D. Auerbach, MD

Introduction: Scoliosis in SMA occurs at a young age and is often progressive, requiring surgery before age 10. The study purpose was to assess radiographic outcomes and CS in SMA patients with minimum 5-year follow-up at 3 institutions.

Methods: 22 patients (10 F:12 M) were available for analysis. Average age at surgery was 8.4 years (range 6-11 years). TRC was open on all patients preoperatively. Average follow-up was 7.8 years (range 5-13 years). Coronal Cobb angle, apical vertebral translation (AVT), pelvic obliquity, coronal balance and sagittal Cobb angles (T5-T12 and T12-sacrum) were analyzed preoperatively and at initial and final follow-up. CS was defined as an increase in coronal Cobb angle of 10° or more between initial and final follow-up.

Results: SMA patients as a whole had significant improvement in all radiographic parameters from preop to initial and final follow-up (see figure). 8 patients (36%) developed CS. CS group was younger (7.8 vs. 8.8 years; $p=0.09$) and had smaller preop coronal Cobb angle (63 vs. 84°; $p=0.03$) and AVT (42 vs. 73mm, $p=0.03$) than non-CS group. At initial follow-up, CS patients had greater correction in coronal Cobb (69% vs. 57%; $p=0.01$) and AVT (71% vs. 55%; $p=0.03$) measurements than non-CS patients, but the groups were similar at final follow-up. Ultimate correction for both groups remained improved over preop deformity (see figure). 6 of the 22 patients underwent ASF/PSF. These children had greater preop coronal Cobb angles (99 vs. 68°; $p=0.002$), coronal imbalance (214 vs. 106mm; $p=0.001$) and pelvic obliquity (39 vs. 18°; $p=0.002$) than PSF-only patients, but there were no differences between groups at initial or final follow-up. Two ASF/PSF patients developed CS and were similar to the 4 PSF-only CS and 4 ASF/PSF non-CS patients at all time points. TRC remained open in 2 CS patients at final follow-up.

Conclusion: SMA patients maintained coronal and sagittal deformity correction with long spinal fusion at 5-year follow-up. CS developed in only 36%; both CS and non-CS patients had similar ultimate correction. ASF may not prevent CS as 25% of CS patients had ASF/PSF surgery.

Significance: ASF did not prevent CS in all patients. Younger age and greater correction may increase CS risk; curve size did not.

(See table next page)



	Coronal Cobb Angle (degrees)	p value for change from preop to:		AWT (mm)	p value for change from preop to:	Pelvic Obliquity (degrees)	p value for change from preop to:	Coronal Balance (mm)		p value for change from preop to:	Sagittal T5-T12 (degrees)		p value for change from preop to:	Sagittal T12-Sacrum (degrees)		p value for change from preop to:
		Preop	Final F/U					Initial F/U	Final F/U		Preop	Final F/U		Preop	Final F/U	
All Patients (n=22)	76.5+/-21.6	<0.0001	62+/-33.9	<0.0001	23.7+/-12.0	<0.0001	135.8+/-67.1	41.9+/-16.6	-18.0+/-40.3							
	29.8+/-15.7	<0.0001	25.6+/-22.8	<0.0001	10.0+/-5.7	<0.0001	73.7+/-45.4	30.3+/-14.9	-41.0+/-20.4	0.02						0.03
	39.3+/-15.9	<0.0001	36.2+/-32.3	0.01	10.8+/-7.7	<0.0001	91.6+/-54.9	29.4+/-18.5	-35.0+/-28.8	0.02						0.12
All CS Patients (n=8)	63.3+/-22.3	<0.0001	42.1+/-21.2		22.4+/-14.5		116.6+/-77.0	44.9+/-16.0	-19.4+/-51.5							
	19.3+/-7.8	<0.0001	12.1+/-9.8	0.005	10.6+/-5.8	0.06	54.4+/-45.3	29.3+/-16.2	-44.4+/-20.4	0.07						0.26
	44.9+/-15.1	0.08	33.1+/-22.8	0.45	15.1+/-10.5	0.27	96.8+/-64.7	28.3+/-22.6	-28.6+/-41.9	0.59						0.72
All Non-CS Patients (n=14)	84.0+/-17.9	<0.0001	73.3+/-35.1		24.4+/-10.8		147.2+/-61.1	40.4+/-17.3	-17.2+/-35.7							
	35.8+/-16.1	<0.0001	33.3+/-24.7	0.002	9.6+/-5.9	<0.0001	84.7+/-43.2	30.8+/-14.9	-39.2+/-20.9	0.005						0.06
	38.4+/-15.0	<0.0001	37.6+/-37.9	0.02	8.4+/-4.2	<0.0001	88.6+/-50.9	29.9+/-17.0	-38.1+/-20.8	0.01						0.07

* The FDA has not cleared a drug and/or medical device in use described in this presentation (i.e., the drug or medical device is being discussed in an off-label use). For full information see page 10.



Paper #40

Spinal Fusion for Spastic Neuromuscular Scoliosis (NMS): Is Anterior Releasing Necessary When Intraoperative Halo-Femoral Traction is Used?

Kathryn A. Keeley, MD; Scott J. Luhmann, MD (Washington University School of Medicine); Lawrence G. Lenke, MD; Christopher R. Good, MD; Brenda A. Sides, MA; Mario Schootman, PhD; Keith H. Bridwell, MD

Introduction: Combined anterior-posterior fusion (A/PSF) has been used to improve correction and fusion rate in patients (pts) with neuromuscular scoliosis (NMS), but is associated with increased morbidity. Posterior-only spinal fusion (PSF-only) may be sufficient, thereby forgoing the need for the anterior approach without sacrificing deformity correction or outcome.

Methods: 26 pts (age<21 y.o) who underwent PSF for spastic NMS (quadriplegic cerebral palsy) were matched with 26 pts who underwent A/PSF (11 staged, 15 same day). All posterior fusions extended from the proximal thoracic spine (T2/T3) to the pelvis. Anterior fusions used a thoracoabdominal approach. All 52 pts underwent intraop halo-femoral traction.

Results: There were no significant demographic or radiographic differences between the 2 groups. Average OR time in the PSF-only vs A/PSF groups was 6.3 hrs vs 10.9 hrs. Average EBL in the PSF-only vs A/PSF groups was 900mL vs 1430mL. In the PSF-only group, 16 pts (62%) were extubated immediately postop, 10 pts (38%) were intubated a mean of 2 days. In the A/PSF group 5 pts (19%) were extubated immediately postop, 21 pts (81%) were intubated a mean of 6.5 days. 2 pts in the PSF-only group and 8 pts in the A/PSF group developed pneumonia postop. Mean correction of TL/L curve and pelvic obliquity was similar (Table). Improvements in C7-CSLV, sagittal T5-T12 and T12-S1 were also similar. There were minimal changes in all radiographic parameters between immediate postop and 2-year F/U. 2 pts in the A/PSF group required partial removal of implants for skin breakdown. There were no implant related complications in the PSF-only group.

Conclusion: Using intraop halo-femoral traction with PSF-only surgery for NMS can provide excellent curve correction and coronal/sagittal balance. The PSF-only group had shorter OR time, less EBL, reduced intubation and fewer cases of postop pneumonia compared to A/PSF with similar radiographic outcomes immediately postop and at 2-year F/U.

Significance: When using intraoperative halo-femoral traction, PSF-only for NMS avoids the morbidity of entering the thoracoabdominal cavity while providing similar correction to circumferential surgery.

Paper #41

30 Years of Experience with Infections in Pediatric Neuromuscular Spinal Deformity Surgery

Patrick J. Cahill, MD (Shriners' Hospital for Children); Drew E. Warnick, MD; Michael J. Lee, MD; Lawrence C. Vogel, MD; Kim W. Hammerberg, MD; Peter F. Sturm, MD

Introduction: We report on 30 years of experience and over 300 pediatric patients who underwent instrumented spinal fusion for scoliosis related to an underlying neuromuscular condition. The objective is to determine risk factors for infection, infection rates in specific neuromuscular entities, and elucidate the treatment strategies for successful eradication of infection.

Methods: A retrospective review was performed of the medical records and radiographs of all children with neuromuscular conditions undergoing surgery for spinal deformity at a pediatric orthopedic hospital from January 1st, 1975 to January 1st, 2005.

Results: 305 patients underwent spinal surgery for deformity related to a neuromuscular condition. 43 of these patients developed a post-operative infection requiring surgical treatment. The rate of infection in neuromuscular scoliosis is 14.1%. The patients with infections had an average of 2.5 surgeries before developing an infection. Our patients had a wide variety of diagnoses including cerebral palsy, myelomeningocele, Duchenne's muscular dystrophy, and centronuclear myopathy. We have further stratified the rates of infection by diagnosis. The rate of infection in myelomeningocele is 19.2% (16/83). In the myopathies, the infection rate is 4.3% (2/46). The rate of infection in cerebral palsy is 11.2% (12/107). An average of 2.1 surgeries was required to clear the infections. 26 (60%) of the patients who developed an infection required complete removal of their implants. The average time from the index procedure to the first irrigation and debridement was 382 days. There were on average 1.9 infecting organisms.

Conclusion: The rate of infection in neuromuscular spinal deformity is largely related to the underlying diagnosis. Once an infection develops multiple surgeries are usually required and the majority of patients will require removal of their implants to treat the infection.

Significance: We have presented a large series of pediatric patients with spinal deformity related to an underlying neuromuscular condition. Physicians can use the data to counsel patients and their families on the risk of developing a post-operative infection and the expected course should an infection occur.

Diagnosis	Number of Patients	Number of Infections	Rate
Cerebral Palsy	107	12	11.2
myelomeningocele	83	16	19.2
myopathies	46	2	4.3
SCI	20	6	30
polio	5	4	80
others	34	3	8.8



Paper #42

Progression of Scoliosis in Non-Ambulatory Duchenne Muscular Dystrophy Patients

Frederic Shapiro, MD (Children's Hospital Boston); David Zurakowski, PhD; Basil T. Darras, MD

Introduction: We determined progression of scoliosis in Duchenne muscular dystrophy (DMD) patients not treated with steroids from time of full wheelchair dependency until spinal fusion surgery or latest assessment if surgery not done.

Methods: Scoliosis was documented from sitting full spine antero-posterior radiographs without brace support. Longitudinal mixed-model analysis with repeated measures was performed using data from 80 patients to determine relationship between time in wheelchair and degree of thoraco-lumbar scoliosis. Regression coefficients with 95% confidence intervals (CI) were used to derive trajectories for predicting thoraco-lumbar curves. We determined developmental patterns (time in wheelchair related to degree of scoliosis) in 47 patients with at least 3 radiographs.

Results: Mean age at full-time wheelchair use was 10.6 years (SD 1.9, r=6.7-14.7 years). Median time in chair was 36 months (interquartile range 20-56 months). Mixed model regression analysis indicated a highly significant effect of time in wheelchair and predicted size of the curve ($t=17.88$, $p<0.0001$). Projected scoliosis curve magnitude (95% CI) based on time in wheelchair was: 3 months-3 degrees (2-4); 6 months-5 degrees (0-12); 12 months-12 degrees (6-18); 24 months-25 degrees (18-31); 36 months-38 degrees (32-43); 48 months-50 degrees (44-56); 60 months-65 degrees (58-70); 72 months-78 degrees (70-86); 84 months-90 degrees (82-98); and 96 months-105 degrees (95-115). Three patterns were noted: I: no scoliosis for 2-3 years followed by a steady increase in deformity (19 patients); II: steady increase in deformity from time of wheelchair dependency (20 patients); and III: rapid increase of deformity over a period of a few months in types I/II (collapsing curve) (8 patients). Only 2 of 80 patients (2.6%) had no scoliosis. Deformity of 10 degrees+ developed in 95% and 20 degrees+ in 87%.

Conclusion: Patients with longer wheelchair time have larger curves. Our statistical model accounts for the different number of time points for assessing curve magnitude between patients. Three developmental patterns were seen. This information aids in timing spinal fusion and serves as a baseline to compare development of scoliosis in DMD patients with medical treatment regimens.

Paper #43

Spinal Deformity Correction in Duchenne Muscular Dystrophy: Sublaminar Wiring Fixation versus Pedicle Screw Instrumentation

Ujjwal K. Debnath, FRCS (Nottingham University Hospital); Hossein Mehdian, FRCS, MD; Harshad Dabke, FRCS; A.S. Hoakazemi; Nanjundappa S. Harshavardhana, MS(Orth), Dip. SICOT; Brian J. Freeman, MD; John K. Webb, MBBS, FRCS

Introduction: Historically segmental sublaminar wiring (SLW) fixation has been used for the correction of spinal deformity in neuromuscular scoliosis, however pedicle screw (PS) fixation is gaining popularity.

Methods: Two groups of patients with DMD were matched according to the age at surgery, magnitude of deformity and vital capacity. Indications for surgery included loss of sitting balance, rapid decline of vital capacity and curve progression. In Group 1 (22 patients) SLW fixation was used from T2 to S1 with the Galveston technique. In Group 2 (18 patients) PS fixation was used from T2 to L5. Minimum follow-up was 2 years (range 2-13 years). Radiographs, SRS- 22 and lung function tests were performed at standardised intervals.

Results: Mean Cobb angle in Group 1 improved from 47deg (range 26 -75deg) to 23.5deg (range 10 -36deg) and mean pelvic obliquity improved from 15deg (range 8 -25deg) to 2.4deg (range 0 -8deg). Mean Cobb angle in Group 2 improved from 46deg (range 28-82deg) to 8.5deg (range 0-18deg) and mean pelvic obliquity improved from 15deg (range 7 -30deg) to 1.1deg (range 0 -6deg) [$p<0.05$]. Mean operating time and blood loss were less in Group 2 [$p<0.05$]. In Group 1, the infection rate and instrumentation failure was higher, and SRS-22 outcomes showed no significant difference between the groups. Interestingly the mean Body Mass Index (BMI) in Group 2 was much higher than group 1.

Conclusion: PS fixation resulted in superior correction and controlled pelvic obliquity to a large extent without the need for pelvic fixation. Lower rates of infection and failure of instrumentation were noted with PS fixation, despite high BMI of patients presumably due to steroid therapy.

Significance: We recommend the use of Pedicle Screw instrumentation for the correction of spinal deformity in DMD.



Paper #44

Spondylolysis Repair with Rigid Fixation: A Prospective Clinical and Radiographic Outcome Study

Matthew D. Hepler, MD (Northwestern University); Matthew Walker, MD; Eugene P. Lautenschlager, PhD

Introduction: Spondylolysis is a common source of back pain and chronic defects can produce continued pain and disability, alter spinal biomechanics, and increase stress to the adjacent disc. Surgical treatment has had variable results and there are no prospective studies evaluating the clinical and radiologic outcome of patients treated with fracture debridement, impaction grafting, and rigid fixation with a pedicle screw-sublaminar hook (claw) construct.

Methods: A prospective cohort study evaluating spondylolysis repair with debridement, impaction bone grafting, and pedicle screw-sublaminar hook fixation. Inclusion criteria included back pain, spondylolysis on CT/MRI, diagnostic injection (if concomitant pathology), and failure to improve with non-operative treatment including bracing. Eleven patients (12 lesions) were evaluated preoperatively and at 3, 6, 12, and 24 months postoperatively with SF-36, ODI, Roland-Morris, and VAS (repeated measures ANOVA and Tukey post hoc testing). Radiologic evaluation included flex/ext xrays and CT scan for those returning to contact sports.

Results: All patients returned to full activities including contact sports within 6 months of surgery. Statistically significant improvement ($p < .05$) was seen in each outcome instrument at 6, 12 and 24 month follow-up. Flexion-extension x-rays and CT demonstrated fracture repair in all cases. There were no infections and no revision surgeries. One patient developed discogenic back pain 18 months postoperatively.

Conclusion: Spondylolysis repair with impaction grafting and rigid fixation has excellent clinical and radiologic outcome at 6 months and results are maintained at 2 year follow-up. All outcome measures improved and imaging studies demonstrate fracture repair. Symptomatic lesions (confirmed by injection) did well in the presence of other pathology demonstrating primary significance of this lesion.

Significance: Spondylolysis repair is a high benefit/risk ratio procedure that reliably corrects the lytic defect while restoring physiologic motion and lumbar biomechanics and should be strongly considered in patients who fail to heal non operatively. Patients can return to activities including contact sports at 6 months if CT confirms adequate healing. Properly selected patients can be successfully treated in the presence of other pathology.

Paper #45

Dynamic Stabilization and Laminectomy in Degenerative Lumbar Scoliosis of Elderly Patients

Mario Di Silvestre, MD (Istituto Ortopedico Rizzolo); Georgios Bakaloudis, MD; Francesco Lolli, MD; Patrizio Parisini, MD

Introduction: In elderly patients with degenerative lumbar scoliosis posterior instrumented fusion can cause some undesirable effects, such as pedicle screw loosening and adjacent segment degeneration. The use of dynamic stabilization (Dynesys) without fusion has been advocated to reduce such adverse effects. No study in literature analyzed outcomes of dynamic stabilization in degenerative lumbar scoliosis.

Methods: A total of 26 consecutive patients (17 females, 9 males) with a mean age of 65.3 years (range, 61 to 78) undergoing, between 2002 and 2004 at our Department, dynamic stabilization and laminectomy for a degenerative lumbar scoliosis were included in the study. 7 cases presented additional mild degenerative spondylolisthesis. No patient had a previous surgery. All patients complained of back pain and leg pain while walking. 20 patients had diffuse paresthesia at one or both legs, additionally.

Results: At an average follow-up of 3.7 years (range, 3.1 to 4.1) all cases were reviewed. The average scoliosis Cobb angle before surgery was 20.1° (range, 12°-35°); this was corrected to 8.5° (range, 5°-10°) at the last visit. The average number of levels instrumented was 4.8 (range, 5 to 7) and laminectomy was extended for 4.3 levels on average (range, 4 to 7). The mean preoperative VAS was 6.1 for low back pain and 6.7 for back pain and decreased to 3.5 and 3.9 respectively at follow-up. There was a significant increase at last visit of preoperative SF-36 scores of 7 items together (PF,RP,BP,MH,SF,V,GH): it was from 35 to 58 (65%). There was also a significant increase in the ODI from 48.4 to 24.9, which represents an improvement of 83%. There were no neurological complications. Asymptomatic radiolucent lines up to 2 mm around the thread of pedicle screws in L5 and S1 were shown in 4 cases (15%), no instrumentation failure was observed in any patient. One patient (3.8%) required revision surgery for extension of the dynamic fixation for junctional degeneration.

Conclusion: In degenerative lumbar scoliosis, dynamic stabilization in addition to decompressive laminectomy is a safe procedure. This no-fusion stabilization procedure appears to be less aggressive and more physiological than instrumented fusion, being less invasive with shorter operation time.



Paper #46

TLIF vs ALIF as an Adjunct to Posterior Instrumented Correction of Degenerative Lumbar Scoliosis: 3-Year Clinical and Radiographic Outcomes

Dennis Crandall, MD (Sonoran Spine Center); Jan Revella, RN

Introduction: Is anterior-posterior fusion required for optimal outcomes in Degenerative Lumbar Scoliosis (DLS)? We studied DLS pts surgically treated to determine the need for anterior surgery.

Methods: 42 consecutive pts with DLS age 68yrs underwent posterior instrumented reduction/fusion by 1 surgeon. TLIF in 21 pts avg 2.7 levels (1-4 levels), and ALIF in 21 avg 4.2 levels (3-6 levels). 2 ALIF pts required osteotomy. BMP-2 was used at 2-8mg/disk for ea interbody fusion. Posterior constructs avg 6.8 levels (4-9 levels) for both groups. Oswestry (ODI), visual analog pain scores (VAS), pain medication use, and radiographs measuring curves, lumbar lordosis, thoracic kyphosis, spinal balance, pelvic incidence were followed avg 38mo (24-68mo).

Results: ALIF group complications: 3 nonunions, 3 adjacent fx, 3 revisions for adjacent degeneration, 3 infections, 1 footdrop, 1 pulmonary embolus, 1 ileus requiring colostomy, and 1 stroke. TLIF group had 1 infection, nonunion, transient footdrop, and additional surgery for coronal balance. VAS were similar: TLIF 6.8 pre-op (3-10) improved to 2.9 (1-8), and ALIF 6.4 pre-op (0-10) improved to 2.2 (1-7). Pain medication usage was similar. ODI was similar: TLIF 46 (18-62) pre-op improved to 23.8 (0-58), ALIF 50.9 (28-82) improved to 31.0 (0-70). More A/P pts had severe (>10cm) sagittal imbalance (6pts vs 2pts) and less lordosis (24 vs 45°) preop requiring correction. Curve correction was similar: ALIF group 34° (13-49°) pre-op correcting 70% to 10° (0-18°); TLIF group 27° (14-64°) pre-op corrected 70% to 8° (0-15°). More lordosis was obtained with A/P surgery.

Conclusion: With current correction techniques/TLIF/BMP, similar outcomes can be achieved with posterior-only vs. A/P surgery for most pts. However, complications with posterior-only surgery are significantly fewer.

Significance: These findings suggest anterior surgery is only indicated for significant spinal imbalance in DLS.

Paper #47

Use of Vertebroplasty to Prevent Proximal Junctional Kyphosis in Adult Spinal Deformity Surgery: A Biomechanical Cadaveric Study.

Ivan E. LaMotta, MD (Johns Hopkins School of Medicine); Gabor Voros, MD; Joseph R. O'Brien, MD; Stephen Belkoff, MD; Khaled Kebaish, MD

Introduction: PJK has been reported to occur in up to 26% of patients following long posterior spinal arthodesis. The consequences of PJK can include sagittal decompensation, neurologic impairment and severe pain. A prior clinical study that we recently presented compared proximal stopping points and prophylactic vertebroplasty on incidence of PJK. In this study, the biomechanical effect of prophylactic vertebroplasty on the proximal instrumented level (PIL) or the PIL with the supra-adjacent vertebra (PIL+1) was examined.

Methods: Eighteen fresh frozen human cadaveric spines were used. All specimens underwent dual energy x-ray absorptiometry scanning and were grouped according to bone mineral density. Specimens were assigned to three groups according to proximal treatment: 1) no vertebroplasty, 2) T10 vertebroplasty (PIL) and 3) T10 and T9 vertebroplasty (PIL+1). The specimens were then instrumented with bilateral pedicle screws from T10 to L5 and augmented with PMMA according to the group. Vertebroplasty with PMMA was performed using a bipedicular technique at the assigned levels, 2 cc of PMMA was used in each pedicle. Spines were potted and mounted to a materials testing machine. Axial compression was applied eccentrically (10 mm anterior offset) at 5mm/min for 50 mm. Peak loads and failure levels were recorded. Visual inspection, fluoroscopy, and CT scan were used to confirm the fracture levels.

Results: Data are presented in Table 1. There was no statistically significant difference in the peak load to failure across groups. Specimens without vertebroplasty were more likely to have fracture at T9 compared to specimens with T9 and T10 vertebroplasty (PIL+1; p=0.003). Additionally, T9 & T10 vertebroplasty specimens (PIL+1) were less likely to have a junctional fracture compared to specimens with T10 vertebroplasty (PIL) or no vertebroplasty (p=0.005).

Conclusion: The use of vertebroplasty at T9 and T10 (PIL +1) for T10 to L5 constructs in cadaveric spines, reduces the likelihood of PJK due to vertebral fractures.

Significance: Prophylactic vertebroplasty at the proximal fusion vertebra and the adjacent level may decrease the incidence of PJK by reducing the incidence of vertebral compression fractures in long posterior spinal arthrodesis.

Table 1: Summary of Experimental Data.

Group 3 was significantly less likely to have vertebral fracture compared to groups 1 and 2 (p=0.005).

Group	Peak Load to Failure	Number of Fractures
1. No Vertebroplasty	2191 N/mm	Five [T9(3), T10(2)]
2. Vertebroplasty T10 (PIL)	3377 N/mm	Six [T9 (6)]
3. Vertebroplasty T9 and T10 (PIL +1)	2550 N/mm	One [T8 (1)]



Paper #48

Preoperative Inferior Vena Cava Filters for Major Spinal Reconstruction in Adults

Timothy R. Kuklo, MD, JD (Washington University School of Medicine); Michael Rosner, MD; Stephen L. Ondra, MD; Brian A. O'Shaughnessy, MD; Jamal McClendon, MD

Introduction: Pulmonary embolism (PE) can be a major cause of morbidity and mortality after major spinal reconstruction in adult pts, and is reported in up to 6% of pts. Consequently, preop placement of prophylactic inferior vena cava (IVC) filter was instituted as standard protocol after conducting a pilot study showing efficacy. The purpose of this study is to evaluate this protocol in high-risk adult pts undergoing major spinal reconstruction.

Methods: We reviewed the medical records of all pts receiving a preop IVC filter at 3 institutions from 2002-2007. In addition to standard demographics, evaluation included surgical approach/extent, presence of postop lower extremity deep venous thrombosis (LE DVT) and/or PE, and complications from placement and failure to remove if retrievable. General indications included contradiction to anti-coagulation therapy, history of DVT or PE, major debilitation with expected prolonged postop immobilization/hospitalization or malignancy. Optional indications included age over 60 with planned surgery of over 6 hrs, obesity and anterior (combined) approach.

Results: 178 pts (114F, 64M; ave 62.1 yrs, range 32-82) were included in the study (142 posterior only, 36 anterior-posterior approach). There were no complications from filter placement (84 Greenfield, 94 retrievable). LE DVT was noted in 36 pts (20.2%) and PE in 2 pts (1.1%; both with no documented LE DVT). As well 90/94 (96%) retrievable filters were removed within 30 days. Most notably, an anterior approach (combined) was associated with DVT (14/36;39%) vs posterior only (22/142;15%). (p=0.02) No association was noted with age, obesity or levels fused. There were 3 deaths within 1 year postop-none related to a LE DVT/PE.

Conclusion: The LE DVT rate (20.2%) appears to be higher than previously recognized. In addition, prophylactic IVC filter placement appears to be safe (no insertion complications), and effective (PE rate 1.1%, no related deaths). Most notably, the anterior (combined) surgical approach appears to have a higher rate of DVT (39%, p=0.02), and may be the best group to consider this prophylactic treatment. There is some concern that doppler ultrasound may not detect LE DVT.

Paper #49

CT and Biomechanical Evaluation of Screw Fixation Options at the Cervicothoracic Junction: Intralaminar vs. Intrapedicuar Techniques

Mario J. Cardoso, MD, DC (Walter Reed Army Medical Center); Anton E. Dmitriev, MSc; Ronald A. Lehman, Jr., MD; Melvin D. Helgeson, MD; Patrick B. Cooper, MD; Michael Rosner, MD

Introduction: Proximal thoracic fixation in cervicothoracic fusions is placed in a challenging biomechanical environment. Transpedicular instrumentation is well accepted, but salvage techniques in this region are limited. Recently, the intralaminar technique for fixation into this region has gained in popularity. The purpose of our study was to define T1 and T2 anatomic laminar size, and evaluate the bone-screw interface strength of various pedicle screw options and intralaminar techniques.

Methods: Fourteen (14) cervicothoracic cadaveric specimens were DEXA scanned for bone mineral density (BMD) and CT scans obtained for anatomic characterization. On the right side, pedicle screws were first placed in a straight forward trajectory, with insertional torque (IT) recorded with each revolution. Screws were then pulled out in-line with the screw axis to simulate intraoperative failure of fixation. “Salvage” anatomic trajectory pedicle screws were then inserted into the same pedicle, with IT and pull-out strength (POS) measured in a similar fashion. Finally, all specimens were “salvaged” with intralaminar screws placed into the contralateral laminae from the right spinous process/lamina junction (Fig 1.). All screws were placed by a fellowship trained spine surgeon under direct fluoroscopic visualization. Standard 4.5 mm cervical pedicle screws were utilized as they are the maximum diameter available in a cervical set for cervicothoracic reconstructions. Insertional torque (IT) was measured in “lbs-in”. Tensile loading to failure was performed at a rate of 0.25mm/sec using a MTS 858 MiniBionix II System. Data was normalized to peak failure load of the index straight forward trajectory and recorded as percent change. Statistical significance was set at alpha < 0.05.

Results: Laminar screws as a salvage technique generated statistically greater peak IT (p<0.001) and relative POS (p=0.032) compared to straight forward transpedicular screws as the initial fixation type (Table 1.). Furthermore, laminar screws, when compared to the salvage anatomic trajectory pedicle screws, had a significantly greater peak IT (p=0.007). The peak IT showed a stronger correlation with POS in laminar screws (r=0.744) than straight forward (r=0.548) or anatomic (r=0.471) pedicle screws. A similar trend was noted in mean IT (r=0.786, r=0.568, r=0.521, respectively). BMD correlated with POS in all methods of fixation: straight forward pedicle, anatomic pedicle, and laminar screws (r=0.765, r=0.719, and r=0.632, respectively). The mean laminar width measured on CT at the thinnest point was 5.9 ± 0.7 mm (Range 4.8-7.5).

Conclusion: Our results suggest that laminar screws, used as a salvage technique in the proximal thoracic spine, provide stronger fixation than transpedicular screws when using standard 4.5mm cervical screws. Intralaminar screws present as a biomechanically sound salvage technique in this region, and appear to be a safe, effective option for instrumenting the proximal thoracic spine.

	Straight Forward Trajectory	Anatomic Trajectory	Laminar Screw
Mean IT (lbs-in)	2.20 ± 0.53	2.76±0.78	3.86±1.65
Mean POS (% change)	100± 0.00	108.9± 20.3	115.8±37.6



Paper #50

Shilla Growth Enhancing System for the Treatment of Scoliosis in Children: Greater than Two Year Follow Up

Richard E. McCarthy, MD (Arkansas Spine Center); Frances L. McCullough, MNSc; Scott J. Luhmann, MD; Lawrence G. Lenke, MD

Introduction: The Shilla growth enhancing system has been developed to treat spinal deformities without repeated operative lengthenings. The dual stainless steel rods are fixed to the corrected apex of the curve via pedicle screws and limited fusion. Vertebral growth occurs in a cephalad and caudad direction via extraperiosteally placed sliding pedicle screws. We are reporting on the first 10 patients with 2 years' follow-up after undergoing this procedure.

Methods: Ten patients with a mean age of 7+6 yrs. (2-10) with progressive scoliosis (average 70.5 degrees) underwent the Shilla procedure. Diagnoses were: infantile idiopathic scoliosis (2), juvenile idiopathic scoliosis (1), congenital scoliosis (1), Prader-Willi syndrome (1), neuromuscular scoliosis (2), myelomeningocele (1), intraspinal lesion (1), and Beale's syndrome (1). Spinal cord monitoring was accomplished where appropriate.

Results: Initial curve correction went from 70.5 degrees (40-86) to an average of 27 degrees (7-52) at 6 wk. follow-up and maintained at 34 degrees (18-57) at 2 yr. follow-up. The space available for lung (SAL) improved an average of 13%. Truncal height increased an average of 12%. Two patients had a staged anterior apical release prior to the posterior procedure. One patient required rod revision due to growth off the end of the rods, 1 patient required rod change to a smaller size rod due to prominence, 1 patient required rod replacement due to a broken rod, 2 patients required wound debridement for low-grade infection for a total of 5 procedures beyond initial correction. No patient had significant changes in spinal cord monitoring or changes neurologically postoperatively. Patients were braced for 3 mos. postop but not beyond.

Conclusion: At two yrs. follow-up, the Shilla procedure has allowed children correction of their spinal deformity and to grow brace free without repeated trips to the operating room for lengthenings. Curve correction has been maintained and the complication rate has been acceptable. These patients would have had 49 lengthening procedures after their initial correction if treated by conventional growing rod methods. We feel the Shilla procedure is applicable in many cases of childhood spinal deformity and can be performed safely.

Paper #51

Treatment of Spinal Deformities in Patients with Diastrophic Dysplasia (DD) - A Long-Term, Retrospective, Nationwide Study

Tuomas Jalanko, MS; Ville Remes, MD, PhD; Jari Peltonen, MD; Asst. Prof. Mikko S. Poussa; Ilkka Helenius, MD (Helsinki University Central Hospital)

Introduction: Diastrophic dysplasia (DD) is a rare skeletal dysplasia with short-limbs, joint contractures, cervical kyphosis and severe rigid spinal deformities. No data exist on brace treatment of spinal deformities in these patients.

Methods: All patients undergoing either brace or surgical treatment of spinal deformity with a minimum of 2 yrs follow-up were identified in our country. 8 patients had undergone brace treatment (Boston 7 pts; Milwaukee 1) and 12 had been treated operatively (altogether 17 pts). 2 patients had early progressive type and the rest idiopathic-like scoliosis. 5 patients underwent posterior only, 1 anterior only, and 6 anteroposterior surgery. Mean age at brace treatment was 6.9 (range 0.9-12.7) years and at surgery 13.4 (6.5-20.1) years. Follow-up time averaged 16.5 (6.6-44.3) years for brace and 14.0 (2.1-37.2) for the surgical treatment groups. Upright AP and lateral radiographs were obtained preop, postop, at two years, and at final follow-up visit. Scoliosis Research Society (SRS-24) questionnaire was fulfilled at the last follow-up visit. The radiographic follow-up rate was 100%.

Results: Both thoracic and lumbar curves progressed during brace treatment (major curve progression 82%, 25%-143%). 3 of 8 patients with brace treatment progressed to surgery and 1 is on waitinglist. Before surgery, mean thoracic Cobb angle was 70 (42-100) deg and 42 (25-68) deg in the lumbar spine. At final follow-up visit, mean correction was 23 (-6-76)% for thoracic and 26 (-68-93)% for lumbar curve. The correction of major curve was significantly higher in patients undergoing anteroposterior vs. posterior surgery (38% vs 13%, $p=0.044$). 5 (42%) operated patients had complications (one paraplegia, two proximal junctional kyphosis, one deep infection, re-instrumentations on subcutaneous rod). The SRS-24 yielded 90 (79-103) points for brace treatment and 90 (68-114) for surgical group.

Conclusion: Brace treatment has little role in the treatment of spinal deformity in patients with diastrophic dysplasia. Spinal deformities are very rigid. Early anteroposterior surgery is the preferred method.

Significance: This long-term follow-up study suggests that anteroposterior surgery is the only effective and safe treatment in patients with Diastrophic Dysplasia.



Paper #52

Scoliosis and the Effects of Growth Hormone Treatment in Children With Prader-Willi Syndrome

Roderick de Lind van Wijngaarden, MSc (Dutch Growth Research Foundation); Luuk W. de Klerk, MD, PhD; Dederieke A. Festen, MD, PhD; Barto J. Otten, MD, PhD; Anita C. Hokken-Koelega, MD, PhD

Introduction: The prevalence of scoliosis and the effects of GH treatment on scoliosis in PWS was unknown. Scoliosis in PWS children is often regarded as a contraindication for GH treatment.

Methods: A prospective, multi-center, randomized, controlled GH study. Children were divided into 3 groups: infants (6 mos - 3.5 yrs), prepubertal children (girls 3.5-12, boys 3.5-14 yrs) and pubertal children (12/14-16 yrs). Infants followed a one year and prepubertal children a two year controlled study design. Treatment consisted of somatropin 1.0 mg/m² × day. Pubertal children were treated with somatropin 1.0 or 1.5 mg/m² × day. Yearly, height and weight were measured, X-rays and blood samples were taken and a DXA scan was performed to measure the lean body mass of the trunk (trunkLBM). A low ratio of trunkLBM versus body surface area (trunkLBM:BSA) was used as a proxy for hypotonia of the trunk.

Results: 104 children were included, with a mean (SD) age of 5.4 (3.9) yrs. The prevalence of scoliosis was high and increased with age (~30% infantile and juvenile, 80% adolescent scoliosis). The prevalence of moderate or severe scoliosis was alarmingly high (44% of scoliosis >20°, 13% treated). Two types of scoliosis were identified: *Long C-curve type* (LCS) and *scoliosis resembling idiopathic scoliosis* (IS). Children with LCS were younger and had lower trunkLBM:BSA than those with IS. GH increased growth velocity (GV), trunkLBM:BSA and IGF-I SDS, and normalized BMI SDS. A higher dose resulted in a higher GV and IGF-I SDS. In infants and pubertal children, GV and IGF-I did not affect the prevalence or progression of scoliosis. Prepubertal children treated with GH had a lower risk of developing scoliosis than untreated children (OR=0.04, p=0.02).

Conclusion: The prevalence of scoliosis in PWS children is high, with a high rate of progression. GH has beneficial effects in PWS children and has no adverse effects on the prevalence or progression of scoliosis. Scoliosis should not be a contraindication for GH treatment in PWS children.

Significance: This is the first study in a large population of children with PWS describing scoliosis and the effects of GH treatment. Based on our study, scoliosis should no longer be a contraindication for GH treatment in PWS children.

Paper #53

Lumbar Plexus Nerve Root Position within the Psoas Muscle: An Anatomic Study

Carl Paulino, MD; Nael Shanti, MD; Martin Quirno, MD; Jeffrey M. Spivak, MD (NYU Hospital for Joint Diseases)

Introduction: Complications from direct anterior surgical approaches to the lumbar spine can be avoided by trans-psoas approach; however, this approach potentially places the lumbar nerve roots at risk of direct injury during retractor placement. This anatomic study attempts to define a safe zone for retractor placement to minimize the morbidity using the trans-psoas approach

Methods: 12 human cadavers with intact and undisturbed psoas muscles and lumbar plexus underwent bilateral psoas muscle dissection to determine the position of the L2, L3, and L4 nerve roots within the muscle at the L2-3, L3-4, and L4-5 disc levels. The nerve roots were identified and isolated without disturbing the natural anatomic course. Measurements taken at each disc space level included: psoas M-L width; psoas A-P height; anterior-posterior (AP) displacement of the L2, L3, and L4 nerve roots. All nerve root AP measurements were made in relation to a reference measurement of sagittal disc space position at each level, measured from the anterior aspect of the vertebral foramen below the upper vertebral pedicle to the anterior aspect of the vertebral body.

Results: The psoas muscle demonstrated increased coverage of the disc space as it progressed distally from L2 to L4, with a mean coverage of approximately 80%, 86%, and 85% at L2-3, L3-4, and L4-5, respectively. The psoas also showed increase in its medial-lateral thickness progressing distally from L2 to L4, with a mean lateral extent of 16 mm, 23 mm, and 29 mm at L2/3, L3/L4, L4/L5, respectively. The L2 nerve root demonstrated the greatest variability of the three roots examined in its course, with an average anterior excursion of 5.7% (maximal 10%) from the posterior disc margin at L3-4 and 11.5% (maximal 32%) at L4-5. The L3 root demonstrated an average anterior excursion of 9% at the L4-5 level, with a maximal anterior excursion of 33% in a single specimen. The L4 root did not demonstrate any significant anterior excursion relative to the L4/L5 disc margin.

Conclusion: Based on this data, the upper lumbar plexus nerve roots are not at risk of direct injury as long as the retractor blades are placed and opened within the anterior 95% of the psoas at the L2-3 disc space, 90% at the L3-4 disc, and 67% at the L4-5 disc.

Paper #54

Does Treatment (Nonoperative and Operative) Help Patients with Adult Symptomatic Lumbar Scoliosis: A Prospective Multicenter Evidence-Based Medicine Study

Lukas P. Zebala, MD; Keith H. Bridwell, MD (Washington University in St. Louis); Steven D. Glassman, MD; William C. Horton, III, MD; Christopher I. Shaffrey, MD; Frank J. Schwab, MD; Joan F. Hilton, ScD; Michael R. Shainline, MS; Christine Baldus, RN, MHS; David Wooten, PhD

Introduction: No EBM article answers whether treatment helps adult spinal deformity patients. This study evaluated nonoperative and operative treatment outcomes in ASLS patients.

Methods: From 2003 to 2005, 5 centers prospectively enrolled 160 consecutively enrolled ASLS patients, age 40-80 years, with no history of prior spine surgery. ASLS was defined as a thoracolumbar/lumbar (T/L) coronal Cobb angle ≥ 30 and either an Oswestry disability index (ODI) score ≥ 20 or a Scoliosis Research Society (SRS) score ≤ 4 in pain, function or activity domains. Patients were non-randomly assigned to nonoperative (observation, medication, injection, physical therapy) and operative treatment groups. Propensity matching was used to compare nonoperative and operative treatment outcomes. Pretreatment and minimum 2-year follow-up HRQOL outcomes and radiographs were analyzed.

Results: In the unmatched groups analysis (75 nonoperative and 85 operative), operative patients had slightly larger preoperative T/L Cobb angle (56 ± 15 vs. 50 ± 18 , $p=0.02$) and lower HRQOL scores (SRS subscore $p=0.047$; ODI $p=0.17$). From pretreatment to 2-year follow-up, only operative patients reported significant improvement in HRQOL scores. At 2 years post-treatment, operative patients had better HRQOL (SRS subscore and ODI $p<0.001$) and less pain (NRS [Numerical Rating Scale] back/leg pain and SRS pain $p<0.001$) than nonoperative patients. For propensity matching, 82 (50%) patients with similar baseline T/L Cobb angle, SRS subscore, ODI and NRS back/leg pain were available for analysis. From pre-treatment to 2-year follow-up, only the matched operative group had significant improvement in HRQOL and pain measures. At 2-years post-treatment, the propensity matched operative patients reported better health (SRS subscore and ODI $p<0.001$) and less pain (NRS back/leg pain, SRS pain $p<0.05$) than the nonoperative group. See figure.

Conclusion: This study shows operative treatment helped ASLS patients as determined by HRQOL measures (SRS, ODI, NRS back/ leg pain) in both the unmatched and propensity-matched comparisons, while nonoperative treatment did not help.

Significance: This first of its kind EBM study demonstrated operative treatment did help ASLS patients by all HRQOL measures while nonoperative treatment did not.

Table 1.

	SRS Subscore			ODI			SRS Pain		
	Pre-treatment	≥ 2 Yr F/U	p-value	Pre-treatment	≥ 2 Yr F/U	p-value	Pre-treatment	≥ 2 Yr F/U	p-value
Matched Subgroup									
Operative (N=41)	3.1 \pm 0.6	3.8 \pm 0.7	<0.001	34.2 \pm 15.1	22.1 \pm 17.0	<0.001	2.8 \pm 0.7	3.8 \pm 0.9	<0.001
Nonoperative (N=41)	3.1 \pm 0.5	3.1 \pm 0.5	NSSD*	33.5 \pm 15.1	33.3 \pm 15.2	NSSD*	3.0 \pm 0.6	2.9 \pm 0.8	NSSD*
Unmatched Group									
Operative (N=85)	3.1 \pm 0.5	3.8 \pm 0.7	<0.001	33.4 \pm 15.3	20.0 \pm 15.3	<0.001	3.0 \pm 0.7	3.9 \pm 0.8	<0.001
Nonoperative (N=75)	3.3 \pm 0.5	3.3 \pm 0.6	NSSD*	30.3 \pm 14.3	32.3 \pm 17.3	NSSD*	3.1 \pm 0.6	3.2 \pm 0.9	NSSD*

*NSD=no statistically significant difference

* The FDA has not cleared a drug and/or medical device in use described in this presentation (i.e., the drug or medical device is being discussed in an off-label use). For full information see page 10.

Paper #55

Functional Outcomes and Complications following Primary Spinal Surgery for Scoliosis in Adults Age 40 Years and Older: A Prospective Study, with a Minimum 2-Year Follow-Up

Ryan M. Zimmerman, BS; Khaled Kebaish, MD (Johns Hopkins University School of Medicine); Ahmed S. Mohamed, MBCh, MsC, Ortho; Richard Skolasky, ScD; Malaya Robinson, RN, BSN, RNFA

Introduction: Older adults with scoliosis pose a surgical challenge, due largely to their high risk of complications that may lead to poor outcomes. There have been few outcome studies of older adults undergoing surgery for scoliosis.

Methods: Thirty-five adults mean age 56.3 years (40-81, SD=11.0), 33 females, 33 Whites, undergoing spinal fusions for scoliosis between 2001-2006 were followed prospectively for >2 years, mean 49.4 months (25-97, SD=17.7). Patients completed standard outcome questionnaires pre-op and during regular follow-up. Intra- and post-op complications were recorded.

Results: The predominant chief complaint was back pain (29/35). Sixteen patients had only posterior procedures, 5 were anterior-posterior same-day and 14 were staged. Pre-op coronal curvature was 48.5° (20-87°, SD=15.8°), thoracic kyphosis 35.7° (18-59°, SD=12.1°) and lumbar lordosis 38.2° (10-68°, SD=13.7°). Post-op coronal curvature was 19.5° (5-45°, SD=9.3°), thoracic kyphosis 39.2° (17-72°, SD=14.6°) and lumbar lordosis 43.2° (23-75°, SD=11.2°). Coronal correction was 61% (35-85%, SD=13%). Mean levels fused was 10 (5-15, SD=2.8); 20 extended to the sacrum. **The overall complication rate was 49% (17/35) with 26% (9/35) major and 31% (11/35) minor. There were no mortalities, but two pseudoarthroses, one requiring reoperation.** Operative time was 519 (253-815, SD=160) minutes and blood loss was 2735 (300-8500, SD=1928) cc. There were post-op improvements in: Oswestry Disability Index (ODI) -21.7 (p<.001), SF-36 physical +20.6 (p<.001) and SF-36 mental +3.1 (p=.026). There were no relationships between complications, sagittal or coronal correction and ODI or SF-36 scores, nor differences in outcomes based on staging regimen. Patients whose fusions stopped proximal to the sacrum showed greater improvements on SF-36 mental health scores than patients whose fusions extended more distally (p=.041).

Conclusions: Despite the high complication rate, older patients with scoliosis benefit from surgical treatment.

Major Complications	
Mortality	0
Pulmonary Embolism	1
Deep Wound Infection/Osteomyelitis	4
Pseudoarthrosis	2
Sacral Fracture	2
Retroperitoneal Hematoma	1
Minor Complications	
Superficial Wound Infection	0
Pleural Effusion (Requiring Intervention)	3
Urinary Tract Infection	5
Yeast Infection	1
Dural Tear	2
Post-Operative Atrial Fibrillation	1
Peroneal Nerve Palsy (Transient)	1
Brachial Plexopathy (Transient)	1
Spleen Laceration	1
Pneumothorax	1
Total	26

* The FDA has not cleared a drug and/or medical device in use described in this presentation (i.e., the drug or medical device is being discussed in an off-label use). For full information see page 10.



Paper #56

Pedicle Subtraction versus Smith-Petersen Osteotomies for Correction of Fixed Sagittal Plane Deformities: Clinical and Radiographic Outcomes in 151 Patients

Brian Hsu, MB, BS, FRACS (Twin Cities Spine Center); Amir A. Mehdod, MD; Prof. Serkan Erkan; Ensor E. Transfeldt, MD; Joseph H. Perra, MD; Francis Denis, MD; Timothy A. Garvey, MD; Manuel R. Pinto, MD; James D. Schwender, MD; Daryll C. Dykes, MD, PhD; John E. Lonstein, MD; Robert B. Winter, MD

Introduction: Pedicle subtraction (PSO) and Smith Peterson (SPO) osteotomies are commonly used surgical techniques in the correction of spinal deformities, in particular the correction of sagittal plane deformity. This study compares the radiographic profile and outcomes in 151 such osteotomies, the largest series comparing 2 techniques from a single institution.

Methods: At our center, from 1985 to 2005, there have been over 800 spinal fusion operations performed that involved arthrodesis of more than 5 levels. Within this group of patients, 322 underwent spinal osteotomy procedures for a variety of indications. Included were patients having either SPO or PSO, skeletally mature and at least 2-year follow-up. The pre-operative and post-operative radiographs were reviewed and a range of parameters were recorded.

Results: There were 151 patients identified who met the inclusion criteria. There were 100 (Mean age 47.3, male 40) patients who underwent SPO. 54% had an anterior procedure. Patients who had 3 or more SPO on average had greater than 10 fusion levels and had greater change in segmental kyphotic angle and sagittal balance than 1 or 2 levels. The mean segmental kyphosis correction showed significant difference between 1 and 2 level SPO (19°) versus 3 or more SPO (36°). There were 51 patients who underwent PSO (Ave age 50.8, Male 21). 13 patients had thoracic PSO (11/13 did not have an anterior procedure). PSO patients showed greater sagittal plane correction than 1, 2 or 3 level SPO (Mean C7 plumb line correction: SPO 15 mm per level, PSO 78 mm per level). PSO also showed greater segmental kyphosis correction compared to 1 or 2 level SPO. (SPO: 12° lordosis per level, PSO: 32° lordosis per level).

Conclusion: The choice of osteotomy technique depends on the goals of surgery. SPO may be more effective in correcting segmental kyphosis, whereas PSO may restore more sagittal balance depending on the level of the osteotomy. Thoracic PSO is effective in managing segmental kyphosis without an anterior procedure.

Significance: Both Smith-Petersen and Pedicle Subtraction Osteotomy surgery can provide adequate correction of sagittal plane deformities, but PSO surgery gave more correction per osteotomy for both sagittal balance and segmental kyphosis.

Paper #57

Early Complications of Methylprednisolone Sodium Succinate (MPSS) in the Treatment of Acute Cervical Spinal Cord Injury

Yasuo Ito, MD, PhD (Kobe Red Cross Hospital); Y. Sugimoto, MD

Introduction: MPSS is the only single treatment drug used for acute spinal cord injury. In the present study, we investigated the effects and complications of a high-dose MPSS therapy in cases of acute cervical spinal cord injury.

Methods: Prospectively, a treatment was performed according to the NASCIS protocol in all cases of cervical spinal cord injury during a 2 year period from August 2003 through July 2005 (the MPSS Group), whereas steroids were not administered in all cases of cervical spinal cord injury after August 2005 (non MPSS Group). During the period, the number of cases of cervical spinal cord injury was as follows: 38 cases in the MPSS Group (30 males and 8 females), and 41 cases in the non-MPSS Group (33 males and 8 females). The degrees of severity of paralysis were as follows according to the Frankel Classification: A: 10, B: 4, C:11, D:13 (MPSS Group) and A:11, B:11, C: 12, D: 7 (Non-MPSS Group). Improvements in the American Spinal Injury Association Motor Score were investigated. In both groups, improvements and complications that onset within 3 month from the injury were investigated and compared between the two groups.

Results: With respect to the ASIA Motor Scores, the average number of points gained was 12.4 points (MPSS Group) and 13.8 points (non-MPSS Group), which indicated no significant difference. The pulmonary complications represented by pneumonia were found in 19 cases (50%) (MPSS Group) and 11 cases (27%) (non-MPSS Group), which indicated a significant difference. In particular, in the cases of Frankel A and B, pneumonia was associated in 11 cases (79%) in the MPSS Group and 8 cases (36%) in the non-MPSS Group, which indicated a significant difference.

Conclusion: In our study cases, we could not find any significant difference in the improvement effects of high-dose MPSS therapy on paralysis. In contrast, we had the statistically significant that the incidences of pulmonary side effects were higher in the MPSS Group, especially in Frankel A and B.

Significance: We could not find any significant difference in the improvement effects of high-dose MPSS therapy on paralysis. We had the statistically significant that the incidences of pulmonary side effects were higher in the MPSS Group.

Paper #58

***Inflammatory Cytokine Expression and the Development of Injury-Severity Biomarkers after Human Spinal Cord Injury**

Anthea M. Stammers, MSc; Lise Belanger, RN, BSN, MSN; Donna Chan, RN; Arlene Bernardo, RN; Hamed Umedaly, MD; Wolfram Tetzlaff, MD, PhD; Mitch Giffin, MD; Scott C. Paquette, MD; Michael C. Boyd, MD, MSc; John Street, MD; Charles Fisher, BSc, MHSc, MD, FRCSC; Marcel F. Dvorak, MD; Brian Kwon, MD, PhD (University of British Columbia)

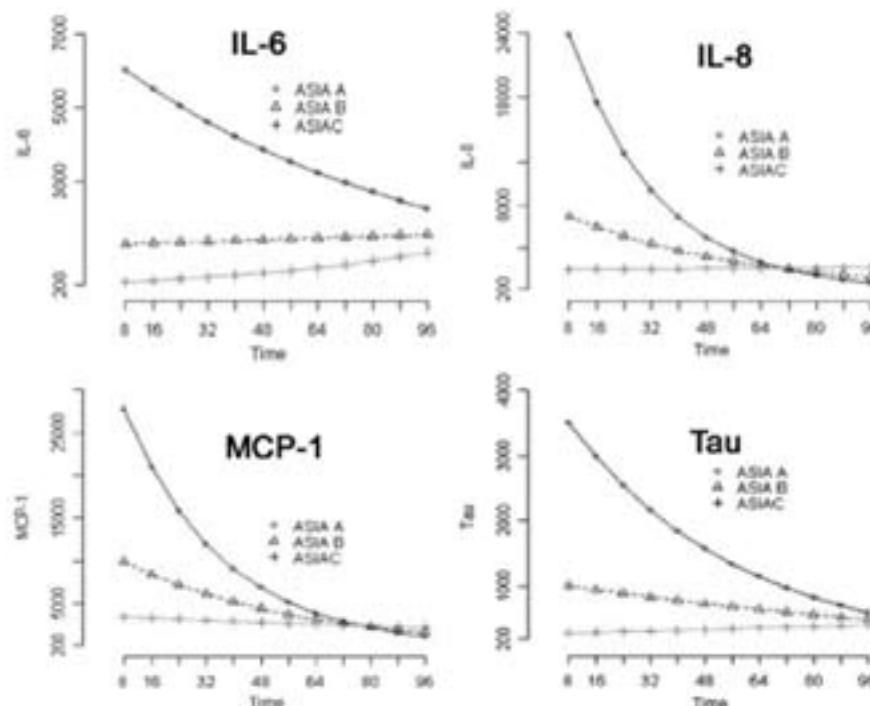
Introduction: An important barrier to the SCI community in its search for therapies has been the paucity of knowledge about the pathophysiology of human SCI (in contrast to animal SCI). An important challenge in human SCI clinical trials has been our reliance upon functional measures (ie. the neurologic examination) for stratifying the severity of paralysis. This study addresses both obstacles, by characterizing the inflammatory response to human SCI, and establishing biological correlates to injury severity.

Methods: 20 patients within 48 hours of sustaining a complete (ASIA A) SCI or incomplete (ASIA B or C) SCI were enrolled in a clinical trial in which an intrathecal catheter was inserted to drain CSF for 72 hours. Cytokines were measured in CSF and serum samples using a multiplex cytokine array system and standard ELISA techniques. CSF of patients undergoing joint replacements under spinal anesthesia served as controls.

Results: IL-6, IL-8, IP-10, MCP-1, TNF-R1, and tau were elevated within 24 hours after SCI and tended to decrease over the next 72 hours. IL-6, IL-8, MCP-1, and tau were elevated in a severity-dependent fashion (ie. higher in ASIA A injuries than B or C injuries). A model was generated using IL-6, IL-8, and MCP-1 to predict injury severity (ASIA A, B, or C). After inputting the observed CSF concentrations into this model, we were able to accurately predict the patients' ASIA grade with a rate of 84.2%. Furthermore, the cytokine levels were more accurate than the patients' ASIA grade at predicting motor recovery at 6 months post-injury.

Conclusion: The temporal expression pattern of a number of inflammatory cytokines such as IL-6, IL-8, and MCP-1 provides invaluable information about the of human SCI, and gives us the ability make comparisons with the animal condition. Additionally, a combination of these cytokines appear to be expressed in an injury-severity dependent fashion.

Significance: This is the first ever description of the temporal pattern of change in inflammatory cytokine expression after human SCI. Additionally, our prediction model represents the first biological surrogates of cord injury that may be used to more accurately predict severity and stratify patients for clinical trials.



* The FDA has not cleared a drug and/or medical device in use described in this presentation (i.e., the drug or medical device is being discussed in an off-label use). For full information see page 10.

Paper #59

Magnesium in a Polyethylene Glycol Formulation Provides Neuroprotection after Acute Spinal Cord Injury

Brian K. Kwon, MD, PhD; Josee Roy, PhD (Medtronic); Jae H. Lee, BSc; Jie Liu, MD; Anthea M. Stammers, MSc; Jeffrey Marx, PhD

Introduction: Many experimental treatments have shown promising neuroprotection in animal models of SCI. Of particular interest are those drugs that are already in safe clinical use for other unrelated indications. Such drugs are prime candidates for translation into human trials because of their well-established safety profiles. Examples of such “clinically safe” drugs are the statins. These form a broad class of drugs which are clinically used to reduce cholesterol. Recently, however, other pleiotrophic effects of statins have been recognized, such as immuno-modulation and neuroprotection. In this regard, statins have been shown by several laboratories to be efficacious treatments for experimental models of stroke, traumatic brain injury, and SCI.

Methods: A T9/10 moderate severity spinal cord contusion (OSU Impactor, 1.5 mm) was performed on Sprague-Dawley rats. The animals were randomized to Simvastatin (20mg/kg/day), Atorvastatin (5mg/kg/day), or Saline administered via oral gavage for 7 days. For each drug, the dosage used was identical to that used in previous neuroprotective studies. Behavioral recovery was evaluated in a blinded fashion over 6 weeks using an open field locomotion test (BBB scores and subscores). The spinal cords were harvested and subjected to histological analysis.

Results: Locomotor recovery (BBB and subscores) was significantly increased after Simvastatin treatment but not with Atorvastatin. There was significantly increased white matter sparing at the injury epicenter after Simvastatin treatment. Analysis of the injury site revealed that macrophage infiltration or microglial activation was significantly decreased after Simvastatin treatment.

Conclusion: Only Simvastatin was observed to protect spinal cord white matter and improve neurological recovery after SCI. Unfortunately, we were not able to reproduce results that others have reported treating SCI with Atorvastatin.

Significance: We report for the first time the efficacy of Simvastatin in the treatment of acute SCI. The safety and tolerability of Simvastatin and widespread clinical usage makes it a favorable candidate for human SCI.



Paper #60

Increasing Lumbar Lordosis of Adult Spinal Deformity Patients via Intraoperative Prone Positioning

Katsumi Harimaya, MD; Takuya Mishiro, PhD, MD (Washington University); Lawrence G. Lenke, MD; Keith H. Bridwell, MD; Linda Koester; Brenda A. Sides, MA

Introduction: Intraoperative prone positioning with hip extension may posturally increase lumbar lordosis during adult spinal deformity surgery. We evaluated the change of lumbar lordosis in spinal deformity patients occurring during prone positioning on the operative table via radiographic analysis.

Methods: Radiographs of 26 operative spinal deformity patients (25 females 1 male, ave. age 58.2 yrs, 22-primary and 4-revision) were analyzed. There were 14 idiopathic scolioses, 6 degenerative lumbar scolioses, and 6 other diagnoses. Total lumbar lordosis (T12-S1), segmental disc angles, and C7 plumbline (C7PL) were measured on preop upright, preop supine, intraop prone, and postop upright lateral x-rays. All patients were positioned intraoperatively with hip extension on the OSI (Jackson) frame.

Results: (See table). The average preop upright, preop supine, intraop prone, and postop upright lumbar lordosis was -31.7°, -43.1°, -46.2°, -49.9°, respectively ($p < 0.05$ for preop upright to all other comparisons). 2 groups were noted: those with increased lumbar lordosis ($>5^\circ$) during intraoperative prone positioning ($n=19$, increased lordosis group vs. those with unchanged lordosis during intraop prone positioning ($n=7$, unchanged lordosis group). The corresponding lumbar lordosis measurements for the increased lordosis group were: -22.5°, -37.2°, -42.3°, -47.3° ($p < 0.05$ for preop upright to all other comparisons). The corresponding lumbar lordoses for the unchanged lordosis group were: -56.7°, -59.1°, -57.0°, -57.0° (no significant differences). Preop upright lumbar lordosis of those patients who did not have an increased lumbar lordosis was substantially higher than the value of those with increased lumbar lordosis ($p < 0.05$).

Conclusion: Adult spinal deformity patients with preoperative hypolordosis who are positioned prone during spinal deformity reconstructions will have an enhanced lumbar lordosis via positioning alone averaging 19.8° vs their preop upright radiographs. Conversely, those with substantial preop lordosis (ave. -56.7°) will remain unchanged with intraoperative prone positioning. This knowledge will help in surgical planning of adult spinal deformity reconstructions.

Paper #61

A New Way of Assessing Sagittal Balance: A Radiologic Study of 232 Asymptomatic Individuals

Sebastien Charosky, MD (Institut Calot); Ian J. Harding, BA, FRCS (Orth); Raphael Vialle, MD, PhD; Eric Berthonnaud, PhD; Pierre Roussouly, MD; Daniel Chopin, MD

Introduction: The C7 plumb line (the vertical line between the center of C7 and the posterior superior corner of S1 on the lateral standing X-ray) is currently being used to measure sagittal alignment although the appropriateness of this measurement has been debated. Drawbacks of using a distance from a vertical line are difficulty in comparison to angular parameters in the sagittal plane and the error of x-ray magnification. The objective of this study was to describe a new method for the assessment of sagittal balance.

Methods: Lateral x-rays of 232 asymptomatic individuals in a standardized standing position were analyzed using a computerized measurement. Pelvic incidence (PI), sacral slope (SS), pelvic tilt (PT), lumbar lordosis (LL) and a new angle, the C7 tilt (C7t) were measured. This angle is formed by the vertical line that passes through the center between the femoral heads and a line from this point to the center of C7. The theoretical ideal pelvic tilt (ThPT) according to the PI was also calculated. A comparison between theoretical and measured variables enabled normal sagittal balance to be described using two parameters: the C7 and pelvic tilts.

Results: Mean values (with standard deviations) were: PI:51.6° (11.1°); SS:40.8° (8.3°); PT:12.7° (6.2°); LL:42.6° (11.4°); C7 tilt:-2.7° (2.4°). A negative value means the angle is behind the vertical line passing through the center between the femoral heads. There was no significant difference between the ThPT and the actual PT. A significant correlation was found between the PI, PT and LL ($p < 0.0001$). Two parameters were chosen to describe normal sagittal balance: the C7t to describe the global positioning of the trunk and the PT to describe the position of the pelvis and lumbar spine. As the C7t angle is too small, only the direction (positive v. negative: ahead or behind the vertical line passing through the center of the femoral heads) was taken into consideration. Normal sagittal balance can then be described as following two criteria: $C7t = 0^\circ$ and $PT = ThPT \pm SD$.

Conclusion: The C7 tilt angle describes the global positioning of the trunk and the PT the alignment of the pelvis. These angular measurements allow thorough description of the global sagittal alignment without measuring a distance from a vertical line



Paper #62

Long Term Clinico-Radiological Outcomes after Surgical Treatment of Scheurmann's Kyphosis (SK): A UK Experience of 35 Cases with an Average Follow-Up of 9 Years

Nanjundappa Harshavardhana, MS(Orth), Dip. SICOT (Queen's Medical Center, Nottingham University Hospitals NHS Trust); Hossein Mehdian, FRCS, MD; Harshad Dabke, FRCS; Ujjwal K. Debnath, FRCS; John K. Webb, MBBS, FRCS

Introduction: Indications for anterior release are not well defined for SK. Both under & over-correction are attributed to cause JK.

Methods: A retrospective review of 35 patients (19 males;16 females) who underwent surgery for SK was undertaken. The mean age & follow-up were 20.5 (13.25-45.75) and 9 years (5-22) respectively. Patient demographics, clinico-radiological parameters & functional outcomes (ODI & SRS-22) were assessed. The radiological indices studied were Cobb & Ferguson angles, Voutsinas index, sacral inclination (SI) and sagittal vertical axis (SVA). The incidence of JK was co-related with radiographic parameters & instrumentation levels. Outcomes of posterior instrumentation (GroupI-13) were compared with anterior release & posterior instrumentation (GroupII-22). Of group-II, maintenance of correction & fusion rates of morcellised rib grafts (12) were compared with titanium cages (10).

Results: Cobb angle of 60 on redression x-rays and anterior bony bridge required anterior release. JK of 10 was seen in 12 cases (7 proximal & 5 distal). PJK was seen in cases where T3-4 was the UIV. DJK was seen in patients with body mass index (BMI) of 30 and when LIV did not include 1st lordotic disc segment. There was significant difference in mean thoracic kyphosis correction between the 2 groups (35.70 vs 44.50; p=0.003). The mean loss of correction at 9 yrs was 5.9 and 3.4 respectively. There was no difference in the mean correction of lumbar lordosis (-22.60 vs -19.30; p=0.12). There were 3 deep infections requiring debridement & implant removal and 1 patient each with pneumothorax & transient neurodeficit recovered uneventfully. 33/35 were subjectively satisfied with cosmesis and 28/35 patients returned to their previous occupation. Of the remaining 7, 3 were off work due to chronic back pain and 4 others had job modifications.

Conclusion: Stiff curves require anterior release. PJK could be overcome by including T2 as UIV. DJK could be prevented by including 1st lordotic disc segment in LIV. Instrumenting L3 as LIV would reduce the risk of implant failure in patients with BMI >30. There was no advantage of cages compared to rib grafts.

Significance: Surgery for SK is associated with good functional outcome, high satisfaction with acceptable complication rate.



Paper #63

Increasing Pain and Disability, Rather than Deformity, Determine Treatment Modality for Older Patients with Adult Scoliosis

Oheneba Boachie-Adjei, MD; R. Shay Bess, MD (San Diego Center for Spinal Disorders); Matthew E. Cunningham, MSc; Douglas C. Burton, MD; Christopher I. Shaffrey, MD; Alexis P. Shelokov, MD; Richard A. Hostin, MD; Frank J. Schwab, MD; Kirkham B. Wood, MD; Munish C. Gupta, MD; Behrooz A. Akbarnia, MD; International Spine Study Group

Introduction: Little information exists on factors determining adult scoliosis (AS) treatment. Existing reports have not age stratified features leading to operative (OP) or nonoperative (NON) treatment. The goals of this study were to identify age related clinical and radiographic features correlating with AS treatment.

Methods: Multi-center, retrospective review of 282 AS patients treated OP (n=150; avg. age 52 yrs) or NON (n=132; avg. age 54.6 yrs). Inclusion criteria: age >18 yrs, scoliosis >20 deg. Patients divided into treatment type (OP or NON) and stratified into 3 age groups (GP1=<50 yrs, GP2=50-65 yrs, GP3=>65 yrs). Radiographic (XR) evaluation included coronal, sagittal and spinopelvic measures. Health related quality of life measures (HRQL): SRS-22, Oswestry Disability Index (ODI), visual analog pain scale (VAS).

Results: Age non-stratified, OP vs. NON showed no demographic differences. Average thoracic curve size was the only age non-stratified XR difference (OP=51.2, NON=45 dg; p<0.05). Age non-stratified VAS and SRS scores were worse in OP vs. NON (VAS=6.9 vs. 5.6, p<0.001; SRS=2.9 vs. 3.1, p<0.05). All age stratified subgroups had similar patient numbers and mean age. Age stratified XR differences within treatment type: OP= GP1 had larger avg. thoracic curve than GP3 (54 vs. 34 dg, p<0.05), and GP2 had larger avg. thoracolumbar curve than GP3 (58 vs. 46 dg, p<0.05). Conversely, NON= GP2 had larger avg. thoracic curve than GP1 (53 vs. 43 dg, p<0.05). Both OP and NON demonstrated progressive sagittal imbalance with aging (p<0.05). Age stratified XR differences by treatment type: GP1= OP thoracic curves were larger than NON (53 vs. 43 dg, p<0.05). GP2= OP demonstrated hypokyphosis and hypolordosis compared to NON. GP3= No XR differences OP vs. NON. Comparing HRQL values: GP1= no differences OP vs. NON. GP2 and GP3= all OP HRQL were worse than NON, except SRS score (Table 1). GP3 OP demonstrated worst VAS and ODI of all groups. All NON groups had similar HRQL.

Conclusion: Operative treatment for older patients is driven by disability and poor HRQL scores while deformity dictates treatment for younger patients. Radiographic parameters have little treatment influence for older patients.

Group	Operative	Nonoperative	p value
(n=OP; n=NON)	(VAS/ODI/SRS)	(VAS/ODI/SRS)	(VAS/ODI/SRS)
GP 1 (55;56)	5.5** / 21.8* / 3.2**	5.7 / 23.8 / 3.3	NS / NS / NS
GP 2 (53;52)	7.3 / 37.2* / 2.7	5.3 / 28.7 / 3.1	<0.001 / <0.05 / <0.05
GP 3 (24;42)	7.9 / 50.8* / 2.7	5.7 / 36.1*** / 3.0	<0.05 / <0.05 / NS

*= p<0.05, between each pairwise comparison / **=p<0.05, GP2 and GP3 vs. GP1 / ***=p<0.05, GP1 and GP2 vs. GP3



Paper #64

Clinical Instinct versus Standardized Questionnaire: The Spinal Surgeons Ability to Detect Psychological Distress.

Michael D. Daubs, MD (University Utah); Alpesh Patel, MD; Darrel S. Brodke, MD

Introduction: Psychosocial risk factors can effect treatment outcomes. Psychological distress has been shown to be a predictor for poor outcomes with spinal surgery. Most spinal surgeons do not use validated questionnaires to assess psychological distress, but instead rely on their clinical instincts. The purpose of this study was to evaluate surgeons' ability to clinically assess psychological distress compared to the validated Distress Risk Assessment Method (DRAM) questionnaire.

Methods: A prospective, blinded study consisting of 400 patients being evaluated for a spinal disorder and 8 physicians (4 spinal surgeons, 4 physiatrists) was performed to evaluate the physician's ability to assess levels of psychological distress. All patients completed a DRAM questionnaire. The physicians, blinded from the results of the DRAM, performed their routine clinical evaluation and categorized the patient's level of psychological distress into one of the four DRAM categories: N, Normal; AR, At-risk; DD, Distressed Depressive; and DS, Distressed Somatic. The physician's ability to correctly assess psychological distress as compared to the DRAM score was recorded. Comparison in accuracy of assessments between surgeons, physiatrists, less experienced surgeons (< 2 years) and more experienced surgeons (>10 years) were made.

Results: 37% (146/400) of the new patients were categorized as Normal; 42% (167/400) At-Risk; 13% (51/400) Distressed Depressed; and 9% (36/400) Distressed Somatic. As a group, physicians correctly assessed patients 44% of the time (kappa .15). Surgeons were correct 40% of the time and physiatrists 49% (p=0.08). Physiatrists were better at discerning patients who were AR (p=0.004) and DS (p=0.006) compared to surgeons. Surgeon experience was not a significant factor (p>0.05).

Conclusion: Spinal surgeons performed poorly when clinically assessing psychological distress. Psychological distress is a predictor for poor surgical outcomes. Validated questionnaires like the DRAM should be used routinely and incorporated in the surgical decision making process.

Significance: Psychosocial risk factors are important determinants in spinal surgery outcomes. Spinal surgeons need to be aware of these risks and rely on more than clinical instincts when screening for them.

Paper #65

RT-PCR and Microarray Experimental Study for the Impact of Methylprednisolone and Sodium Channel Blocker on Axonal Growth after Acute Spinal Cord Injury in Rats

Jun-Young Yang, MD, PhD (Chungnam National University Hospital); Prof. June Kyu Lee; Ho sup Song, MD; Eui Pyo Hong, MD

Introduction: Development of drug related to regeneration of nerve and neuroprotection was focused to control secondary injury after SCI. The aim of this study is to determine the the impact of methylprednisolone (MP) and sodium channel blocker (Riluzole) on axonal growth after acute spinal cord injury (SCI) in rats.

Methods: The SCI models of SD rat were divided into 2 groups. Group I was injected with saline (1ml/kg) and group II was injected MP (300mg/kg) with riluzole (5mg/kg) simultaneously. We evaluated behavioral test, RT-PCR and in situ hybridization for chondroitin sulfate proteoglycans (CSPG) and the change of transcription factor including c-JUN, ATF-2, p53 and Elk-1 which related with MAPK pathway using microarray method in each group.

Results: On behavioral test used BBB scoring system, the differences between I and II had a statistical significance at 4th and 7th day ($P < 0.05$), while two groups did not have difference statistically at 1st day after SCI. In RT-PCR and in-situ hybridization for CSPG, we found significance differences between groups at 4th and 7th day after SCI and also noted large cavity and more expression of CSPG in group I. The change of c-JUN was on the increase immediately and then drop and increment in group I, but increased with the lapse of time in group II. The degree of c-JUN in group II at 7th day was less than in group I at 1st day. The expression of ATF-2 was increased with the lapse of time but group II was less expressed than group I with statistical differences. The pattern of p53 expression in group I was down-regulation with the lapse of time. In group II, down-regulation was noted at 4th day and then the increment was noted at 7th day. we found significance differences at 7th day only. The change of Elk-1 was more complicated; up-regulation in group I and II at 4th day, and then plateau in group I, but down-regulation in group II.

Conclusion: MP and riluzole were confirmed to have a neuroprotective effect in view of various transcription factors which related with MAPK pathway and CSPG production which from glial scar.

Significance: This study afford the basic data to future studies about the clinical relevances of methylprednisolone with riluzole for acute spinal cord injured patients.

Paper #66

Transplantation of Human Marrow Stromal Cells and Mono-Nuclear Bone Marrow Cells into the Injured Spinal Cord: A Comparative Study

Amer F. Samdani, MD (Shriners Hospital); Courtney Paul, BS; Birgit Neuhuber, PhD; Randal R. Betz, MD; Itzhak Fischer, PhD

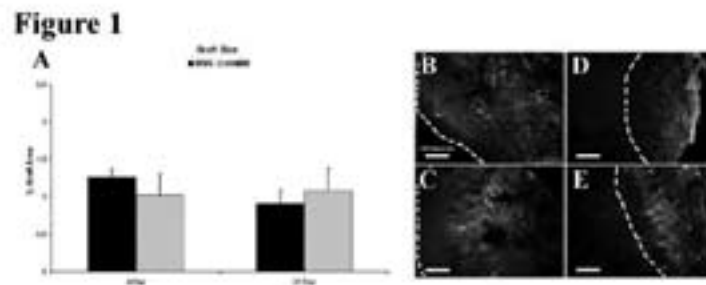
Introduction: Cellular transplantation is a promising treatment strategy for spinal cord injury. Bone marrow stromal cells are particularly attractive because of the ease of isolation and banking and the availability of autologous sources. In addition, recent animal studies have shown that MSC support recovery after SCI. However, the need to culture MSC prior to transplantation may interfere with optimal transplantation protocols and possibly increase their immunogenicity. These risks can be avoided by using an alternate cell type - the mnBM, which consists of hematopoietic precursors and a small percentage of MSC. mnBM is equally easy to isolate (from autologous sources) and bank but does not require culturing, thus allowing transplantation within hours.

Methods: Twelve Sprague-Dawley rats (n=3/group) received cervical hemisection injuries followed by direct parenchymal injection of 150,000 MSC or mnBM. Animals were sacrificed at 4 or 21 days and their spinal cords were analyzed histologically. Grafting efficiency was determined using a human nucleus specific antibody; Nissl/myelin staining was used for analysis of tissue protection; glial scar was analyzed using an antibody against glial fibrillary acidic protein (GFAP); host immune response was evaluated using antibodies specific for macrophages/microglia (ED-1) and T-cells (CD5).

Results: Grafting efficiency and tissue sparing were comparable for both cell types at 4 and 21 days (Figure 1). mnBM resulted in less glial scarring at 4 days as well as reduced macrophage/microglia response at 4 days ($p < 0.05$), no difference was seen at 21 days. Host T-cell response was comparable for both cell types at 4 and 21 days.

Conclusion: mnBM and MSC showed comparable properties with respect to grafting efficiency, tissue sparing, glial scar reduction, and host immune response. Therefore, mnBM is a viable alternative to MSC for transplantation into spinal cord injury.

Significance: The ability to use the mnBM will dramatically ease the clinical translation of this promising therapeutic strategy for patients with SCI.



Paper # 67

****RUSSELL A. HIBBS AWARD NOMINEE FOR BEST BASIC SCIENCE PRESENTATION**

VEPTR Improves Pulmonary Hypoplasia in a Postnatal Rabbit Model of Thoracic Insufficiency Syndrome

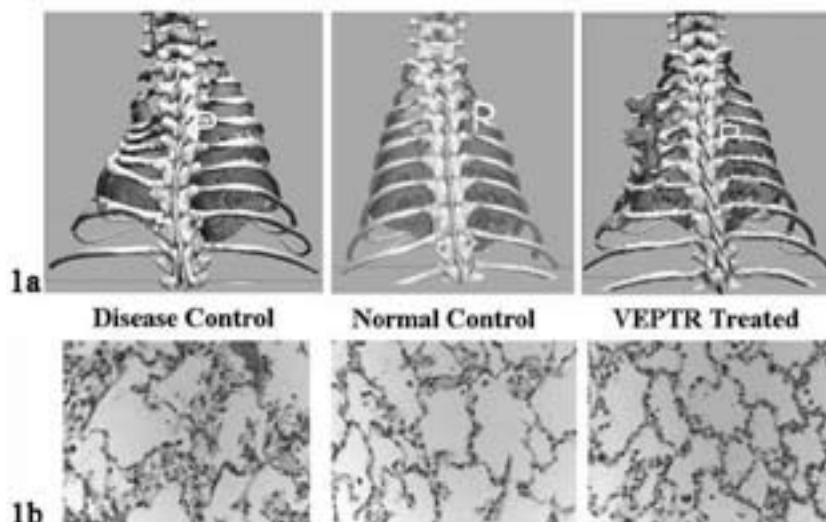
Hemal Mehta, MSc (Beth Israel Deaconess Medical Center); Brian D. Snyder, MD, PhD; Stephen R. Baldassarri, BA; Melissa J. Hayward, MD; Michael J. Giuffrida, MD; Supriya P. Bansal, BS; Vahid Entezari, MD; Nipun D. Patel, MS; Andrew C. Jackson, PhD

Introduction: Using a VEPTR, Campbell demonstrated that expansion thoracoplasty of a constricted hemithorax improves respiratory function and controls scoliosis in children with TIS. We hypothesized that expansion thoracoplasty of the constricted hemithorax improves postnatal pulmonary hypoplasia by allowing the lung to expand, improving respiratory function and stimulating normal lung growth.

Methods: In this feasibility study, tethering left ribs 3-8 in 7 five week old rabbits constricted the left hemithorax by 10 weeks and induced postnatal pulmonary hypoplasia of the left lung and scoliosis. Expansion thoracoplasty through the fused ribs was performed in 4 rabbits using a mini-VEPTR. These were compared to 3 DISEASE rabbits that grew until maturity with a constricted left hemithorax and 2 NORMAL rabbits. Thoracic deformity, scoliosis, right, left and total lung volumes were measured on 3-D CT reconstructions of the thorax at regular intervals 8-18 weeks. At maturity (24 weeks), lungs were excised and quantitative histology used to estimate alveolar air space fraction and surface density. ANOVA and Fisher's least significant difference comparative statistics were performed.

Results: Compared to DISEASE rabbits, expansion thoracoplasty of the constricted left hemithorax using mini-VEPTR improved the scoliosis but only minimally increased left lung volumes (Fig. 1a). Compared to NORMAL, compensatory increases in right lung volumes stabilized the total lung volume/kg for DISEASE and VEPTR treated rabbits. Alveolar air space fraction was significantly greater in DISEASE rabbits, indicating improved emphysematous changes in VEPTR treated rabbits. Capillaries adjacent to alveoli were also more prominent in VEPTR treated rabbits (Fig. 1b).

Conclusion: These data suggest that while expansion thoracoplasty reduces scoliosis and increases the volume of the constricted hemithorax, the relative increase in the ipsilateral lung volume is small since compensatory hypertrophy of the contralateral lung has already occurred. Thus VEPTR may improve respiratory function by increasing alveolar capillaries and preventing emphysematous changes.





Paper #68

**RUSSELL A. HIBBS AWARD NOMINEE FOR BEST BASIC SCIENCE PRESENTATION

Transient Short Term Local Bone Remodeling Effects of High-Doses of rhBMP-2 in a Novel Preclinical Interbody Spine Fusion Model

Hyun W. Bae, MD (The Spine Institute at St. John's); Ben B. Pradhan, MD, MSE; Vikas V. Patel, MA; Jeffrey M. Toth, PhD; Jeffrey M. Badura, MS; Howard B. Seim, DVM; A. Simon Turner, BVSc, MS, Dipl. ACVS

Introduction: The clinically safe volume/concentration of rhBMP-2/ACS has been established for select interbody constructs. However, peri-implant transient bone resorption has been observed on CT scans clinically. The objective was to investigate the effects of increasing rhBMP-2 dose on bone biology in a novel preclinical fusion model.

Methods: Fifteen (15) skeletally mature female sheep underwent transverse psoas interbody fusion at L2-L3 and L4-L5. Interbody spaces were meticulously prepared by separating the cartilaginous endplate from the cortical endplate after disc removal. No rasp or electric burr was used. Specially designed endplate-sparing impacted polyetheretherketone (PEEK) implants filled with two rhBMP-2/ACS doses (normal - 0.13 mg or high - 0.9 mg) were implanted. Unilateral rod/screw provided stability. Three animals were sacrificed at 1, 2, 3, 4, and 20 weeks with CTs and histology performed.

Results: Minimal bony endplate remodeling occurred at 1 and 2-weeks. However, 3 and 4-week CT scans at the high-dose levels demonstrated marked resorption which extended into the vertebral bodies, often compromising bony structures around the implant. These extensive resorption zones were not observed in normal-dose levels at any time. Histology demonstrated immature osteoid in peri-implant tissues at 3-4 weeks in both groups. At 20-weeks, all levels demonstrated fusion.

Conclusion: This study utilized an endplate sparing interbody fusion model to demonstrate rhBMP-2 dose-dependent osteoclastic activity and peri-implant resorption. However, this response is transient with fusion occurring by 20-weeks.

Paper #69

**RUSSELL A. HIBBS AWARD NOMINEE FOR BEST BASIC SCIENCE PRESENTATION

Porcine Scoliosis Model Based on Animal Growth Created with Minimal Invasive Off-Set Tethering

Thierry Odent, MD (Hôpital Necker Enfants Malades); Thibault Cachon, MV; Bertrand Peultier; José Gournay; Erwan Jolivet; Prof. Eric Viguier

Introduction: Conventional animal model of spine scoliosis are based on spinal combined with chest wall asymmetric tethering. Limits of those models are : important early mortality due to respiratory problems and thoracic effect of the scar with extensive concave paraspinal fibrosis which limits the ability of testing correcting methods. The purpose of the study is to create a porcine scoliosis model to class as an infantile scoliosis without chest wall injury based on the growth potential of the animal.

Methods: Seven 1 month's old pigs (9 kilograms weight, T1-S1 length : 30 cm) were used (6 +1 control). Using two mini-invasive posterior approach, an offset implant was fixed on two adjacent levels with unilateral pedicle screw (mid thoracic spine and L1-L2 vertebrae). The implants were connected with a cable inserted in a subcutaneous fashion without initial load. Spinal deformity was assess by a CT scan at 1 and 2 months. A three dimension stereographic analysis of the clinical parameters was performed with two digital reconstructed radiography (Pomero, Clin Biomechanics 2004). In two pigs, the cable was cut after two months and deformity followed-up for next 2 months.

Results: No post-operative complication was observed. Mean weight growth was linear (10 kg/months) as well as mean spine(T1-S1)lengthening :7cm/month. Mean Cobb angle was 45° at 2 months. One specimen had a less important Cobb angle (35°) due to a screw pull-out. We obtained a regular structural curve with vertebral Anteroposterior and lateral wedging at the apex of the deformity with chest wall deformity. Sagittal analysis reveals an hypokyphosis in the distal thoracic area. The loss of deformity after cable section was 30 % at 2 months.

Conclusion: This technique create a structural scoliosis and chest wall deformity without violating spinal and chest wall elements. Deformity was repeatable in term of amount and characteristic with minimal morbidity. Deformities were obtained quickly (2 months) and a minimal loss of correction was observed after cable section. This model with important, constant and rapid growth potential would be an interesting tool in order to test fusionless techniques of correction.



Paper #70

**RUSSELL A. HIBBS AWARD NOMINEE FOR BEST BASIC SCIENCE PRESENTATION

The Effect of Calmodulin Antagonists on the Incidence and Magnitude of Scoliosis in Pinealectomized Chicken and Bipedal C57BL/6 Mice

Ibrahim Akel, MD; Gokhan H. Demirkiran, MD; Ahmet Alanay, MD; Ralph Marcucio, MD; Emre Acaroglu, MD (Hacettepe University)

Introduction: Calmodulin probably has a regulatory role in muscle contraction and its' antagonism may decrease the magnitude as well as the progression of scoliosis. A separate study has shown especially tamoxifene (TMX), a known antagonist to be effective in altering the natural history in an avian model, it remains to be seen whether the same effect is conceivable in mammals.

Methods: 60 female 3-week-old C57BL/6 mice underwent amputations of forelimbs and tails. Available 57 were grouped as Gr C, no medications; Gr TMX, 10mg-TMX/lt drinking water and Gr combined, 10mg TMX+10mg trifluoperazine (TFP)/lt drinking water. PA scoliosis X-rays were taken at 20th and 40th weeks and evaluated for presence and magnitude of spinal curves. Pearson Chi-square test to compare curve incidences between and within the groups, ANOVA and Kruskal Wallis tests were used to compare the Cobb angles. Curve incidence changes within groups by time were compared by paired t-tests.

Results: 4 mice were lost in the TMX group. Overall scoliosis rate was significantly lower in this group (33%) compared to control (90%) and combined drug groups (68%) ($p = 0.001$) at 40th week. Likewise, upper thoracic scoliosis rate (27%) compared to control (74%) and combined drug groups (47%) ($p = 0,01$); lower thoracic scoliosis rate (7%) group compared to control (63%) and combined drug groups (26%) ($p = 0,001$) were lower in TMX group. Combined drug group had lower thoracic and lumbar Cobb angles ($17,50 \pm 3,45$) compared to control group ($29,40 \pm 5,98$) ($p = 0,031$). Furthermore, double curve incidence at 40th week was lower in TMX group (12%) compared to control (74%) and combined drug groups (47%) ($p = 0,001$), triple curve incidence was also lower in combined (0%) and TMX drug groups (6%) compared to control group (15%) but was not significant ($p = 0,167$).

Conclusion: Tamoxifen is shown to effectively decrease the incidence and magnitude of the scoliotic curves in C57BL/6 mice scoliosis model.

Significance: This study has proven that it is possible to change the natural history of scoliosis by way of oral medications antagonizing calmodulin in a mammal model. This is a novel finding, and may be very important in opening a pathway for the conservative treatment of idiopathic scoliosis by oral medications.

Paper #71

**RUSSELL A. HIBBS AWARD NOMINEE FOR BEST BASIC SCIENCE PRESENTATION

Effect of Teriparatide [rhPTH(1,34)] and Calcitonin on Intertransverse Process Fusion in a Rabbit Model

Ronald A. Lehman, Jr., MD (Walter Reed Army Medical Center); Anton E. Dmitriev, MSc; Mario J. Cardoso, MD, DC; Christen Christensen; Melvin D. Helgeson, MD; Timothy R. Kuklo, MD, JD; K. Daniel Riew, MD

Introduction: It is widely recognized that some osteoporosis medications, including bisphosphonates, can interfere with bone healing. Although prescribed frequently in the treatment of osteoporosis, the effect of teriparatide and calcitonin on spinal fusion has not been fully elucidated.

Methods: Fifty-one New Zealand white (NZW) rabbits underwent a posterolateral L5-L6 intertransverse process arthrodesis using autogenous iliac crest bone graft. The rabbits were randomly divided into three groups. All animals received daily subcutaneous injections of: Group I (n=17) 1cc of saline placebo; Group II (n=17) 10mcg/kg/d of teriparatide; Group III (n=17) 14IU/animal of calcitonin during the 8-week postoperative period. Post-mortem analyses included manual palpation, radiographic, biomechanical and histologic assessment (performed by two independent veterinary pathologists). Three random 10x fields were examined/graded within the cephalad, middle and caudad regions of each section (828 fields). Fusion quality was graded using the Emery histological scale (0-7 based on fibrous/bone content of the fusion mass).

Results: Histologic fusion rates for teriparatide averaged 86.7% and was significantly greater than the autograft control group (62.5%) (p=0.033). The average Emery grading score was 5.99+1.46SD for the autologous group and 6.26+0.93SD for the Forteo group (p=0.031). Radiographically, there was a strong trend towards teriparatide being superior to the calcitonin group (85.7% versus 56.3%, respectively; p=0.07). Although not significant, the Forteo group showed less motion in both flexion/extension (I-8.8+1.3, II-7.5+1.3 & III-8.7 +1.3) and axial rotation (I-2.3+1.1, II-1.7+0.8, III-2.1+0.7) (p=0.118).

Conclusion: Our results suggest that Forteo enhances spinal fusion while calcitonin has a neutral effect. The teriparatide group had the best histologic fusion rate and Emery scores, while the calcitonin group was similar to the saline controls. Although not significant, the Forteo group had a strong trend towards superior radiographic fusion over the calcitonin group.

Significance: Our results suggest that teriparatide (Forteo) is the drug of choice for osteoporotic patients undergoing spinal fusion surgery.

Paper #72

**RUSSELL A. HIBBS AWARD NOMINEE FOR BEST BASIC SCIENCE PRESENTATION

Sacral-Pelvic Fixation: A Biomechanical Comparison Between Constructs Ending with S2 Bicortical Bitriangulated (BCBT) Screws and Iliac Screws

William C. Horton, III, MD; JinHwan Kim, MD, PhD (Inje University, Paik Hospital); Takahiko Hamasaki, MD; Brett A. Freedman, MD; William C. Hutton, DSc

Introduction: Common to the two techniques of sacral-pelvic fixation is S1 pedicle screws; the difference lies between S2 screws versus iliac screws. Iliac screws are clinically effective, but present difficulties. S2 screws can obviate these difficulties, but traditional S2 screws have underperformed by comparison. In an effort to improve S2 fixation we have used a bicortical, bitriangulated (BCBT) S2 screws. The purpose of this study is to compare constructs using BCBT S2 screws and iliac screws.

Methods: Eight fresh human sacral-pelvic specimens were harvested (average age 78.7 years; bone density 0.75 g/cm²). Screws were placed bilaterally: 7.5 mm diameter by 60 mm long bicortical S1 pedicle screws, 7.5 mm by 60 mm BCBT S2 screws and 7.5 mm by 80 mm iliac screws. Sacral-pelvic constructs were assembled and biomechanical stiffness testing was performed as follows: compression 500 N, flexion/extension 10 Nm, lateral bending 10 Nm, and torsion 10 Nm. (Figure 1) Each specimen was tested first with the BCBT S2 screws and then again with the iliac screws. This sequence was reversed on alternate specimens. The stiffness in each loading mode was calculated and given as a ratio: BCBT S2/Iliac stiffness. Then each BCBT S2 screw and each iliac screw was individually loaded to determine fixation strength.

Results: There was no significant difference in stiffness between the two constructs, although the BCBT S2 construct tended to be stiffer in all modes: compression (stiffness ratio = 1.29), flexion (1.30), extension (1.26), lateral bending (1.29) and torsion (1.20). However the BCBT S2 screws loosened at significantly lower average loads than the iliac screws (compare 435 N against 144 N; p=.02).

Conclusion: The constructs using BCBT S2 screws were as stiff as those using iliac screws. However, the iliac screws provide stronger fixation.

Significance: In terms of stiffness both systems appear to represent viable alternatives to sacral-pelvic fixation. However having a strength advantage, the iliac screws may be preferable in cases of advanced osteopenia and osteoporosis.



Paper #73

Thoracic Pedicle Screw Instrumentation: The Learning Curve In Adolescent Idiopathic Scoliosis

Baron S. Lonner, MD (New York University-Hospital for Joint Diseases); Joshua D. Auerbach, MD; Michael B. Estreicher, BA; Kristin E. Kean, BA

Introduction: Common treatment for adolescent idiopathic scoliosis (AIS) now includes posterior spinal fusion using thoracic pedicle screws (TPS). It is critical to assess the efficacy, safety profile, and learning curve associated with this technique as its use becomes more widespread among inexperienced surgeons.

Methods: Retrospective review of the senior author's first 96 TPS cases for Lenke Type I AIS curves. Multiple regression techniques were used to discern whether increasing case number (CN) was associated with improved perioperative and 2-year minimum radiographic outcomes. The 96 cases were also divided into 4 equal quartiles of 24 cases/group (i.e. Q1-4) and compared using analysis of variance measures.

Results: A total of 1,169 thoracic pedicle screws were placed in 96 patients. After controlling for age, gender, number of levels fused, screw type, screw number, and major curve magnitude, we found a significant correlation between CN and major curve correction at 2 years ($p=0.0002$), an inverse correlation between CN and length of stay ($p=0.02$) and estimated blood loss ($p=0.03$), but no differences were detected in correction of kyphosis, the use of cell saver, or complication rate. Univariate analysis revealed a significant inverse correlation between increasing CN and transfusion rate ($p=0.02$) and operative times ($p=0.0001$). The total number of screws placed (Q1:9.4 vs Q4:16.2, $p<0.0001$), the number of screws/level (Q1:0.98 vs Q4:1.64, $p<0.0001$), and the average time for screw placement (Q1:24.2 vs Q4:11.4 minutes, $p<0.0001$) all demonstrated linear improvement with increasing CN.

Conclusion: Dramatic increases in the #screws/level, total #screws placed, and significant reductions in minutes/screw were seen as late as between the 3-4th quartiles of cases. This suggests a significant learning curve effect in TPS constructs. Increasing case number was associated with improvements in curve correction, length of stay, blood loss, transfusion rate, and operative times, with no difference in complication rate.

Significance: There appears to be a significant learning curve with thoracic pedicle screw instrumentation. Inexperienced surgeons should use extra caution early on and expect a gradual improvement over time in radiographic and clinical outcomes.



Paper #74

The Majority of Initial Coronal Imbalance Following Fusion Surgery for AIS Improves within Six Months

JahanGir Asghar, MD (Shriners Hospitals for Children); Daniel M. Sciubba, MD; Amer F. Samdani, MD; Patrick J. Cahill, MD; David H. Clements, III, MD; M. Darryl Antonacci, MD, FACS; Randal R. Betz, MD; Harms Study Group

Introduction: A substantial percentage of patients with AIS who undergo spinal fusion procedures will exhibit coronal imbalance (>2cm) on initial postoperative erect radiographs. Due to the flexibility of non-instrumented segments in this population, it is often assumed that initial coronal imbalance will improve over time. In this study, patients with initial coronal imbalance were followed to assess the natural history of the imbalance and to identify potential factors associated with failure to correct.

Methods: A retrospective analysis was conducted at a single institution on patients with AIS undergoing spinal fusion from 1998-2005. Patients with radiographic coronal imbalance on initial erect radiographs were identified and serial erect radiographs at 3, 6, 12, and 24 months were evaluated. Parameters collected included: Lenke curve type, Lumbar modifier, fusion levels, stable vertebrae and length of construct, trunk shape analysis, SRS scores, self image scores, and postoperative C7 plumb line to central sacral vertical line (CSVL) distance. Correlation of persistent coronal imbalance with such factors was assessed via logistic regression analysis.

Results: Of 296 patients reviewed for this cohort, 91 patients (30.7%) exhibited coronal imbalance with initial erect radiograph. At 3, 6, 12, and 24 months postoperatively, the number of patients with persistent coronal imbalance fell to 29 (9.7%), 15 (5%), 12 (4.5%), and 14 (4.7%), respectively. Logistic regression analysis revealed no factors associated with failure to return to balance.

Conclusion: In patients with AIS undergoing spinal fusion procedures, initial postoperative coronal imbalance (>2cm) improves dramatically, but such improvement plateaus at 6 months, with 5% still persisting.

Significance: Most patients with AIS undergoing spinal fusion who show initial postoperative coronal imbalance can be expected to spontaneously obtain balance within 6 months. If patients are symptomatic from such imbalance, revision should be considered only after 6 months of observation.

Paper #75

Significance of Intraoperative Thoracic Kyphosis Increase to Prevent the Proximal Junctional Kyphosis in Adolescent Idiopathic Scoliosis Following Posterior Segmental Spinal Instrumentation and Fusion: A Multicenter Analysis of 518 Cases

Yongjung Kim, MD (Hospital for Special Surgery); Lawrence G. Lenke, MD; Keith H. Bridwell, MD; Oheneba Boachie-Adjei, MD; Naobumi Hosogane, MD; Youngbae B. Kim, MD

Introduction: To analyze the effects of intraoperative thoracic kyphosis change on sagittal proximal junctional kyphosis (PJK)

Methods: Standing whole spine lateral radiographs of 518 patients (mean age 14.7 years) who underwent posterior only segmental spinal instrumentation for adolescent idiopathic scoliosis at three institutions with a minimum 2-year (mean 4.5 years) follow-up were evaluated. Instrumentations were hooks only (n=209), hybrid (proximal hooks and distal pedicle screws, n=104), apical sublaminar wiring (hybrid with apical sublaminar wiring, n=88), and thoracic pedicle screws (n=117). Abnormal PJK was defined by proximal junction sagittal Cobb angle between the lower end plate of the uppermost instrumented vertebra and the upper end plate of 2 suprajacent vertebra +15 degrees or more in addition to at least 15 degrees greater than the preoperative measurement at the ultimate follow-up.

Results: Prevalence of PJK as defined at the ultimate follow-up was 12% (62/ 518 patients). Factors which demonstrated a significant correlation with the ultimate PJ angle changes were: immediate postoperative PJ angle changes ($r=0.674$, $p<0.0001$), thoracic kyphosis decrease at ultimate follow-up ($r=0.317$, $p<0.0001$), and immediate postoperative thoracic kyphosis decrease ($r=0.307$, $p<0.0001$). Various parameters such as instrumentation ($r=0.022$, $p=0.613$), thoracic modifier ($r=0.124$, $p=0.005$), and gender ($r=0.122$, $p=0.005$) did not demonstrate a significant correlation after controlling for thoracic kyphosis increase >10 degree. Patients with a minimal 10 degree increase of thoracic kyphosis during operation demonstrated a statistically lower increase (2°) in proximal junctional angle at the ultimate follow up (vs. change<10 degree: 5° increase, $p=0.014$) (vs. decrease>10 degree: 9° increase, $p<0.0001$).

Conclusion: This current study demonstrated the significance of immediate postoperative thoracic kyphosis angle increase to prevent the PJK at the ultimate follow-up in AIS following 4 different posterior only segmental spinal instrumented fusions.

Significance: This current study suggested the way to prevent the PJK at the ultimate follow-up in AIS following 4 different posterior only segmental spinal instrumented fusions.

Paper #76

Elevated Plasma Factor P is Involved in AIS Onset and Curve Progression

Alain Moreau, PhD (Research Center Sainte-Justine University Hospital); Anita Franco, MSc; Bouziane Azeddine, MSc; Pierre H. Rompré, MSc; Isabelle Turgeon, BSc; Keith M. Bagnall, PhD; Benoît Poitras, MD; Hubert Labelle, MD; Charles-Hilaire Rivard, MD; Guy Grimard, MD; Jean Ouellet, MD; Stefan Parent, MD, PhD; Ginette Larouche; Ginette Lacroix

Introduction: We investigated the involvement of Factor P, a multifunctional cytokine regulated by melatonin, in AIS pathomechanism.

Methods: We determined plasma Factor P concentrations in three populations in a prospective manner: patients with AIS, healthy controls without any family antecedent for scoliosis and asymptomatic offspring, born from at least one scoliotic parent and who are considered at risk. A group of 159 consecutive patients with AIS were compared with 33 healthy control subjects and 70 asymptomatic children at risk of developing a scoliosis. Plasma Factor P and soluble Factor P receptor (sFPR) levels were measured by enzyme-linked immunosorbent assay every six month. We also studied genetically modified bipedal C57BI/6j mice devoid of either Factor P or Factor P receptor to validate the contribution of Factor P in the scoliosis pathomechanism.

Results: Mean plasma Factor P concentrations in patients with AIS were significantly higher (p-value <0.001) in patients with AIS having a Cobb's angle >45° (1152.55 ± 378.48 ng/mL) than AIS patients with a Cobb's angle <45° (749.77 ± 313.18 ng/mL) or in healthy controls (561.47 ± 150.77 ng/mL). Diagnostic sensitivity and specificity of Factor P for AIS were 84.4% and 90.9% respectively (cut-off value 800 ng/mL) with an area of under curve value of 0.94. Subgroup analysis showed that 48.6% of children at risk had Factor P values higher than 800 ng/mL (mean value of 1019.61 ± 424.13 ng/mL) as opposed to only 8.6% for the controls. There were no significant differences in mean plasma sFPR levels between all groups. In respect to the pathophysiology of scoliosis, our bipedal C57BI/6j mouse model demonstrated that the development of scoliosis requires Factor P interactions with its receptor as none of the genetically-modified bipedal mice developed scoliosis.

Conclusion: Taken together with experimental data from mice, our clinical data suggest that elevated plasma Factor P concentration triggers scoliosis and could exacerbate curve progression through interactions with its membranous receptors.

Significance: Factor P could be a valuable marker for diagnosis of AIS and prognosis of curve progression although a longer follow-up period is required to validate its usefulness in clinics.

Paper #77

Pre-Operative CT Does Not Appear to Improve Accuracy of Pedicle Screw Placement and Exposes the Patient to Increased Quantities of Radiation.

John Czerwein, MD (Albert Einstein College of Medicine); Terry Amaral, MD; Adam L. Wollowick, MD; Alok D. Sharan; Beverly Thornhill, MD; Vishal Sarwahi, MD

Introduction: The purpose of this study was to compare the safety and accuracy of pedicle screw placement in the thoracic spine with and without the knowledge of pre-op CT scan parameters. Effective doses of radiation are as follows: background radiation: 3 mSiverts/year, routine CXR: .1 mSiverts, routine Scoliosis AP: .15 mSiverts, routine Scoliosis Lateral: .2 mSiverts, CT scan of pediatric spine: 17 - 18 mSiverts. CT scan has 50x more radiation than XR (AP and lateral) and is equivalent to 6 years of background radiation

Methods: 22 patients undergoing spinal deformity surgery were prospectively randomized into two groups. In Group A, the operative surgeon was blinded to pre-op CT findings. In Group B, the surgeon reviewed the CT scan and used the pedicle size, orientation, and morphology in pre-op planning and intra-operatively. Pedicle screws were placed utilizing the free-hand anatomic technique. 5.0 mm or 6.0 mm pedicle screws were placed in the thoracic spine. Screws were placed bilaterally at nearly all levels. Post-operative CT scans were obtained in all patients to evaluate screw placement.

Results: The average patient age was 14.6 years (10-18 years). All patients had idiopathic scoliosis, except one in Group B who had Schuermann's Kyphosis. The average Cobb angle was 50.3° (40-77°). A total of 369 thoracic pedicle screws were placed. 49 screws were mal-positioned. In group A, 18/168 screws were malpositioned (12.5%). In group B, 31/201 screws were mal-positioned (15.4%). The incidence of screw mal-positioning (12.5% vs 15.4%) was similar in the two groups. There was no significant difference between the two groups ($p > 0.05$).

Conclusion: In experienced hands, there is no significant difference in the incidence of pedicle screw malpositioning based upon preoperative evaluation of a CT scan.

Significance: With meticulous technique, safe placement of pedicle screws is possible and can be done without reliance upon pre-operative CT scan. This can decrease total radiation exposure during the course of treatment for spinal deformity.

Paper #78

New Parameters to Represent the Position of the Aorta Relative to the Spine for Pedicle Screw Placement

Katsushi Takeshita, MD (The University of Tokyo); Toru Maruyama, MD; Hiroataka Chikuda, MD; Takashi Ono, MD; Naoki Shoda, MD; Kozo Nakamura, MD

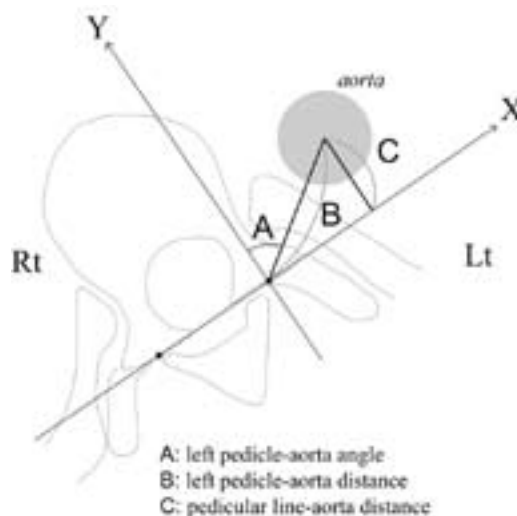
Introduction: Parameters of the position of the aorta in previous reports were determined for anterior surgery. Therefore, surgeons have had difficulty in utilizing these values in placing a pedicle screw. This study evaluated the relative position of the aorta to the spine by new parameters which can enhance the safety of pedicle screw placement.

Methods: Three parameters were defined in a new Cartesian coordinate system (Figure 1). We selected an entry point of a left pedicle screw (the middle of the base of the superior facet) as the origin. A line connecting entry points of both sides was defined as the X-axis. The angle formed by the Y-axis and a line connecting the origin and the center of the aorta was defined as the left pedicle-aorta angle. Length of a line connecting the origin and the edge of the aorta was defined as the left pedicle-aorta distance. Distance from the edge of the aorta to the X-axis was defined as the pedicular line-aorta distance. These parameters were measured preoperatively in 293 vertebral bodies of 24 patients with a right thoracic curve. We defined a potentially dangerous pedicle when the absolute value of an angle fits within 30° AND the pedicular line-aorta distance is less than 40 mm, and calculated the ratio of dangerous pedicles from T4 to L4.

Results: The left pedicle-aorta angle spanned from -46° to 78° (average 16.1°) and the left pedicle-aorta distance ranged from 11 to 72 mm (average 32.9 mm). The pedicular line-aorta distance ranged from -4 to 75 mm (average 27.9 mm). Ratio of dangerous pedicles was highest at T11 with 67%, followed by T4 (63%), T5 (54%), T10 (46%), and T12 (38%).

Conclusion: When a left pedicle screw perforates an anterior/lateral wall of the vertebral body, the aorta may be at risk, especially at T4, T5, and T10-T12. These new parameters enable surgeons to intuitively understand the position of the aorta in surgical planning or in placement of a pedicle screw.

Significance: New parameters clearly show us the dangerous range of the thoracic spine when a pedicle screw perforates the vertebral body.



Paper #79

Intrathecal Morphine Administration for Preemptive Analgesia in Children Undergoing Posterior Spinal Instrumentation and Fusion for Idiopathic Scoliosis

Jochen Son-Hing, MD, FRCSC (Rainbow Babies & Children's Hospital); Paul A. Tripi, MD; Jennifer M. Potzman, MD; Connie Poekochert, RN, BSN, CNP; George H. Thompson, MD

Introduction: Children undergoing posterior spinal fusion (PSF) and segmental spinal instrumentation (SSI) for idiopathic scoliosis (IS) may experience severe postoperative pain. Although others have examined the effectiveness of intraoperative intrathecal morphine administration for postoperative analgesia, no study has established an optimal dose. The purpose was to identify an optimal dose of intrathecal morphine.

Methods: We reviewed the results of 407 patients receiving intrathecal morphine for IS undergoing PSF and SSI at our institution. Following induction of general anesthesia and prior to surgical incision, patients received preemptive neuraxial analgesia. There were 3 groups based on dose: no dose (0 µg/kg); moderate dose (9-19 µg/kg); and high dose (20 µg/kg). Factors analyzed included postoperative pain scores measured by visual analog scale (VAS), time to first opioid rescue dose, and postoperative complications including respiratory depression and PICU admission.

Results: There were 68 patients in the no dose (ND) group, 293 patients in the moderate dose (MD) group, and 46 patients in the high dose (HD) group. Mean VAS pain scores in PACU were 5.14, 0.49, and 0.15, respectively. Mean times to first opioid rescue dose were 398.18, 999.66, and 1375.00 minutes, respectively. Respiratory depression occurred in 8 (2.7%) MD and 7 (15.2%) HD patients. PICU admission occurred in 9 (3.0%) MD and 8 (17.4%) HD patients. Analysis of variance (ANOVA) demonstrated a significant difference ($p=0.0001$) between ND, MD, and HD VAS scores; post hoc analysis showed a difference between ND and MD groups, not MD and HD. There was a significant difference ($p=0.0001$) for mean time to first rescue dose; post hoc analysis showed a difference between ND and MD, and MD and HD. Z-test for two proportions showed significantly fewer incidents of respiratory depression and PICU admission in the MD versus the HD group.

Conclusion: Intrathecal morphine in doses of 9-19 µg/kg provides effective and safe postoperative pain relief in children undergoing PSF and SSI.

Significance: Higher intrathecal morphine doses allow a longer interval until first opioid rescue dose, but provide no added benefit to VAS scores and increase complications such as respiratory depression and PICU admission.



Paper #80

Halo-Gravity Traction in Severe Pediatric Spinal Deformity

Kristina Walick, MD (Texas Scottish Rite Hospital); Anna McClung, RN; Daniel J. Sucato, MD, MS; Charles E. Johnston, MD

Introduction: Halo-gravity traction (HGT) has been used as adjunctive treatment for severe pediatric spinal deformity.

Methods: 50 HGT patients treated 1997-2007 were reviewed. Pretraction, early and final traction xrays were measured for major curve Cobb, T1-12 height, trunk shift (C7-CSVL + Floman), sagittal parameters/balance. Pts were divided into 3 groups: group 1: < age 8, no prev Rx; group 2: >8, no prev Rx; group 3: revision s/p prev Rx. Avg time in traction was 13.3 weeks (range 1.3-41).

Results: 40 pts had scoliosis as main deformity. Group 1 (n=17, mean age 5.5, initial Cobb range 76-108°) corrected 31% pre-tn to final; group 2 (n=12, age 12.9, initial range 74-160°) corrected 30.5%; group 3 (n=11, age 11.3, initial range 70-121°) corrected 24.5%. Mean correction during traction (early-final) was 10.8, 9.6, 6.8% respectively. Floman trunk correction was 48.5, 53.7, 24.5% respectively, while C7-CSVL corrected 15.6, 30.4, 36.8%. Increase in T1-12 height was 15, 22.1, 30.2%. No measures between groups were significant, although pts with neuromuscular or other etiologies obtained correction faster than idiopathic (p<0.05). 10 other pts with main deformity kyphosis and 19 of 40 scoliosis pts with >70° kyphosis were analyzed for kyphosis outcome. Group 3 pts (initial range 71-140°) had 31% Cobb correction compared to 8% group 1 (initial 91-108°) and 3% group 2 (initial 70-134°). T1-12 height increased 15-24%, no diff between groups. PFTs for all 50 pts improved 4-13% (pred), with no group diff. Complications: 7 cases of pin problems, 2 falls requiring pin revision, 2 cases of neurologic deficit - 1 not resolving on d/c of traction.

Conclusion: Patients of all ages, etiologies, and prev Rx respond to HGT with mean Cobb correction 30%, increase T1-12 height and improved trunk shift. We found no correlation between groups and xray improvement. Pts with previous fusion can equally benefit from HGT prior to further revision.

Significance: HGT should be considered an effective adjunctive treatment for severe pediatric spinal deformity in all ages, etiologies, and even those with prior surgery needing revision.

Paper #81

Is Extended Preoperative Halo Traction Safe and Effective for Severe Pediatric Spinal Deformity? Critical Review of 62 Pediatric Patients

Timothy R. Kuklo, MD, JD (Washington University); Kathryn A. Keele, MD; Laura A. Meyer, MA; Scott J. Luhmann, MD; Keith H. Bridwell, MD; Lawrence G. Lenke, MD

Introduction: To determine the preoperative efficacy and complication rate of prolonged halo traction for severe pediatric spinal deformity.

Methods: We reviewed the inpatient medical records and radiographs of 62 consecutive pediatric pts treated at a single institution from 1998-2007 with extended preop halo traction and a standard traction protocol (in bed, wheelchair, and treadmill when possible) from 1998-2007. Diagnoses included severe kyphoscoliosis (19), congenital scoliosis (11), neurofibromatosis (7), infantile (6), syndromic (5), neuromuscular (4), Marfan's (2), myelomeningocele (2), juvenile (2) and SMA (1). In addition to standard demographics, evaluation included ht/wt, traction weight and % total body weight (TBW), duration, complications, % major curve correction, and PFTs (pre-halo and preop FVC and FEV1).

Results: Complete records were available on 59 patients (26M,33F; age 12.0±4.8 yrs, range 4 mos-20yrs). Days in traction was 60.6±32.1 (range 17-167 days) at an average of 39% TBW (range 11-68%) using a standard of 6 pins. 17 temporary minor complications (16 considered halo related) occurred in 14 pts (24%); 4 required a decrease in traction wt. (2 temporary, 2 permanent). Complications included nystagmus (5, all less than 2 days), upper extremity numbness (4), pin site erythema (4), pin site infection/pin removal (1), neck pain (1), unilateral miotic pupil (1). One pt developed heel cord tightness that was not considered secondary to halo traction. There were no neurologic complications. Major coronal curve correction improved on ave. 42° (160° to 118°, 26%), sagittal 66° (177°-111°, 37%). PFTs (pre-halo and preop) were obtained in 34 pts. (25 unable to perform) - 28 demonstrated improved FVC (48% to 59±29%, p=.00) and 6 no change, while FEV1 similarly improved in 32 pts (45%-58%, ±28%, p=.00) and no change in 2 pts.

Conclusion: There were no major neurologic complications and only a 24% temporary minor complication rate (14/59 pts) with prolonged preop halo traction. In addition, PFTs significantly improved in the vast majority of these challenging patients, while the major curve improved by 26°. This "benefit" is of particular importance, especially in a susceptible population.



Paper #82

A 13-14 Year Follow Up of Outcome for Fusions in Idiopathic Scoliosis

Colin Nnadi, FRCS(Orth) (Queens Medical Campus); Prakash Jayakumar, MRCS; Satoshi Hori, BSc, MB, BS, MRCS; Adrian Casey; David Harrison, FRCS; Ben Taylor; Dimitri A. Raptis, MRCS

Introduction: Corrective Scoliosis surgery has evolved since the introduction of the Harrington instrumentation system. Newer techniques of correction involve the use of segmental instrumentation which improves 3-dimensional correction. Previous studies have based outcome assessments of surgery on the older instrumentation systems such as the Harrington system using objective parameters such as radiographic data and health related quality of life measures. We now know that some of these parameters are only weakly linked to outcomes more relevant to patients. Health related quality of life assessments have addressed this issue considerably but still retain the drawback of not being specific to the condition being assessed. We have used a validated and reliable disease specific questionnaire to evaluate outcome.

Methods: Over a 2 year period from 1993 to 1994, 101 patients with a diagnosis of Adolescent Idiopathic Scoliosis who had undergone surgery in a tertiary institution in the UK were identified. These patients were recontacted and evaluated using the Modified Scoliosis Research Society Questionnaire. Correlations between patient generated data and outcome were also evaluated.

Results: There was an overall general satisfaction with surgery. No correlation was found between patient generated data and outcome except in patients with posterior instrumentation extending proximal to T4 vertebra. In this group of patients the outcome scores in 4 out of 5 domains of the questionnaire were significantly better than in other groups.

Conclusion: Using a disease specific questionnaire to evaluate surgically treated Idiopathic Scoliosis we have identified the proximal extent of the fusion as the single variable to affect outcome. This contrasts with previous work which has focused on the distal extent of fusion. We have also shown that the Harrington system, contrary to opinion, compares favourably with the more modern instrumentation systems.

Significance: The strength of our study is the focus on patient based evaluation of the effects of scoliosis surgery. Surprisingly, there are no significant differences in outcome between older and more modern corrective techniques despite the perceived theoretical advantages of the latter.

Paper #83

Fixation Points within the Main Thoracic Curve: Does More Instrumentation Produce Greater Curve Correction?

James O. Sanders, MD; Mohammad Diab, MD (UCSF); B. Stephens Richards, III, MD; Lawrence G. Lenke, MD; Charles E. Johnston, MD; John B. Emans, MD; Daniel J. Sucato, MD, MS; Mark A. Erickson, MD; Keith H. Bridwell, MD; Richard E. McCarthy, MD; John F. Sarwark, MD; John P. Dormans, MD; Timothy R. Kuklo, MD, JD; Michael R. Shainline, MS; Spinal Deformity Study Group

Introduction: The enhanced mechanical purchase on the spine from segmental fixation of scoliosis should increase the overall corrective force implants can exert without bone failure. This study evaluates whether this translates into additional correction beyond that expected from preoperative bending radiographs in thoracic curves where maximum correction was feasible (1A, 1B, and nonselective fusions of 1C).

Methods: 177 Lenke type 1 curves (118 1A, 36 1B, 23 1C) with two year follow-up were evaluated for correction relative to preoperative side bending films. The number and type of individual fixation points within the main curves were compared to the correction obtained on the bend films. SRS scores were also compared relative to the amount of correction obtained.

Results: The number of fixation points both within the curve ($p=0.01$) and for each vertebral body ($p=0.002$) was significantly larger for curves with greater correction compared to the bend films than those with less correction. When comparing fixation type, overall correction was best for all screw constructs followed by screw and wire, hook and screw, and least with all pure hooks. However, when compared to the bend films, these differences were not significant ($p=.132$). The SRS scores significantly improved from preoperative to two year postoperative ($p<0.001$), and this was more notable for the all screw constructs than other instrumentation patterns ($p=0.023$). However, there were no significant difference in this improvement between those correcting more and those correcting less than the bend films ($p=0.578$).

Conclusion: Absolute curve correction improved most with all pedicle screw constructs, but, when compared to bending films, the number of fixation points is more important than whether the construct uses screws, hooks, or wire combinations. SRS scores improved the most in those with all screw constructs, but the SRS scores did not relate to whether curve correction was more or less than the bend films.

Significance: Curve correction in Lenke 1 curves is improved relative to the preoperative bending by more fixation points. With any of the studied fixation techniques, SRS scores are improved and unrelated to correction relative to the bend films.



Paper #84

‘Don’t End Your Fusion at T12 in Idiopathic Scoliosis’: Wisdom or Myth?

John M. Flynn, MD (Children’s Hospital of Philadelphia); Tracey P. Bastrom, MA; Peter O. Newton, MD; Lawrence G. Lenke, MD; Alvin H. Crawford, MD; Thomas G. Lowe, MD; Randal R. Betz, MD; David H. Clements, III, MD; Baron S. Lonner, MD; Michelle C. Marks, PT, MA; Harms Study Group

Introduction: The 12th thoracic vertebra has unique facet anatomy, representing a transition between the more rigid thoracic spine and the more flexible lumbar spine. According to conventional wisdom, instrumented posterior fusions ending at T12 have a higher risk of post-operative problems. Is this true? Has it changed now that the distal anchor is typically a pedicle screw?

Methods: From a multi-center AIS database, we identified every Lenke 1 or 2 PSF, min. 2 yr f/u, in which the last instrumented vertebra (LIV) was T10, T11, T12 or L1. 3 groups (above:T10/11, junction:T12 and below:L1) were analyzed.

Results: 159 cases had 2 yr f/u. See Table. Thoracic curve correction was sig. better when the LIV was L1 v. T12 (p=0.001), despite the pre-op Cobb being sig. larger in the L1 cohort (p=0.03). The change in T10-L2 kyphosis was sig. greater with T12 as the LIV (p=0.026). Repeated measures ANOVA revealed a sig. difference in distal junctional kyphosis (DJK) between the three groups (p=0.04): fusion at all levels was kyphogenic at first f/u; however, with an LIV at T10/T11 or L1, kyphosis decreased or stabilized over 2 yrs, while cases fused to T12 became more kyphotic. At 2 yrs, a higher % of cases were >2cm out of coronal balance when the LIV was thoracic (did not reach significance). When the LIV was T12, anchor choice significantly mitigated the risk of DJK (hook 8° v. screw 4°, p=0.048) and disc angulation (p=0.023). There was no sig. difference in instrument-related complications or re-operation.

Conclusion: This data supports conventional wisdom: in Lenke 1 or 2 curves, choosing an LIV of L1, rather than T12, results in less DJK, less T10-L2 kyphosis, better correction of Cobb angle, and perhaps a lower likelihood of poor coronal balance at 2 years post-op. Using screws rather than hooks as the most distal anchor may mitigate some of this risk.

Significance: When planning a fusion for AIS, choosing T12 as the LIV carries risks that should be balanced against other factors.

LIV	# of patients	Thoracic curve		T10-L2 kyphosis		DJK		Percent that were > 2 cm out of coronal balance 2 yrs post-op
		pre-op	2 yrs post-op	pre-op	2 yrs post-op	pre-op	2 yrs post-op	
T10/T11	19	52°	21°	-4°	3°	0°	4°	26.30%
T12	50	50°	23°	0°	8°	0°	5°	20.00%
L1	90	55°	20°	-2°	2°	-3°	0°	11.10%

* The FDA has not cleared a drug and/or medical device in use described in this presentation (i.e., the drug or medical device is being discussed in an off-label use). For full information see page 10.

Paper #85

***Quality of Life in Adult AIS Patients - Comparison Between Untreated and Brace Treated Patients**

Aina J. Danielsson, MD, PhD (Sahlgrenska University Hospital); Ralph Hasselius, PhD; Acke Ohlin, MD, PhD; Alf Nachemson, MD, PhD

Introduction: The previously performed prospective SRS brace study included two consecutive series of immature patients with AIS of moderate curve size (Cobb 25-35). The radiographic outcome on curve changes has been presented; curves of neither brace treated nor observed only patients increased significantly during mean 16 years after maturity. By using quality of life measurements for outcome studies, the patients own subjective view can be recorded.

Purpose: The aim was to analyse and compare quality of life in adulthood between AIS patients observed only or brace treated during adolescence, respectively. Results using the SRS-22 questionnaire have never before been presented for AIS patients without treatment.

Methods: 77 out of the original 100 patients attended the complete follow up, 40 observed only and 37 brace treated patients. This included clinical and radiological examination and completion of two quality of life questionnaires (SRS-22 and SF-36). Translation and validation of the SRS-22 for use in Sweden was performed as part of the study.

Results: No differences between the groups in terms of age at FU (mean 32 y), follow-up time after completed treatment/maturity (mean 16.0 y), curve size at inclusion (mean 30°) or at follow up (mean 35°, 19°- 48°) were observed.

The SRS-22/ total score was mean 4.2 (SD 0.4, 3.1-5.0) for braced patients and 4.1 (SD 0.5, 2.7-5.0) for observed only patients. Neither total scores nor subscales differed significantly between the groups.

Both previously braced and observed only patients had the same quality of life as measured by SF-36 and no differences compared to the Swedish age-matched norm scales were found.

Conclusion: Patients not having received any active treatment during adolescence for moderate AIS report a good quality of life in their 30's, as measured both by SRS-22 and SF-36. Patients having been braced for curves of similar size had a concurrent level of quality of life. None of the groups showed any difference compared to the age matched norm groups for SF-36.

Paper #86

The Association Between the SRS-22 and Scoliosis Severity Changes at a Clinically Relevant Threshold

Eric C. Parent, PT, MSc, PhD (University of Alberta); Daniel L. Wong; Douglas L. Hill, P.Eng, MBA; James Mahood, MD; Marc Moreau, MD, FRCS(C); Jim Raso, MAsC; Edmond Lou, PhD

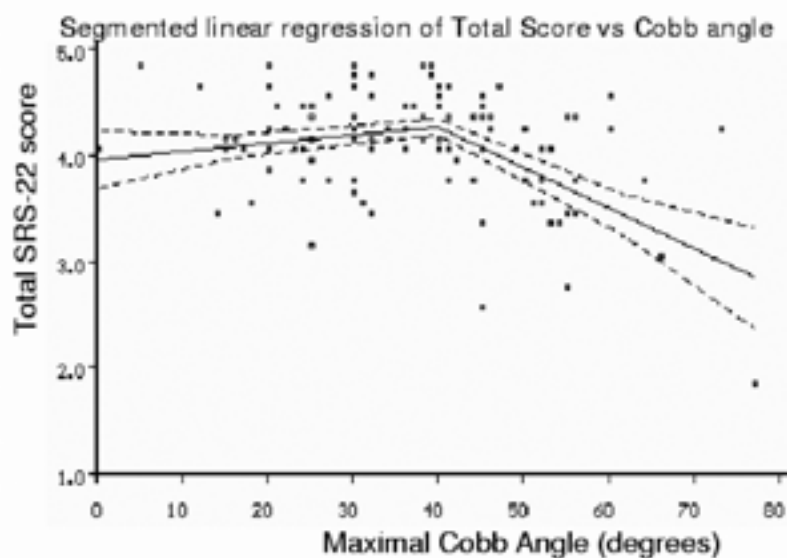
Introduction: The associations between health-related quality-of-life (HRQOL) and scoliosis deformity measures are at best moderate when assessed using linear regressions. This may be because HRQOL is not affected until a severity threshold is reached. Identifying the thresholds in deformity beyond which HRQOL deteriorates may assist with treatment prescription. The goal was to determine the thresholds in spinal deformity measures beyond which increases in severity are more strongly associated with declines in HRQOL as measured by the SRS-22.

Methods: The SRS-22 questionnaire was completed by 101 females with adolescent idiopathic scoliosis (age 15.0 ± 1.8 years, maximal Cobb angle $36.9^\circ \pm 14.6^\circ$). Radiographs and surface topography were used to quantify the severity of the internal (maximal Cobb angle) and external deformity (cosmetic score, decompensation, trunk twist), respectively. Segmented linear regression models were used to determine the association between SRS-22 domains and spinal deformity measures. This analysis also identified deformity thresholds beyond which SRS-22 HRQOL is more affected. The percentage of variance explained (R) by linear and segmented models were compared ($p < 0.05$) to identify the best approach.

Results: Cobb angle predicted significantly more variance in all SRS-22 domains except mental health using segmented models (R 0.09 to 0.30) than linear models (R 0.02 to 0.21). Segmented models with a single threshold estimated at between 43° and 48° predicted between 3 and 11 additional percent of variance compared to corresponding linear models using the same variables. Surface topography parameters were not strongly associated with SRS-22 variables with linear and segmented models, explaining less than 10% of the variance.

Conclusion: Deterioration of HRQOL as measured by the SRS-22 questionnaire is mildly associated with increases in the severity of the internal deformity. HRQOL is stable until the curve reaches a maximal Cobb angle threshold at 45° where HRQOL declines linearly with increasing internal deformity (Figure).

Significance: The association between HRQOL and scoliosis severity was better explained by segmented than linear models.



Paper #87

Hospital Costs Associated with Surgical Treatment of Adolescent Idiopathic Scoliosis

Charles T. Mehlman, DO, MPH (Cincinnati Children's Hospital Medical Center); Jun Ying, PhD; Cassie L. Kirby, BA

Introduction: Posterior spinal fusion (PSF) is the most common surgical treatment for AIS. The purpose of this study was to analyze the hospital costs associated with PSF treatment for AIS and to assess potential regional differences (Northeast, Midwest, South, and West) using a large national (USA) database.

Methods: The Healthcare Cost and Utilization Project (HCUP) KID database was used to study hospital costs associated with AIS pts (ICD-9 737.30) undergoing PSF (ICD-9 81.05) during the years 1997, 2000, and 2003. Exclusion criteria included co-morbid diagnoses related to neurologic dysfunction, connective tissue abnormalities, or genetic defects, age < 10 or > 18 years, or a hospital length of stay > 2 wks. Costs were adjusted for inflation using the consumer price index (CPI) from the U.S. Department of Labor and standardized to 1997 dollars. Data was analyzed using analysis of variance (ANOVA) models (with Bonferroni's correction) via a SAS callable SUDAAN software package.

Results: A total of 9,013 AIS patients that met our inclusion criteria underwent PSF during the three years studied. Demographically the study population was 76% female, 65% white, and 17% black. The inflation adjusted average costs were \$31,200 (SD 400) in 1997, \$37,100 (SD 500) in 2000, and \$56,700 (SD 700) in 2003. These were statistically significant cost increases ($p < 0.001$). Regional subgroup analysis revealed that the greatest hospital costs were associated with the West region ($p < 0.001$).

Conclusion: Our results indicate that in recent years significant increases in the hospital cost of PSF for AIS have occurred that greatly exceed those expected from inflation alone.

Significance: Within the context of the 7 year time frame covered by this study, scoliosis surgery has become more than 80% more expensive. We are unaware of commensurate improvements in patient-level outcome measures during this same time period.



Paper #88

Change in Thoracic Sagittal Alignment Following Posterior Instrumentation for Lenke 1A and B Curves

James O. Sanders, MD (University of Rochester); John P. Dormans, MD; Timothy R. Kuklo, MD, JD; Lawrence G. Lenke, MD; B. Stephens Richards, III, MD; Charles E. Johnston, MD; Daniel J. Sucato, MD, MS; John B. Emans, MD; Mohammad Diab, MD; Michael R. Shainline, MS; Spinal Deformity Study Group

Introduction: Modern segmental instrumentation is very effective in coronal curve correction, but the effects of various types of posterior segmental instrumentation on sagittal correction is unknown. The purpose of this study was to evaluate the sagittal mechanical effects of various instrumentation types in patients with single thoracic curves (Lenke 1A and 1B) adolescent idiopathic scoliosis.

Methods: 165 patients with adolescent idiopathic Lenke 1A or B curves treated surgically were evaluated for their preoperative and two-year postoperative T5-T12 sagittal contour. Instrumentation was classified as screws only, hooks only, screws and hooks, and hybrid. The category of "hooks and screws" principally used screws distally and hooks proximally while hybrids used sublaminar wires along with other anchor types. Sagittal alignment was classified according to the Lenke modifiers

Results: Postoperative, 106 (64.2%) showed no change in sagittal classification. 4 (2.4%) changed from N to plus, 14 (8.5%) from N to minus, 14 (8.5%) from plus to N, and 27 (16.4%) from minus to N. No patients went from minus to plus or plus to minus. There were no significant changes between 1 and 2 yr follow-up ($p = .509$), but significant variation in change in main thoracic Cobb angle from preop to two years by change in thoracic sagittal modifier group ($p=.012$). Patients who remained hyperkyphotic had significantly less coronal curve correction (mean=27.5 degrees, +/- 10.8) when compared to those who went from hyperkyphotic to normal (mean=45.6 degrees, +/- 12.5) ($p<.02$). Changes in sagittal classification by instrumentation type are shown in the table. This was statistically significant for screws only (increased lordosis $p=0.006$), and for hybrids (increased kyphosis $p=0.002$).

Conclusion: A large majority of patients did not change their sagittal modifier regardless of the instrumentation used. In general, screws (screws only) have a lordosing tendency while wires (hybrid) have a kyphosing tendency compared to hooks, and screws plus hooks.

Significance: Surgeons should recognize the kyphosing tendency of wires and the lordosing tendency of thoracic pedicle screws when planning their operative curve correction strategy.

Paper #89

Preservation of Thoracic Kyphosis: A Critical Component to Maintaining Post-Operative Lumbar Lordosis during the Surgical Treatment of Adolescent Idiopathic Scoliosis

Vidyadhar V. Upasani, MD; Peter O. Newton, MD (Rady Children's Hospital and Health Center); Jeff B. Pawelek, BS; Tracey P. Bastrom, MA; Lawrence G. Lenke, MD; Thomas G. Lowe, MD; Alvin H. Crawford, MD; Randal R. Betz, MD; Baron S. Lonner, MD; Harms Study Group

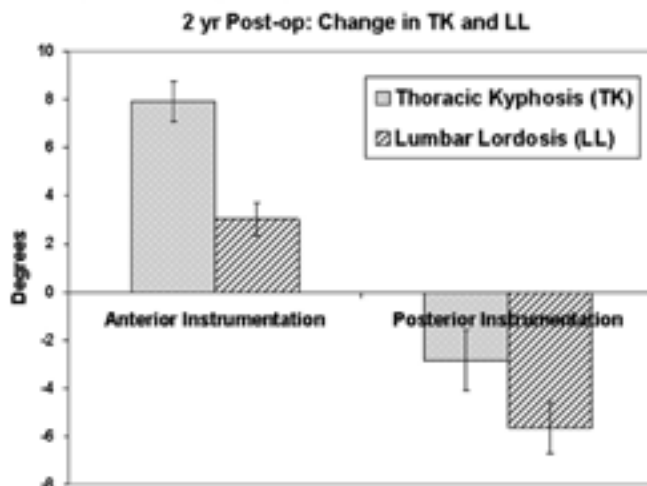
Introduction: With the increasing popularity of segmental pedicle screw spinal instrumentation, there is a tendency to sacrifice thoracic kyphosis (TK) in order to achieve coronal and axial plane correction. The purpose of this study was to evaluate the sagittal profile of surgically treated adolescent idiopathic scoliosis (AIS) patients.

Methods: First-erect, one-year and two-year post-op radiographs of AIS patients with a Lenke type 1 deformity and minimum 2-year follow-up after a selective thoracic fusion (lowest instrumented vertebra of T11, T12 or L1) were evaluated. Changes in TK were correlated with changes in lumbar lordosis (LL) at each visit using Pearson's correlation analysis ($p < 0.05$). The patients were then sub-divided according to approach (open/thoracoscopic anterior versus posterior) and an ANOVA was used to compare pre- and post-op radiographic measures ($p < 0.05$).

Results: 251 patients (age: 14 ± 2 years) were included in this analysis. 67% of the patients had an anterior surgery (97 open anterior, 71 thoracoscopic) and 33% (83 patients) had a posterior spinal fusion. A decrease in post-op TK was significantly correlated ($p = 0.001$) with a decrease in LL at the first-erect ($r = 0.3$), one-year ($r = 0.4$) and two-year ($r = 0.4$) visits, independent of surgical approach. LL decreased significantly at the first-erect visit regardless of approach ($p = 0.003$); however at 2-yrs post-op TK and LL were significantly decreased after a posterior approach ($p = 0.001$) as compared to an anterior approach which added kyphosis (Fig 1). Of note, the decrease in LL ($5.6 \pm 9.7^\circ$) was nearly twice the decrease in TK ($2.8 \pm 11.4^\circ$) in the posterior group at 2-years post-op.

Conclusion: Given that thoracic AIS is often associated with a preexisting reduction in TK; ideally surgical correction should address this deformity. Procedures which further reduce TK also reduce LL. It is unclear if the loss of LL from thoracic scoliosis correction will compound the loss of LL that occurs with age; leading to further decline in sagittal balance. With this concern, we recommend a posterior column lengthening and/or an anterior column shortening during the surgical correction of thoracic AIS to achieve restoration of normal TK and maximal LL.

Figure 1: 2-year post-op change in thoracic kyphosis (TK) and lumbar lordosis (LL) by surgical approach (average \pm SEM).





Paper #90

3D Sub-Classification of Lenke 1 Curves

Archana Sangole, PhD (Ecole Polytechnique); Carl-Éric Aubin, PhD, P.Eng; Hubert Labelle, MD; Lawrence G. Lenke, MD; Ian A. Stokes, PhD; Peter O. Newton, MD; Roger P. Jackson, MD

Introduction: Scoliosis is recognized to be a three-dimensional (3D) deformity of the spine. Yet, its measurement and classification have predominantly been based on radiographic assessments which are 2D projections in the coronal and sagittal planes. The general objective of this study was to develop a multi-dimensional scheme to classify the scoliotic spine. As a first attempt, the specific aim was to investigate the presence of sub-groups within the Lenke type-1 curves.

Methods: 172 patients with right thoracic adolescent idiopathic scoliosis (AIS), reviewed by the 3D Classification Committee of the SRS, were evaluated using 3D reconstructions of upright PA and lateral radiographs. The evaluated indices in the main thoracic segment were: Cobb angles, orientation of the plane of maximum curvature (PMC), axial rotation of the apical vertebra, and constrained thoracic kyphosis (T4-T12). The ISOData unsupervised clustering algorithm was applied to determine the optimal classification scheme.

Results: The optimal solution provided 3 subgroups; the orientation of the PMC being the primary discriminator. The first group was smaller (22 cases) with mainly non-surgical cases (mean Cobb: $22^{\circ} \pm 10^{\circ}$). The remaining 2 groups (G2=79, G3=71 cases) consisted of thoracic curves with overlapping Cobb angles (G2= $51^{\circ} \pm 10^{\circ}$; G3= $41^{\circ} \pm 14^{\circ}$) but distinct PMC orientations (G2: 65° - 81° ; G3: 76° - 104° with respect to the sagittal plane) and kyphotic values (G2: 23° - 43° ; G3: 7° - 25°). Fig. 1 illustrates representative cases from G2 and G3 that appear similar in the coronal plane but are in fact different when viewed in the sagittal and transverse planes.

Conclusion: Two distinct sub-groups were identified in Lenke 1 surgical curves that exhibited different PMC and showed that these curves are not always hypokyphotic.

Significance: Cluster analysis of 3D characteristics highlighted structural differences and 3D spinal complexities that were not clearly apparent in single radiographic planes. Should different instrumentation strategies be adapted to those specific characteristics is yet to be determined.

Paper #91

Treatment Outcome and Patient's Acceptance of a Dynamic corrective Brace Vs Rigid Bracing System for AIS Girls - A Randomized Controlled Trial with Follow Up Till Skeletal Maturity

Tsz-ping Lam, MB, BS; Man-sang Wong, PhD; Bobby Kin-wah Ng, MD (The Chinese University of Hong Kong); Sai-wing Sin; Hoi-kei Rachel Kwok; Lai-fong Sandra Shum; Prof. Daniel Hung-kay Chow; Jack Chun Yiu Cheng, MD

Introduction: SpineCor was a relatively new bracing system designed for comfort, appearance and compliance. Coillard et al and Weiss et al reported different treatment results; otherwise, very few reports regarding its use were available. To better understand the role of SpineCor for AIS, we studied its effectiveness and patient's acceptance using rigid braces as controls.

Methods: This was a prospective randomized controlled trial on 22 SpineCor and 21 rigid-brace subjects who were skeletally immature AIS girls. All patients were managed by a dedicated team according to a standardized protocol at a special clinic. The average follow up since bracing was 67 months (range: 46 to 80). All subjects have now reached skeletal maturity. Clinical, anthropometric and radiographic assessments were made once every three months. Levels of patient's acceptance and satisfaction were assessed with a visual-analog scale on 16 items at the 3rd, 9th and 18th months of orthotic intervention. Bjure and Nachemson's adjustment was employed for the anthropometric data. An increase of Cobb's angle > 5 degrees within brace was considered a failure.

Results: The mean age, mean Risser and mean initial Cobb's angle for the SpineCor and rigid-brace groups were 12.3 and 12.6, 0.55 and 0.24, 24.0 and 24.4 respectively. 2 SpineCor and 3 rigid-brace subjects defaulted follow up. There were 7 failures in the SpineCor and 1 failure in the rigid-brace group (p=0.022 with the Log Rank test). Apart from item 1, 7 and 14 (see table), patient's acceptance and satisfaction were similar between the two groups. At the time of curve progression with SpineCor, the corrected Standing Height, Sitting Height and Armspan were 99%, 98% and 99% of their final values. It followed that curve progression was still observed with SpineCor at the late phase of the growing period.

Conclusion: SpineCor seemed to give a less favourable result for curve control when compared with the rigid brace. Patient's acceptance was similar between the two groups except for item 1, 7 and 14. A larger study was required for defining the role of SpineCor in treating AIS.

Significance: This report serves as an important reference when braces are used to treat AIS.

Mean percentage of Visual Analog Scale (VAS) score in the feedback survey.

Questions		Mean Percentage of VAS Score (%)					
		SpineCor Group (n=22)			Rigid Brace Group (n=21)		
		3 rd month	9 th month	18 th month	3 rd month	9 th month	18 th month
1	Pain score	26.4	22.0	39.1*	23.9	22.8	20.7*
2	Skin irritation	16.2	16.3	21.3	27.5	16.4	25.3
3	Pressure sore	24.0	17.4	28.6	20.8	22.8	25.7
4	Limitation of upper limb movement	26.0	25.5	33.5	20.2	28.0	32.9
5	Problems with breathing	16.0	19.4	30.5	26.4	31.5	27.4
6	Problems with traveling	20.3	11.9	28.3	16.4	24.9	22.7
7	Problems with writing & reading	7.1	2.4*	13.1	14.0	15.3*	12.0
8	Problems with sports	39.4	42.6	44.5	30.6	47.8	44.1
9	Problems with hygiene	34.1	33.5	36.5	21.4	30.7	16.1
10	Problem with sleeping	18.0	18.8	29.9	13.4	14.4	15.8
11	Problem with full stomach	36.6	43.7	47.8	36.1	44.8	48.3
12	Problems with dressing	32.2	33.3	43.5	34.8	42.1	42.2
13	Problems with walking	15.2	11.7	20.8	8.7	15.2	15.1
14	Problems with toileting	50.3*	60.8	55.9*	23.1*	31.7	24.4*
15	Difficulty with donning & doffing	14.0	13.5	17.4	17.0	23.6	22.5
16	General dislike	55.2	69.2	73.3	73.4	64.1	60.5

Remarks:
* = Significant difference (p<0.05) found between 2 subject groups (Mann-Whitney Test)

* The FDA has not cleared a drug and/or medical device in use described in this presentation (i.e., the drug or medical device is being discussed in an off-label use). For full information see page 10.

Paper #92

Relative Contributions of Discal and Vertebral Wedging To Cobb Angle Progression During the Adolescent Growth Spurt

Ryan Will, MD; Ian A. Stokes, PhD; Xing Qiu, MD; Matthew Walker, MD; James O. Sanders, MD (University of Rochester)


Introduction: Both disc wedging and vertebral body wedging are found in progressive scoliosis, but their relative contribution to curve progression over time is unknown. Which occurs first is important for understanding how scoliosis progresses and for developing methods to halt progression. Previous studies have not properly identified maturity and provide conflicting results.

Methods: 18 girls were followed through their adolescent growth spurt with serial spine and hand skeletal age radiographs. Each Cobb angle was partitioned into the relative contribution of the disc and vertebral body wedging. The corresponding hand radiographs provided a measure of maturity level (Digital Skeletal Age = DSA). The disc versus bone contributions to the Cobb angle were then compared prior to the growth spurt, during the early growth spurt (DSA=375 corresponding to Risser 0, open TRC), late growth spurt (DSA=450 corresponding to Risser positive), and after the growth spurt (Figure 1). Significance of relative changes was assessed by using the Wilcoxin two-sided mean rank test.

Results: Prior to the growth spurt, there was no difference in relative contributions of the bone and the disc ($p=0.38$) to curve progression. During the growth spurt, the mean disc component progressed significantly more than that of the vertebrae ($p=0.0002$). This reversed following the growth spurt with the vertebral component progressing more than the disc ($p=0.01$).

Conclusion: On average, and in the majority of subjects, the scoliosis initially increased through increased disc wedging during the rapid growth spurt with progressive bone wedging occurring later.

Significance: This is the first study to distinguish between contributions and vertebral and discal wedging to curve progression at various points in the growth spurt. The disc and surrounding tissues are implicated in initial rapid curve progression, with bony deformation occurring afterwards.



Paper #93

Post Operative Trunk Flexibility Loss is Modest but Incremental as the Fusion Progresses Distally

Peter O. Newton, MD (Rady Children's Hospital); Michelle C. Marks, PT, MA; Tracey P. Bastrom, MA; Randal R. Betz, MD; David H. Clements, III, MD; Baron S. Lonner, MD; Alvin H. Crawford, MD; Lynn Letko, MD; Harry L. Shufflebarger, MD; Michael F. O'Brien, MD

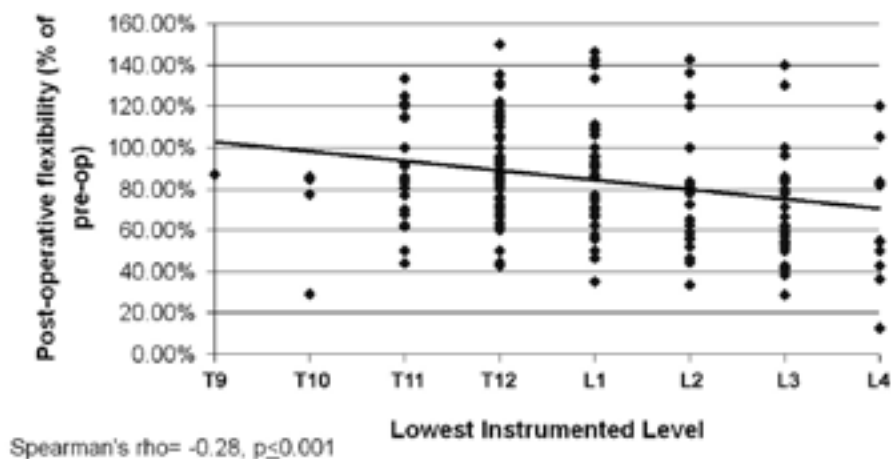
Introduction: After curve stabilization, motion preservation is a primary aim of spinal fusion. The purpose of this study was to evaluate the relationship between post-operative flexibility and the lowest instrumented vertebrae (LIV) in a spinal fusion.

Methods: Clinical trunk flexibility measurements were obtained pre-operatively and at 2 years post-operatively on adolescent idiopathic scoliosis (AIS) patients included in a prospective AIS database. The data for patients with Lenke 1, 3, or 6 curve patterns were used to evaluate the relationship between the 2 yr trunk flexibility (expressed as a percentage of the pre-operative measure) and the LIV. Trunk motion was assessed in flexion and lateral bending with a fingertip to floor measurement. Spearman's rho correlation coefficient was employed ($p=0.05$).

Results: The data for 177 patients, 148 females and 29 males (age: 15 ± 2 years) were included in this analysis. Despite a wide variation in data, the post-operative trunk flexibility was negatively affected the more distal the instrumentation progressed ($r = -0.28, p < 0.001$). For each distal level fused, post-operative trunk flexibility is reduced by 5%. However, post-operative flexibility does not drop to below 80% of pre-operative motion until the LIV reaches L2. Even for patients fused to L4 on average their post-operative flexibility was 65% of pre-operative motion. (Fig.1)

Conclusion: It is difficult to quantify the actual loss in function a patient experiences when flexibility is reduced following a spinal fusion. This evaluation of the relationship between post-op flexibility and LIV exhibits reductions in flexibility of roughly 5% for each level fused distal to T10. If the fusion ends at L2 or above, approximately 80% of pre-operative flexibility can be maintained.

Significance: This evaluation of the relationship between post-op flexibility and LIV exhibits reductions in flexibility of roughly 5% for each level fused distal to T10.





Paper #94

Postoperative Left Shoulder Elevation (LSE): An Unexpected Consequence of Surgical Correction of Lenke 1 Main Thoracic Curves

Michael F. O'Brien, MD (Miami Children's Hospital); Harry L. Shufflebarger, MD; Angel Macagno, MD; Michelle C. Marks, PT, MA; Tracey P. Bastrom, MA; Randal R. Betz, MD; Peter O. Newton, MD; Baron S. Lonner, MD; Alvin H. Crawford, MD; Suken A. Shah, MD; Harms Study Group

Introduction: Lenke 1 curves should be treated with fusion of the MT curve only. Spontaneous correction of the “non-structural” UT and TL/L curves is expected. The purpose of this study was to identify risk factors that predict post-op LSE in Lenke 1 curves.

Methods: Lenke 1 curves were identified in a prospective surgical AIS database. Using binary logistic regression the data was analyzed. Radiographic measures of shoulder heights were confirmed with clinical photographs of each pt.

Results: 132 Lenke 1 patients with minimum 2 yr f/u, postop x-rays and clinical photos were identified with a mean age of 14±2. 51/132 (39%) pts had LSE, 59/132 (45%) had neutral shoulders, 22/132 (17%) had right shoulder elevation (RSE). Instrumentation type and surgical approach were not predictive of LSE post-op. UT >25° pre-op (p=0.015) and post-op UT >14° (p=0.02) were predictive for LSE. Pre-op shoulder height was predictive of LSE post op (p=0.02). 58% of pts with LSE pre-op remained so post-op compared to 20% who started out neutral and 33% who started with RSE. 47% of pts were instrumented into the UT curve. This was predictive of LSE (p=0.03) with a 59% chance that the pt would have LSE at 2 yrs compared to 40% if the fusion ended at or below the MT proximal end vertebra. Pts with a LSE post-op had longer fusions, 9 vs 8 levels, (p=0.02). There was also a trend toward LSE in pts who had higher % correction of the MT curve (>67% p=0.09). Pts with a lumbar “A” modifier had the highest incidence of LSE (p=0.05).

Conclusion: Structural criteria of side bending to < 25 degrees is insufficient for defining UT curves that require instrumentation. LSE after surgical correction of Lenke 1 AIS was identified in 39% of pts in spite of the presumed protection afforded by the “non-structural” UT and TL/L curves. Risk factors for LSE post-op are: LSE pre-op, an UT >25°, incomplete instrumentation of the UT, a post-op UT >14° and correction of MT by >67%.

Paper #95

Surgeon Reliability for Assessing Shoulder Height in AIS Patients with Double Thoracic Curves

Bryan Tompkins, MD; Daniel J. Sucato, MD, MS (Texas Scottish Rite Hospital); Anna McClung, RN

Introduction: When planning surgical treatment for double thoracic curve patterns in adolescent idiopathic scoliosis (AIS), multiple radiographic and clinical criteria are utilized when deciding to include the proximal thoracic (PT) curve. The clinical assessment of shoulder balance plays an important role in this decision. The objective of this study was to evaluate surgeon reliability in rating of shoulder height in double thoracic curves in preoperative patients and correlate clinical assessments with standard radiographic measurements.

Methods: Preoperative clinical photographs for a series of patients with AIS at a single institution from 1996-2004 were reviewed by 10 observers (4 pediatric orthopaedic fellows and 6 pediatric orthopaedic staff). Subjects were judged independently on shoulder balance on two separate occasions 1 month apart. The results were determined by calculating the average percentage of intraobserver and interobserver agreement. Reliability was quantified using kappa statistics.

Results: There were 58 subjects (48 Lenke Type-2 and 10 Lenke Type-1 curves). Intraobserver agreement of shoulder height for Lenke-1 curves was 67%, Lenke-2 curves 75% and all curves 74% (kappa coefficient, 0.65). Interobserver agreement for Lenke-1 curves was 52%, Lenke-2 curves was 62% and all curves was 60% (kappa coefficient=0.40). No correlation was seen between radiographic measurements (MT and PT curve magnitudes, curve apex, T1 tilt, shoulder height, and clavicle angle) and clinical agreement of shoulder heights.

Conclusion: For double thoracic curves, intrarater reliability of shoulder height assessment is good while interrater reliability is poor. No correlation was seen between clinical observations and radiographic measures.

Significance: When assessing clinical shoulder height in scoliosis, each surgeon provides consistent responses, however, agreement between surgeons is poor. More objective criteria are needed to improve our ability to assess shoulder asymmetry and must correlate with functional outcome.



Paper #96

Impact of Idiopathic Scoliosis and its Surgical Treatment on Appearance in Children.

Mohammad Diab, MD (UCSF); Timothy R. Kuklo, MD, JD; James O. Sanders, MD; Lawrence G. Lenke, MD; Daniel J. Sucato, MD, MS; Spinal Deformity Group

Introduction: The Spinal Appearance Questionnaire has been developed and validated to objectively determine the impact of idiopathic scoliosis on body image.

Methods: We reviewed a prospective consecutive series of 2044 children (8-18 yr) undergoing operation for idiopathic scoliosis, to whom was administered the Spinal Appearance Questionnaire preop, and at 1 (N = 919) and 2 (N = 504) yr postop.

Results: 1662 girls (81.3%) and 382 boys (18.7%). Curve magnitudes 44-91 degrees. 66.8% of children expected to be more even, which was the most important expectation overall preop. Preop, most important expectation varied by gender. Priorities differed by gender. More important to girls were “even hips”, “even waist” and “even breasts”, to “look better in clothes/swimsuit”, and to “look more attractive”; they also were more “self-conscious about scar” (all $p < 0.01$). Boys were “more bothered by height than back shape” ($p = 0.015$). Importance of even shoulders and rib/chest shape did not show gender variation (all $p > 0.1$). Children whose top priority was to be “more even” ($p = 0.022$ and 0.003 , respectively), to have a “more even waist” ($p = 0.037$ and 0.008) or “more even breasts” ($p = 0.003$ and 0.001), and those who were “self-conscious about scar” ($p = 0.005$ and 0.001), were less satisfied and less likely to say “yes” to the same treatment at 1 and 2 yr postop. Children whose top priority was to “look better in clothes” were more likely to say “yes” to the same treatment at 2 yr postop ($p = 0.043$). Satisfaction with, and likelihood of saying “yes” to the same, treatment did not vary by gender or curve type. Child-parent agreement on priorities was fair, ranging from “more even” at 58% to “self-conscious about scar” at 39%.

Conclusion: To be more even was the top goal of children undergoing surgical correction of idiopathic scoliosis. Least well addressed by current surgical techniques are waist and breast asymmetry. Scar appearance is a major source of dissatisfaction, which may be underappreciated by parents. Children for whom most important was to look better in clothing were more likely to say “yes” to the same treatment.

Significance: Our findings may aid the surgeon in managing patient expectations in children undergoing surgical treatment of idiopathic scoliosis.

Paper #97

Is Hypotensive Anesthesia Effective at Reducing Blood Loss During Pediatric Spine Fusion?

Richard E. Bowen, MD (Shriners Hospitals for Children); Stephen Gardner, BS; Anthony A. Scaduto, MD; Michael J. Eagan, MD; Jason Beckstead, MD

Introduction: The efficacy of hypotensive anesthesia in pediatric spinal fusion surgery is controversial. Purported benefits include decreased surgical blood loss, need for transfusion, and surgical time. However, reports of ischemic complications, including optic neuropathy and spinal cord monitoring changes, exist in children. This study evaluates if hypotensive anesthesia is reliably achieved and effective in pediatric spine fusion patients.

Methods: 107 consecutive patients undergoing spinal fusion surgery (>5 levels) were studied. Intraoperative mean arterial pressure (IMAP) reduction from baseline (BMAP) was averaged from skin incision until the beginning of skin closure. The independent variable was intraoperative EBL (ml/kg/levels fused). Dependent variables included: surgeon, anesthesiologist, surgeon experience, surgery time, surgical approach, revision vs. primary surgery, fusion to the pelvis, bone graft type (allograft vs. ICBG), and IMAP/BMAP. A t-test and a two-way ANOVA examined POD1 Hct between surgeons and among anesthesiologists, respectively. A stepwise multiple linear regression analysis between dependent variables and EBL was performed. A correlation analysis was performed for IMAP % reduction and EBL.

Results: No significant differences in postop Hct (28.2, STD 3.6) existed between surgeons (28.4 vs 27.9; p=.52) or among anesthesiologists (p=.27). Mean IMAP was -19.3% (-40% to +10%). Reduction in average IMAP was between 10 and 30% in 68% of patients. EBL correlated to iliac crest bone grafting (1.57 ml/kg/level vs. 1.22 for allograft; p=.023) and combined anterior/posterior surgery (1.45 ml/kg/level vs. 0.98 for posterior surgery; p=.002). There was no correlation between IMAP reduction and EBL (r=.03). When grouping patients in 10% increments, the range of 90% confidence intervals for EBL between 0 to -40% reduction in IMAP was 1.0 to 1.9 ml/kg/level. There were no ischemic complications in any patient.

Conclusion: Hypotensive anesthesia was achieved within 10% of the target IMAP in the majority of cases, but it was not effective at reducing EBL within the range of 0-40% reduction of IMAP in this study.

Significance: Consideration should be given for normotensive (but not hypertensive) anesthesia during pediatric spinal fusion surgery.

Paper #98

Can We Safely Reduce Blood Loss During Lumbar Pedicle Subtraction Osteotomy Procedures using Tranexamic Acid or Aprotinin? A Comparative Study with Controls.

Christine Baldus, RN, MHS; Keith H. Bridwell, MD (Washington University); Gbolahan O. Okubadejo, MD; Lawrence G. Lenke, MD

Introduction: The study objective is to compare the safety and efficacy of two pharmaceutical antifibrinolytic agents, aprotinin and tranexamic acid, in controlling blood loss during lumbar pedicle subtraction osteotomy (PSO) in adults.

Methods: Analysis of 44 consecutive adults who underwent posterior spinal fusion procedures which included lumbar PSO at one institution. Patients were analyzed according to treatment group: controls (10), aprotinin (14) and tranexamic acid (20). There were no significant differences in demographic (gender, age, comorbidities) or surgical traits (length of surgery, levels fused/exposed, preoperative hematocrit, bone graft source, primary/revision) between the three groups.

Results: The aprotinin group had significantly less intra-operative blood loss (1114+/-992ml; p<0.01) than the tranexamic acid and control group (2102+/-1076ml and 2260+/-1580ml respectively). The aprotinin group received significantly less blood (577+/-806ml; p<0.002) during the surgical procedure than both the tranexamic acid (1838+/-1096ml) and the control group (1502+/-1241ml). See attached figure. There were no significant differences found in the amount of postoperative blood loss collected in self-suction devices or in the transfusions required during the postoperative period for the three groups. There were no major intra-operative complications for any of the treatment groups. There were no postoperative cases of MI, CVA, DVT, or PE with any of the treatment groups. There was one acute tubular necrosis event in the aprotinin group. This resolved prior to discharge but required several days of dialysis.

Conclusion: The aprotinin treatment group lost significantly less blood and received significantly less blood transfusions than both the tranexamic acid and control group without significant differences in intra- and postoperative complications. Aprotinin may be a reasonable consideration for controlling blood loss in spinal surgeries where large blood losses are anticipated, such as PSO procedures.

Significance: This study shows aprotinin use during PSO procedures significantly reduces blood loss and blood transfusion requirements whereas tranexamic acid does not. This suggests aprotinin should be returned to the market for lumbar PSO surgeries.

Variable	Controls (N=10)	T Acid (N=20)	Aprotinin (N=14)	p-value*
Blood Loss				
Total blood lost, intraop (cc)	2260 ± 1580 MDN=1500	2102 ± 1076 MDN=2150	1114 ± 922 MDN=850	0.01**
Total blood lost, postop (cc)	1138 ± 430 MDN=1225	1373 ± 750 MDN=1235	1020 ± 647 MDN=878	0.3
Total blood lost, intraop + postop (cc)	3398 ± 1651 MDN=2732	3476 ± 1493 MDN=3505	2135 ± 1157 MDN=1938	0.03
Blood Given				
Total blood given, intraop (cc)	1502 ± 1241 MDN=1188	1838 ± 1096 MDN=1850	577 ± 806 MDN=412	0.0002**
Total blood given, postop (cc)	420 ± 430 MDN=350	259 ± 288 MDN=175	342 ± 276 MDN=350	0.53**
Total blood given, intraop + postop (cc)	1922 ± 1214 MDN=1712	2096 ± 1172 MDN=1928	919 ± 781 MDN=762	0.003**
Complications				
Complications, intraop:				
None	10 (100%)	18 (90%)	13 (93%)	0.6
Major	0	0	0	
Minor	0	2 (10%)	1 (7%)	
Complications, postop:				
None	9 (90%)	16 (80%)	13 (93%)	0.55
Major	1 (10%)	3 (15%)	1 (7%)	
Minor	0	1 (5%)	0	

* The FDA has not cleared a drug and/or medical device in use described in this presentation (i.e., the drug or medical device is being discussed in an off-label use). For full information see page 10.

Paper #99

***Epsilon Aminocaproic Acid (EACA) Reduces Postoperative Red-Cell Transfusion Requirements in Patients Undergoing Major Spinal Surgery: A Prospective, Randomized, Placebo-Controlled Trial in 182 Patients.**

Sean Berenholtz, MD, MHS, FCCM; Khaled Kebaish, MD (Johns Hopkins University School of Medicine); Julius Pham, MD; Elizabeth Garrett-Mayer, PhD; David B. Cohen, MD; John P. Kostuik, MD; Peter J. Pronovost, MD, PhD, FCCM; Todd Dorman, MD

Introduction: Spinal surgery, can be associated with significant blood loss and as a result, patients often receive multiple red-cell transfusions which may be associated with significant morbidity, including infectious transmission, immunosuppression and transfusion reactions. Prior studies evaluating the efficacy of EACA in patients undergoing spinal surgery have produced conflicting results. In addition, several of these studies have significant limitations.

Methods: We evaluated 310 patients, 128 were excluded. The remaining 182 patients were randomly assigned, 91 to receive aminocaproic acid and 91 to receive placebo. Average age in the EACA group was 55.5 ± 14.0 and in the control group (55.4 ± 15.5). Randomization was performed 24-72 hs prior to surgery, all study personnel, patients and care-providers were blinded to treatment allocation. The study drug (EACA, 100 mg/kg) or an identical-appearing placebo was administered in the operating room immediately after anesthesia induction followed by an infusion (EACA 10 mg/kg/hr) or placebo. that was continued for 8 hs postoperatively. Potential thrombotic and infectious complications were compared between the two groups using Fisher's exact test. Statistical analyses were based on the intention-to-treat principle and involved all randomized patients.

Results: The characteristics of the patients, medical co-morbidities, preoperative medications, diagnosis, surgeon and surgical procedure in the two groups were similar. Median estimated blood loss tended to be less in the EACA group (2440 vs 3020 cc, $p=0.08$). The mean number of allogeneic plus autologous red-cell transfusions during the postoperative period (post-surgery through POD 8) in the EACA group was significantly less than in the placebo group (median 2 & 3 units, respectively, $p=0.04$)

Conclusion: This is the largest study to date to evaluate the effect of EACA on red-cell transfusion requirements in patients undergoing major spinal surgery. There was a 30% reduction in the mean number of allogeneic plus autologous red-cell transfusions during the postoperative period among patients in the EACA group compared to the placebo group.

Significance: On the basis of the results from this study we believe that EACA could benefit patients undergoing major spinal surgery.



Paper #100

Efficacy of Intraoperative Cell Salvage Machines in Pediatric Spinal Deformity Surgery

Richard E. Bowen, MD (Shriners Hospitals for Children); Stephen Gardner, BS; Anthony A. Scaduto, MD; Michael J. Eagan, MD; Jason Beckstead, MD

Introduction: Use of intraoperative cell salvage machines (CS) may decrease homologous transfusion (HT) and the need for autologous blood predonation. This study aims to determine the safety, efficacy, and utility of intraoperative CS use in pediatric spinal deformity surgery.

Methods: 191 consecutive surgical spinal deformity patients were studied. 37 had no CS (BCS) and 154 did (ACS) according to CS purchase date. The same blood management strategy was used for all patients. The independent variables were HT and CST (ml/kg). Dependent variables included: age, diagnosis, preop Hct; surgery time, # levels fused, surgical approach, revision vs. primary surgery, fusion to the pelvis, intraop MAP, EBL, graft type; POD1 Hct, and transfusion reactions. Sequential t-tests were performed for HT+CST, POD1 Hct, and EBL between BCS and ACS. A Chi-square analysis of HT rate between ACS and BCS, and a stepwise multiple linear regression analysis among covariates and 1)HT and 2)CST in ACS patients, examined the efficacy of CS use. An odds ratio analysis of significant factors from the linear regression analysis described the utility of CS use in patient subgroups.

Results: There were no transfusion reactions with CST up to 1,440ml. The BCS group had higher EBL (36.4 cc/kg vs 13.3 cc/kg; $p=6*10^{-9}$), total intraop transfusion (14.5 cc/kg vs 6.2 cc/kg; $p=.00005$), and higher POD1 Hct (31.8 vs. 28.3; $p=.00004$). The HT rate was 72.1% vs. 22.3% in BCS and ACS ($p<0.0005$ on multivariate analysis). The HT volume in patients not receiving CST was 20.2ml/kg vs. 1.4ml/kg ($p<.0005$). No CST occurred in patients <20kg, undergoing growth sparing surgery, or having anterior release only. Odds ratio analysis in ACS patients showed fusions to the pelvis (OR=5.4; 95% CI 1.1 - 26.2), anterior/posterior fusions (3.3; 1.1-11.1), and surgical time >6hrs (2.5; 1.3-4.9) had higher rates of CST.

Conclusion: CS use was safe in this patient population. Despite differences in blood loss and transfusions in ACS vs. BCS, CS was effective in reducing HT volume and rate. CS was not useful in this population for patients <20kg or during growth sparing/isolated anterior release surgery.

Significance: This data helps surgeons decide which spinal deformity patients might benefit from CS usage.

Paper #101

Prevention of Surgical Site Infection Following Spinal Instrumentation Surgery. Is Postoperative Antimicrobial Prophylaxis Indispensable?

Hiroshi Taneichi, MD (School of Medicine Dokkyo Medical University); Kota Suda, MD; Tomomichi Kajino, MD; Hiroshi Moridaira, MD; Yutaka Nohara, MD

Introduction: Surgical site infection (SSI) is one of the worst consequences of spinal instrumentation surgery. Especially, SSI caused by antimicrobial-resistant pathogens, such as methicillin-resistant *S. aureus* (MRSA), represents a catastrophe because implant removal is frequently unavoidable in morbid spine with instability and/or deformity. The aim of this study was to verify efficacy of one-day antimicrobial prophylaxis (AMP) according to CDC guideline for prevention of SSI in spinal instrumentation surgery.

Methods: 225 consecutive patients (AMP-1) who underwent spinal instrumentation surgery (2004.4-2006.3) were enrolled in this prospective study. Exclusion criteria were diabetes, steroid use, autoimmune diseases, and penicillin/cephalosporin allergy. Dosage regimen of AMP was that cefazolin or sulbactam/ampicillin was initially infused 15 minutes before surgery and added every 3 hours during surgery with the final administration within 3 hours after skin closure. No additional use of AMP agents was done. As a control, 289 patients (AMP-5) with spinal instrumentation (2001.1-2004.3) who received traditional AMP in which cephalosporin was administered twice a day from day-0 to -5 of surgery were selected. Incidence and pathogens of SSI were compared between the two groups.

Results: Total incidence of SSI was 2.2% in AMP-1 and 4.2% in AMP-5 ($p>0.05$). Deep incisional SSI occurred in 0.9% of AMP-1 and in 2.8% of AMP-5 ($p>0.05$). Pathogens of SSI were *S. aureus* in all cases. Rate of MRSA was 41% in AMP-1 and 100% in AMP-5 ($p=0.008$). There was no difference between two groups in postoperative course of body temperature and blood data such as CRP.

Conclusion: Incidence of SSI did not increase when a very brief AMP was employed instead of traditional long postoperative AMP. Critically timed adjunct used AMP agents reduce the microbial burden of intraoperative contamination to a level that cannot overwhelm host defenses. In patients with normal immune status, SSI caused by postoperative contamination can be avoided by self defense mechanism. Lengthy AMP can lead to microbial substitution which brings about MRSA infection.

Significance: One-day antimicrobial prophylaxis proposed by CDC effectively controlled surgical site infection following spinal instrumentation surgery.



Paper #102

Major Perioperative Neurologic Deficits in Pediatric and Adult Spine Surgery Patients: Incidence, Etiology and Outcomes over a 14 Year Period at One Institution

Christopher R. Good, MD (Washington University); Keith H. Bridwell, MD; Patrick T. O'Leary, MD; Mark Pichelmann, MD; Lawrence G. Lenke, MD; K. Daniel Riew, MD; Scott J. Luhmann, MD; Timothy R. Kuklo, MD, JD; Jacob M. Buchowski, MD, MS; Jennifer Flynn, BS

Introduction: We hypothesized that rates of neurologic deficit are higher in kyphosis and revision surgery and that neurologic outcome is related to level of deficit. Also, that spinal cord monitoring (SCM) would not detect all deficits and that many deficits would not recover. We expected recovery to be similar in spinal cord (SC) and cauda equina (CE) deficits.

Methods: 6071 consecutive pts (3127 adult / 2791 pediatric) undergoing surgery of the thoracic and lumbar spine were analyzed. Intra-operative or early post-operative deficits were included. Major deficit was defined as loss of bowel/bladder function (B/B) or motor deficit that prohibited ambulation (amb).

Results: Incidence of deficit was 0.28% (Table Ia). Incidence was higher in deformity than non-deformity pts (0.36% vs 0.06%, $p=.025$). Deficit was higher in revisions than primary surgery (0.55% vs 0.17%, $p=.017$) and in kyphosis than scoliosis (.63% vs .20%, $p=0.021$). Anterior/posterior surgery trended to a higher rate than posterior surgery (0.43% vs 0.20%, $p=0.12$). Age was not a significant risk factor. 11 pts had intraop deficit (8 SC, 3CE). SCM identified 9/11 (8/8 SC, 1/3 CE) and wake-up test 11/11. 6 pts had delayed postop deficit (2 SC, 4 CE). Etiology was known in 8/10 SC, 5/7 CE. CT myelo/MRI aided diagnosis in 10/17 and further surgery was undertaken for 11/17. At onset of deficit; 6 lost amb, 4 B/B, and 7 amb&B/B. At FU; 2 were without amb, 0 B/B and 4 amb&B/B (11/17 regained amb and B/B: 7/12 adults vs 4/5 kids, $p=0.60$). Of 10 SC deficits; 4 lost amb, 6 amb&B/B. At FU; 1 was without amb, 4 amb&B/B (5/10 improved). Of CE deficits; 2 lost amb, 4 B/B, 1 amb&B/B. At FU 1 pt could not amb (6/7 improved) (Table Ib).

Conclusion: Spinal deformity, revision and kyphosis surgery are at higher risk for neurologic deficit. SCM identified all SC deficits, 1/3 CE deficits. Likelihood of recovery from SC deficit was 50% and CE deficit 86%.

Significance: Revision and kyphosis surgery is at increased risk. SCM is dependable in SC but not CE territory. Imaging helps identify the etiology of some, but not all deficits. Neurologic improvement occurred in 50% SC vs 86% CE deficits and in 59% adults vs 80% kids.

(See table next page)



Table I			
(a) Rates of Neurologic Deficit			
	Deficits	Deficit Rate	p value
All Surgeries	17 / 6071	0.28%	
Primary	7 / 4101	0.17%	0.017 *
Revision	10 / 1818	0.55%	
Deformity	16 / 4388	0.36%	0.025 *
Non-Deformity	1 / 1621	0.06%	
Scoliosis	6 / 2947	0.20%	0.021 *
Kyphosis	9 / 1278	0.63%	
Ant / Post	8 / 1852	0.43%	0.116
Post	9 / 3801	0.24%	
Adult	10 / 3127	.032%	0.608
Pediatric	7 / 2791	0.25%	
* Statistically Significant			
	All Deficits	Spinal Cord	Cauda Equina
Number of Deficits	17	10	7
Intra-op Deficits	11	8	3
SCM detected	9 / 11	8 / 8	1 / 3
WUT Identified	11 / 11	8 / 8	3 / 3
Delayed Deficits	6	2	4
Imaging Helpful	10	5 / 10	5 / 7
Initial Neuro Deficit	6 Amb 4 BB 7 amb & BB	4 amb 0 BB 6 amb & BB	2 amb 4 BB 1 amb & BB
Final Neuro Deficit	2 amb 0 BB 4 Amb & BB	1 amb 0 BB 4 Amb & BB	1 amb 0 BB 0 Amb & BB
Immediate Frankel Grade	A: 4 B: 5 C: 6 D: 2 E: 0	A: 3 B: 4 C: 3 D: 0 E: 0	A: 1 B: 1 C: 3 D: 2 E: 0
Follow-up Frankel Grade	A: 2 B: 1 C: 2 D: 7 E: 5	A: 2 B: 1 C: 2 D: 1 E: 4	A: 0 B: 0 C: 0 D: 6 E: 1
# Improved at FU (Ambulatory & BB control)	11 / 17 Adults 7/2 Peds 4/5	5 / 10	6 / 7
SCM: Spinal Cord Monitoring WUT: Wake Up Test Amb: Motor deficit prohibiting ambulation BB: Loss of Bowel / Bladder control Amb & BB: Deficit prohibiting ambulation and Loss of Bowel / Bladder			

* The FDA has not cleared a drug and/or medical device in use described in this presentation (i.e., the drug or medical device is being discussed in an off-label use). For full information see page 10.



Paper #103

What Radiographic Sagittal Parameters Correlate with Improved SRS Self-Image Scores Postoperatively in Patients with Sagittal Imbalance: An Analysis of 102 Lumbar Pedicle Subtraction Osteotomy Patients

Yongjung J. Kim, MD; Keith H. Bridwell, MD; Lawrence G. Lenke, MD; Oheneba Boachie-Adjei, MD; Youngbae B. Kim, MD; Jacob M. Buchowski, MD, MS (Washington University)

Introduction: To analyze the correlation between sagittal alignment change and self-image outcome scores after lumbar pedicle subtraction osteotomy (LPSO) in patients with C7 plumb >5cm.

Methods: 102 patients with sagittal imbalance (78 females/24 males, average age at surgery 54.1 years) who underwent LPSO (2 at L1, 38 at L2, 54 at L3, 8 at L4) at 2 different institutions were analyzed (average follow-up 4.4 years; range 2-12 years). Sagittal standing whole spine radiograph, including femoral heads, and SRS-outcome instruments/Oswestry Disability Index (ODI) at the pre-operation and ultimate follow-up were evaluated. Scoliosis Research Society-Self Image (SRS-SI) subscale (total score of 5) was re-defined as Good if 4 or higher, Acceptable if 3-4, and Poor if lower than 3 at final follow-up.

Results: Average angle increase at the ultimate follow-up by LPSO was 33° (33° lumbar lordosis increase). Average increase in whole thoracic kyphosis (T1-T12) was 15° and average improvement in sagittal vertical axis (SVA) 9.6cm. Average increase in SRS-SI score was 1.4 (2.2 to 3.6 out of 5) and that of ODI score was 25 (52 to 27 out of 100). Patients distribution at final follow-up was: Good n=43, Acceptable n=39, and Poor n=20). Good SRS-SI score at ultimate follow-up demonstrated a moderately strong significant correlation with C7 plumb to bicoxofemoral head ($r=-0.413$, $p<0.0001$), SVA ($r=-0.405$, $p<0.0001$), and lumbar lordosis increase ($r=0.346$, $p<0.0001$) at the ultimate follow-up. Parameters at ultimate follow-up related to good SRS-SI (4) were: SVA <5cm (vs. >5cm, $p=0.003$), C7 plumb to bicoxofemoral head <0cm (vs. >0cm, $p=0.015$) and T12 plumb to S1 <-1cm (vs. >1cm, $p=0.017$).

Conclusion: Self-image score at ultimate follow-up demonstrated significant correlations with C7 plumb to bicoxofemoral head, SVA, and lumbar lordosis increase at the final follow-up. Significant parameters at ultimate follow-up related with good self-image were SVA <5cm, distance from C7 plumb to bicoxofemoral head <0cm and T12 plumb to S1 <-1cm.

Significance: SVA <5cm, distance from C7 plumb to bicoxofemoral head <0cm and T12 plumb to S1 <-1cm correlate with improved SRS Self-Image Scores postoperatively in patients with sagittal imbalance.

(See table next page)

Table. Associated factors for better SI score

Associated Factors		Total Patients (n=102)	Better SI score (n=43)	P value
SVA	≤5.0cm	56	31	0.003
	> 5.0cm	46	12	
C7 plumb to bicoxofemoral head	≤ 0cm	67	34	0.015
	> 0cm	35	9	
T12 plumb	≤ -1cm	43	24	0.017
	> -1cm	59	19	
TK+LL+PI	≤55	75	36	0.046
	>55	27	7	
LIV	L5	14	4	0.23
	S1	88	39	
Co-morbidity(ies)	Yes	58	23	0.56
	No	44	20	
Age at surgery	≤55	50	22	0.71
	>55	52	21	
PSO level	L1	2	1	0.85
	L2	38	14	
	L3	54	24	
	L4	8	4	
Longer follow-up	<5 years	43	18	0.96
	≥5 years	59	25	

** The FDA has not cleared a drug and/or medical device in use described in this presentation (i.e., the drug or medical device is being discussed in an off-label use). For full information see page 10.*



Paper #104

Does Vertebral Level of Pedicle Subtraction Osteotomy Correlate with Degree Of Spino-Pelvic Parameter Correction?

Frank J. Schwab, MD (NYU Hospital for Joint Diseases); Virginie Lafage, PhD; Ashish Patel, MD; Robert A. Hart, MD; Douglas C. Burton, MD; Oheneba Boachie-Adjei, MD; Alexis P. Shelokov, MD; Richard A. Hostin, MD; Christopher I. Shaffrey, MD; Munish C. Gupta, MD; Behrooz A. Akbarnia, MD; R. Shay Bess, MD

Introduction: Pedicle subtraction osteotomy (PSO) is a spinal realignment technique which may be used to correct sagittal spinal imbalance (SI). Theoretically, a more caudal lumbar PSO would result in greater correction of global sagittal balance (SVA) compared with a more proximal PSO. The effect of PSO level on immediate post-operative spino-pelvic parameters has not been well described. The purpose of this study is to analyze the relationship between the level/degree of PSO and changes in both global sagittal balance and spino-pelvic parameters.

Methods: Multi-center retrospective study of 70 patients (54 female, 16 male) that underwent lumbar PSO surgery for SI. Pre- and post-op free standing sagittal x-rays were obtained and analyzed by regional curves (lumbar, thoracic and thoraco-lumbar), pelvic parameters (pelvic incidence, pelvic tilt [PT] and sacral slope) and global balance (SVA, T1 spino-pelvic inclination [T1-SPI]). Correlations between PSO parameters (level and degree [change in angle between the 2 adjacent vertebrae]) and spino-pelvic measurements were analyzed.

Results: PSO distribution by level and degree of correction was as follows: L1 (n=6; 24°), L2 (n=15; 24°), L3 (n=29; 25°) and L4 (n=20; 22°). There was no significant difference in the focal correction achieved by PSO by level. All patients demonstrated differences from pre-op to post-op parameters included: increased lumbar lordosis (20° to 29°, p<0.001), increased thoracic kyphosis (30° to 38°, p<0.001), decreased SVA and T1-SPI (122mm to 34mm, p<0.001 and -4° to -8°, p<0.001, respectively) and decreased PT (33° to 23°, p<0.001). More caudal PSO was correlated with greater PT reduction (r=-0.410, p<0.05). No correlation was found between SVA correction and PSO location. PSO degree was correlated with change in thoracic kyphosis (r=-0.474, p<0.001), lumbar lordosis (r=0.667, p<0.001), sacral slope (r=0.426, p<0.001) and pelvic tilt (r=-0.358, p<0.005).

Conclusion: Degree of PSO resection correlates more with spino-pelvic parameters (lumbar lordosis, thoracic kyphosis, pelvic tilt, sacral slope) than PSO level. More importantly: PSO level impacts post-operative pelvic tilt correction but not SVA.

Significance: When selecting PSO level, desired PT correction is an important consideration.

Paper #105

Sagittal Spinopelvic Alignment Change after Lumbar Pedicle Subtraction Osteotomy: A Multicenter Analysis of 113 Patients with a Minimum 2 Years Follow-Up

Yongjung J. Kim, MD (Hospital for Special Surgery); Keith H. Bridwell, MD; Lawrence G. Lenke, MD; Oheneba Boachie-Adjei, MD; Christopher L. Hamill, MD; Youngbae B. Kim, MD

Introduction: To analyze sagittal spinopelvic alignment change after lumbar pedicle subtraction osteotomy (LPSO) in sagittally imbalanced patients.

Methods: 113 patients (84 females/29 males, average age at surgery 54.5 years) with a sagittal imbalance (C7 plumb >5cm) who underwent LPSO (2 at L1, 41 at L2, 61 at L3, 9 at L4) at 3 different institutions were analyzed (average follow-up 4.2 years; range 2-12 years). Radiographic analysis included assessment of thoracic kyphosis (T1-T12 and T5-T12), T12 horizontal angle (T12 lower end plate and horizontal angle), lumbar lordosis (T12-S1), lordosis through the PSO (Upper end plate of proximal vertebra and lower end plate of distal vertebra to PSO level), sacral slope (upper endplate of S1 and horizontal angle), pelvic tilt (center of S1 upper end plate to bicoxofemoral head and vertical line from bicoxofemoral head), pelvic incidence (sacran slope + pelvic tilt), sagittal vertical axis (SVA: C7 plumb to posterosuperior end of S1 upper endplate), T12 plumb to S1, C7 plumb to bicoxofemoral head and distance from posterosuperior endplate of S1 to bicoxofemoral head.

Results: Average increase in lumbar lordosis was 33° (-15 to -48), equal to the angle increase by LPSO (4 to -29). Average increase in thoracic kyphosis (T1-T12) was 14° (33 to 48) and that between T5 and T12 was 9° (27 to 36). Average 9° increase in sacral slope (24 to 34) resulted in 24° degree increase in the T12 horizontal angle (9 to -16) and 9° decrease in pelvic tilt (32 to 24). Average improvement in SVA was 10.2 cm (153 to 53). Average improvement in C7 plumb to bicoxofemoral head was 8.7cm (7.3 to -1.1) and of T12 plumb to S1 was 2.4cm (2.7 to 0.4). Average decrease in distance from S1 to bicoxofemoral head was 1.5cm (7.9 to 6.5).

Conclusion: Lumbar PSO changes sacral slope, pelvic tilt, T12 horizontal angle, and thoracic kyphosis. Multi-factorial consideration is necessary to obtain better correction of patients with sagittal imbalance.

Significance: We have to expect various changes such as sagittal vertical axis, sacral slope, pelvic tilt, T12 horizontal angle and thoracic kyphosis following lumbar PSO.

	Preoperation	Ultimate follow-up	P- value
Thoracic kyphosis (T1-T12)	33+22.6°	48+21.0°	<0.0001
Thoracic kyphosis (T5-T12)	27+19.9°	36+17.4°	<0.0001
T12 horizontal angle	9+12.2°	-15+9.9°	<0.0001
Osteotomy angle	4+16.9°	-29+14.3°	<0.0001
Lumbar lordosis (LL:T12-S1)	-15+19.8°	-48+16.7°	<0.0001
Sacral slope (SS)	24+15.7°	34+11.5°	<0.0001
Pelvic incidence (PI)	56+14.2°	58+13.2°	
Sagittal vertical axis (SVA)	15.3+5.5cm	5.3+6.0cm	<0.0001
C7 plumb to femoral head	7.3+6.1cm	-1.1+5.3cm	<0.0001
T12 plumb to sacrum	2.7+4.4cm	0.4+3.5cm	<0.0001
Bicoxofemoral head to S1 distance	7.9+2.3cm	6.5+2.1cm	<0.0001

Table: Radiographic sacropelvic change following lumbar PSO

Paper #106

Normative SRS-QOL Data to Allow Age and Gender Specific Comparisons to Adult Deformity Patients. An Analysis of 1346 Unaffected Subjects.

Christine Baldus, RN, MHS (Washington University); Keith H. Bridwell, MD; John Harrast; Christopher I. Shaffrey, MD; Stephen L. Ondra, MD; Lawrence G. Lenke, MD; Frank J. Schwab, MD; Steven M. Mardjetko, MD, FAAP; Steven D. Glassman, MD; Charles C. Edwards, II, MD; Christopher J. DeWald, MD; Thomas G. Lowe, MD; William C. Horton, III, MD; David W. Polly, Jr., MD

Introduction: The SRS QOL tool is used to evaluate treatment outcomes in spinal deformity patients. The study purpose was to establish normative age-gender values for the SRS QOL questionnaire, providing a reference for its interpretation. Clinicians and investigators will now be able to compare individual and/or groups of spinal deformity patients to their generational peers.

Methods: We randomly sampled 1346 volunteers (582 M, 764 F) recruited from across the US. Volunteers had no history of scoliosis or spine surgery and were not being treated for any spinal condition. Volunteer mean scores and standard deviations were calculated for 6 age-gender groups: male/female; 20-39, 40-59 and 60-80 years of age.

Results: The volunteer population means and standard deviations at 95% confidence interval for the SRS domains and sub-score (all domains excluding 2 satisfaction questions) were calculated. See table. The younger males (20-39 y/o) scored significantly higher than their female counter parts in all domains ($p \leq 0.002$). Only the mental health domain and SRS sub-score were significantly higher in middle (40-59 y/o) and older (60-80 y/o) males when compared to female counterparts ($p \leq 0.004$). Mean generational domain scores did decrease with age in both genders. The younger males had better scores in all domains except mental health when compared to both middle and older male groups ($p < 0.01$). The younger females (20-39 y/o) had less pain and better function than the older females (60-80 y/o) ($p < 0.01$). The middle age females (40-59 y/o) reported better function than the older females ($p < 0.01$).

Conclusion: This study established normative values for the SRS QOL tool in a non-spinal deformity population at a 95% confidence interval. Age-gender analysis found males had higher (better) domain scores than female counterparts but both genders reported lower outcome scores with advancing age.

Significance: With this study, normative values for the SRS HRQOL domains were established. These values do vary according to age and gender. Clinicians must be mindful of these factors when assessing deformity populations. Generational decreases noted in volunteer scores may allow investigators to extrapolate similar decreases that may be seen in their patient population over time.

Volunteer Mean +/- 95% confidence interval at 95% confidence level

	Age Group	N	Pain	p value*	Function	p value*	Self-Image	p value*	Mental Health	p value*	Sub Total	p value*
Males	20-39	181	4.6 + 0.07	0.002	4.4 + 0.05	0.000	4.4 + 0.07	<0.0001	4.2 + 0.09	<0.0001	4.4 + 0.05	<0.001
	40-59	201	4.4 + 0.09	0.346	4.3 + 0.06	0.957	4.3 + 0.09	0.075	4.2 + 0.09	0.001	4.3 + 0.07	0.042
	60-80	200	4.4 + 0.09	0.015	4.2 + 0.07	0.170	4.3 + 0.08	0.100	4.3 + 0.08	0.000	4.3 + 0.06	0.004
Females	20-39	203	4.4 + 0.08		4.3 + 0.06		4.2 + 0.08		3.9 + 0.08		4.2 + 0.06	
	40-59	299	4.3 + 0.07		4.3 + 0.05		4.1 + 0.07		4.0 + 0.08		4.2 + 0.05	
	60-80	262	4.2 + 0.10		4.1 + 0.07		4.2 + 0.08		4.0 + 0.08		4.1 + 0.07	

*p value compared to female generational counterpart.

Paper #107

Do One Year Outcomes Predict Two Year Outcomes in Adult Deformity Surgery?

Steven D. Glassman, MD (Leatherman Spine Center); Frank J. Schwab, MD; Keith H. Bridwell, MD; Christopher I. Shaffrey, MD; William C. Horton, III, MD; Serena S. Hu, MD

Introduction: With the validation of the SRS-22, HRQOL outcomes are being used more frequently for adult spinal deformity. The purpose of this study is to examine the pattern of HRQOL outcome responses following adult deformity surgery.

Methods: We reviewed 283 patients with two-year follow-up from a multi-center database for adult spinal deformity. Outcome measures were the SRS-22, SF-12, ODI and back/leg pain numeric rating scales (NRS). Change in scores at 6 months, 1 year, and 2 years post-op were evaluated by matched pair t-test and post-hoc analysis of ANOVA findings.

Results: The study cohort included 243 females (86%). Age ranged from 17 to 78 yrs (mean 50). Primary diagnosis was scoliosis (50%), kyphosis (22%), or other (23%). Overall, SRS-22, improved from a mean 3.0 at baseline to 3.2 at 6 months and 3.7 at one and two years post-op. Mean ODI score was 36.9 pre-op and improved to 26.9 at 6 months, 22.8 at one year and 22.7 at two years post-op. Mean SF-12 PCS was 33.6 at baseline, improving to 36.2 at 6 months, 39.9 at one year and 40.0 at two years post-op. Back pain NRS was 6.2 pre-op, and improved to 3.1 pts at 6 months, 3.0 pts at one year and 2.9 at two years post-op. Leg pain NRS was 4.0 pre-op, improved to 1.7 at 6 months, deteriorated to 1.9 at one year post-op, and was 1.8 at 2 years post-op. Paired samples analysis showed deterioration between 6 months and one year for leg pain NRS (p=0.05), no change for back pain NRS (p=0.28), a trend for improvement in SF-12 PCS (p=0.06) and significant improvement for ODI (p=0.02) and SRS-22 (p<0.0001). Comparison of one-year vs. two-year post-op scores revealed no statistically significant differences for any of the HRQOL parameters.

Conclusion: This study supports the use of HRQOL measures, particularly the SRS-22, as a valuable tool in the assessment of adult deformity patients. Outcome scores stabilized after the one-year post-op interval in most patients, suggesting that the one-year interval is a reasonable time frame to anticipate maximal improvement.

Significance: Outcome scores following adult deformity surgery stabilized after the one-year post-op interval in most patients, suggesting that the one-year interval is a reasonable time frame to anticipate maximal improvement.

Mean HRQOL scores following adult deformity surgery.

	Baseline	6 months	1 year	2 years
NRS back pain	6.24	3.06	2.97	2.89
NRS leg pain	3.96	1.69	1.91	1.79
SF-12 PCS	33.6	36.2	39.9	40.0
ODI	36.9	26.9	22.8	22.7
SRS-22	3.03	3.20	3.70	3.70



Paper #108

Operative vs. Non-Operative Outcomes: Adult Scoliosis Patients Age over 65 at Two Years Follow-Up

Gang Li, MD (Massachusetts General Hospital, Harvard Medical School); Eric Fu, BA; Peter G. Passias, MD; Guoan Li, PhD; Kirkham Wood, MD

Introduction: The current spine literature contains few studies that compare the long-term outcomes of surgically and non-surgically treated adult scoliosis patients older than 65 years using more than one self-assessment questionnaire. The purpose of this study was to compare the long-term outcomes between these two groups of adult scoliosis patients with the use of four distinct self-assessment questionnaires (SRS-22, SF-12, EQ5D, and ODI).

Methods: A total of 76 adult scoliosis patients retrospectively identified older than 65 years from one spine center treated by one surgeon. Nineteen of these were treated surgically, while fifty-seven were managed non-operatively. For each of these patients standard radiographic measurements were recorded both before and following treatment. Each patient received questionnaires (SRS-22, SF-12, EQ5D, and ODI) that were completed in their initial visit. T-test has been used for analysis.

Results: Radiographic measurements for the non-operative cohort revealed the presence of more severe deformity compared with the operative group before the treatment of both groups. In contrast to the non-surgically treated patients, the surgically treated patients had a significant improvement in radiographic anatomic measurements following treatment. In addition, the operative group reported significantly better self-assessment scores for EQ5D index, EQ5D VAS, SRS-22, and SF-12 PCS. There was, however, no statistically significant difference between the groups for the SF-12 MCS.

Conclusion: This study compared the long-term outcomes of adult scoliosis patients greater than 65 years who did and did not undergo operative treatment using primarily patient-derived outcome measures. The operative cohort reported better outcomes as measured by the four self-assessment questionnaires. When compared with the non-operative cohort following treatment, the operative cohort reported significantly less severe pain, better self-image, and greater overall satisfaction with their treatment.

Significance: Pre-operative radiographic deformity was not determined to be a significant factor for predicting whether an operative or non-operative treatment course was chosen.

Paper #109

The Changing Practice of Adult Spinal Deformity Surgery: An Emerging New Paradigm for Surgical Approach, Staged Procedures and Fusion Levels.

Charles C. Edwards, II, MD (The Maryland Spine Center); Keith H. Bridwell, MD; Michael R. Shainline, MS; Sigurd Berven, MD; Stephen L. Ondra, MD; William C. Horton, III, MD; Steven D. Glassman, MD; Christopher I. Shaffrey, MD; Christopher L. Hamill, MD; Frank J. Schwab, MD

Introduction: Medical advances typically lead to a change in clinical practice over time. The effect of recent spinal deformity advances on current clinical practice, however, is unknown. The purpose of this study was to assess whether surgical strategies used in the treatment of adult spinal deformity have changed over the past 5 years.

Methods: The surgical practices of 16 academic and private practice spinal deformity orthopaedic surgeons and neurosurgeons were evaluated using a prospective surgical database. 1159 patients with major spinal deformities that underwent surgery between 2002 and 2007 were included. Practice trends were evaluated according to surgeon seniority and surgical volume. 83% of patients were female with a mean age of 52 (range 17-86). Statistical analysis was performed with a Pearson Chi-square test.

Results: Analysis of surgical practice by year of surgery revealed no trends in terms of mean blood loss, surgical time, and use of autograft. Overall, staged procedures were used in 28% of cases (328 of 1169). The use of staged procedures decreased from 34% in 2002 to 19% in 2007 ($p < 0.001$). Circumferential approaches were used in 36.6% of cases (428 of 1169). The use of circumferential approaches decreased year by year from 54.3% in 2002 to 20.3% in 2007 ($p < 0.0001$). 692 cases involved long fusions extending from the thoracic spine to either L5 or S1. The percentage of long fusions stopping at L5 decreased dramatically in a straight line from 35% in 2002 to 5.9% in 2007 ($p = 0.002$). Each of these changes were consistent across surgeon groups.

Conclusion: Significant changes to the surgical treatment paradigm for adult scoliosis have occurred in the past 5-years. Among a cross section of spinal deformity practices there is a significant decreased utilization of staged procedures, circumferential approaches and long fusions terminating at L5.

Significance: A dramatic shift in the surgical paradigm for adult spinal deformity has occurred over the past 5 years in terms of staged procedures, surgical approach and distal fusion level. The effect of these changes on clinical outcomes needs to be critically investigated.

Paper #110

Can Posterior Only Surgery Replace Combined Anterior (Thoracotomy/Thoracoabdominal)/Posterior Approaches for Adult Scoliosis?

Christopher R. Good, MD; Lawrence G. Lenke, MD (Washington University); Patrick T. O'Leary, MD; Mark Pichelmann, MD; Kathryn A. Keeler, MD; Keith H. Bridwell, MD; Christine Baldus, RN, MHS; Linda Koester

Introduction: Combined anterior/posterior (A/P) fusion has traditionally been used to treat severe adult scoliosis deformities. Anterior approaches negatively impact pulmonary function and may require additional operative time and anesthesia. Posterior only (Post-only) techniques consisting of pedicle screws, osteotomies and BMP-2 may eliminate the need for the anterior approach without sacrificing deformity correction, fusion rates or outcome.

Methods: 24 patients who had A/P fusion for primary adult scoliosis (16 staged, 8 same day) were matched with a cohort of 24 patients who had Post-only treatment. Anterior fusion was performed via a thoracotomy (n=1)/thoracoabdominal (n=23) approach. All Post-only surgeries were under one anesthesia. Minimum 2-year follow-up included radiographic, clinical and outcomes data.

Results: There were no significant differences between groups for age, gender, diagnosis, co morbidities, preop curve magnitudes or global balance (see Table). Avg surgical time was higher in A/P vs Post-only group (11.6 hrs vs 6.9 hrs, p<.0001) as was total EBL (1330ml vs 980 ml, p=.04). Hospital Length of Stay (LOS) was longer in A/P vs Post-only group (11.9 vs 8.3 days, p=0.03). There were no significant differences between postop complications. Revision surgery was performed in 5 A/P pts (1 immediate postop for radiculopathy, 4 delayed for pseudoarthrosis) and 2 Post-only pts (1 immediate for coronal imbalance, 1 delayed for distal degeneration). Higher pseudo rates A/P vs Post-only (17% vs 0%) were not significant (p=0.11). SRS-30 and Oswestry scores reflected a similar patient assessment of outcome and function between groups both pre-op and at follow-up.

Conclusion: A post-only approach provides the same deformity correction as A/P fusion. OR times, EBL, and LOS are significantly less and outcomes and complications are equivalent at over 2 year follow-up, with a surprisingly lower pseudoarthrosis rate in the Post-only group.

Significance: Posterior-only adult scoliosis surgery avoids the morbidity of a thoracoabdominal approach, and achieves similar correction to A/P surgery while decreasing blood loss, operative time, LOS, and avoiding additional anesthesia. Complications, radiographic and clinical outcomes are similar at over 2 year follow-up.

Table : Demographic, Radiographic, Clinical and Outcome Data for A/P versus All-Posterior Surgery

	A/P	Posterior	p-value
Age	45.1	43.7	0.6
Gender	22 F 2 M	22 F 2 M	
Diagnosis	AdiS: 21 AdKS: 2 Cong Scol: 1	AdiS: 21 AdKS: 2 Cong Scol: 1	
Curve Types	Single: 15 Double: 3	Single: 15 Double: 3	
Pre-op Th Cobb	47°	56°	0.08
% Th Cobb Improvement PO	44%	50%	0.32
Pre-op TL Cobb	60°	58°	0.56
% TL Cobb Improvement PO	43%	55%	0.03 *
Pre-op CVA	-8.2 mm	-5.2 mm	0.72
CVA Improvement PO	7 mm	6.6 mm	0.94
Pre-op SVA	5.1 mm	-5.6 mm	0.3
SVA Improvement PO	2 mm	3 mm	0.89
OR time	11.6 hr	6.9 hr	<0.0001 *
EBL	1330 ml	980 ml	0.04 *
Hospital LOS	11.9 days	8.3 days	0.03 *
Anterior Interbody Fusion	22 Cages 2 Auto bone	6 TUFs	
Posterior Implants	20 TPS 3 Hybrid 1 Hook/wires	22 TPS 1 Hybrid 1 Hook/wires	
Osteotomies	0	6 multilevel SPOs	
BMP	8	19	0.003 *
Length of FU	4.88 yr	2.85 yr	<0.001 *
Medical Complications	1 (renal failure)	1 (resp failure)	
SRS Subscore Pre-op	3.09	3.18	0.53
SRS Subscore Final FU	3.61	3.79	0.38
SRS Satisfaction FU	3.4	3.68	0.61
Oswestry Pre-op	33.6	32.4	0.79
Oswestry Final FU	21.1	19.7	0.74

* = Statistically Significant

A/P: Anterior/Posterior, AdiS: Adult Idiopathic Scoliosis, AdKS: Adult Kyphoscoliosis, Th: thoracic, TL: thoracolumbar, LOS: Length of Stay, FU: Follow Up, CVA: Coronal vertebral axis, SVA: Sagittal vertebral axis, Sx: Surgery, Pseudo: Pseudoarthrosis, Impr: Improvement

Paper #111

Does Correction of Preoperative Coronal Imbalance Make a Difference in Outcomes of Adult Deformity Patients?

Michael D. Daubs, MD (Washington University); Lawrence G. Lenke, MD; Yongjung J. Kim, MD; Gene Cheh, MD; Keith H. Bridwell, MD

Introduction: There are few studies evaluating the treatment or affect of coronal imbalance on adult deformity patient outcomes. Prior studies have suggested that the severity of coronal imbalance postoperatively was insignificant. We evaluated the clinical outcomes and radiographic results of deformity surgery on patients with greater than 4 cm of coronal imbalance.

Methods: 36 patients (mean age 51 years; range 18-77) with at least 4 cm of preoperative coronal imbalance who underwent a thoracic/lumbar fusion for deformity correction having a mean follow-up of 49 months (range 24-124) were evaluated. Preoperative, postoperative, and last follow-up radiographs were measured. Outcomes were measured using the Oswestry Disability Index (ODI).

Results: Preoperative coronal imbalance averaged 61 mm (range 40-142), correcting to an average of 35 mm (range 0-84) ($p < 0.0001$) for an average correction rate of 43%. Postoperative improvement in coronal imbalance was seen in 89% (32/36) of patients. Oswestry scores improved at a mean of 15 points, 45-30 ($p < 0.0001$). Patients were divided into 3 groups based on coronal C7 plumbline measurements at last follow-up: 0-2 cm (n=9); 2-4 cm (n=14), and greater than 4 cm (n=13) of coronal imbalance. There were no significant differences with regard to the severity of preoperative coronal imbalance, or preoperative and postoperative ODI scores. All 3 groups showed significant improvement in ODI scores ($p < 0.05$).

Conclusion: There was significant improvement in clinical outcomes following surgical treatment of patients with greater than 4 cm of coronal imbalance. There was no significant difference in outcomes based on the severity of the residual imbalance whether it was greater or less than 4 cm. However, 89% (32/36) had postoperative coronal imbalance improvement ($p < 0.001$). This data suggests that the absolute amount of residual postoperative coronal imbalance may not be as important a factor in patient outcomes as is the fact that there was postoperative improvement in their coronal balance.



Paper #112

Risk Factors and Outcomes for Catastrophic Failures at the Top of Long Pedicle Screw Constructs (FPSC): A Matched Cohort Analysis Performed at a Single Center

Patrick T. O'Leary, MD (Washington University); Keith H. Bridwell, MD; Christopher R. Good, MD; Lawrence G. Lenke, MD; Jacob M. Buchowski, MD, MS; Yongjung J. Kim, MD; Jennifer Flynn, BA

Introduction: Acute fractures at the top of long segmental pedicle screw constructs (FPSC) are often catastrophic. Substantial surgical increase in lordosis predisposes to this problem. In relation to a matched cohort, we postulated that age, body mass index (BMI) and significant correction of lumbar lordosis would increase risk of FPSC and patients with FPSC would have lesser improvements in outcomes.

Methods: 13 patients who sustained FPSC at one institution between 2000 and 2007 were evaluated. During this time, 259 patients aged 40 or older had a spinal fusion from the thoracic spine to the sacrum utilizing an all-pedicle screw construct. A cohort of 31 of these patients without FPSC but with all pedicle screw constructs was matched for diagnosis of '+' sagittal imbalance, gender, preop C7 sagittal plumb, and number of levels fused. All patients in both groups were fused from the thoracic spine to the sacrum.

Results: FPSC occurred within 69 (24-117) days of surgery. A history of minor trauma was elicited in 4 cases. There was a statistically significant difference in age ($p=.02$) and BMI ($p=.006$) between the matched groups. There was no significant difference in preop/postop C7 plumb or change in lumbar lordosis between groups (Table 1). Acute paraplegia developed in 3 patients; only 1 patient returned to neurologic baseline. The second patient has persistent deficits and the third remains paraplegic. 9 patients had further surgery - proximal extension of the fusion. For 7 of the 13 FPSC patients with bone mineral density data (BMD) available, average T-score was -1.73 ; -0.58 for the matched group ($p=.02$). There was less clinical improvement, thought not statistically significant, in the FPSC group based on Oswestry (ODI) scores.

Conclusion: Factors that increased the risk of FPSC included obesity and older age. Osteopenia increased the risk as evidenced by BMD (based on 17 patients) and the older age of these patients. Neuro deficits were severe. There was no statistical difference in clinical improvement between groups based on ODI.

Significance: In female patients with $BMI > 30$ and $age > 60$, surgeons should consider alternatives to segmental pedicle screws at the proximal end of the construct.

(See table next page)

TABLE 1

	FPSC (Fracture) Group n=13	Matched Cohort n=31	p value*
Gender	13/13 female	31/31 female	n/a
Number of levels fused	9.4±3.7	9.4±3.4	0.98
Sagittal C7 plumb >5cm	10/13 (77%)	24/31 (77%)	1.0
Sagittal C7 plumb preop (mm)	109.4±79.8	107.1±80.8	0.93
Sagittal C7 plumb postop (mm)	33.3±48.9	22.0±39.7	0.47
Pedicle subtraction osteotomy	5/13	14/31	0.75†
Sagittal T12-S1 preop	-23.6±19.5	-19.4±26.6	0.81
Sagittal T12-S1 postop	-49.4±9.6	-51.3±16	0.43
Fusion Distal thoracic spine-S1	10(77%)	23 (74%)	1.0†
Fusion Proximal thoracic spine-S1	3(23%)	8(26%)	1.0†
Sagittal UIV plumb preop	47.6±62.0	27.2±53.3	0.32
Sagittal UIV plumb postop	-10.3±43.8	-23.5±33.6	0.34
Diabetes	2 (15%)	0 (0%)	0.08†
Smoker	0 (0%)	2 (6%)	0.57†
Age	66±10.3	58.9±8.6	0.02
Body Mass Index (BMI)	32.3±6.7	27.3±4.3	0.006
T-Scores	-1.73±0.76 (n=7)	-0.58±1.12 (n=10)	0.02
Oswestry Disability Index (% of 100)	54.1±15.8	47.2±19.6	0.31
Preop	40.1±23	27.2±18.2	0.11
Postop	p=0.04	p<0.0001	
p value††			

*P-value compares groups by chi-square test (for categorical variables) or by unpaired t-test (for continuous variables) unless otherwise indicated

†Fisher's exact test for categorical variables

††p-value tests for change within a group by paired t-test.



Paper #113

Pelvic Tilt Shows Correlation with Health Related Quality of Life Measures and Truncal Inclination

Ashish Patel, MD (New York University Hospital for Joint Diseases); Frank J. Schwab, MD; Virginie Lafage, PhD; Nicola Hawkinson, BSN, MA, NP; Jean-Pierre Farcy, MD

Introduction: It is becoming increasingly recognized that the study of spinal alignment should include pelvic position. While pelvic incidence determines lumbar lordosis, pelvic tilt (PT) is a positional parameter reflecting compensation to spinal deformity. Correlation between plumbline offset (SVA) and Health Related Quality of Life (HRQOL) measures has been demonstrated, but such a study is lacking for PT. The purpose of this study was to confirm the correlation between SVA and HRQOL in a population with adult deformity and also examine correlation with PT. The hypothesis was that PT, among other spino-pelvic parameters, would correlate with HRQOL measures.

Methods: This is a prospective radiographic and clinical analysis of 125 adult patients suffering from spinal deformity (mean age 57 years). Full-length free-standing radiographs including the spine and pelvis were available for all patients. HRQOL instruments included: ODI, SF12, SRS. Correlation analysis between radiographic spino-pelvic parameters and HRQOL measures was pursued.

Results: Correlation analysis revealed no significance pertaining to coronal plane parameters. Significant sagittal plane correlations were identified. SVA and truncal inclination measured by T1 spino-pelvic inclination (T1-SPI) (angle between T1-hip axis and vertical) correlated with: SRS (appearance, activity, total score), ODI, and SF12 (PCS). Correlation coefficients ranged from $0.42 \leq r \leq 0.55$ ($p < 0.0001$). T1-SPI revealed greater correlation with HRQOL compared to SVA. PT showed correlation with HRQOL ($0.28 \leq r \leq 0.42$) and with SVA ($r = 0.64$ $p < 0.0001$).

Conclusion: This study confirms that pelvic position measured via PT correlates with HRQOL in the setting of adult deformity. High values of PT express compensatory pelvic retroversion for sagittal spinal malalignment. This study also demonstrates significant T1-SPI correlation with HRQOL measures and outperforms SVA. This parameter carries the advantage of being an angular measurement which avoids the error inherent in measuring offsets in non-calibrated radiographs.

Paper #114

Low Back Pain in Patients Treated Surgically for Scoliosis -Longer than 15 Year Follow-Up

Kazushi Takayama, MD (Osaka City University Graduate School of Medicine); Hiroaki Nakamura, MD; Hidetomi Terai, MD; Tadao Tsujio, MD, PhD; Akira Matsumura, MD, PhD; Akinobu Suzuki, MD, PhD; Takafumi Maeno, MD; Sho Dohzono; Hideki Matsuda, MD; Prof. Kunio Takaoka

Introduction: Measures of long-term outcome after surgery for scoliosis have focused principally on radiological changes. However, subjective symptoms such as low back pain (LBP) are the subjects of greatest concern for patients who have had or will undergo surgical treatment for scoliosis. The purpose of this study was to evaluate long-term outcome in the point of LBP following scoliosis surgery.

Methods: Thirty-two patients treated surgically for scoliosis between 1976 and 1989 were included in this study. There were 8 men and 24 women, and the mean follow-up duration was 21 years (range 17-29). The mean age at the time of surgery was 15.3 years old (range 11-22). For the type of scoliosis, 18 patients were adolescent idiopathic scoliosis, 8 were congenital scoliosis, and 6 were symptomatic scoliosis. All patients were operated upon by one senior author, and the instrumentation used was Harrington in 14 cases, Cotrel-Dubousset in 11 cases, and other in 7 cases. We evaluated the radiological parameters related with LBP among these patients, and the degree of LBP was evaluated by Visual Analogue Scale score and also by Moskowitz classification, and Short Form-36 Health Survey (SF-36).

Results: Cobb angle improved from a mean of 70 degrees to 33 degrees postoperatively with surgical treatment. The angle at most recent follow-up was 42 degrees in average, with a mean of 9 degrees loss of correction over 21 years of follow-up. Degenerative change of the caudal adjacent segment on plain X-ray was detected in 6 patients, but their degree of LBP was not so severe. And there was not apparent correlation between the distal fusion level and the degree of LBP. In Moskowitz classification, 27 patients had no pain or rare pain, and the mean VAS score was 21 (range 0-80). On the SF-36, the results were not quite different from those of age-matched healthy controls except for Physical Function, and the scores for Bodily Pain were same as controls.

Conclusion: In the-mean-follow-up of 21 years after surgery for scoliosis, LBP was found to be no more frequent than in the normal population.



Paper #115

Predicting Surgical Outcome by Change in Critical Parameters of Thoracolumbar/Lumbar Spinal Deformity in Adults

Frank J. Schwab, MD (New York University Hospital for Joint Diseases); Virginie Lafage, PhD; Ashish Patel, MD; Jean-Pierre Farcy, MD; Keith H. Bridwell, MD; Steven D. Glassman, MD; Michael R. Shainline, MS

Introduction: Surgery for treatment of adult spinal deformity carries significant risk, and few reports have focused on health related quality of life measures (HRQOL). Classification approaches have identified parameters associated with poor function and pain. To determine which patients can benefit from surgery it is important to build models for predicting post-operative outcome. The purpose of this study was to isolate critical clinical and radiographic parameters to predict significant improvement through surgery for thoracolumbar and lumbar deformity.

Methods: This is a prospective multi-center analysis of 74 patients with thoracolumbar or lumbar major deformity: 90% female, mean age 53 years. Each had complete radiographic and outcomes instrument data at the pre-operative and 1- and 2-year follow up (SRS, ODI, SF-12). All baseline parameters were utilized to create statistical models predicting outcomes at 2 years. A backward conditional elimination technique was applied to retain only those predictor variables that contributed non-redundant explanations of outcome. The model predictors were patient satisfaction in appearance, function and pain (SRS).

Results: Using all variables, models were able to correctly predict 2 yr post operative satisfaction in: appearance 100%, function and daily activity 85%, pain 100%. The parsimonious model reduced only the prediction of function and daily activity to 78%. Key variables included: age, global balance modifier, changes in category by classification through surgery (improved lordosis, global balance), osteotomy, and baseline physical component score (SRS).

Conclusion: The study shows promise that diagnostic and demographic information about adult deformity patients combined with surgical strategy can identify patients who are most likely to be satisfied with their outcome. Patients most disabled before surgery, and who experience Classification category change (structural improvement) are most likely to report improved function two years after surgery. The ability to model and predict outcomes will offer reliable treatment algorithms for these complex patients in the future.

TRADITIONAL POSTER ABSTRACTS



SCOLIOSIS RESEARCH SOCIETY



Poster #1

**LOUIS A. GOLDSTEIN AWARD NOMINEE FOR BEST CLINICAL PRESENTATION

What Factors are Important in Determining Intraoperative Blood Loss During Scoliosis Surgery?

Suken A. Shah, MD (Alfred I. duPont Hospital for Children); Gabriela Ramirez-Garnica, PhD, MPH; Gang Ye, PhD; Robert Stanton, MD; Lubica Celerin, MD

Introduction: Blood loss during surgery for AIS is an area of concern for the surgeon, anesthesiologist and family; significant practice variation exists in this area. We sought to: 1) evaluate the importance and magnitude of peri-operative variables and blood loss; and 2) examine the relationship between autologous donation, blood loss, cell salvage and allogenic replacement.

Methods: Retrospective cohort study using data collected on patients who underwent surgery for scoliosis from 2004-2006 within one health care system. For this study, we focused on 262 AIS patients who underwent posterior-only surgery. A generalized linear model was fit to predict blood loss.

Results: The mean age of patients was 14.8 yrs with 210/262 (80%) females. Mean weight was 57.5 kg and mean preop major Cobb angle was 57°. Mean levels fused was 9.5. There was a strong positive correlation with: number of levels fused ($p<0.001$), male gender ($p<0.001$), duration of surgery ($p<0.001$), use of pedicle screws ($p<0.001$) preop Cobb angle ($p<0.01$) and patient age ($p<0.03$). Factors not found to have significant correlation were: surgeon experience or volume, patient weight, preoperative hematocrit or curve type. 103 patients had donated an average of 1.6 units of auto blood preop, and these units were utilized 75% of the time. An average of 0.6 units was discarded per patient. Cell salvage was utilized in 68% of cases and the mean volume returned was 307 cc. The frequency of banked blood transfusions for patients who had auto donated and those who did not was 15.5% and 15.1% respectively ($p=0.92$). Similarly, there was little difference in the frequency of banked blood transfusions for patients with and without cell salvage (10.4% and 15.7%, respectively, $p=0.26$).

Conclusion: The following factors were important in determining blood loss: number of levels fused, male gender, duration of surgery, use of pedicle screws, preop Cobb angle and patient age. Auto donation or cell salvage did not seem to change the frequency of allogenic blood transfusion. A formula using preop factors was constructed to estimate blood loss: $EBL (cc) = (Age \times 39) + (Levels \text{ fused} \times 64) + (Cobb \text{ Angle} \times 10.5) - 248$ (if female) - 805.

Poster #2

Trunk Flexibility and Activity/Function are Significantly Less with Lumbar Fusion in Patients with Lenke 1&2 Curve Types

Linda P. D’Andrea, MD (Brandywine Institute of Orthopaedics); James T. Guille, MD; Lynn Letko, MD; Peter O. Newton, MD; Baron S. Lonner, MD; Alvin H. Crawford, MD; Randal R. Betz, MD

Introduction: It has not been demonstrated that spinal fusion below T12 would result in a loss of trunk flexibility. Maintaining trunk flexibility after scoliosis fusion surgery is an important goal for some patients. The purpose of this study was to evaluate this preop to postop change in trunk flexibility, and clinical outcomes as measured by SRS domain scores.

Methods: Prospectively collected data for 196 AIS patients with Lenke 1&2 curve was evaluated. Patients were separated into two groups based on the lowest instrumented vertebra (LIV) of fusion: T12 & above (N= 101) [T8 N=1, T9 N=1, T10 N=4, T11 N=29, T12 N=66], or L1 & below (N= 95) [L1 N=37, L2 N=28, L3 N=22, L4 N=8]. Two year post-operative trunk flexibility (represented as a percent of the pre-operative baseline value) was compared between the LIV groups. Clinical measurements included: thoracolumbar flexion & extension; right & left lateral bending; right & left trunk rotation. The two groups were also analyzed for differences in SRS questionnaire domains & total score preop & at 2 years.

Results: Patients fused T12 & above maintained a much higher percentage of preoperative flexibility in all clinical measures except for right trunk rotation as compared to those fused L1 & below (Table 1). This is most significant with 21% more trunk extension, 11.3% greater flexion, & 13.7% greater left lateral flexion in patients fused T12 or higher. Patients fused T12 or higher reported higher general activity scores (4.77±0.37) compared to the L1 & below group (4.61 ± 0.55, p=0.015). They also reported increased function after surgery (3.33 ± 0.84) compared to the L1 & below patients (3.02 ± 1.14, p=0.036).

Conclusion: While it has been shown that longer fusions may yield increased correction in the coronal plane, these findings show that fusion to T12 & higher, maintains a greater percentage of preoperative trunk flexibility. This is clinically and statistically significant compared to patients fused to L1 & below for Lenke 1&2 curves. Careful evaluation of surgical goals (radiographic superiority vs. motion/function preservation) must be considered for each patient.

Significance: A significant loss of trunk flexibility results from fusion to L1 & below in patients with Lenke 1&2 curve types.

Table 1. Two-year Postoperative Clinical Measures of Trunk Flexibility represented as a percent of the pre-operative baseline value

Clinical Measure of Trunk Flexibility	LIV T12 & above Mean (std dev)	LIV L1 & below Mean (std dev)	p- value
Flexion	90.09 (24.21)	78.83 (30.39)	0.007
Extension	86.71 (32.88)	65.72(37.04)	< 0.001
Right Lateral Flexion	87.60 (19.11)	80.60 (27.32)	0.046
Left Lateral Flexion	85.61 (21.93)	71.89 (22.66)	< 0.001
Right Rotation	92.38 (24.02)	87.67 (23.93)	0.182
Left Rotation	93.18 (25.11)	84.67 (23.55)	0.017

* The FDA has not cleared a drug and/or medical device in use described in this presentation (i.e., the drug or medical device is being discussed in an off-label use). For full information see page 10.

Poster #3

Does Abnormal Pedicle Morphology Correlate with Degree of Vertebral Rotation, Curve Severity, or Location within the Curve Apex in Pediatric Spinal Deformity?

John K. Czerwejn, Jr., MD; Adam L. Wollowick, MD; Beverly Thornhill, MD; Alok D. Sharan, MD; Terry Amaral, MD; Vishal Sarwahi, MD (Albert Einstein College of Medicine); Melanie Gambassi, NP

Introduction: Accurate assessment of pedicle morphology is important for safe pedicle screw placement. The purpose of this study was to determine if a correlation exists between dysmorphic pedicles and curve size, degree of vertebral rotation, and location within the periapical region.

Methods: CT scans of 59 spinal deformity patients were reviewed independently by a bone radiologist and a spine surgeon. Pedicle morphology was classified as: Type A (normal pedicle) - >4mm diameter cancellous channel, Type B - 2-4 mm cancellous channel, Type C - cortical channel, and Type D <2mm or non-existent pedicle. Types B, C, and D were considered dysmorphic. 15 patients had Cobb angles > 70 degrees and 44 had Cobb angles < 70 degrees. 38 patients had Nash and Moe grades 1 and 2 at the apical vertebra and 21 patients had grades 3 and 4. A total of 354 periapical pedicles were assessed for dysmorphism. The periapical region included vertebrae one level above and one level below the apex vertebra.

Results: 2006 pedicles (1416 thoracic and 590 lumbar) were reviewed. Of the 2006, 445 were dysmorphic. There were 292 Type B pedicles, 93 of Type C, and 60 with Type D. 21% (106 of 510) of pedicles in curves greater than 70 degrees were dysmorphic vs. 20% (305 of 1496) in curves < 70 degrees. Apical vertebrae with Nash and Moe grades 1 and 2 had an 18% incidence of dysmorphic pedicles vs. a 24% incidence seen in grades 3 and 4. In the peri-apical region, 29% of pedicles were dysmorphic vs. only 21% in the non-apical region. All results were statistically significant ($p < .05$).

Conclusion: A higher incidence of dysmorphic pedicles was found in the periapical region and in vertebrae with Nash and Moe grades 3 and 4. The incidence of dysmorphic pedicles in the periapical region is 29%. Awareness of abnormal pedicle morphology can assist the surgeon in appropriate preoperative planning.

Significance: Awareness of certain curve characteristics may assist the surgeon in accurate and safe placement of pedicle screws. The surgeon may obtain a preoperative CT scan to assess pedicle morphology and potentially avoid malpositioning pedicle screws.



Poster #4

Allogeneic Blood Transfusion Saving Program for Patients Undergoing Major Spine Surgery: Results of a Risk Adapted Strategy

Federico Moscardó, MD (Hospital Universitario La Fe); Teresa Bas, MD, PhD; Nelly Carpio, MD; Paloma Bas, MD; Francisco Arriaga, MD; Jaime Sanz, MD; Daniel Bonete, MD; Monica Roig, MD; Javier De La Rubia, MD; Vicente Ariño, MD; Ismael Escribá, MD; Miguel A. Sanz, MD

Introduction: Pre-surgical ABC is a common strategy for preventing AlloBT after surgery. However, it results in a high rate of total transfusion and expired collected blood bags. For this reason, we analyze the efficacy of a risk adapted strategy using ABC only in selected high risk patients.

Methods: During years 2002 to 2005 ABC was used at our institution for all patients as a blood saving strategy (Protocol 1). After 2005 patients were classified in three different treatment arms (Protocol 2): i) Oral iron for patients with hemoglobin level higher than 14 g/dL and with less than 5 instrumented spine levels; ii) Erythropoietin (EPO) 40.000 IU per week plus IV iron 200 mg per week for patients with less than 14 g/dL hemoglobin level and having less than 5 instrumented spine levels; and iii) Weekly ABC, EPO and IV iron for patients having 5 or more instrumented levels.

Results: Overall, 308 patients were included in the study. A total of 192 patients were evaluated for Protocol 1. The prevalence of AlloBT was 10%. However, 154 patients (80%) received an autologous transfusion (AutoBT). Additionally, at least one ABC bag was not used in 42% of the patients. Patients needing more than two blood units were 36% when there was more than 4 instrumented levels as compare with only 13% in the remaining patients ($P = 0.001$). On the other hand, 116 patients were evaluated in Protocol 2. The incidence of AlloBT, AutoBT and not used ABC bags, comparing with Protocol 1, were 9% vs. 10% ($P = \text{NS}$); 29% vs. 80% ($P < 0.001$); and 8% vs. 42% ($P < 0.001$). The variables related with the risk of AlloBT in Protocol 2 were adult degenerative scoliosis ($P = 0.02$) and age ($P = 0.05$).

Conclusion: A risk adapted strategy based on the number of instrumented spine levels and pre-treatment hemoglobin results in a low rate of AlloBT after major spine surgery avoiding the inconveniences of a universal pre-surgical ABC.

Significance: Results of this study suggest that a blood saving program for patients undergoing major spine surgery results in a low AlloBT rate. A risk adapted strategy taking into account the number of spine fusion levels and the pre-treatment hemoglobin level seems to be a good schedule.

Poster #5

Incidence and Causes of Revision Surgery following Thoracolumbar Fusion to the Sacrum for Kyphoscoliosis in Patients Greater than 60 Years Old

Brian A. O'Shaughnessy, MD (Northwestern University); Tyler Koski, MD; Patrick C. Hsieh, MD; Stephen L. Ondra, MD

Introduction: As the population matures, there is greater interest in outcomes of surgery for kyphoscoliosis in the aging spine. The purpose of our study was to determine the incidence and causes of revision surgery following major spinal reconstruction in patients greater than 60 years old.

Methods: 43 patients with a mean age of 70.5 ± 6.1 years who underwent thoracolumbar fusion to the sacrum for adult deformity by a single surgeon were followed for a mean of 4.1 years (range, 28-72 months). Caudal segment interbodies were placed through a mini-open anterior approach in all patients and 62.8% had iliac screw fixation. Mean number of levels instrumented/fused was 10.7 ± 4.7 . Correction was achieved through an anterior-posterior (23.3%) or posterior-only (76.7%) approach. Patients underwent multilevel SPOs (n=35) or a lumbar PSO (n=8).

Results: At latest follow-up, 46.5% of patients underwent additional surgery. Hook/screw revision was performed in 6.9% of patients and wound revision in 13.9%. Pseudarthrosis occurred in 20.9% of patients (one case at L5-S1). Proximal junctional kyphosis (PJK) was found in 8 (18.6%) cases, 3 of which were revised. PJK did not correlate with proximal instrumented vertebra. Three patients who initially underwent SPOs were later revised with a PSO for additional sagittal correction.

Conclusion: Major reconstructive spinal deformity surgery in patients greater than 60 years of age is associated with a relatively high incidence of revision surgery. Rates of PJK and pseudarthrosis are comparable with that in the general adult population. No patient with caudal segment interbodies and iliac screws sustained lumbosacral pseudarthrosis.

Significance: No study to date reports data on the incidence and causes of revision surgery following spinal deformity correction in the aging spine population.



Poster #6

***Safety and Efficacy of Growing Rods for Pediatric Congenital Spinal Deformities**

Hazem B. Elsebaie, FRCS, MD (Cairo University); Muharrem Yazici, MD; George H. Thompson, MD; John B. Emans, MD; David S. Marks, FRCS; David L. Skaggs, MD; Alvin H. Crawford, MD; Lawrence I. Karlin, MD; Richard E. McCarthy, MD; Connie Poe-Kochert, RN, BSN, CNP; Patricia Kostial, BSN, RN; Tina Chen, BS; Behrooz A. Akbarnia, MD; Growing Spine Study Group

Introduction: Growing rods have been used as a modern alternative treatment for young children with different types of spinal deformities. This is the first study focused on the use of growing rods in progressive congenital spinal deformities.

Methods: A retrospective analysis was done for 19 patients with the average age of 6 years and 10 months (3 ± 2 to 10 ± 7) with progressive congenital spinal deformities that underwent growing rod procedures with a minimum of 2 years follow up. The average number of affected vertebrae per patient was 5.2 (2-9). The average follow up period was 3 years 9 months (2 ± 6 to 6 ± 0). The number of lengthenings averaged 4.3 (1-10) per patient.

Results: The mean scoliosis Cobb angle improved from 65.3° (40° - 90°) pre-initial to 44.9° (13° - 79°) post initial and 47.2° (18° - 78°) at the last follow-up. T1-S1 length increased from 263.8mm (192-322) after initial surgery to 310.5mm (261-352) at last follow-up with an average T1-S1 length increase 12mm per year. The space available for lungs (SAL) ratio increased from 0.81 preoperatively to 0.94 post latest follow up. Five patients reached final fusion. During the treatment period, complications occurred in 8 of the 19 patients (42%), and there were a total of 15 complications out of 100 procedures (15%): 2 pulmonary, 2 infections and 11 implant-related. There were no neurological complications in any of the patients during the treatment period.

Conclusion: Growing rods are safe and effective in selected patients with congenital spinal deformities. The scoliosis angle, spinal growth and the SAL improved. The rate of complication is acceptable and most importantly there were no neurological complications.

Poster #7

Abnormal Morphogenesis in the Spondylocostal Dysplasia/Pudgy Mouse

Frederic Shapiro, MD (Children's Hospital Boston)

Introduction: The pudgy mouse (Pu/Pu) has axial skeleton abnormalities similar to human congenital scoliosis. Mutation in the spondylocostal dysplasia/pudgy gene delta-like3 (Dl13) is the initiating abnormality. We study the pudgy mouse abnormal morphogenesis.

Methods: Assessments in 66 mice [36 affected (Pu/Pu) and 30 non-affected (Pu/+; (late embryo to 6th post-natal week)] include: whole mount preparations (7 pu/pu, 5 pu/+); antero-posterior radiographs of vertebrae and ribs (19 pu/pu and 13 pu/+); and histology (23 pu/pu, 19 pu/+). Serial sections (60-200) are assessed from 6 pu/pu spines.

Results: In each pudgy mouse the pattern of vertebral and rib abnormalities is different, including differences in 7 groups of affected siblings from the same litter. RIBS: Abnormalities include: absent ribs [deletions], fused ribs [confluent rib origin sites with peripheral branching], and irregular spacing. Bilateral abnormal rib symmetry is never seen. VERTEBRAL BODIES: Deformation is seen in virtually every vertebral body. Patterns of abnormality in random array involve failure of segmentation [block vertebrae, unilateral bars] and failure of formation [wedged, hemi-, vestigial and bifid vertebrae]. Bone in the vertebral bodies develops normally by endochondral and intramembranous mechanisms but with inappropriate shapes and positions. INTERVERTEBRAL DISCS: Intervertebral discs are markedly abnormal [completely absent, partially absent, thicker or thinner, vertically or obliquely positioned]. A central symmetric nucleus pulposus is virtually never seen.

Conclusion: 1. Each pudgy mouse, including siblings from the same litter, has a different pattern of deformity. A single molecular defect alone cannot explain all the morphologic phenomena. The variable appearance from mouse to mouse indicates that the gene abnormality is expressed early in embryogenesis but that differing secondary inductive/epigenetic effects take precedence in outlining the abnormal pattern by a cascade of differing multi-molecular changes. 2. In radiolucent regions between the osseous vertebral bodies the tissue can be disc material or cartilage. 3. Failure of segmentation, failure of formation, and rib anomalies are seen all commingled in the same axial skeleton.

Poster #8

A Prospective Study Characterizing Pedicle and Neurocentral Synchronosis Development in Infantile and Juvenile Idiopathic Scoliosis Using Magnetic Resonance Imaging

Hong Zhang, MD (Texas Scottish Rite Hospital for Children); Daniel J. Sucato, MD, MS; Pamela Nurenberg, MD; Anna McClung, RN

Introduction: The neurocentral synchronosis (NCS) is the growth plate of the spine which may have some role in the development and/or progression of infantile (IIS) and juvenile idiopathic scoliosis (JIS). The objective of this study was to analyze the developmental asymmetry of the pedicle and NCS in IIS and JIS patients.

Methods: True axial MRI images were obtained in the thoracic and lumbar vertebrae of 15 patients who had IIS and JIS. The axial images were acquired to ensure they were symmetric to both pedicles, and parallel to the superior endplate of the vertebra. The images for the vertebrae in the major curve were digitally analyzed for the following parameters (Figure): 1) NCS developmental stages (6-point scale: 0- no closure to 5- 100% closure); 2) NCS width and thickness; 3) pedicle width and length; and 4) vertebral body area. Comparisons between the concavity and convexity of the each vertebra were performed.

Results: There were 12 females and 3 males with an average age of 5.8 years (0.8 to 10 years). The average curve magnitude was 40.1 degree (14 to 70 degree) with 11 thoracic and 4 TL/L curves and the average apical vertebral rotation was 17.2 degree. The concave NCS morphology was 29% wider and 23% thicker than the convexity (P<0.05). The concave pedicle length was 9% greater than the convexity (P<0.05). There was a positive correlation between the NCS width and the pedicle length at the apical/periapical vertebrae (P<0.05). The increased NCS and pedicle morphology on the concavity correlated with vertebral axial rotation (P<0.008).

Conclusion: Developmental asymmetry of the NCS, pedicle and vertebral body was seen in IIS and JIS patients. The concave NCS, pedicle and vertebral body had greater growth when compared to the convexity and were associated with greater vertebral axial rotation and the NCS may play a role in the development or progression of idiopathic scoliosis in these young patients. Growth inhibition of the concave NCS may be a strategy for surgical treatment of early onset scoliosis.

Significance: This study demonstrated that the concave NCS and pedicle had greater growth when compared to the convexity in IIS and JIS patients. Growth inhibition of the concave NCS may be a strategy for surgical treatment of early onset scoliosis.

Table: NCS, Pedicle and Vertebral Body Measurement in the Vertebrae of Major Cobb Curve

Vertebrae in Major Cobb Curve	Axial Rotation (Degree)	NCS Scale		NCS Width (mm)		NCS Thickness (mm)		Pedicle Length (mm)		Vertebral Body Area (mm ²)	
		Concavity	Convexity	Concavity	Convexity	Concavity	Convexity	Concavity	Convexity	Concavity	Convexity
Upper End	1.6	1.2	1.6	5.2	4.7	1.3	1.2	18.9	19	149.2	150.1
Apex-2	9.2	1.1	1.6	6.1*	4.6	1.6*	1.3	21.2*	19.9	172.5*	159.6
Apex-1	14.3	1.1	1.6	6.5*	5	1.5*	1.2	21.6*	19.7	186.7*	169.4
Apex	17.2	1.3*	2.3	6.4*	4	1.4*	1	22.3*	19.8	182.9*	173.1
Apex+1	16.4	2.3*	3	4.6*	2.6	1.2*	0.7	22.6*	20.4	219.8*	196.7
Apex+2	11.3	2.1	2.3	5.1*	4.2	1.2	1.1	23.3*	21.6	226.3*	203.1
Lower End	4.3	2.7	2.7	3.3	3.5	0.7	0.7	21.8	21.8	241.9	235.9

* P < 0.05, Concavity vs. Convexity.

Poster #9

The Standard Lateral Radiograph Does Not Represent Reality at the Thoracic Apex in Adolescent Idiopathic Scoliosis: A 3-Dimensional Analysis Confirms Lordosis

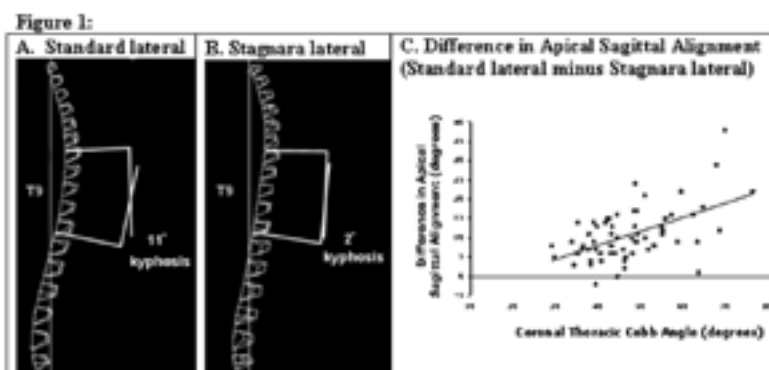
Katsuhiko Hayashi, MD; Peter O. Newton, MD (Rady Children's Hospital and Health Center); Jeff B. Pawelek, BS; Vidyadhar V. Upasani, MD; Carl-Éric Aubin, PhD, P.Eng; Hubert Labelle, MD; Lawrence G. Lenke, MD; Roger P. Jackson, MD; Ian A. Stokes, PhD; The SRS 3-D Classification Committee

Introduction: The Stagnara lateral x-ray view has been used to assess the degree of apical lordosis in patients with thoracic scoliosis. The purpose of this study was to perform a 3-dimensional analysis to identify differences in the measured thoracic sagittal profile between the standard lateral projection and the Stagnara lateral view in patients with thoracic adolescent idiopathic scoliosis (AIS).

Methods: Sixty-six patients with right thoracic AIS, reviewed by the SRS 3-D Classification Committee, were evaluated using 3-dimensional reconstructions of PA and lateral standing radiographs. A measurement of sagittal curvature from 2 vertebral levels above and below the thoracic apex (5 vertebrae) was recorded from the standard lateral view (Fig 1A). The 3-D reconstruction was then rotated to achieve a "true" lateral view of the apical vertebra and the sagittal apical curvature was re-measured (Fig 1B). The difference in the two measures of sagittal apical alignment was compared using a repeated measures ANOVA ($p < 0.05$), and then correlated to the coronal thoracic Cobb using a Pearson's correlation analysis ($p < 0.05$).

Results: The thoracic coronal spinal deformity averaged $47^\circ \pm 10^\circ$ with thoracic apices ranging from T8 to T11. The apical thoracic sagittal curvature in the standard lateral view averaged $11^\circ \pm 10^\circ$ of kyphosis (range: -8° to 38°). This was statistically greater ($p < 0.001$) than the apical sagittal curvature in the Stagnara lateral view that averaged $1^\circ \pm 9^\circ$ (range: -23° to 22°). The standard lateral view was rotated an average of $13^\circ \pm 4^\circ$ to achieve the ideal Stagnara lateral view of the thoracic apex. There was a statistically significant correlation between increasing thoracic scoliosis and the difference between the standard lateral and the ideal Stagnara lateral sagittal apical Cobb measurements ($r = 0.55$; $p < 0.001$), (Fig 1C).

Conclusion: This 3-D assessment of thoracic scoliosis demonstrates a consistent loss of kyphosis within the 5 apical vertebrae. The "true" apical kyphosis in AIS is over-estimated by an average of 10° compared to the standard lateral radiograph. The larger the thoracic scoliosis, the larger the error in the apical kyphosis measured on the standard lateral x-ray.





Poster #10

The SRS Outcome Questionnaire can Discriminate Between Patients with Spondylolisthesis and Normal Healthy Adolescents.

Stefan Parent, MD, PhD (Ste-Justine University Health Center); Julie Joncas, RN; Marie Beausejour; Marjolaine Roy-Beaudry, MSc; Martin Forcier, MSc; Hubert Labelle, MD

Introduction: The SRS-22 has been shown to be able to discriminate between patients with adolescent idiopathic scoliosis (AIS) and normal healthy adolescents. The SRS-22 is currently used to evaluate adolescent patients with developmental spondylolisthesis but its reliability and validity has not been evaluated for this condition. The objective of this study was to test the response of the SRS Outcome Questionnaire in an adolescent population with spondylolisthesis.

Methods: The validated SRS-22 was used in 113 patients with spondylolisthesis, 144 with AIS and 64 healthy controls. Reliability was assessed with the internal consistency coefficients (Cronbach α), concurrent validity was done by comparison with the SF-12 and discriminant validity using ANOVA on clinical variables.

Results: The SRS-22 showed a good global internal consistency and in all of its domains. Mean scores and significant differences can be found in table 1. The factorial structure was coherent with the original questionnaire, with 59% of explained variance. High correlation coefficients were obtained between SRS-22 and SF-12 corresponding domains. Young children had higher scores than older patients in Activity and Mental health. Grade 1 as well as high grade (50% slip) patients had lower scores than grade 2 patients in Total and Activity domains. Patients having conservative treatment were less active and less satisfied compared to untreated and surgical patients. Patients with associated scoliosis had lower scores (Total score, Activities, Mental Health and Self-image) than patients with no secondary condition but without any statistical significant difference. Scores showed differences between the spondylolithesis, AIS and healthy subjects in the Total scores, Activities, Pain and Self-Image confirming that the SRS-22 can discriminate between the 3 groups.

Conclusion: The SRS-22 showed satisfactory reliability and validity for clinical use in adolescents with spondylolisthesis.

Significance: The SRS-22 demonstrates a clear gradient in response between subjects with low grade and high grade spondylolisthesis, AIS patients and healthy controls.

Poster #11

***Extravasation of rhBMP-2 with Use of Postoperative Drains After Posterolateral Spinal Fusion**

James M. Mok, MD (University of California, San Francisco); Salim K. Durrani, MS; Samantha L. Piper; Serena S. Hu, MD; Vedat Deviren, MD; Sigurd Berven, MD; Shane Burch, MD

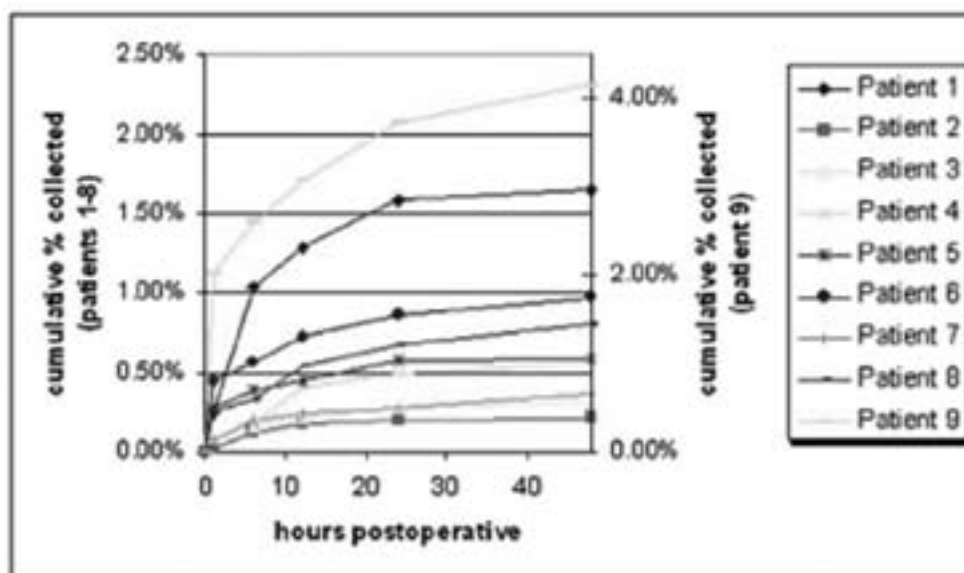
Introduction: Retention of rhBMP-2 at the fusion site is essential for clinical efficacy and avoidance of unintentional bony growth in other areas of the spine. In vitro studies have shown a large degree of rhBMP-2 release from the sponge within the first 48 hours. It is unknown what effect wound drainage may have on the local concentration of BMP at the posterolateral site.

Methods: The entire contents of drains were collected for 48 hours postoperatively from 9 patients who underwent instrumented posterolateral fusion with rhBMP-2. In order to increase the solubility of rhBMP-2, specimens were acidified with 15% 0.1 M HCl and titrated to pH 4.5. Following acidification, specimens were diluted in buffer solution [25.3 mM L-glutamic acid, 1.875 mM NaCl, 2.5% glycine, 0.5% sucrose, 0.01% polysorbate 80, pH 4.5] until the rhBMP-2 concentration was within the working range of the standard curve. The total amount collected was calculated from the volume and concentration of BMP-2 as measured by ELISA.

Results: A median 68 mcg of BMP-2 (range, 13-498) was recovered from drains, representing a median 0.58% (range, 0.21-4.2%) of the amount implanted; adjusted for yield rate, a median 1.08% was recovered. Cumulative drain volume was median 1220 cc (range, 345-1,840). No rhBMP-2 was detectable in drainage specimens from 3 control patients. No significant relationships were found between percentage of BMP-2 extravasation and amount implanted, number of levels, and drainage output. A mean 54% of the total amount recovered was in the drain within the first 6 hours.

Conclusion: The greater bleeding and muscular compression associated with posterolateral fusion did not result in a substantial amount of rhBMP-2 extravasation into postoperative drains. This degree of recovery occurred in the presence of substantial drainage, drain suction, and patency of the drain tubing. The kinetics of rhBMP-2 extravasation into the drain are consistent with diffusion.

Significance: Based on the small rates of recovery, drains may be placed following surgeries involving large blood loss without the loss of significant amounts of implanted rhBMP-2 into the drain.



Cumulative percent covered

* The FDA has not cleared a drug and/or medical device in use described in this presentation (i.e., the drug or medical device is being discussed in an off-label use). For full information see page 10.



Poster #12

Intervertebral Foramen Size and Volume Changes in Relation to Isthmic Spondylolisthesis

Jeffrey M. Spivak, MD (NYU Hospital for Joint Diseases); Martin Quirno, MD; Jonathan R. Kamerlink, MD; Frederick Kummer

Introduction: Radicular pain and varying degrees of nerve root dysfunction are present in many isthmic spondylolisthesis patients and may be the result of compression of the L5 root within its foramen. The purpose of this study is to examine the change in intervertebral foramen geometry in relation to the slip percentage, slip angle, and disc height, using a cadaveric model of L5-S1 isthmic spondylolisthesis.

Methods: The L5 vertebrae and sacrum of six (6) human cadaver specimens were used. Bilateral pars defects were created in L5 which was then constrained, along with the sacrum, on an adjustable frame allowing independent positioning of each bony element. Clay molds of the foramen were made for different L5-S1 positions, varying the sagittal translation, slip angle, and disc height; all combinations were tested. Molds were frozen then sliced into six 2mm increments using a customized microtome. The medial surface of each slice was digitized and its cross-sectional area was measured to calculate the foraminal area. In addition, the volume of each foramen was calculated.

Results: The areas and volumes of the foramen at a sagittal slip of 0%, slip angle of 0°, and 10 mm disc height were used as a control. A decreased of disc height from 10 mm to 5 mm and to 0 mm significantly ($p < 0.01$) decreased the cross-sectional area and volume of the foramen. A similar result was observed when increasing percent slip from 0% to 25% and 50% and slip angle from 0° to -30° ($p < 0.05$). With a 10 mm disc height and incremental slip from 12.5% to 50%, a slip angle of 20° lordosis was associated with significantly smaller foraminal area and volume as compared to 10° kyphosis ($p < 0.05$). At a 0 mm disc height with an incremental slip from 0% to 50%, an increase of slip angle from 0° to 20° of lordosis significantly ($p < 0.03$) decreased the foraminal area and volume.

Conclusion: Disc height loss has the largest effect in decreasing dimensions of the intervertebral foramen in isthmic spondylolisthesis. Lordotic slip angles decreased foraminal cross-sectional area, but to a lesser degree. Surgical treatment strategies should include restoring disc height loss to decompress the foramen. Lordotic correction without disc height restoration will place the L5 root at risk.

Poster #13

Anterior Dual Rod versus Posterior Pedicle Fixation Surgery for the Surgical Treatment in Lenke 5C Adolescent Idiopathic Scoliosis: A Multicenter Matched Case Analysis.

Matthew Geck, MD (University Medical Center at Brackenridge); Anthony S. Rinella, MD; Dana Hawthorne, BS, MPAS; Angel Macagno, MD; Brenda A. Sides, MA; Linda Koester; Lawrence G. Lenke, MD; Michael F. O'Brien, MD; Keith H. Bridwell, MD; Harry L. Shufflebarger, MD

Introduction: The treatment of choice for Lenke 5 AIS remains a matter of debate. Both anterior and posterior approaches have shown to have good correction of deformity parameters with low reoperation rates. Direct clinical comparisons are few in number, limited by the heterogeneity in the patient groups and by surgeon biases regarding approach and levels.

Methods: We analyzed a sequential database of 96 patients with Lenke 5C AIS curves based on radiographic and clinical data at 3 institutions surgically treated between 2000 and 2005 with minimum 2-year follow up. These patients were case matched with the following criteria: age within 1 year, sex, curve within 5 degrees, lower end vertebrae (LEV), and lowest instrumented vertebrae (LIV). 21 patients treated with posterior pedicle screw instrumented fusions at 1 institution (group PSF) were matched with 21 patients with anterior dual-rod instrumented fusions at 2 other institutions (group ASF).

Results: There were no significant differences between groups in any preoperative clinical or the following radiographic parameters (age: PSF 15yrs, ASF 15.1yrs; curve size: PSF 49.8 degrees, ASF 48.9 degrees; Apical vertebral translation (AVT): PSF 50mm, ASF 47mm; LIV translation (LIVT): PSF 25mm, ASF 29mm; LIV tilt: PSF 28 degrees, ASF 27 degrees). At final follow-up, the major curve measured 8 degrees (83% correction) in the PSF group, compared to 13 degrees (72% correction) in the ASF group (p=0.002). There were no final follow up differences in the other parameters listed above (AVT, LIVT, LIV Tilt). EBL was similar in both groups, and length of hospital stay was significantly (PSF 4.3 days vs. ASF 6.5) shorter in the PSF group. There were no complications in either group which extended hospital stay or required an unplanned second surgery.

Conclusion: At a minimum of 2 years follow-up in a multicenter, matched case analysis, adolescents with Lenke 5C curves demonstrated statistically significantly better curve correction and shorter hospital stays when treated with a posterior release with pedicle screw instrumented fusion compared to an anterior instrumented fusion with dual rods for similar patient populations. There were no unplanned reoperations for any reason in either group.

Table 1: Other balance and sagittal plane measurements

PSF	Disc below LIV	Sagittal T5-T12	Sagittal T12-LIV	Sagittal T12-S1	Sagittal Plumb
Preop	7.9°	18	-11	-57	-45mm
Final	4.1	24	-25	-62	-37
ASF					
Preop	3.6	23	-3	-56	-19
Final	6.3	26	-4	-58	-23



Poster #14

Peak Oxygen Consumption Measures During Graded Exercise Testing in Scoliotic versus Non-Scoliotic Adolescents

Jody L. Clasey, PhD; Vishwas Talwalkar, MD; Henry Iwinski, Jr., MD; Joan C. Darbee, PhD; Todd Milbrandt, MD, MS (Shriners Hospital)

Introduction: Pulmonary ventilation limitations due to severe thoracic curves are well known, and often measured during static pulmonary spirometry testing (SPST). This testing does not assess the cardiopulmonary function effects of the 3-dimensional chest wall distortion that is apparent in individuals with scoliosis. Correlation to exercise tolerance is also not known. Our study compared oxygen consumption (VO₂) peak measures from a maximal graded exercise testing (GXT) protocol in patients with thoracic idiopathic scoliosis versus control subjects.

Methods: GXT was performed by 6 subjects (SS) ages 12 to 16 years with right thoracic curve (> 40 deg) scoliosis (Lenke 1) prior to spinal fusion; and 6 subjects (CS) without scoliosis matched for sex, ethnicity, age, and BMI for sex and age classification. The GXT was a standardized intensity (speed and grade) progressive (3 minutes/stage) treadmill protocol with VO₂ measure determined by indirect calorimetry. All subjects had a DXA scan to determine fat-free mass (FFM), and mineral-free lean mass (MFL), thus allowing VO₂ peak measures to be expressed relative body weight and these tissue masses.

Results: Absolute VO₂ (L/30 sec) peak was greater in the CS (1.74 ± 0.15) versus the SS (1.50 ± 1.11) group. The CS group also had greater VO₂ peak expressed relative to body weight (31.0 ± 2.8 vs 27.8 ± 1.2 ml/kg/30 sec), to FFM (46.4 ± 3.0 vs 42.2 ± 2.0 ml/kg/30 sec), and to MFL (49.2 ± 3.2 vs 44.9 ± 2.1 ml/kg/30 sec). This resulted in a 16.1% greater absolute, 11.6% greater body weight relative, 10.1% greater FFM relative, and a 9.6% greater MFL relative VO₂ peak achieved by the CS group.

Conclusion: It has been previously demonstrated that scoliosis imposes limitations that can be measured during SPST. We have shown that scoliosis adversely impacted physical activity performance measures reflected by decreased absolute and relative VO₂ peak measures.

Significance: This study demonstrated that there are probable function limitations during dynamic physical activity. Further research is necessary to determine the impact and effectiveness of spinal instrumentation and fusion on VO₂ parameters during exercise and other activities of daily living.

Poster #15

Restoration of Thoracic Kyphosis in Adolescent Idiopathic Scoliosis. Comparative Analysis of Two Methods of Reduction with Posterior Instrumentation.

Jean-Luc Clement, MD (Lenval Hospital); Edouard Chau, MD; Marie-José Vallade, MD; Bruno Vare, MD

Introduction: Recent publications concerning Adolescent Idiopathic Scoliosis (AIS) confirm the moderate correction of thoracic hypokyphosis by posterior instrumentation with hooks and also with pedicle screws. The purpose of this study was to compare radiographic results of two different methods of reduction: Cantilever Reduction (CR-Moss-Miami system) and Simultaneous Translation on Two Rods (ST2R-Passmed system).

Methods: Retrospective comparative analysis of two consecutive cohorts of patients treated by the same surgeon. Forty-two patients (Lenke type 1, 2 and 3) underwent a posterior spinal fusion and instrumentation (CR series: n=20 - ST2R series: n=22). The mean follow-up was 72 months (range 36 to 122) in the CR series and 47 months (range 24 to 73) in the ST2R series. Thoracic kyphosis (T4-T12) and Cobb angle measurements have been evaluated preoperatively, at 6 weeks, 1 year and at final visit, by an independent observer. For CR series, polyaxial pedicle screws and one or two thoracic hooks have been used. For ST2R series, polyaxial pedicle screws and polyaxial claws have been implanted. Three groups of preoperative kyphosis were generated: 11 patients with severe hypokyphosis (T4T12 10°) (CR: 5 patients; ST2R: 6 patients); 11 patients with mild hypokyphosis (10° to 20°) (respectively 4 and 7) and 20 patients with normal kyphosis (>20°) (respectively 11 and 9).

Results: At final follow-up, for patients with severe hypokyphosis, the mean gain was 14° in the CR series (8° preoperative - 22° postoperative) and 25° in the ST2R series (6° to 31°) (p<0.05). Concerning patients with mild hypokyphosis, the mean gain were respectively 7° (16° to 23°) and 18° (16° to 34°) (p<0.05). After surgery, 3 patients of CR series always had hypokyphosis and no one in the ST2R series. In coronal plane, the mean correction of scoliosis was similar for both groups (75% vs 69% (NS)).

Conclusion: Simultaneous reduction on two rods provides a better correction of thoracic kyphosis than the cantilever reduction on patients with preoperative hypokyphosis. This technique seems to restore normal thoracic kyphosis.

Poster #16

Characterize Neurocentral Synchondrosis Developmental Stages in Normal Pediatric Patients Using Magnetic Resonance Imaging

Hong Zhang, MD (Texas Scottish Rite Hospital for Children); Daniel J. Sucato, MD, MS; Pamela Nurenberg, MD; Anna McClung, RN

Introduction: The neurocentral synchondrosis (NCS) is a growth plate at the base of pedicle presumably responsible for normal growth of each vertebra and is most active in the young age group. Detailed analysis of the normal closure of this growth plate has not been performed. The objective of this study was to determine the development of the NCS using magnetic resonance imaging (MRI) in normal infantile and juvenile patients.

Methods: 34 normal pediatric patients who had MRI axial images from T1 to L5 were assigned to 3 groups: infantile group (n=11): <3 years old; juvenile-young group (n=16): 4-7 years old; and juvenile-old group (n=7): 8-10 years old. T2-weighted axial MRI images were used to analyze the NCS developmental stages using a custom 6-point scale (Figure): 0: actively open with 0% closure; 1: < 25% NCS closure; 2: 25-49% NCS closure; 3: 50-74% NCS closure; 4: 75-99% NCS closure; and 5: 100% NCS closure. For the stage 0 closure NCS, the length and thickness of the NCS were measured.

Results: The NCS was open without closure in all patients less than 3 years old. The NCS had 50-74% closure in the lumbar region (L1-5) at 4 years while the thoracic NCS were actively open. At 5 years, the proximal thoracic (T1-6) NCS had <25% closure while the middle (T7-9) and distal (T10-12) thoracic NCS demonstrated no closure. At 6 years, the middle and distal thoracic NCS had < 25% closure (Table). For the NCS without closure, the average length and thickness were 7.9 x 1.5 mm on the left and 8.0 x 1.4 mm on the right which was not significantly different. For the NCS with closure, the left and right NCS closure rate was not significantly different.

Conclusion: The NCS developmental stage is age and vertebral level dependent. The NCS closes from the lumbar and the proximal thoracic spine to the middle / distal thoracic spine and times from very early juvenile to the adolescent. The NCS symmetry bilaterally occurred not only during the active open, but also the long closure period. The NCS symmetric open and/or closure may be important to maintain the normal spine alignment.

Significance: This study was done to determine the NCS development in normal pediatric patients. It provided significant information for growth modulation treatment of early onset spinal deformities.

Table. NCS Developmental Stage Scale at the Different Level in the Different Age Group

	Infantile Group		Juvenile-Young Group								Juvenile-Old Group	
	0-3 Years (n=11)		4 Years (n=4)		5 Years (n=4)		6 Years (n=2)		7 Years (n=5)		8-10 Years (n=7)	
	Left	Right	Left	Right	Left	Right	Left	Right	Left	Right	Left	Right
Proximal Thoracic (T1-6)	0	0	0	0	1.2	1.3	2.1	2.2	2.7	2.6	2.7	3
Middle Thoracic (T7-9)	0	0	0	0	0.6	0.5	1.7	1.4	2.1	2	2.6	2.7
Distal Thoracic (T10-12)	0	0	0.4	0.2	0.5	0.4	1.9	1.9	2.8	2.6	3.3	3.2
Lumbar (L1-5)	0	0	3.2	3.1	2.5	2.5	3.8	3.7	3.9	3.7	4	4.1

* The FDA has not cleared a drug and/or medical device in use described in this presentation (i.e., the drug or medical device is being discussed in an off-label use). For full information see page 10.

Poster #17

Characterization of Anti-HLA Antibody Response in Recipients of Freeze Dried Cadaveric Cancellous Bone Graft

Michael S. Shuler, MD; Walter B. McClelland, Jr., MD (Emory University School of Medicine); Martin N. Wijkstrom, MD; Timothy S. Oswald, MD; David K. Monson, MD; Robert W. Bruce, Jr., MD

Introduction: Recipients of fresh allograft bone have demonstrated an immune response with formation of anti-HLA antibodies. The immune response to freeze-dried allograft bone chips is poorly described. The development of anti-HLA antibodies can preclude the patient from future cell or organ transplantation. The purpose of this study was to evaluate the formation of anti-donor HLA antibodies in recipients of freeze-dried allograft bone.

Methods: Pediatric scoliosis subjects receiving freeze-dried cancellous allogeneic bone chips for posterior spinal fusions were considered. Enrolled patients donated blood preoperatively, at six weeks postop, and again at 12 months postop. A patient was excluded from the study if an event occurred which might result in a confounding immune response. Immune response was determined by PRA assay for HLA class I and II antigen.

Results: Twenty-five consecutive pediatric scoliosis patients were enrolled. Four patients required blood transfusions and were excluded from analysis. Two patients refused postoperative blood draws. The mean volume of allograft chips was 110 mL. Two subjects' PRA results were positive at 6 weeks postop. Both patients were also positive at preop screening with unchanged PRA levels. There was no detectable immune response to freeze dried allograft cancellous chips postop. Using the previously described sensitization rate of 21%, the p-value was determined to be 0.011.

Conclusion: Freeze dried allograft chips have been used without consideration of immune response or clinical significance extending beyond the orthopaedic outcomes. There has been one previous report limited to freeze dried allograft demonstrating a immune response of 21%. The results of this study do not coincide with the previous study. The lack of immune response may be due to newer processing techniques employed by the tissue bank supplying the allograft samples.

Significance: Patients with identifiable risk factors for future transplantation should avoid fresh allografts if possible due to the sustained HLA sensitization. These risk factors include common disorders found in many orthopaedic patients. These patients can be counseled that freeze dried allograft chips do not pose the same risk for sensitization as fresh allograft tissue.



Poster #18

Antibiotic-Loaded Allograft Decreases the Rate of Deep Wound Infection after Spinal Fusion in Cerebral Palsy

Suken A. Shah, MD (Alfred I. duPont Hospital for Children); Battugs Borkhuu, MD; Andrzej Borowski, MD; Aaron Littleton; Kirk W. Dabney, MD; Freeman Miller, MD

Introduction: A major complication of spinal surgery in children with scoliosis due to cerebral palsy (CP) is a postoperative deep wound infection. Previous studies reported wound infection rates of 8.7-15% after spinal fusion surgery in children with CP. The concept of using antibiotic-loaded bone graft to provide local antibiotics has been explored in high risk patients, such as those with osteomyelitis or infected joint arthroplasty. There have been no reports of using antibiotic-loaded bone graft prophylactically in spine surgery.

Methods: After IRB approval, the medical records of 220 consecutive children with (CP) who underwent spinal fusion with unit rod instrumentation at a single institution for a primary spinal deformity between 2000 and 2006 with minimum 2 year follow-up were retrospectively reviewed. We evaluated the incidence of postoperative deep wound infection in patients with antibiotic-loaded bone graft (AbBGF) and those without (BGF).

Results: One hundred fifty-four patients received AbBGF during spinal fusion surgery and 6 patients (3.9%) developed a deep wound infection. Ten of the 66 patients (15.2%) without antibiotic-loaded bone graft developed a deep wound infection. The difference between groups was statistically different ($p=0.003$). The mean age at surgery, preoperative Cobb angle, correction rate, operative time, and estimated blood loss were not statistically different between the two groups. The length of hospital stay was decreased in the AbBGF group ($p<0.05$).

Conclusion: The incidence of deep wound infection after spinal fusion in 220 children with CP scoliosis decreased from 15% to 4% with the use of prophylactic antibiotics in corticocancellous allograft bone.

Significance: The use of antibiotic-impregnated bone graft during spinal surgery in children with cerebral palsy may decrease the incidence of deep wound infection, improve outcomes and reduce hospital stay.

Poster #19

Does Obesity Hide Adolescent Idiopathic Scoliosis?

Brandon T. Bruce, MD; Vishwas Takwalkar, MD; Henry Iwinski, Jr., MD; Janet Walker, MD; Todd Milbrandt, MD, MS (Shriners Hospital for Children)

Introduction: Childhood and adolescent obesity is a national epidemic that is having a significant impact in the field of pediatric medicine. Currently, 17.1% of adolescents are considered overweight, which is defined as being greater than the 95th percentile for age-normed body mass index (BMI). It is our hypothesis that increased BMI can influence scoliosis presentation.

Methods: Retrospective analysis of individuals presenting to the Shriners Hospital in Lexington Kentucky with the diagnosis of idiopathic scoliosis was undertaken. Patients with non-idiopathic curves and ages less than 9 were excluded. We documented each individual's age, sex, curve magnitude, height, and weight at presentation. Using these data we performed regression analysis to compare BMI to curve magnitude and to age at presentation.

Results: The group consisted of 427 individuals and 80% were female. No direct correlation between BMI and curve magnitude or age at presentation was revealed. However, female patients who presented with a Cobb angle greater than 50 deg had a significantly greater BMI than those with curves less than 50 deg ($P=0.0557$). In addition, individuals with a BMI greater than 23 presented later in life ($P=0.0246$).

Conclusion: Adolescent obesity continues to increase at alarming rate and is known to have an effect on many disease states. From our study we can conclude that females presenting with large curves (> 50 deg) were older and did have a greater BMI. The reasons for these findings may be that the subcutaneous fat may make curve detection more difficult. There may be an influence of endocrine factors as well, with recent literature showing an increased fat mass can lead to earlier puberty. The consequence of our findings could be the elimination of bracing as a treatment option if the curves are too big and the patient is too skeletally mature. In addition, current recommendations for screening for scoliosis may need to be re-examined in the obese child.

Significance: With ever increasing rates of childhood obesity, clinicians need to be aware of the changes this may have in the presentation and management of idiopathic scoliosis.



Poster #20

**JOHN H. MOE AWARD NOMINEE FOR BEST BASIC SCIENCE PRESENTATION

Effects of a Growth Modulation Device on the Immature Goat Spine

John Thometz, MD (Medical College of Wisconsin); XueCheng Liu, MD, PhD

Introduction: A growth modulation device (GMD) was developed to explore the hypothesis: higher compressive forces induced by the GMD between intervertebral regions lead to changes of vertebral endochondral ossification.

Methods: The four skeletally immature goats were approached via a standard thoracotomy from T6 to T10. The right side of the spine was exposed and instrumented with the GMD. One goat was sacrificed at 1, 2, 3, and 6 months following spinal surgery, respectively. Radiographs and histomorphometry were performed.

Results: The average Cobb angle between T2 to T12 was increased from 3 to 10 degrees. The length between T6 and T10 increased from 8.9cm to 12.6cm. Bony density and cartilage density on the instrumented side vertebrae were greater than on the uninstrumented side. The heights of physis were decreased approximately 9.4% on the anterior vertebral physis of the instrumented side, but to less extent on the posterior portion.

Conclusion: The GMD yields an appreciable impact on the bony and cartilage density, and endochondral ossification height.

Significance: The study provides an insight into the biophysiologic response of the immature spine to fusionless device.

Poster #21

Comparison of Pedicle Screw Fixation with Hybrid Sublaminar Wiring Instrumentation for Correction of Spinal Deformity in Patients with Cerebral Palsy

Ujjwal K. Debnath, FRCS (Nottingham University Hospital); Hossein Mehdian, FRCS, MD; Nanjundappa S. Harshavardhana, MS(Orth), Dip. SICOT; Harshad Dabke, FRCS; John K. Webb, MBBS, FRCS

Introduction: We compared the amount of spinal deformity correction by using two methods of instrumentation [pedicle screw (PS) construct only with a hybrid sublaminar wire and pedicle screw construct (HS)] in CP patients.

Methods: 22 male and 14 female CP patients with average age of 16 years (range 8 -25 years) underwent surgical correction for spinal deformity. Indications for surgery included loss of sitting balance, progression of spinal deformity, pelvic obliquity and back pain. Group 1 (18 patients) had PS construct only and Group 2 (18 patients) had HS constructs. 32 patients (90%) required sacral fixation. 5 patients in Group 2 required anterior release. All patients had a minimum follow-up of 2 years (range 2-13 years). Clinical and radiographic analyses were performed in both groups.

Results: Mean Cobb angle in Group 1 improved from 65.0 (range 120-950) to 18.50 (range 0-280) and in Group 2 from 77.60 (range 400-1050) to 34.80 (range 100-620) [$p < 0.05$]. Mean pelvic obliquity in Group 1 improved from 14.30 (range 00-420) to 2.50 (range 00-50) and in Group 2 from 24.70 (100-510) to 9.70 (range 20-180) [$p < 0.05$]. Mean surgical time in Group 1 was 224 minutes as compared to 260 minutes in Group 2 [$P < 0.05$]. 6 patients in Group 2 had proximal junctional kyphosis and implant failure requiring revision. One patient in each group had infection treated with antibiotic therapy.

Conclusion: PS fixation in CP patients, allowed significant correction of large curves without anterior release, eliminated proximal junctional kyphosis and instrumentation failure. Correction of pelvic obliquity was also superior due to three-dimensional corrective force of pedicle screws. Although PS fixation is expensive and technically demanding, it outweighs the costs incurred by two-stage surgery because of its superior durability correction.

Significance: Pedicle Screw constructs allowed significant correction of large curves without anterior release, eliminated proximal junctional kyphosis and instrumentation failure.



Poster #22

Thoracoplasty in Idiopathic Scoliosis -Should We Keep Doing it?

B. Stephens Richards, III, MD (Texas Scottish Rite Hospital for Children); Daniel J. Sucato, MD, MS; Charles E. Johnston, MD; Lawrence G. Lenke, MD; Timothy R. Kuklo, MD, JD; Mohammad Diab, MD; Spinal Deformity Study Group

Introduction: Thoracoplasty is used to improve the cosmetic appearance in patients with excessive rib humps. This study was undertaken to test the hypothesis that for patients undergoing PSF using a hybrid construct for idiopathic scoliosis, there will be no measurable differences between those who had thoracoplasty and those who did not have thoracoplasty.

Methods: From a multicenter scoliosis database, 93 patients with thoracic (Lenke types 1-4) curves who underwent PSF using hybrid constructs, and who had a minimum 2-year followup, were evaluated. 20 of these patients had thoracoplasty (Group A) while 73 did not (Group B). Clinical rotation (scoliometer), radiographic rotation (Nash-Moe), body mass index, and SRS-30 measures (appearance, satisfaction, pain) were evaluated preoperatively and two years postoperatively.

Results: Preoperatively, there were no significant differences between groups (A/B) with regard to thoracic curve size (61.6°/62.3°), clinical rotation (15.0/14.7), radiographic rotation, or body mass index (22.2/23.7). Of the three SRS domains tested, the preoperative satisfaction score was higher in the thoracoplasty group, but no differences were found in pain or appearance scores. Two years postoperatively, there were no significant differences between groups (A/B) with regard to thoracic curve size (26.3°/22.9°), radiographic rotation, body mass index (22.2/23.1), or any of the three SRS domain scores. The clinical rotation was larger for the thoracoplasty group (13.2/11.2) [p=0.039].

Conclusion: Two years following thoracoplasty in patients treated with hybrid constructs, no improvements were noted in the patients' SRS domains of appearance, satisfaction, or pain, when compared to those who did not have thoracoplasty. The thoracoplasty group had slightly greater residual clinical rotation. This information brings into question the usefulness of thoracoplasty.

Poster #23

***Shape Memory Metal Rods Tested in a Porcine Model: Single Rod Constructs Result in Greater Deformity at One Week**

Peter O. Newton, MD (Rady Children's Hospital, San Diego); Christine L. Farnsworth, MS; Vidyadhar V. Upasani, MD; Reid Chambers, BA; Seung Hwan Yoon, MD; Paul Firkins, PhD

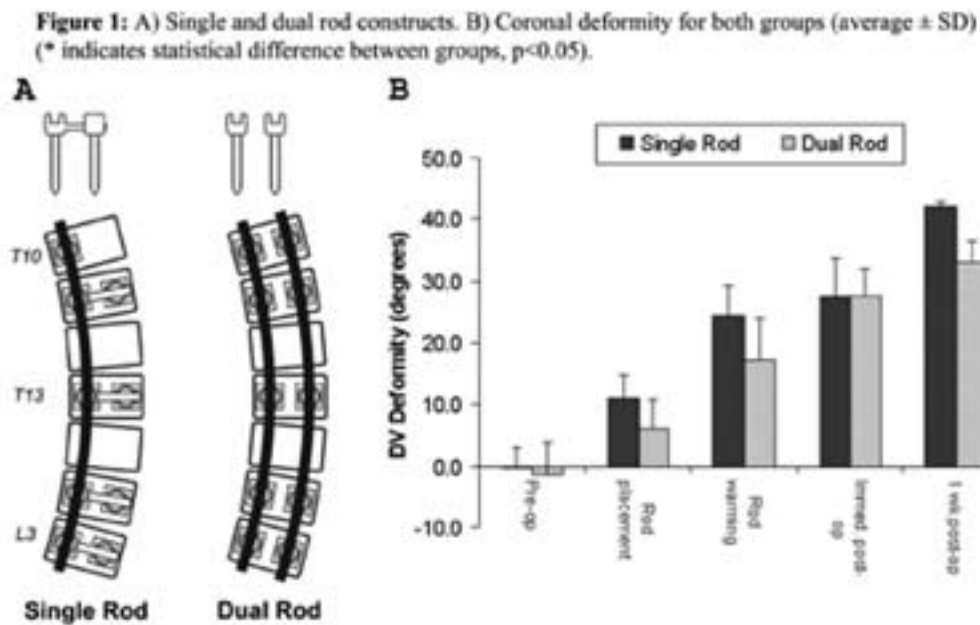
Introduction: In the surgical treatment of spinal deformity, shape memory metal (Nitinol) rods can theoretically be approximated to a curved spine in their malleable, cooled state, then achieve spinal deformity correction as they return to their original shape with warming (straight in the coronal plane with a pre-contoured sagittal profile). A square cross-sectional rod profile may additionally allow deformity correction in the transverse plane when engaged in squared head pedicle screws. Single rod constructs, thought to be less constrained, may be able to achieve a greater deformity correction (clinically) / creation (experimentally), while dual rod constructs are likely more stable with less risk of implant failure. The purpose of this study was to determine the clinical feasibility and potential effectiveness of using single vs dual nitinol rod constructs by creating spinal deformity in an in vivo animal model.

Methods: 10 mature Yucatan mini-pigs were instrumented with single (n=5) or dual (n=5) nitinol rod constructs (Fig1A). The rods were instrumented straight at -15°C and allowed to return to their pre-contoured 90° coronal profile (twice the normal porcine lateral bending range of motion) after being warmed with a 41°C saline solution. Serial radiographs were obtained to follow deformity creation and compared between single and dual rod groups (p<0.05).

Results: Scoliotic deformity creation was observed in both single and dual rod groups during the surgery (Fig 1B) and was not significantly different at the completion of the procedure (28°± 6° vs 28°± 4°, p=0.95). One week following rod placement, however, coronal deformity in the single rod group progressed to 42°± 1°, which was significantly more than the dual rod group (33°± 3°, p=0.002).

Conclusion: Pre-contoured (90° coronal curve), square-cross section shape memory metal rods successfully created coronal spinal deformity in all 10 animals. The less constrained single rod constructs resulted in greater deformity creation compared to dual rod constructs, at one-week post-op, with no evidence of implant failure/screw pullout in either group.

Significance: Nitinol rods may be useful in achieving spinal deformity correction that occurs both acutely during surgery and increases post-operatively over time.



* The FDA has not cleared a drug and/or medical device in use described in this presentation (i.e., the drug or medical device is being discussed in an off-label use). For full information see page 10.

Poster #24

The Relation Between an Insertion Point of Thoracic Pedicle Screwing and Aorta

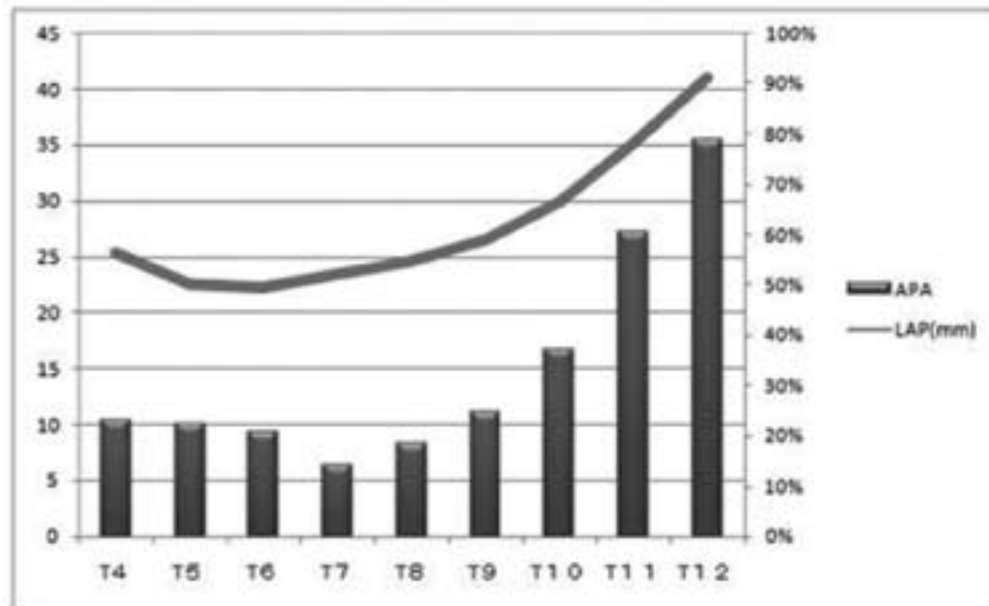
Yoshiyuki Okada, MD (National Hospital Organization Kobe Medical Center); Koki Uno, MD, PhD; Hiroshi Miyamoto, MD; Yoshihiro Inui, MD; Ko Tadokoro, MD; Naoatsu Megumi, MD

Introduction: In thoracic pedicle screwing (PS), there are many papers reporting the free-hand technique, though the perforation risk might increase. However, there were few papers reporting the concrete methods to avoid vascular complication.

Methods: To examine the safety length and direction of thoracic pedicle screws and screwing, pre-operative CT of 415 pedicles at concave side of the curve in 47 scoliosis patients were examined. We measured the length between an aorta and an insertion point of PS (LAP). We also measured the angle that subtended longitudinal line of the pedicle and the line drawn from the insertion point of PS to the aorta (APA).

Results: The aorta located closely to upper thoracic, shifted laterally down to midthoracic and shifted anteromedially down to thoracolumbar spine. The shortest LAP was 22.3mm at T6. The longest LAP was 41.2mm at T12. There was no statistical relation between magnitude of the curve and LAP and APA. The aorta located far laterally at T7 and APA at T7 was 11.2 degrees in average. The short LAP and small APA, which might be an important risk factor for vascular complication, was observed at T8-10.

Conclusion: These result suggests careful selection of length of pedicular screw and direction of screwing might be necessary when screwing at T8-10 concave side of the curve in scoliosis.



Poster #25

Charge Analysis of Adolescent Idiopathic Scoliosis Correction Surgery in 122 Consecutive Cases

Martin Quirno, MD; Jonathan R. Kamerlink, MD; Joshua D. Auerbach, MD; Thomas J. Errico, MD; Joseph W. Dryer, MD; Andrew H. Milby, BS; Baron S. Lommer, MD (NYU Hospital for Joint Diseases)

Introduction: Although providing efficacious and safe curve correction in the coronal and sagittal planes is the primary goal of surgical treatment in AIS, it is becoming increasingly important to do so in a cost-effective manner. This study sets out to determine the surgical and hospitalization charges for AIS correction surgery at one institution, as well as the relative contributions of various parameters to total charges.

Methods: We performed a retrospective review of 20,979 individual charges on 122 consecutive patients who underwent surgical treatment for AIS by 3 different surgeons between 2006-2007. Pertinent demographic, surgical, and radiographic data were recorded for each patient. A multivariate linear correlation analysis was performed to calculate which independent demographic, surgical, or radiographic components are predictive of higher charges. Finally, a separate one-way ANOVA analysis evaluating the predictive value of Lenke classification was performed.

Results: Patients' mean age was 15 (range 9 to 19) with a mean BMI of 21.7. Females (89) outnumbered males (39) on a 2:1 ratio. The mean measured proximal curve was 29°, main thoracic curve 50°, and thoracolumbar curve 41°. Independently significant increases were found for total charge per pedicle screw placed (\$1,260), level fused (\$2,147) and male patients (\$10,495) ($R^2 = 0.40, p < 0.001$). There was a significant difference in mean total charges with varying Lenke curve type: Type 1 = \$72,572 ± 15,894; Type 2: \$85,108 ± 16,891; Type 3: \$78,961 ± 18,329; Type 4: \$102,152 ± 25,927; Type 5: \$73,063 ± 18,032; Type 6: \$90,107 ± 20,403 ($p = 0.01$).

Conclusion: Instrumentation charges accounted for the highest percentage of total charges (34%) followed by ICU and inpatient room charges (19%), and OR (16%). The number of screws placed, number of levels fused, and male sex were identified as significant independent predictors of higher total charge.

Significance: An accurate analysis of surgical and hospital charges for AIS is of paramount importance to ensure future equitable allocation of medical reimbursements

Charges	Mean in US\$	Percentage of total charges
Instrumentation	26,661.64	34
Inpatient rooms + ICU	15,127.42	19
Operating Room	12,055.21	16
Miscellaneous	11,379.10	15
Bone grafts	6,179.51	8
Anesthesia	2,114.03	3
X-rays	1,480.63	2
Blood bank	765.82	1
Neuro-monitoring	580.64	0.8
Physical therapy	520.42	0.8
Fluoroscopy	297.15	0.4
Total	77,161.57	100

* The FDA has not cleared a drug and/or medical device in use described in this presentation (i.e., the drug or medical device is being discussed in an off-label use). For full information see page 10.

Poster #26

**JOHN H. MOE AWARD NOMINEE FOR BEST BASIC SCIENCE PRESENTATION

Pedicle Screw Coatings Increase Screw Fixation by 4-Fold in Dynamic Non-Fusion Spinal Constructs

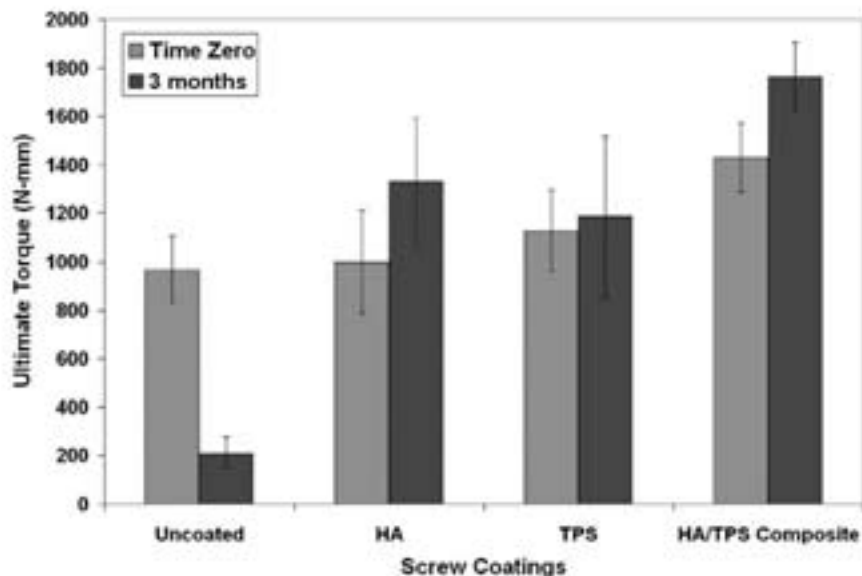
Vidyadhar Upasani (Rady Children's Hospital and Health Center); Christine L. Farnsworth, MS; Reid Chambers, BA; Tucker Tomlinson, MS; Shunji Tsutsui, MS; Andrew Mahar, MS; Michael A. Slivka, MSc; Peter O. Newton, MD

Introduction: Pedicle screw surface coatings have been considered for use with non-fusion constructs (growing rods and dynamic stabilization). The purpose of this study was to compare fixation strength of titanium pedicle screws treated with two different surface coatings.

Methods: Four types of 4.35mm x 25mm titanium mono-axial pedicle screws (uncoated, hydroxyapatite coated (HA), titanium plasma spray coated (TPS), and HA/TPS composite coated) were instrumented in 5 mature porcine thoracolumbar spines, and connected in mono-segmental constructs by a 5cm dynamic (flexible) rod in a randomized, single-blinded fashion. After a 3-month survival period, the spines were harvested and time zero control screws were instrumented at adjacent levels. A CT was performed to evaluate screw placement and bone mineral density (BMD), followed by torsional testing to evaluate pedicle screw holding strength. A two-way ANOVA ($p < 0.05$) was used to compare BMD and ultimate torque (N-mm), with time post-op and screw type as the two independent variables.

Results: CT confirmed intra-pedicular placement of all screws. BMD of the 5 pigs was not statistically different ($p = 0.90$) and averaged 4.5 ± 0.3 g/cm². Data for ultimate torque are shown in Figure 1. At time zero, no significant differences were found between the 4 screw types ($p > 0.10$). At 3 months post-op, however, the ultimate torque for the HA/TPS composite coated screws increased significantly ($p = 0.008$), while these values tended to decrease for the uncoated screws ($p = 0.11$); resulting in a 4-fold difference at 3 months post-op (uncoated: 490 ± 180 N-mm, HA/TPS coated: 2360 ± 200 N-mm, $p < 0.001$). The HA-only coated screws ($p = 0.15$) and the TPS-only coated screws ($p = 0.18$) also had trends towards increased fixation at 3 months; however to a lesser extent than the screws with the HA/TPS composite coating.

Conclusion: These findings suggest a loss of fixation over time for standard, uncoated pedicle screws placed in a non-fusion model. However, screw coatings which likely promote bony in-growth (TPS) or direct osteoblast bonding (HA), substantially increased fixation in this mechanically demanding non-fusion construct. Coating pedicle screws with both TPS as well as HA increased fixation 4-fold compared to standard screws.



* The FDA has not cleared a drug and/or medical device in use described in this presentation (i.e., the drug or medical device is being discussed in an off-label use). For full information see page 10.

ELECTRONIC POSTER ABSTRACTS



SCOLIOSIS RESEARCH SOCIETY



E-Poster #1

**JOHN H. MOE AWARD NOMINEE FOR BEST BASIC SCIENCE PRESENTATION

Comparative Study of the Osteogenic Potential of Osteoblast from the Lumbar Vertebral Laminae and Iliac Bone

Prof. Helton Defino (Faculdade de Medicina de Ribeirão Preto); Carlos F. Herrero, MD; Grasiela Crippa; Larissa Belessine; Carlos F Estelita, MD; Prof. Adalberto L Rosa

Introduction: The iliac graft has been preferred source of autograft material and the purpose of the study was to determine whether the osteogenic potential of osteoblasts from the cancellous bone from lumbar laminae could be different from osteoblasts from iliac bone.

Methods: It has been utilized culture of osteoblasts derived from cancellous bone of the laminae of the fifth lumbar vertebra and iliac bone of three patients submitted to a lumbar fusion. Bone fragments of the fifth lumbar vertebra and iliac, of the same patient, taken during the lumbar spinal fusion were submitted to enzymatic digestion to obtain cells, which were cultivated in an osteogenic environment (added serum fetal bovine, ascorbic acid, B-glycerophosphate and dexamethasone), 37 C and 5% of CO₂. With the objective of comparing the osteogenic potential, the osteoblasts were cultivated to evaluate the proliferation and cell viability in 3, 7 and 10 days, the alkaline phosphatase activity in 10 days, the mineralized matrix formation in 21 days and Cbfa1, BMP-7, ALP and osteocalcin gene expression in 7 days. The data were compared through t test or Mann-Whitney.

Results: Cell proliferation was higher in the 7 and 10 days in the osteoblasts culture from the vertebral laminae than in the iliac bone osteoblasts cultures ($p=0,0001$), but there was no difference in the cell viability in any period. Alkaline phosphatase activity was 1,8 times higher and the mineralized matrix formation was 5,4 times higher in the vertebral laminae culture than in the iliac bone ($p=0,013$ e $0,001$ respectively). The study of the gene expression involved in the osteogenesis indicated higher expression in the osteoblasts culture from the vertebral laminae than from the iliac bone, 4,8 times higher for Cbfa1, 43,1 times higher for BMP-7, 4 times for ALP and 43,5 times higher for osteocalcin.

Conclusion: The results of the culture of the osteoblasts from the laminae of the fifth lumbar vertebra (L5) presented higher osteogenic potential compared to osteoblasts from iliac bone.

Significance: The results indicate that other factors rather than the osteogenic potential of osteoblasts from iliac crest may play a role in the integration of bone graft.



E-Poster #2

**LOUIS A. GOLDSTEIN AWARD NOMINEE FOR BEST CLINICAL PRESENTATION

Validating Predictive Models of Spino-Pelvic Alignment: Pre- and Post-Operative Analysis of 70 Adults Suffering from Sagittal Plane Malalignment

Virginie Lafage, PhD; Frank J. Schwab, MD (NYU Hospital for Joint Diseases); Ashish Patel, MD; Robert A. Hart, MD; Douglas C. Burton, MD; Oheneba Boachie-Adjei, MD; Alexis P. Shelokov, MD; Richard A. Hostin, MD; Christopher I. Shaffrey, MD; Munish C. Gupta, MD; Behrooz A. Akbarnia, MD; R. Shay Bess, MD

Introduction: In the setting of sagittal plane spinal deformity, pedicle subtraction osteotomy (PSO) can offer significant change in alignment. Despite technique related advances, prediction of post-operative alignment remains challenging. Optimal alignment includes spinal parameters (ex. sagittal vertical axis offset [SVA]) as well as pelvic parameters (tilt [PT]). Formulas have been developed to predict post-operative spino-pelvic parameters based upon pelvic incidence and change in: lumbar lordosis, thoracolumbar alignment, thoracic kyphosis. These formulas have not yet been validated in the setting of PSO surgery. Purpose: validate the ability of predictive models to correctly classify post-operative spino-pelvic alignment following PSO surgery

Methods: Multi-center retrospective study of 70 adults (54 F, 16 M) that underwent PSO surgery for spinal sagittal plane malalignment. Pre- and post-op standing sagittal x-rays were analyzed and patients classified based on post-op measures into "good" (low SVA<5cm, low PT <25deg) or "poor" alignment (high SVA>5cm, high PT>25deg). Predictive formulas were applied to predict post-operative SVA and PT. A comparison between predicted (good vs. poor alignment) and actual outcome category (by spino-pelvic parameters) was pursued.

Results: PSO distribution by level and angular resection were as follow: L1 (n=6, 24°), L2 (n=15, 24°), L3 (n=29, 25°) and L4 (n=20, 22°). Significant differences pre- to post-op were as follows: SVA 122mm to 34mm (p<0.001), and PT from 33° to 23° (p<0.001). A "good" realignment, combined low SVA/PT, was found in nearly 50%, while high SVA/PT ("poor" alignment) was noted in 23%. Predictive formulas were able to correctly classify post-operative SVA/PT combinations as "good" or "poor" in 83% of cases.

Conclusion: The prediction of post-operative spino-pelvic parameters following PSO is critical. This study has offered validation of formulas for predicting SVA and PT following surgery. Further work will permit additional refinement of predictive formulas such that the degree and level of osteotomy can be carefully planned with accurate anticipation of post-operative spino-pelvic alignment.

Significance: This effort is certain to improve outcomes and offer improved surgical planning.

E-Poster #3

**LOUIS A. GOLDSTEIN AWARD NOMINEE FOR BEST CLINICAL PRESENTATION

Relation Between Health-Related Quality of Life Score and Survival in the Patients with Spinal Metastases - A Prospective Analysis

Takayuki Yamashita, MD (Cleveland Clinic); Krzysztof Siemionow, MD; Thomas E. Mroz, MD; Isador H. Lieberman, MD, MBA, FRCS

Introduction: Approximately one third of cancer patients develop metastases to the spinal column. The prognosis once spinal metastases have been diagnosed and the most appropriate treatment still remains controversial. Prognostic factors in the patients with spinal metastases were previously reported. However, the relation between health-related quality of life score and survival has not been reported.

Methods: All patients diagnosed with any form of spinal metastases, who presented in the Taussig Cancer Institute or Center for Spine Health at Cleveland Clinic, whether symptomatic or not, regardless of tumor biology were asked to enter the study. This was a prospective non-intervention observational study, as such no intervention or treatment plan changes were associated with this study. At enrollment, the health-related quality of life score (SF-36) was asked to the patients and documented. The patients who survived for more than six months following enrollment were defined as long survival. The patients who died within six months were defined as short survival.

Results: Of the patients who were enrolled to this study, 34 patients were stratified in the long survival group, and 17 patients in the short survival group. Of SF-36 health domains, there were significant differences between the two groups according to physical functioning (long survival 38.3 vs short survival 19.4; $p=0.019$), bodily pain (long survival 38.0 vs short survival 22.3; $p=0.017$), and mental health (long survival 71.5 vs short survival 54.6; $p=0.005$).

Conclusion: Physical functioning, bodily pain, and mental health of SF-36 health domains were statistically higher scores in the long survival group. These domains would be prognostic factors in the patients with spinal metastases. The health-related quality of life score would be useful for the assessment of such patients.

Significance: More accurate prediction of prognosis will provide cancer patients with a better quality of life.



E-Poster #4

**LOUIS A. GOLDSTEIN AWARD NOMINEE FOR BEST CLINICAL PRESENTATION

Does the Occurrence of Postoperative Complications Adversely Affect SRS Scores?

James T. Guille, MD (Brandywine Institute of Orthopaedics); Linda P. D'Andrea, MD; Maty Petcharaporn, BS; Tracey P. Bastrom, MA; Peter O. Newton, MD

Introduction: We wanted to test our hypothesis that patients who incurred a postoperative complication after corrective AIS surgery would have lower SRS scores 2 years after surgery than patients who did not have a complication.

Methods: We reviewed the complication data on 323 patients with AIS who had been followed for a minimum of 2 years and had a complete chart review. Patients were placed into 3 groups: those with a major complication, those with a minor complication, or neither. Major complications included severe medical conditions (e.g., pulmonary embolism), neurologic problems, deep infections, and problems requiring reoperation. Minor complications included easily treated medical conditions (e.g., ileus, atelectasis), instrumentation failures not requiring revision, and superficial wound problems.

Results: Sixteen patients (5%) had a major complication, 56 (17%) had a minor complication, and 251 (78%) had no complications. Mean age at operation was 15 years and was not significantly different amongst the groups. Interestingly, and without explanation, the patients with no complications had significantly higher preoperative function scores ($p < 0.001$) than the other two groups. Otherwise, there were no significant differences in the preoperative domains of pain, self-image, activity, or total scores for all groups. There was no significant difference in the final Cobb magnitude amongst the groups. At 2-year follow-up, the patients with a major complication had significantly lower reported self-image ($p < 0.03$) and activity ($p < 0.02$) scores than patients with no complications. This difference was also seen when compared with patients who had a minor complication and approached statistical significance ($p < 0.07$ and $p < 0.09$, respectively).

Conclusion: In future outcome studies on the operative treatment of AIS, the occurrence of a major postoperative complication needs to be taken into consideration, as it may adversely skew the results of the SRS scores of an otherwise successful procedure.

Significance: The occurrence of a major postoperative complication significantly decreases SRS scores.

E-Poster #5

**LOUIS A. GOLDSTEIN AWARD NOMINEE FOR BEST CLINICAL PRESENTATION

Risk Factors for Critical Intraoperative Neuromonitoring Changes During AIS Surgery

Daniel J. Sucato, MD, MS (Texas Scottish Rite Hospital for Children); Timothy R. Kuklo, MD, JD; Mohammad Diab, MD; B. Stephens Richards, III, MD; Charles E. Johnston, MD; Lawrence G. Lenke, MD; Spinal Deformity Study Group

Introduction: Intraoperative neuromonitoring (IONM) is an essential strategy to avoid neurologic problems during surgery for adolescent idiopathic scoliosis (AIS). To our knowledge there are no large studies which have determined factors associated with the ability to maintain good baseline IONM.

Methods: A multi-center prospective scoliosis database of patients who underwent surgery for AIS was reviewed to determine those patients who had a critical change in somatosensory-evoked potentials (SSEP) and/or motor-evoked potentials (MEP).

Results: 2189 patients undergoing AIS surgery were reviewed. SSEP was attempted in 92.5% and MEP in 77.7%. A critical change in SSEP was noted in 1.2% and was associated with larger preoperative proximal thoracic (PT) Cobb angle (32.3 vs. 23.7°), main thoracic (MT) Cobb angle (66.1 vs. 54.8°), and type of posterior surgical approach. Patients who had PSF with hybrid constructs (hooks, wires and screws) had higher incidence of critical changes compared to hooks alone, hooks with screws, and all screws (2.5% vs. 0.0 vs. 0.5 vs. 1.3%) ($p < 0.05$). A critical change in MEP data occurred in 3.0% of patients and was associated with a larger proximal thoracic Cobb (29.5 vs. 24.2°), main thoracic Cobb (67.4 vs. 55.4°), male gender (5.9 vs. 2.2%), and type of posterior procedure in which hybrid construct was greater than hooks only, hooks with screws, and pedicle screws only (5.4 vs. 0.0 vs. 3.2 vs. 2.0%) ($p < 0.05$). Those patients who had thoracic kyphosis $>40^\circ$ were more likely to have MEP changes compared to $<40^\circ$ (6.7 vs. 2.2%). Preoperative MRI findings did not correlate with critical IONM changes.

Conclusion: Risk factors for having critical IONM changes during AIS surgery are greater preoperative PT and MT curve magnitude, $>40^\circ$ of thoracic kyphosis and the use of sublaminar wires. These preoperative factors should be taken into consideration when planning surgical treatment for AIS and the use of sublaminar wires should be avoided.

Significance: Neurologic deficit is the most feared complication following surgical treatment for adolescent idiopathic scoliosis. The results in this study provide clear preoperative risk factors for the development of critical IONM changes and strongly suggest against the use of sublaminar wires in the treatment of AIS.



E-Poster #6

Long-Term Outcome for Myelomeningocele Kyphectomy

Richard E. McCall, MD (Shriners Hospitals for Children)

Introduction: Lumbar kyphosis occurs in 12-20% of patients with Myelodysplasia. Treatment remains complex: Kyphectomy with instrumentation. There are few long-term (greater than 10 year) follow-ups of outcomes of lumbar kyphectomy in myelodysplasias.

Methods: From January 1989 to January 1994, 17 patients with thoracic level myelomeningocele and severe kyphotic deformity underwent kyphectomy. Sixteen patients were reviewed in 1998, average follow-up of 57.2 months (36-94 months). Study of same cohort was done in 2008, average follow-up of 170 months (156-214 months). Operative indications included: spinal deformity, progression of kyphus, repeated skin breakdown over kyphos, and poor sitting balance.

Results: Preoperative kyphotic deformity averaged 111° (75°- 157°); postoperatively 15° (minus 18 - 36°). At average follow-up of 57 months, average kyphos was 20° (minus 17 -83°), a loss of correction of 6° (0 - 27°). At latest follow-up kyphus averaged 25° (minus 10 - 83°). All skin remained well healed after healing of operative wound. Bracing was stopped in all patients at age 12 to protect hardware as no fusion was done proximal to kyphectomy site. Four of 16 patients had rod breakage after brace removal, none required hardware removal. Two patients required hardware removal about 6 years postoperatively secondary to hardware prominence, one with skin erosion over distal tip of the rod. All healed uneventfully after hardware removal. One lost further 10° of correction after hardware removal. Residual thoracic spine growth, as no fusion was done proximally, averaged 5cm (2 - 7cm) demonstrated by migration of proximal wires over rods. Postoperative sitting was also maintained long-term.

Conclusion: Despite the complexity of kyphectomy in myelomeningocele and potential for complications, long-term follow-up indicates that kyphectomy may provide overall excellent results for this subset of complex spine patients.

Significance: Long-term follow-up supports the efficacy of kyphectomy with instrumentation and local fusion in managing myelomeningocele kyphus.

E-Poster #7

A Validated Formula for Predicting Post Operative Sagittal Balance in the Setting of Adult Spinal Deformity

Virginie Lafage, PhD (New York University Hospital for Joint Disease); Frank J. Schwab, MD; Ashish Patel, MD; Nicola Hawkinson, BSN, MA, NP; Jean-Pierre Farcy, MD

Introduction: Spinal balance involves a complex interaction between the pelvis and vertebral column. In the setting of adult deformity, prediction of post-operative alignment can be challenging. The aim of this study was to build predictive models for pelvic tilt (PT) and T1 spino-pelvic inclination (T1-SPI more specific than SVA) and to evaluate the effectiveness of these predictive models against a group of patients following pedicle subtraction osteotomy (PSO).

Methods: The study included 218 adult patients with spinal deformity. Full-length standing films were available for all subjects. Multi-linear models with a stepwise condition were used on a first group of patients (n=178) in order to predict the pelvic tilt (PT) and the T1-SPI (sagittal global spino-pelvic parameter; angle between the T1-hip axis and the vertical). Prediction models were then applied on the second group (n=40) to estimate post-operative parameters after PSO surgery. Differences between estimated parameters and real values were evaluated.

Results: Multi-linear regression analysis applied on the first group of patients led to a predictive formula for PT ($r=0.93$, std error= 4.4°) using the following parameters: pelvic incidence (PI), maximal lordosis, maximal kyphosis. These parameters with the addition of the predicted PT were then used to predict T1-SPI ($r=0.81$, standard error= 3°). Validation of predictive models (second group of patients) applied; pelvic incidence and post-operative sagittal curves. Post-operative PT was predicted with a mean error of 4.6° (SD 3.6°) and T1-SPI was predicted with a mean error of 3.5° (SD 2.7°)

Conclusion: This is the first study to develop and validate pragmatic predictive models for key spino-pelvic parameters (PT and T1-SPI) in the setting of spinal malalignment. Using a morphological pelvic parameter (PI), and spinal parameters modifiable through surgery; lumbar lordosis, thoracic kyphosis, post-operative sagittal alignment can be predicted.



E-Poster #8

Polysegmental Growing Construct in the Treatment of Juvenile Idiopathic Scoliosis: 9 Years Follow-Up

Andriy Mezentsev, MD (Sytenko Institute of Spine and Joint Pathology); Dmytro Petrenko, MD

Introduction: Surgical management of Juvenile Idiopathic Scoliosis in skeletal immature patients is a challenging problem. Current methods present loss of correction, implant breakage and migration, need of revision surgeries. Use of pedicular hooks and screws in growing construct combined with anterior convex epiphyseodesis would decrease these complications and avoid revision surgeries for gradual correction.

Methods: 31 growing patients with Juvenile Idiopathic Scoliosis were surgically treated using anterior convex epiphysiodesis and growing construct with screws and hooks without posterior fusion. Mean follow-up was 9 years. Postoperative bracing was used.

Results: Mean age at operation was 10,3 years (range 7-12). Mean preoperative Cobb angle was 69,6, mean preoperative rotation was 43,6. Preoperative thoracic kyphosis was 25,1 on the average. Immediately after surgery Cobb angle was 21,2 (69% correction) and rotation was 16,4, mean thoracic kyphosis was 27,2. After 9-years follow-up mean Cobb angle of the major curve was 23,8 (5,2% loss of correction), spinal rotation was 13,7, mean thoracic kyphosis was 29,1. Mean growth of the instrumented spine at the end of follow-up was 8 mm per year. 3 patients had the loss of the correction more than 10 degrees, screw breakage occurred in 1 patient, rod exchange was done in 1 patient, hook displacement observed in 3 patients.

Conclusion: Polysegmental growing construct and anterior convex epiphyseodesis is an effective method of the surgical treatment of Juvenile Idiopathic Scoliosis in skeletal immature patients.

Significance: Using polysegmental growing construct and anterior convex epiphyseodesis avoids complications peculiar to current growth-sparing procedures.

E-Poster #9

Hemivertebra Excision: Comparison of Circumferential vs Posterior-only Approaches

Sumeet Garg, MD (Washington University in St Louis); Jason A. Brant; Lawrence G. Lenke, MD; Keith H. Bridwell, MD; Brenda A. Sides, MA; Kathryn A. Keeler, MD

Introduction: Excision of hemivertebra has traditionally been performed through a circumferential (A/P) approach. Posterior only (Post.) approaches have recently been advocated.

Methods: 26 children with congenital scoliosis with a hemivertebra underwent either an A/P approach (n=18) or a Post. (n = 8) approach and had minimum two year follow-up. The A/P group had an average age of 8.1 years (range 1.3 to 16.1) and mean follow-up of 5.1 years. The Post. group had an average age of 11.3 years (range 3.6 to 18) and a mean follow-up 5 years.

Results: Average preoperative Cobb angle of the major curve was 41 deg in the A/P group and 40 deg in the Post. group. Average Cobb angle at last follow-up was 13 deg in the A/P group and 28 deg in the Post. group. Sagittal and coronal balance was equivalent in the two groups. An average of 4.4 levels was fused in the A/P group compared to 4.1 in the Post. group. Average blood loss was higher (765mL vs 371mL) and operative time was longer (8 hr 35 min vs 5 hr 15 min) in the A/P group. There were no infections requiring return to the OR in the Post. group compared to 4 in the A/P group. The A/P group also developed two neurologic deficits (foot drop), one of which reversed after early decompression. The Post. group developed no neurologic deficits. There were two revision surgeries in each group (A/P -one for pseudarthrosis and one proximal junctional kyphosis, Post. -one for pseudarthrosis and one for prominent implants).

Conclusion: This single center, two surgeon series demonstrated acceptable curve correction with both A/P and Post. approaches to hemivertebra excision and spinal fusion. There was a trend towards decreased infection rates and neurologic compromise in the Post. group.

Significance: A posterior only approach to hemivertebra excision and spinal fusion is the preferred method of treatment for children with congenital scoliosis who require surgery.

E-Poster #10

Proposal for a Reference Axis as a Basis for 3D Classification of Idiopathic Scoliosis

Carl-Éric Aubin, PhD, P.Eng; Hubert Labelle, MD (University Hospital Center); Lawrence G. Lenke, MD; Roger P. Jackson, MD; Peter O. Newton, MD; Ian A. Stokes, PhD

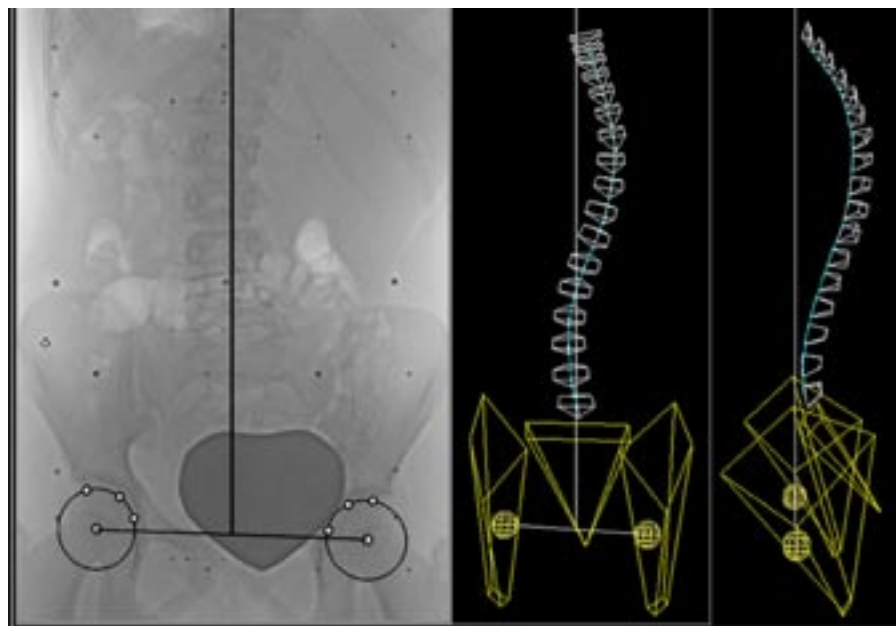
Introduction: The Center Sacral Vertical Line (CSVL), a commonly used determinant to evaluate scoliosis, is a line identified in the PA plane. Its position in the sagittal plane is undefined and therefore cannot be used for 3D classification. This study introduced and assessed a new 3D reference axis, called the Central Hip Vertical Axis (CHVA), proposed by the SRS 3D classification committee for 3D evaluation of scoliosis. The CHVA, defined as the vertical line bisecting the bi-femoral head axis, represents the physiological center of balance of the spino-pelvic unit.

Methods: Preoperative radiographs of 68 Lenke 1 Main Thoracic curves were reviewed twice by 5 members of the SRS 3D classification committee using a software that automatically drew the CHVA and CSVL after the user digitized the lateral borders of S1 facets (CSVL) and three points on each femoral head (CHVA). They also assigned the lumbar modifier (A,B,C) to each of these.

Results: There was no statistical intra- and inter-observer difference for the position of the CHVA and CSVL ($p > 0.1$), except significant intra-observer differences for the CSVL for 2 members ($p < 0.001$). Intra- and inter-observer repeatability in assigning the lumbar modifier was better for the CHVA ($\kappa: 0.86/0.75$; both 'excellent' reliability) compared to the CSVL ($\kappa: 0.77/0.61$; 'excellent' and 'good' reliability respectively). The CHVA was on average 3.2 mm to the right compared to the CSVL generating a shift (A->B->C) in the assignment of the lumbar modifier.

Conclusion: On average, the CHVA was slightly to the right of the CSVL thereby altering the A,B,C modifiers in many cases. It was more reproducible and showed better intra- and inter-observer agreement as compared to the CSVL in identifying the lumbar modifier. We recommend keeping the CSVL for 2D classification, and adopting CHVA as the reference axis for 3D evaluation of idiopathic scoliosis.

Significance: The CHVA reflects a true 3D axis as compared to the CSVL which is only defined in the PA plane. Also, it can easily be computed in 3D and represents the physiological center of balance of the spino-pelvic unit because it takes into account femoral head support.



E-Poster #11

Does a Dymorphic Pedicle Predispose to Pedicle Screw Mal-Positioning?

John K. Czerwejn, Jr., MD (Albert Einstein School of Medicine); Adam L. Wollowick, MD; Alok D. Sharan, MD; Terry Amaral, MD; Beverly Thornhill, MD; Vishal Sarwahi, MD

Introduction: Pedicle morphology can be significantly altered in the deformed spine, presenting challenges for accurate placement of pedicle screws. The purpose of this study was to calculate the incidence of screw mal-position in a dymorphic pedicle, to compare it to the incidence in a normal pedicle and to determine if it improves with surgeon's experience.

Methods: CT scans were reviewed independently of 45 spinal deformity patients by a bone radiologist and spine surgeon and pedicle morphology was classified as: Type A (normal pedicle) - >4mm cancellous channel, Type B - 2-4 mm, Type C -cortical channel, and Type D <2mm. In group I, there were 550 (77%) Type A pedicles, Type B 105 (14.7%), Type C 32 (4.4%), and Type D 27 (3.9%). Group II had 690 (84.6%) Type A pedicles, Type B 82 (10%), Type C 30 (3.7%), and Type D 14 (1.7%). All patients were reviewed for mal-positioned screws.

Results: In both groups, a total of 916 pedicles were instrumented. 46 of 802 (5.7%) normal pedicles had mal-positioned screws vs. 25 of 114 (22%) dymorphic pedicles that had mal-positioned screws. In addition, overall Group I had a mal-position rate of 12% versus Group II which had a mal-position rate of 4%. In group I, 57 pedicles instrumented were dymorphic or of Type B, C, or D of which 16 pedicle screws (28%) were misplaced. Of the 16 misplaced, 4 (25%) were Type B pedicles, 8 (50%) were Type C, and 4 (25%) were Type D. In group II, 57 pedicles instrumented were dymorphic of which 9 pedicles (15.8%) were misplaced. Of the 9 misplaced, 5 (55.6%) were Type B, 3 (33.3%) were Type C, and 1 (11.1%) were Type D. All results were statistically significant ($p < .05$).

Conclusion: An increased incidence of screw mal-positioning was seen in dymorphic pedicles versus normal pedicles. As the surgeon became more experienced, the incidence did decrease in dymorphic pedicles; as well as, normal pedicles.

Significance: Dymorphic pedicles can be much more challenging in proper placement of pedicle screws than a normal pedicle. A surgeon will gain experience over time and it is likely the rate of mal-positioning will decrease; however, appropriate preoperative planning is recommended to minimize cortical breaching and potential complications seen with pedicle screw misplacement.



E-Poster #12

Pelvic Fixation of Growing Rods: Comparison of Constructs

Paul D. Sponseller, MD (Johns Hopkins Medical Institutes); Justin S. Yang, BS; Behrooz A. Akbarnia, MD; John B. Emans, MD; David L. Skaggs, MD; Richard E. McCarthy, MD; Marc A. Asher, MD; Muharrem Yazici, MD; Francisco Sanchez Perez-Grueso, MD; Connie Poekochert, RN, BSN, CNP; Patricia Kostial, BSN, RN; George H. Thompson, MD

Introduction: Growing systems with a pelvic foundation are an option for patients with neurologic or syndromic disorders, but there is little data on them.

Methods: 36 patients with growing rods anchored in the sacrum or ilium were studied. All had minimum 2 yrs with the growing implant. Diagnoses included 6 Cerebral Palsy, 6 SMA, 5 Myelomeningocele, 4 Congenital, 1 Arthrogryposis, 14 miscellaneous. Mean age at surgery was $6.8 \pm 3y$. Seven were ambulatory prior to insertion. Mean preop curve was $86 \pm 22^\circ$. Mean pelvic obliquity was $27 \pm 11^\circ$. Mean follow up was 39 mos.

Results: Iliac screws were used in 22 patients, iliac rods in 9, sacral hooks in 3, S-rods in 3 and sacral screws in 2 (3 had periods of different distal anchors). Dual rods were used in 31 patients; single in 5. Patients had a mean 2.7 ± 1.8 lengthenings. 12 patients were ambulatory after insertion. Mean major Cobb improved to $48 \pm 20^\circ$ at final follow up. Mean increase in T1-S1 length was $8.5 \pm 4.6cm$. Mean pelvic obliquity improved to $11 \pm 7^\circ$; correction was 68% with iliac screws, 53% with S-rods, 52% with iliac rods, 40.5% with sacral hooks or screws ($P < 0.001$). Iliac screws provided better correction of pelvic obliquity than all other anchors except S-rods, and sacral fixation provided less correction than other anchors. Dual rods provided better correction than single rods of both pelvic obliquity (67% vs 44%, $p = 0.008$) and major curve (47% vs 25%, $p = 0.01$). Five patients underwent fusion at mean age $11.2 \pm 1.2y$; the same distal anchors were maintained in three. Complications: Four patients had deep infections. There were five rod breakages; this did not differ from the rate for dual growing rods not fixed to the pelvis ($p = 0.12$). There were five breakages of iliac screws, two migrations of sacral hooks, one of S-rod; none of iliac rods. Implant breakage was higher with single rods than dual rods ($P = 0.036$). Iliac screws had a higher breakage rate than the others ($P = 0.02$).

Conclusion: Pelvic fixation may be used successfully as a foundation for growing rods. Percentage correction of pelvic obliquity exceeds that of the major curve ($P < 0.001$). Iliac fixation provides better correction of pelvic obliquity than sacral fixation and dual rods provide more than single rods. Iliac screws have a higher breakage rate.

E-Poster #13

Histological Changes of Intervertebral Discs and Neural Structures Induced by Spinal Fusion in Immature Rabbit Model

Federico Canavese, MD (CHU Montpellier); Alain Dimeglio, MD; Eugenio Pittioni, MD; Donatella Volpatti, MD; Prof. Bartolomeo Canavese; Prof. Fabio Cavalli

Introduction: Structural changes of intervertebral discs and neural elements induced by dorsal arthrodesis performed in immature spines are not completely understood. The purpose of this study was to describe how an early partial dorsal arthrodesis (T1-T6) affects the shape and structure of intervertebral discs, spinal cord, nerve roots and ganglia, and vascularity of the surrounding tissues.

Methods: Nine New Zealand White rabbits underwent an extracanal dorsal vertebral arthrodesis at age 8 weeks with a control group of three rabbits undergoing a sham operation. CT scans were performed to ascertain whether or not fusion had occurred. At age 8 months the rabbits were sacrificed. Coronal and sagittal segments of the thoracic spine were obtained, fixed in formaldehyde, decalcified and prepared for histology. 8-10 μ m paraffin sections from fused levels of the arthrodesed rabbits were stained with H&E and toluidine blue and compared to specimens from non fused levels and also to specimens from the controls.

Results: CT scans and autopsy at skeletal maturity showed that fusion occurred in all operated rabbits and in none of the controls. Arthrodesed rabbits showed disorganization of the annulus fibrosus with active ossification connecting two adjacent end plates. Costovertebral joints showed cartilage with loss of congruence. Different populations of neurons with pathological changes were identified in the dorsal root ganglia of arthrodesed rabbits. Pathologic changes included reduced size and deformed neurons, chromatolysis and signs of satellitosis of the perineuronal cells. Increased vascularisation and ossification process were found in the arthrodesed region.

Conclusion: Ossification of the annulus fibrosus lead to spontaneous ventral fusion. Neurons of the dorsal roots ganglia and nerve roots were characterized by pathologic changes.

Significance: Early thoracic spinal arthrodesis leads to spontaneous ventral vertebral fusion and affects thoracic growth, nerve roots and spinal ganglia. Those findings contribute to explain reduced chest growth and subsequent thoracic dystrophy in subjects treated with early arthrodesis.

E-Poster #14

***Does Subcutaneous Placement of the Rods Give Better Results in Growing Rod Technique?**

Behrooz A. Akbarnia, MD (San Diego Center of Spinal Disorders); Shahid Khan, FRCS; Pooria A. Salari, MD; Sina Tebi, BS; George H. Thompson, MD; Richard E. McCarthy, MD; Francisco Sanchez Perez-Grueso, MD; Hazem B. Elsebaie, FRCS, MD; Paul D. Sponseller, MD; Patricia Kostial, BSN, RN; Rishi Kadakia; Lawrence I. Karlin, MD; David S. Marks, FRCS; Growing Spine Study Group

Introduction: The management of young children with severe scoliosis remains controversial. Currently, single and dual rod techniques either submuscular or subcutaneous followed by periodic lengthening have been commonly used. The purpose of this study was to evaluate the factors influencing the outcomes of growing rod procedures.

Methods: A retrospective multicenter study of patients with early onset scoliosis who have undergone growing rod surgery. Demographic information, number of lengthening, duration of follow up, position and number of rods were reviewed. Curve magnitude and T1 and S1 distance at three time points (Before initial surgery for rod placement, after initial surgery and at the latest follow up date) were compared.

Results: Total of 138 patients with average age of 6 years and 2 months (1.5-12). There were 57 boys and 81 girls, 43 patients had idiopathic scoliosis (22 Infantile vs. 21 Juvenile) 20 patients with congenital, 31 patients had neuromuscular scoliosis and 44 patients had syndromic curves. 86 patients had sub-muscular rods (deep to the fascia) while subcutaneous placement of rods was used in 52 patients. In 67 patients dual rod and in 71 patients single rod was used. Mean follow up time was 60 months (24-166.5). The average number of lengthenings was 4 for submuscular and 5 for subcutaneous group. Subcutaneous placement ultimately resulted in slightly better curve correction in comparison to submuscular rods. However dual rod placement resulted in significantly better initial and final curve correction regardless of their location. There were no significant differences between groups and sub groups as far as increase of T1 to S1 distance.

Conclusion: Both subcutaneous and submuscular growing rod techniques are effective in scoliosis correction, maintenance of correction and allowing for spinal growth. Subcutaneous rods showed only slightly better final curve correction compared to single rod group. No significant difference was found in spinal growth between the two groups. Dual rods, however, resulted in significant improvement of initial and final curve correction compared to single rods regardless of their location.

Significance: Dual growing rods are superior to single rod technique regardless of being submuscular or subcutaneous.

Radiographic Data

	Curve Correction (%)		T1-S1 Length(mm)					Spine Growth(mm/yr)
	Initial	Ultimate	PRIS	POIS	IC	LFU	FC	
SM	42.6	30.5	262	298	36	329	68	7
SQ	39.8	37.4	251	289	37	317	72	7.6
Dual	47.7*	44.2**	248	287	40	313	71	7
Single	35.9*	22.3**	268	302	34	336	68	7.5

PRIS: Pre Initial Surgery, POIS: Post Initial Surgery, IC: Initial Correction, LFU: Latest Follow Up, FC: Final Correction

*, ** (P<0.05)

E-Poster #15

Safety and Accuracy of Pedicle Screws Placed in Pediatric Patients less than 10 Years of Age

Katsumi Harimaya, MD; Jochen P. Son-Hing, MD, FRCSC; Lawrence G. Lenke, MD (Washington University); Keith H. Bridwell, MD; Richard M. Schwend, MD; Linda Koester; Brenda A. Sides, MA

Introduction: Although much has been written regarding the use of pedicle screws in adolescent and adult spinal deformities, few studies have examined the safety of pedicle screws placed in young pediatric patients. Our purpose was to determine the safety of pedicle screws placed in pediatric patients less than 10 years of age, and to evaluate the accuracy of pedicle screw placement as well as the incidence of short and long-term (>2 years follow-up) complications.

Methods: A retrospective review of 66 cases involving 663 pedicle screws placed for a variety of pediatric spinal deformities was performed at a single institution. To evaluate the accuracy of pedicle screw placement, AP and lateral radiographs were reviewed by 2 spinal surgeons not involved in the surgical treatment by means of the methods reported by Kim YJ et al (Spine 2005).

Results: The average age at surgery was 6.5 years (range 2+0 to 9+11). The distribution of thoracic (n=407) and lumbar (n=256) pedicle screws is shown in the table. Of 663 pedicle screws placed, 2 screws (0.3%) violated the lateral wall of the pedicle, 2 screws (0.3%) the inferior wall; and 2 screws (0.3%) were suspected of medial violation wall for a total of 6 screws (0.9%) malpositioned. Although short-term complication occurred in 9 patients (13.6%, 4: wound infection, 2: foot drop, 2: respiratory problem, 1: 6th cranial nerve palsy), there were no insertion or short-term complications specifically related to the use of pedicle screws. Long-term complication occurred in 6 patients (3: spinal deformity progression, 2: rod breakage in a growing rod), while one patient required revision surgery performed due to the prominence of a single thoracic pedicle screw placed in a growing rod construct.

Conclusion: There were no intraoperative or short-term pedicle screw insertion-related complications and a very low long-term complication rate specifically related to the use of pedicle screws in young pediatric spinal deformity patients. Over 99% of screws were judged to be in accurate position by a detailed, independent radiographic assessment. These results suggest that pedicle screw fixation in these young patients can be performed safely to treat a variety of spinal deformities when used by properly trained spinal surgeons.



E-Poster #16

Are Triggered EMG Thresholds Reliable for Assessing Thoracic Pedicle Screw Breach in the Cerebral Palsy Population?

JahanGir Asghar, MD (Institute for Spine & Scoliosis); Daniel M. Sciubba, MD; James J. McCarthy, MD; Amer F. Samdani, MD; Patrick J. Cahill, MD; David H. Clements, III, MD; M. Darryl Antonacci, MD, FACS; Randal R. Betz, MD; Harms Study Group

Introduction: Pedicle screw fixation has become increasingly common in treating all aspects of spinal deformity, including the neuromuscular spine. However, there has been relatively limited analysis of the accuracy of screw placement in neuromuscular spine deformities. Furthermore, modalities such as triggered EMG thresholds are commonly used to assess intraoperative screw placement with little or no evidence of their efficacy in this population. The purpose of our study is to evaluate the rates of CT breach and their EMG triggered thresholds in relation to postoperative CT-determined placement of pedicle screws in the neuromuscular spine.

Methods: We reviewed 41 consecutive patients with CP with a total of 442 thoracic screws (T1-T12) placed using the “free hand” technique. All patients had postoperative CT scans. Screws placed in the thoracic spine were evaluated intraoperatively using standardized EMG measurement protocols. Threshold intensities <6mA intraoperatively were considered breached and removed or repositioned (Raynor, Lenke et al). The pedicle screw breach was determined as intraosseous or breached using post-op CT (Kim et al., 2005).

Results: The incidence of thoracic pedicle screw breach on CT scan was 11.3% (50 breaches: 31 lateral and 19 medial). The mean amplitude for an intraosseous pedicle screw was 10.1 mA (range of 4-19 mA). The mean amplitude for a medially breached pedicle screw was 8.9 mA (range 4-15 mA, p=0.24). The mean for a lateral breach was 12.7 mA (range of 5-22, p=0.625). 79% of the screws with medial breaches triggered at a threshold of greater than 6 mA. Sensitivity and specificity of EMG to detect medial breach was 0.57 and 0.6, respectively. No postoperative neurologic complications were noted.

Conclusion: In this review, our rate of pedicle screw breach was 11.1%. 79% of medial thoracic pedicle screw breaches triggered at a threshold of > 6mA. No significant differences in triggered thresholds were noted with medial, intra-cortical or lateral breaches.

Significance: The use intraoperative triggered EMG in CP is limited in its capacity to identify thoracic pedicle screw breach. Furthermore, no reliable set of absolute values exists to delineate pedicle screw placement with triggered EMG.

*E-Poster #17

Shilla Growing Rods in a Caprine Animal Model

Richard E. McCarthy, MD (Arkansas Specialty Spine Center); Daniel J. Sucato, MD, MS; Hong Zhang, MD; Joseph Turner, MS; MeLeah A. Henson, MSME; Kathryn McCarthy, MD

Introduction: We are recording the results of a growing rod system implanted in a goat model for six months prior to explantation and analysis. The system identified as the “Shilla” is a growth enhancing pedicle screw system that guides growth at the ends of the dual rods with the apex of the deformity fixed to the rods with limited fusion and pedicle screws. The growth occurs through the extraperiosteally implanted screws that slide along the rods at either end.

Methods: The seven two-month-old immature goats were implanted with the dual rod system with two control animals having a sham operation. The goats lived six months postoperatively. The spines were tested with plain radiographs, microCT, physical examination, and microscopic analysis.

Results: All the goats’ spines grew with the implants in place; the growth was seen in both the thoracic and lumbar ends of the rods for an average of 4.8 cm. total. None of the implants failed. Wear analysis of the rod/screw system showed mild metal wear, primarily at the screw/rod interface dorsally in the lumbar areas. Metal filings were noted in the adjacent soft tissues to the growing screws as well as in the para-aortic lymph nodes adjacent to the Shilla growing screws. H and E staining studies showed phagocytic uptake of metal fragments in these lymph nodes not seen in lymph nodes adjacent to the fused apical segments. The microCT studies revealed that the goat facets at the insertion site of the Shilla growing screws were not functional joints at follow-up whereas the contralateral facets at that same vertebral level were maintained and seemed functional with somewhat altered morphology. Similar results were noted in adjacent level joints.

Conclusion: In this review, our rate of pedicle screw breach was 11.1%. 79% of medial thoracic pedicle screw breaches triggered at a threshold of > 6mA. No significant differences in triggered thresholds were noted with medial, intra-cortical or lateral breaches.



E-Poster #18

Predictors of Curve Progression in Adolescence, Following Growing-Rod Stabilization for Scoliosis in Infancy - A Minimum 7-Year Follow-Up

Dilip K. Sengupta, MD (Dartmouth-Hitchcock Medical Center); John K. Webb, MBBS, FRCS; Hossein Mehdiian, FRCS, MD

Introduction: Conventional Growing-rod requires periodic intervention until definitive fusion at maturity. LT-GR technique does not require periodic interventions. Some cases deteriorate at adolescence requiring definitive fusion. The purpose of this study was to identify the predictors of curve progression requiring definitive surgery.

Methods: 31 cases of infantile idiopathic scoliosis, treated surgically with LT-GR and convex epiphyseodesis without fusion at infancy, due to progressive deformity during 1984-1992; 29 (M-17, F-12) were available for follow-up until their skeletal maturity. Overlapped 'L' configuration of Luque-trolley construct was used (n=14) prior to 1988, and overlapped 'U' configuration in the subsequent 15 cases. No postoperative bracing was used.

Results: Mean age at operation was 4.5 years (1.5-9). Mean Cobb angle was 68° (27°-95°) preoperative, and 25.5° (10°-60°) postoperative. Mean follow-up was 12.5 years (7-25). 4 cases needed revisions before adolescence. Curve progression was noted at adolescence in 17 (58%) cases, requiring definitive fusion at a mean age of 14.5 years. 12 cases had progressive scoliosis (>55°), and 5 developed mid-segment kyphosis, at the junction of the overlapping Luque rods. 12 cases maintained their correction till skeletal maturity without further intervention. Regression of curve was noted in 4 cases. Mean Instrumented segment growth was 3.5 cm (42% of expected growth). Progression of scoliosis was predicted by preoperative apical rib-vertebra angle difference (RVAD) (p=0.002). Excessive instrumented segment growth predicted progressive mid-segment kyphosis but not scoliosis. Age at operation and initial curve size was not a predictive factor. 71% of overlapped 'L' rod construct (n=12), and only 29% of overlapped 'U' rod construct (n=5) had curve progression and needed definitive fusion.

Conclusion: LT-GR instrumentation allows spinal growth, and avoids periodic intervention. Age and curve magnitude at operation was not, but apical RVAD and LT-GR-construct was predictive of curve progression.

Significance: LT-GR technique describes growing-rod without the need for periodic surgical intervention

E-Poster #19

Major Neurological Deficit Immediately Following Adult Spinal Surgery: Incidence and Etiology over 10 Years at a Single Institution

Charles Kuntz, IV, MD (University of Cincinnati / Mayfield Clinic); P. Colby Maher, MD; David B. Pettigrew, PhD; Dennis E. Cramer, MD

Introduction: New onset postoperative paralysis remains one of the most feared complications of spinal surgery. The goal of this study was to determine the incidence and etiology of new onset major neurological deficit immediately following adult spinal surgery.

Methods: The quality assurance records of adult patients who underwent spinal surgery over a ten-year period (7/1/1996-6/30/2006) from a single University Teaching Institution were retrospectively reviewed. Patients with new onset major neurological deficit immediately following spinal surgery were identified. The criteria for new onset major neurological deficit immediately following spinal surgery consisted of new onset motor weakness with less than antigravity strength in two or more extremities occurring within twelve hours after spinal surgery.

Results: Of 11,817 adult neurosurgical spinal operations performed over a decade, 21 patients experienced new onset major neurological deficit immediately following spinal surgery; yielding an overall incidence of 0.178%; in the cervical spine 0.293%, thoracic spine 0.61%, and lumbar/sacral spine 0.0596% ($p=0.00024$). The etiology of the neurological deficits was confirmed with reoperation and/or postoperative imaging studies: 8 epidural hematoma, 5 inadequate decompression, 4 presumed vascular compromise, 2 graft/cage dislodgement, and 2 presumed surgical trauma. Placement of spinal instrumentation was performed in 57.1% of the patients and was associated with a significantly higher risk of new onset major neurological deficit immediately following spinal surgery ($p=0.022$). Postoperative follow-up neurological data were obtained in 20 of 21 patients (mean follow-up 8.4 months). Two patients died of complications related to the paralysis. Four patients demonstrated no significant neurological recovery, 9 patients demonstrated incomplete neurological recovery with improving neurological function, and 7 patients demonstrated complete or near complete neurological recovery with no significant neurological deficit.

Conclusion: The incidence of new onset major neurological deficit immediately following adult spinal surgery is low. Epidural hematoma and inadequate decompression were the primary etiologies in this series of patients.



E-Poster #20

Cosmetic and Functional Outcomes Following Paramedian and Anterolateral Retroperitoneal Approaches in Spine Surgery

Jay Jagannathan, MD (University of Virginia); Vincent Arlet, MD; Christopher I. Shaffrey, MD

Introduction: No study to date has reported on the cosmetic outcomes of the two most commonly used approaches to the spine in scoliosis surgery.

Methods: Three-hundred patients underwent anterior lumbar surgery by 7 surgeons between August 2004 and December 2006. One-hundred eighty patients were treated with an Anterior Paramedian Approach, and 120 patients were treated using an Anterolateral Retroperitoneal Approach. An access surgeon was used in 220 cases (74%). Post-operative evaluation in all patients consisted of clinic visits, a modified Scoliosis Research Society-30 (SRS-30) instrument, as well as a specific questionnaire relating to wound appearance and patient satisfaction with the wound.

Results: At a mean follow-up of 31 months (Range 12-47 months), mean SRS-30 score was 21.2 (of 25) for patients who had an anterior paramedian approach, compared with 19.4 (of 25) for patients who had an anterolateral retroperitoneal approach ($p=0.005$). The largest differences in quality of life measures were observed in the areas of pain control ($p=0.001$), self image ($p=0.004$), and functional activity ($p=0.003$), with the anterior paramedian group having higher scores in all 3 categories. Abdominal bulging in the vicinity of the surgical site was the most common wound complication observed, and was reported by 22 patients who had an anterolateral retroperitoneal approach (18%), compared with 2 patients (1.1%) who had an anterior paramedian approach. Exposures of 3 levels or greater with the anterolateral approach were associated with abdominal bulging ($p=0.04$), while 2- or 1-level exposures were not ($p>0.05$). Overall satisfaction with incisional appearance was higher in patients with an anterior paramedian incision ($p=0.001$) and with approaches performed by an access surgeon ($p=0.004$).

Conclusion: Patients undergoing an anterior paramedian approach to the lumbar spine have higher quality of life and cosmetic outcomes compared with patients following an anterolateral retroperitoneal approach.

Significance: This is the first study of its kind to examine the cosmesis following anterior spine surgery. As ALIF operations become more popular, this information will be valuable in determining the best approach for spinal exposure and for cosmesis.

E-Poster #21

Abnormal Growth Velocity in Severe Adolescent Idiopathic Scoliosis - A Longitudinal Study till Skeletal Maturity

Hiu Yan Yeung, PhD; Vivian W. Hung; Chi Wai Gene Man; Wei Jun Wang, MPHIL; Kwong Man Lee, PhD; Winnie C. Chu, MD; Ling Qin; Bobby KW Ng, MD (The Chinese University of Hong Kong); Yong Qiu, MD; Jack Chun Yiu Cheng, MD

Introduction: One of the hypotheses causations of adolescent idiopathic scoliosis (AIS) is imbalance of growth of the vertebral column. Previous study showed a disproportionate endochondral ossification-membranous bone growth in AIS girls. Although girls with AIS have a tendency to be taller than their peers, some studies showed that AIS girls have similar stature as their health peers. Thus, the growth velocity is thought to be important. This study aims to retrospectively analyse the growth velocity and the related changes in bone turnover markers in different severity groups in comparison with controls.

Methods: In this 4-year longitudinal study, 197 AIS girls and 118 healthy girls were included and followed up regularly until age 16. Their initial age is between 12 and 14. The Cobb's angle, corrected body height, arm span, body mass index (BMI), and serum alkaline phosphatase (ALP) and urinary deoxypyridinoline (Dpd) were measured. During the analysis, the patients were divided into 2 groups based on the final Cobb's angle at maturity: Moderate (Cobb's >20) and Severe (Cobb's >40). Each subject had at least 2 measurement points for the linear mixed model analysis which provides the average rates of change of the parameters.

Results: After adjust with the confounding factors, the growth velocity of the height and arm span of severe group was significantly higher than that of moderate group and health control by 25-42% and 58-71%, respectively. For BMI, AIS girls were significantly lower than the healthy subjects. For ALP and Dpd measurement, no difference in the rate of change between different groups were found though the moderate and severe AIS girls had higher ALP level and lower Dpd than controls.

Conclusion: The present study showed that AIS girls with different severity have different growth velocity and that the growth velocity of AIS girls with severe curve is significantly higher than the moderate curves and health controls. This is in accord with the biochemical marker level observed in the study. AIS girls have different degree of growth disturbance which may result to different curve severity. Abnormal growth velocity of AIS could reflect the underlying abnormality in the control mechanism and genetics of skeletal growth.



E-Poster #22

A Systematic Technique for Assessment of Thoracic Pedicle Screw Placement: Is it 'In' or 'Out'?

Brian Hsu, MD, BS, FRACS (Twin Cities Spine Center); Prof. Serkan Erkan; Chunhui Wu, PhD; Amir A. Mehbod, MD; Francis Denis, MD; Daryll C. Dykes, MD, PhD; Ensor E. Transfeldt, MD

Introduction: This study evaluates the effectiveness of a systematic technique for plain radiographic and image intensifier assessment of thoracic pedicle screw position.

Methods: Eight cadaveric adult thoracic spines were instrumented with titanium pedicle screws from T1 to T12. Screws were placed within the pedicle and outside the pedicle in all four quadrants. Each cadaver was imaged with orthogonal radiographs, image intensifier and high-resolution CT scans. . Using the image intensifier, 3 PA images and 2 lateral images were taken which facilitated more accurate interpretation. The images were read in a blinded fashion by 1 spine fellow and 4 staff spine surgeons. The results were compared with the screw position found at dissection.

Results: In total, 166 pedicle screws were placed in 7 specimens. The sensitivity and specificity were calculated for each imaging technique: plain radiographs (sens = 69%; spec = 88.3%), fluoroscopy (sens = 78%; spec = 86%), CT scan (sens = 82%; spec = 92%). The accuracy of correctly identifying 'out' screws (sensitivity) was higher using image intensifier than plain radiographs. The accuracy approached that of CT scans. The sensitivity and specificity decreased significantly at the upper and lower thoracic levels as those levels became further out of plane of the xray beam.

Conclusion: This methodology of interpreting the placement of pedicle screws can be reliably used intra-operatively using image intensifier imaging which gives an accuracy approaching that of CT scans. Fluoroscopy can be obtained in the correct angular plane of the screw. Three PA images and 2 lateral images using the fluoroscope are better than plain radiographs in assessing the correct position of thoracic pedicle screws.

Significance: In the thoracic spine, using fluoroscopy and a systematic reading method, the accuracy of pedicle screw placement can be assessed reliably.

E-Poster #23

The Effect of the Thoracolumbar Approach on Pulmonary Function in Adolescent Idiopathic Scoliosis

Burt Yaszay, MD (Scoliosis Associates); Kristin E. Kean, BA; Tracey P. Bastrom, MA; Baron S. Lonner, MD

Introduction: Depending on the surgical approach, studies have demonstrated improvement, decline, or no effect on pulmonary function in the treatment of adolescent idiopathic scoliosis (AIS). Little data exists directly evaluating the effect of a thoracolumbar approach in a homogenous AIS population treated by a single surgeon. The purpose of this study is to compare pulmonary function following either anterior spinal fusion (ASF) or posterior spinal fusion (PSF) of Lenke 5/6 (major thoracolumbar) curves and document their trend across a 2 year period.

Methods: Twenty-four AIS patients surgically treated for Lenke 5/6 curves were evaluated for vital capacity (VC) and peak flow (PF) before surgery and following surgery at 1, 3, 6, 12, and 24 months. Data was collected prospectively with a minimum follow-up of 24 months. Eight patients underwent ASF and 16 patients had PSF. Multivariate and repeated measures ANOVA was used to compare pulmonary function between groups and within each group, respectively.

Results: Between groups, no difference was seen in age, pre or postoperative curve magnitude, or baseline VC and PF ($p > 0.05$). At 1 month postoperatively, there was a significant decline in VC and PF following ASF compared with PSF ($p = 0.04$). After 1 month, no difference was seen. Compared with before surgery, the ASF group demonstrated a significant decline in VC at 1 and 3 months and returned to baseline at 6 months ($p < 0.05$). There was a similar decline in PF at 1 month but returned to baseline at 3 months. The PSF group never demonstrated a decline in VC or PF ($p > 0.05$). At two years, both groups demonstrated a significant increase in VC and PF ($p < 0.05$).

Conclusion: In Lenke 5 and 6 curves, an anterior thoracolumbar approach results in an initial decline in pulmonary function compared with PSF. However, at 2 years no difference was seen. Documented return of pulmonary function did not occur until 6 months for ASF.



E-Poster #24

Are There SRS Preoperative Questionnaire Differences between Kyphosis and Scoliosis Patients?

Timothy R. Kuklo, MD, JD (Washington University School of Medicine); Mohammad Diab, MD; B. Stephens Richards, III, MD; Daniel J. Sucato, MD, MS; Lawrence G. Lenke, MD; Spinal Deformity Study Group

Introduction: To determine the self reported preoperative quality of life of patients with kyphosis versus scoliosis using the Health Related Quality of Life SRS22 questionnaire.

Methods: This is a comparative prospective evaluation of preoperative SRS22 scores from a multi-center database. Specifically, preoperative comparison of kyphosis (95 pts, ave. age 15.1 yrs., 65M/30F) versus scoliosis (2,243 pts., ave age 14.3, 403M/1,840F) quality of life using the SRS22. Comparison included sub-analysis of pain, appearance, activity, mental and satisfaction scores, as well as total score.

Results: The kyphosis group was significantly greater in males vs. females, and slightly older (both $p < 0.05$). Kyphosis scores were significantly lower for pain (mean $3.89 \pm .93$ vs. $4.10 \pm .72$, $p = 0.035$), thus indicating a higher level of pain; activity (mean $3.93 \pm .70$ vs. $4.12 \pm .55$, $p = 0.011$), thus indicating a lower activity level; and average total score (mean $3.68 \pm .62$ vs. $3.84 \pm .47$, $p = 0.013$) when compared to scoliosis. SRS scores for appearance, mental, and satisfaction domains were also lower for kyphosis compared to scoliosis, but these differences were not statistically significant. The effect sizes, however, were in the small range (0.26, 0.31, and 0.31 respectively for pain, activity and total score), indicating that the strength of the relationship was not strong. This is most likely due to the lower incidence of kyphosis than scoliosis, and therefore, the smaller numbers in the study.

Conclusion: All SRS22 domain scores were lower for kyphosis versus scoliosis and significantly lower for pain (more pain), as well as activity (lower activity), and total score. Most surprising is the pain score and activity level which indicate that kyphosis has a more significant impact on daily living than scoliosis. This frequently translates more to operative indications with kyphosis (pain/activity) compared to scoliosis (curve progression).

E-Poster #25

Efficacy of Hemivertebra Resection for Congenital Scoliosis (CS): A Multicenter Retrospective Comparison of Three Surgical Techniques

Michael F. O'Brien, MD (Miami Children's Hospital); Harry L. Shufftebarger, MD; Peter O. Newton, MD; Randal R. Betz, MD; Baron S. Lonner, MD; Lynn Letko, MD; Jürgen Harms, MD; Alvin H. Crawford, MD; Suken A. Shah, MD; Paul D. Sponseller, MD; John M. Flynn, MD; Oheneba Boachie-Adjei, MD; Munish C. Gupta, MD; Angel Macagno, MD; Mark F. Abel, MD

Introduction: We compare the outcomes of 3 surgical treatments for CS due to a HV.

Methods: A multi-center retrospective study of patients with CS due to 1 or 2 level HV was performed. The surgical treatments were: Group 1: fusion w/o correction (hemi-epiphysiodesis or in-situ fusion without instrumentation), Group 2: correction w/o HV resection (with or w/o anterior or posterior release) with PI, and Group 3, HV resection (anterior and/or posterior) with PI.

Results: 76 patients with minimum 2 year f/u, were evaluated who were treated between 1991 and 2004. The mean age was 8 years (range 1-18). The HV were: fully segmented, non incarcerated (n=51, 67%), incarcerated (n=1, 1%), and semi-segmented (n=24, 32%). There were 65 patients with single and 11 patients with double HV. There were 14(18.4%) Group 1, 20 (26.3%) Group 2, and 42 (55.3%) Group 3 patients. Group 1(37°) and Group 3(35°) had smaller pre-op curves than Group 2(55°) (p<0.01). The overall complication rate for the entire group was 30%: Group 1(23%), Group 2(17%), Group 3(44%). Group 3 had better % correction at 2 years post-op compared to Group 1 and 2 (p<0.001). Group 3 had shorter fusion (p=0.001), less EBL (p=0.03), and a trend toward shorter operative times compared to Group 2 (p=0.10). Group 1 and 3 had similar length of fusion. One site adept at posterior HV resection, achieved a mean 84±19% coronal correction at 2 years post-op compared to the other group 3 patients who had a mean 50±25% (p<0.001) percent correction suggesting experience with the technique may be important for an optimal result.

Conclusion: While HV resection (Group 3) has a higher complication rate than the other two techniques, posterior HV resection (Group 3) in younger patients results in better % correction than either Insitu fusion (Group 1) or Instrumentation without resection (group 2) and it achieves the correction with a shorter fusion than in Group 2.

Table 1. Treatment Groups for Congenital Spinal Deformity.

	N	Pre-op Curve size	Age @ Surgery	#	Complications	EBL	Operative Time	2 yr % correct
				Level fused				
Group 1: Fusion without Correction	14	37° ± 13°	10 ± 6	3 ± 4	1 infection	344 ± 296	222 ± 104	27 ± 15
					2 other			
Group 2: Correction without HV Resection	20	55° ± 26°	10 ± 5	7 ± 3	1 infection 1 neurological 1 instrumentation	837 ± 691	324 ± 124	42 ± 20
Group 3: Correction with HV Resection	42	36° ± 9°	5 ± 4	3 ± 2	3 infection	455 ± 461	255 ± 89	73 ± 21
					5 neurological 5 instrumentation 4 other			

* The FDA has not cleared a drug and/or medical device in use described in this presentation (i.e., the drug or medical device is being discussed in an off-label use). For full information see page 10.

E-Poster #26

Direct Vertebral Rotation (DVR) in the Treatment of Thoracolumbar/Lumbar Adolescent Idiopathic Scoliosis (AIS): Can It Optimize Correction When Fusing to L3?

Kathryn A. Keeler, MD (Washington University); Ronald A. Lehman, Jr., MD; Lawrence G. Lenke, MD; Keith H. Bridwell, MD; Brenda A. Sides, MA

Introduction: Pedicle screw(PS) fixation combined with direct vertebral rotation(DVR) provides powerful triplanar correction in scoliosis surgery. The purpose of this study was to analyze and compare a consecutive series of AIS patients with structural thoracolumbar/lumbar (TL/L) curves treated with PS constructs with and without DVR.

Methods: 32 consecutive AIS patients who underwent posterior spinal fusion (PSF) to L3 with a minimum 2yr follow-up were evaluated. Patients were divided into 2 groups based on correction technique. Group 1: DVR (n=17), and Group 2: non-DVR (n=15). Radiographic measurements included preoperative (preop), postoperative (PO), and 2-year postop (2yr). Groups were analyzed for deformity correction, lowest instrumented vertebra horizontal (LIV-H) angle, and coronal balance.

Results: There was no significant difference in preop main thoracic (MT) or TL/L curves between the two groups (p=0.08 and 0.12, respectively) (Table). Between group analysis of the MT curve did not show a significant difference when comparing changes over time from preop to 2yrs (p=0.88). The average TL/L curve in the DVR vs non-DVR groups measured 50.9 vs 43.4° preop, corrected to 10.1 vs 12.7° PO (both p<0.0001), and measured 12.1 vs 13.4° at 2 years PO (p=0.13 and 0.66). Between group test interaction did not show a significant difference when comparing changes over time from PO to 2 years (p=0.5). The average LIV-H in the DVR Group measured 19.8° preop, corrected to 3.3° PO (p<0.0001), and was maintained at 3.0° at 2 years PO (p=0.20). On the contrary, the average LIV-H in the non-DVR Group measured 15.8° preop, corrected to 3.2° PO (p<0.0001), but showed regression at 2 years to 5.4° (p=0.0003), thus there was a significant difference in changes over time from PO to 2 years between the groups (p=0.04).

Conclusion: The average TL/L curve correction was 77% in the DVR Group and 68% in the non-DVR Group. There were no construct-related complications/decompensation, pseudarthrosis or neurologic deficits. Patients treated with DVR had excellent maintenance of the L3 horizontal angle; however, without DVR showed regression of the L3 horizontal angle.

Significance: DVR allows for maintained correction of LIV horizontal angle in patients undergoing long PSF to L3 at 2 years F/U.

Group 1 (Direct Vertebral Rotation): Radiographic Changes Overtime

	Preoperative	Immediate Postoperative	2 years Postoperative
Main Thoracic Curve	52.2°+12.6*	12.6°+7.9	12.9°+7.4
Thoracolumbar/Lumbar Curve	50.9°+18.3 [‡]	10.1°+7.7	12.1°+8.8
LIV-H angle	19.8°+13.7	3.4°+2.7	3.0°+4.8

Group 2 (Non-Direct Vertebral Rotation): Radiographic Changes Overtime

	Preoperative	Immediate Postoperative	2 years Postoperative
Main Thoracic Curve	60.3°+11.7*	18.6°+7.9	18.9°+7.6
Thoracolumbar/Lumbar Curve	43.4°+13.8 [‡]	12.7°+7.6	13.4°+7.1
LIV-H angle	15.8°+11.8	3.3°+5.2	5.5°+5.7

*No significant difference between Groups 1 and 2 (p=0.08)

[‡]No significant difference between Groups 1 and 2 (p=0.12)

E-Poster #27

Is Aprotinin Safe for Pediatric Spinal Deformity Surgery?

Katherine M. Bedigrew, BS (Washington University School of Medicine); Timothy R. Kuklo, MD, JD; Scott J. Luhmann, MD; Laura A. Meyer, MA; Lawrence G. Lenke, MD; Keith H. Bridwell, MD

Introduction: Aprotinin is effective in reducing blood loss and transfusions; however, it was recently removed from the market due to safety concerns, specifically a possible increase in all cause mortality and renal dysfunction in adult CABG pts.

Methods: This is a retrospective review of 117 consecutive pediatric spinal deformity pts (60M, 57F; avg age 13.2 yrs, range 3.7- 22) receiving intraoperative aprotinin (10 mg/kg loading dose/30 min and ½ mg/kg/hour) at a single institution (1999-2007). Dx included: 32 severe idiopathic scoliosis/kyphosis, 29 CP, 19 DMD, 19 congenital scoliosis, 9 myelomeningocele, 2 spondylolisthesis, and 7 SMA. In addition to standard demographic data, we evaluated EBL/%EBV, transfusion requirements, increase in postop Cr > 0.5, total ICU/hospitalization and complications.

Results: PSF was performed in 115/117 (98.2%) pts. Avg EBL was 685 ± 418cc (100-2300) or 54 ± 36cc/level. The EBL/%EBV was 26% ± 16% or 2.1%/level fused. CP pts had the highest EBL/%EBV (32.% ± 18%). 89 pts received a transfusion (66 intraop, 23 postop). CP pts had the highest periop transfusion requirement (537 cc). Avg length of ICU and hospital stay was 3.0 days ± 6.1 and 11.8 days respectively. As for renal function, the periop Cr level never exceeded the standard laboratory values for each age range, and there were no pts with a clinical Cr change of > 0.5 mg/dL immediately postop or at 1 wk postop (-0.04 mg/dL ± .11). BUN:Cr ratios were unchanged (26.5 postop/27.5 at one week) and were considered WNL. The complication rate was 27% (32/117): 14 major (12%) and 18 minor (15%) -equal to matched cohorts. Major complications included: 7 respiratory distress necessitating ICU care, 3 implant infections, 1 subdural fluid collection, and 1 CVA, and were highest in the CP group (31%). Only 1/117 (.8%) of the complications was potentially related to aprotinin -CVA on POD5 without obvious cause in a CP pt with a connective tissue disorder. There were no anaphylactic reactions.

Conclusion: Aprotinin use is not associated with a higher complication rate or renal dysfunction in this high risk population. Continued availability is appropriate as there are few efficacious alternatives.

Significance: Aprotinin is not associated with renal dysfunction in the pediatric population.

E-Poster #28

Cervical Sagittal Plane Decompensation After Pediatric AIS Surgery

M. Darryl Antonacci, MD, FACS (Shriners Hospitals for Children, Philadelphia); Patrick J. Cahill, MD; Jason Nydick, DO; JahanGir Asghar, MD; Mark Tantorski, DO; David H. Clements, III, MD; Randal R. Betz, MD; Amer F. Samdani, MD; Harms Study Group

Introduction: There have been several attempts to characterize the relationship between thoracic kyphosis, lumbar lordosis, and pelvic alignment in sagittal balance. To our knowledge, there has been no attempt to correlate the effect of post-op thoracic kyphosis on the cervical spine.

Methods: Radiographic parameters were evaluated on patients undergoing pedicle screw posterior spinal instrumentation and fusion (PSIF) for Lenke Type 1 and 2 curves with two year follow-up and adequate C-spine visualization. Parameters included: fusion levels, cervical sagittal balance (C2-C7), thoracic sagittal balance (T2-T12, T5-T12), lumbar sagittal balance, C2 & C7 plumb lines, Risser, Cobb angles, sacral slope, pelvic incidence, tilt, and obliquity.

Results: 22 patients met inclusion criteria. Pre-op, 6 of 22 (Group A) had frank cervical kyphosis (mean +10.5°) and mean pre-op T2-T12 kyphosis of 26.2°. Post-op, Group A remained in cervical kyphosis with mean thoracic kyphosis:19.5 (p<.05). Pre-op, 16 of 22 had neutral to lordotic cervical spines (mean -13.75°) with thoracic kyphosis (mean: 45°). Post-op, 8/16 (Group B) developed cervical sagittal decompensation (>5°) with 6 developing frank cervical kyphosis (mean +10.5°, p<.006). In Group B, post-op thoracic kyphosis was 25.6°, p<.004. The other 8 of 16 (Group C) did not decompensate cervically and had a post-op thoracic kyphosis of 37.5° (vs. Group B., p<.05). Of the remaining parameters, only sacral slope demonstrated a statistically significant decrease (mean 46.4 to 37.6) between Groups B and C (p<.007).

Conclusion: PSIF had a significant hypokyphosing effect on the thoracic spine (19/22 patients). If thoracic kyphosis is decreased to below 30° the cervical spine decompensates into kyphosis. The long term effect of cervical kyphosis in pediatric scoliosis patients is not well known. The surgeon can influence the sagittal contour of the cervical spine through the construct in the thoracic spine.

Group	Cervical		Thoracic	
	Pre-operative Alignment	Post-operative Alignment	Pre-operative Kyphosis	Post-operative Kyphosis
A	Kyphosis	Kyphosis	26.2	19.5
B	Neutral or Lordosis	Kyphosis	45	25.6
C	Neutral or Lordosis	Neutral or Lordosis	44	37.5

E-Poster #29

Deformity Correction in Tuberculosis of Spine

Sudhir Srivastava, MBBS, MS (K.E.M Hospital); Kshitij M. Agrawal, MBBS; Manish S. Kawade, MBBS

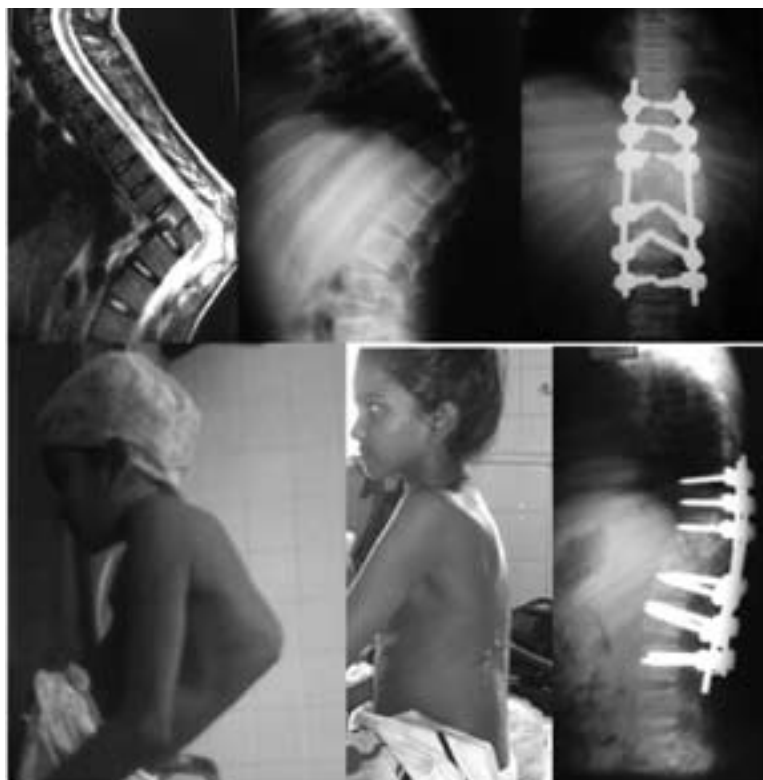Introduction: Neurological deficit and deformity (kyphosis) are the important presentation / sequelae of this morbid disease. Deformity correction in tuberculosis of spine though demanding is a rewarding procedure if done meticulously with proper pre-operative planning

Methods: In a span of ten years we operated 126 patients of tuberculosis of spine of different regions with kyphotic deformity. There were associated coronal plane deformities in 32 patients. Out of 126 patients there were 90 patients with wet lesions (exudative) and 36 patients with healed tuberculosis and significant deformity. The angle of deformity ranged from 20 to 125 degrees. Out of 36 healed lesions with significant kyphotic deformity, 9 patients had late onset paresis. Out of 90 wet lesions with deformity 82 patients had neurological deficit. Cervical and lumbar deformity required both anterior and posterior procedures for correction, stabilization and reconstruction. In dorsal spine (Wet lesion)-we use a versatile approach to do decompression, internal fixation and reconstruction through a single incision without changing patient's position (lateral). Healed lesion with kyphotic deformity were dealt with closed wedge osteotomy or column subtraction technique - all steps via posterior route (prone position). The implants used for fixation were Hartshill -sublaminar wire or Pedicular screw-rod system

Results: In all the wet lesions with deformity full correction could be achieved. 5 patients showed loss of correction in follow up due to graft failure (3 patients) and implant failure (2 patients). Out of 36 healed Koch's with deformity, 9 patients who had early paresis were under corrected. Rest 27 patients had full biomechanical correction and none of them lost their correction at the final follow-up. One patient had neurological deterioration and died of chest complication during early post-operative phase. Average correction was of 72 degree

Conclusion: Deformity correction in tuberculosis of spine has always been feared and guarded. Though demanding, if done adhering to shortening principles and gentleness, it is rewarding.

Significance: Deformity correction in tuberculosis of spine is rewarding if done meticulously.





E-Poster #30

Severe Restrictive Lung Disease and Spinal Surgery in a Pediatric Population

Francisco Sanchez Perez-Grueso, MD (La Paz Hospital); Jorge Payo, MD

Introduction: The purpose of the surgery of spinal deformity in pediatric patients with severe restrictive lung disease is to improve pulmonary function and quality of life, and increase the patients' life expectancy.

Methods: Inclusion criteria: FVC<40%, age<19 years, and scoliosis. Minimum follow-up: 2 years. Etiology: neuromuscular disease: 17; other etiologies: 7.8 had preoperative home BiPAP, 15 preoperative in-hospital BiPAP, and 2 preoperative mechanical ventilation.

Results: 24 patients met the criteria: 13 males and 11 females; mean age: 13 years. Mean preoperative angle of the main curve: 88 degrees; and 37 degrees at follow-up. Mean preoperative FVC: 26%. Mean duration of ICU stay: 5 days; mean postoperative duration of hospitalization: 17 days. Posterior fusion: 19; double approach: 5. In the immediate postoperative period, 16 required BiPAP and 2 volumetric ventilation. Complications: intraoperative, 1 death due to acute heart failure; early postoperative, 4 respiratory failures and 1 respiratory infection. Other minor complications in 6. At the last follow-up, ventilatory support was discontinued in 4 patients, 4 continued without ventilation, and 16 continued requiring ventilatory support; mean FVC postoperative 29%.

Conclusion: Major reconstructive vertebral surgery is well tolerated in patients with restrictive lung disease. Preoperative and postoperative assessment by specialists working in the pediatric age group is important. Familiarity with spinal surgery is needed to decrease operative time, bleeding and complications.

Significance: Pediatric patients with neuromuscular scoliosis have shown an inverse relationship between the vital capacity and the postoperative complications. One of the main risk factors for the development of postoperative lung complications is treatment with anterior fusion. In our opinion, the etiology of scoliosis is a risk factor for the development of postoperative pulmonary complications and for inability to recover lung function: in idiopathic scoliosis the deformity itself is the cause of functional deterioration, in neuromuscular disease the disease persists after the surgery. We found only 3 articles whose results could be compared with ours (table 1). We wish to emphasize the low rate of postoperative complications in our group.

(See table next page)



VARIABLES	WAZEKA, et al	RAWLINS, et al	GILL, et al	Our group
N	21	32	8	24
Follow-up (months)	47.3	58	48	37
Age (years)	11.5	13	12	13
Double approach	18	19		5
Posterior approach alone	3	13		19
Anterior levels fused	6			6
Posterior levels fused	11	13		15
Preoperative Cobb angle	82°	87°	70°	88°
Postoperative Cobb angle	35°		32°	37°
Preoperative spirometry	FVC 30.5%	VC 31%	FVC 20%	FVC 26%
Postoperative spirometry			VC 18%	FVC 29%
ICU (days)		6	3	5
Duration postoperative hospitalization (days)	18	27	14	17
Complications	0 deaths 0 neurological complication 1 implant failure 2 deep infection 2 pancreatitis 1 postoperative tracheostomy 2 pneumonia 1 preoperative tracheostomy 2 pneumothorax 4 atelectasis	3 postoperative tracheostomy 2 pneumonia 2 reintubation 1 pseudoarthrosis 1 preoperative tracheostomy	0 deep infection 0 pulmonary complication 0 tracheostomies	1 deaths 2 radicular pain 2 bloody exudate 1 dehiscence 4 respiratory insufficiency 1 atelectasis 1 pneumonia 1 paralytic ileum



E-Poster #31

Pedicle Screw Trajectory is Improved with Tapping in Thoracic Spines

Serkan Erkan, MD (Twin Cities Spine Center); Brian Hsu, MBBS, FRCAS; Chunhui Wu, PhD; Amir A. Mehbod, MD; John Perl, II, MD; Ensor E. Transfeldt, MD

Introduction: Pedicle screws are placed with the guidance of pilot holes. The correct trajectory of pilot holes is verified by visual inspection, palpation with a pedicle probe, or radiographs. However, a pilot hole alone does not insure the screw will follow the pilot hole trajectory. No studies have characterized the risk of misalignment of a pedicle screw with respect to its pilot hole trajectory. The objective of this study is to quantify the misalignment between pedicle screws and pilot holes with or without tapping.

Methods: Six human cadaveric thoracic spines were used. The entry points were created with a 4mm burr under fluoroscopic guidance. Pilot holes (30mm deep) were introduced with a 3mm straight pedicle probe. Straight steel wires (1.6mm in diameter) were temporarily inserted into all pilot holes and axial computed tomography (CT) scans were performed at 1.25mm resolution to measure the orientation of each pilot hole with respect to its anatomic landmark. The left side pedicles were tapped with 4.5mm fluted tap and the right side pedicles remained untapped. One hundred and forty four pedicle screws (Medtronic Legacy Screws, 5.5mm in diameter and 45mm in length) were inserted into the tapped and untapped pedicles. CT scans were performed following pedicle screw placement to record the orientation. The trajectories of pilot holes and screws were measured with three-dimensional vector analysis. The positions of the pilot holes and pedicle screws were also qualitatively evaluated with CT scans by experienced spine surgeons.

Results: One hundred and thirty eight pilot holes (96%) were inside pedicles. For the untapped side, 9 out of 72 screws (12.5%) did not follow pilot holes and were outside the pedicles. For the tapped side, two screws (2.8%) did not follow the pilot holes and breached the pedicles. The average misalignment angle between the screw and pilot hole trajectory was 5.3° and 3.2° for the untapped side and tapped side respectively ($P < 0.05$).

Conclusion: Tapping of pilot holes (1mm under tap) helps align pedicle screws and reduces the risk of screw malposition.

E-Poster #32

**JOHN H. MOE AWARD NOMINEE FOR BEST BASIC SCIENCE PRESENTATION

A Study on the Effect of Melatonin Toward the Proliferation and Differentiation of Osteoblasts in Adolescent Idiopathic Scoliosis

Chi Wai Gene Man; Hiu Yan Yeung, PhD; Wei Jun Wang, MPHIL; Kwong Man Lee, PhD; Bobby KW Ng, MD (The Chinese University of Hong Kong); Vivian W. Hung; Yong Qiu, MD; Jack Chun Yiu Cheng, MD

Introduction: Low BMD has been clinically reported in AIS patients. Suggestions been made that the dysfunction of MLT signaling pathway might be the key to the spinal deformity in AIS patients. Based on prior studies, MLT has shown to influence and regulate skeletal growth and bone formation in both human and rats. However, there is a lack of direct evidence on the role of MLT on AIS. Hence, we would like to investigate the effect of MLT on AIS bone cells at the cellular level.

Methods: In vitro assays were performed with osteoblasts isolated from 7 female patients with severe AIS and 7 normal controls. The osteoblasts were treated with different concentration of MLT (0, 10⁻¹¹, 10⁻⁹, 10⁻⁷, 10⁻⁵M). The effect of the treatment in cell proliferation was tested by MTT cell viability assay. As for the effect of MLT on osteoblasts differentiation, cells were cultured overnight in osteogenic medium. Then, they were given different concentration of MLT for 3 days, prior to measuring the alkaline phosphatase activity. Moreover, the mineralization of the matrix was determined by qualitative analysis of the alizarin red S staining after 18 days of culture.

Results: There was a significant difference between the control and the AIS at the MLT concentration of 10⁻⁹ to 10⁻⁵ M (p<0.05). In the control, MLT could stimulate the osteoblasts to proliferate when compared with the basal level (p<0.05). Likewise, MLT could also enhanced differentiation in these cells, with incubation overnight in osteogenic medium (p<0.05). The cells were also found to form mineralized matrix. In contrast, none of the osteoblasts from AIS could shown any of the changes when the same concentration of MLT is added.

Conclusion: For the very first time, we have demonstrated that there is a relative difference between the AIS and the normal osteoblasts in response to MLT. This may account for the observation of low BMD and abnormal growth which may play an important role in the etiopathogenesis of AIS.

E-Poster #33**The Ventral Lamina and Superior Facet Rule: The Key to Accurate Placement for Thoracic Pedicle Screws Confirmed by Anatomic Dissection of 102 Thoracic Pedicles**

John Ferguson, FRACS (Starship Hospital); Ronald A. Lehman, Jr., MD; Lawrence G. Lenke, MD; Gene Cheh, MD; Kei Watanabe, MD, PhD; Youngbae B. Kim, MD; Young Woo Kim, MD; Michael D. Daubs, MD

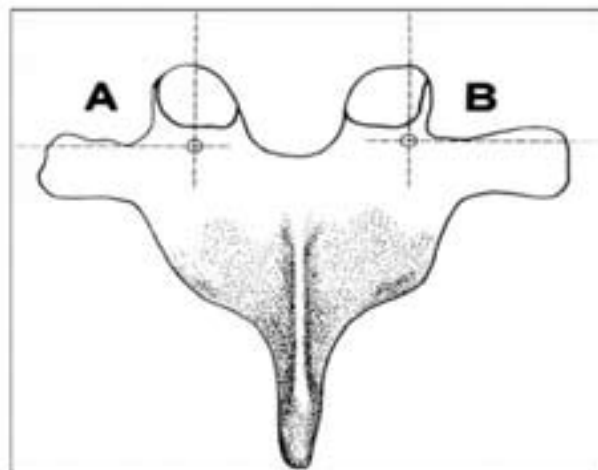
Introduction: With the increasing popularity of thoracic pedicle screws, the freehand technique has been espoused to be safe and effective. The recent concepts of the lateral facet rule and the ventral lamina have provided key insight for improved accuracy.

Methods: Seven cadaveric thoracic spines (102 pedicles) were harvested and divested of all soft tissue. Complete facetectomies were performed at all levels so the superior articulating facet (SAF) was visualized. Using digital calipers, the exact width of each SAF, distance from the lateral border of the SAF to the medial wall of the pedicle and ventral lamina (formed by the roof of spinal canal; confluent laterally with medial aspect of medial pedicle wall) were measured in millimeters.

Results: One hundred two pedicles were dissected and measured. The ventral lamina was clearly identifiable at all levels forming the medial aspect of the medial pedicle wall. Reliable measurements caudad to T11 were not reliable. The mean facet width from T1-T8 averaged 11mm, while from T9-T11 averaged 12.3mm ($p < 0.05$). The average distance from the lateral aspect of the SAF to the ventral lamina was 7mm from T1-T8, and 8mm from T9-T11. For all 102 facets/pedicles, the ventral lamina was located medial to the midpoint of the SAF ($p < 0.0001$).

Conclusion: The ventral lamina is an anatomically reproducible structure. In all specimens, the ventral lamina was located medial to the midportion of the superior articular facet (SAF). The starting point for thoracic pedicle screws should be 2-3mm lateral to the midpoint of the SAF ("superior facet rule"), thereby avoiding penetration into the spinal canal.

Significance: A thorough understanding of the ventral lamina concept and adherence to the "superior facet rule" will significantly improve the accuracy and safety of thoracic pedicle screw placement by avoiding penetration into the spinal canal.



E-Poster #34

The Effect of Implant Density on the Sagittal Curve in Scoliosis Correction: Correlation with the Number and Type of Fixation Anchors

David H. Clements, III, MD (Shriners' Hospital for Children); Randal R. Betz, MD; Peter O. Newton, MD; Michelle C. Marks, PT, MA; Tracey P. Bastrom, MA; Harms Study Group

Introduction: Controversy exists regarding the number and type of spinal anchors needed to achieve optimal structural curve correction in adolescent idiopathic scoliosis (AIS). The purpose of this study was to determine how 'implant density' effected the postoperative sagittal contour at 2 years in patients with AIS.

Methods: An analysis of 360 AIS patients treated with posterior instrumentation and having greater than 2 year follow-up was performed. The sagittal curve change was measured T5-T12, T2-T12, T10-L2 and expressed as absolute change (from pre-op to 2 years post-op) and correlated with the percentage of available implant sites utilized within the measured curve (implant density, max 2 per level). The correlation of kyphosis change to the number of hooks, wires, and screws was also performed. Analysis of variance was used to evaluate change in kyphosis among all screw constructs, hybrids, and all hook constructs.

Results: The higher the implant density within the curve, the greater the loss of preoperative to postoperative kyphosis. This result was significant for kyphosis measured T2-12 ($r = -0.13$, $p < 0.01$), and T5-12 ($r = -0.16$, $p < 0.001$). At T10-L2, increasing screw implant density correlated with decreasing kyphosis ($r = -0.40$, $p < 0.001$), and increasing hook implant density correlated with increasing kyphosis ($r = 0.33$, $p < 0.001$). On average, all hook constructs increased kyphosis T5-T12 by $2^\circ \pm 9^\circ$, which was significantly different than the average decrease seen in hybrids ($-4.3^\circ \pm 13^\circ$, $p = 0.039$). No significant differences were observed for the screw constructs ($-3.8^\circ \pm 12^\circ$). A significant increase in kyphosis from T10-L2 was seen in hook constructs ($10^\circ \pm 15^\circ$) compared to decreases seen in hybrid ($-0.59^\circ \pm 15^\circ$, $p < 0.001$) and all screw constructs ($-3^\circ \pm 11^\circ$, $p < 0.001$).

Conclusion: The higher the implant density within the major thoracic curve, the flatter or less kyphotic the sagittal contour became at 2 years postoperatively measured from T5-12 or T2-12. At T10-L2, the sagittal contour became more kyphotic with more hooks and less kyphotic with more screws. This effect on sagittal contour should be considered in patients when surgical decisions concerning type, density of implants, and adjustments to rod contouring are made.



E-Poster #35

***Growing Rods in Myelomeningocele for Scoliosis Treatment: Long Term Follow Up**

Richard E. McCarthy, MD (Arkansas Spine Center); Behrooz A. Akbarnia, MD; Frances L. McCullough, MNSc; Pooria A. Salari, MD; David L. Skaggs, MD; George H. Thompson, MD; Suken A. Shah, MD; Francisco Sanchez Perez-Grueso, MD; Marc A. Asher, MD; Muharrem Yazici, MD; Growing Spine Study Group

Introduction: Scoliosis is a common and often severe deformity in myelomeningocele patients, frequently presenting at an early age. Little has been reported regarding the use of growing spinal instrumentation in this population.

Methods: Fifteen myelomeningocele patients (9 male; 6 female) with early onset scoliosis underwent lengthening procedures utilizing a variety of instrumentation techniques: 5 traditional dual growing rods, 3 single growing rods, 3 hybrid VEPTR's, 4 Luque trolley, and 1 Shilla. The average age at surgery was 7 yrs. (2-15 yrs). Seven patients have had final fusion with instrumentation performed.

Results: Follow-up was 6 years (2-14). The average preoperative scoliosis Cobb angle was 74 degrees (40-100). Average curve at six week follow-up was 36 degrees (7-72) and at last follow-up was 42 degrees (7-75). Truncal height improved an average of 12% over the length of the study. The average number of surgeries per patient was 5. The number of lengthenings of the distraction based systems averaged 4 (1-12). The Luque trolley and Shilla constructs are designed as self-lengthening systems. Three patients had fractured rods and one patient had rod migration into the sacrum. There were no infections and no changes in neurologic level as a result of the lengthenings. The complication rate was 6%. There was one death due to causes unrelated to the spine. The space available for lung (SAL) increased an average 11% over the length of the study.

Conclusion: Treatment of early onset scoliosis in children with myelomeningocele can be performed successfully utilizing a variety of growing rod systems in this complex patient population. These 15 patients showed an increase in truncal height and an increase in lung space with an acceptable complication rate.

Significance: Growing rod procedures may be one of the options for surgical treatment of patients with scoliosis due to myelodysplasia.

E-Poster #36

**JOHN H. MOE AWARD NOMINEE FOR BEST BASIC SCIENCE PRESENTATION

Tissue Engineered Stem Cell-Bioceramic Composite Enhance Posterior Spinal Fusion without Decortication

Chun wai Chan, MD, PhD; Celine Fan Fong Hui; Wei min Pan, MD; Kwong Man Lee, PhD; Prof. Ling Qin; Yun Yu Hu., MD; Jack Chun Yiu Cheng, MD (The Chinese University of Hong Kong)

Introduction: Extensive decortication of spinal segments during spinal fusion surgery is associated with significant bleeding. This study was to investigate whether tissue engineered composite could promote posterior spinal fusion without decortication in a rabbit model.

Methods: Bone marrow was aspirated from proximal femur of 15 weeks old New Zealand White rabbit. The bone marrow derived MSCs were isolated by adherence on plastic culture ware and expanded in number with DMEM and 10% FCS. The osteogenic differentiation of MSCs was induced by osteogenic supplement including dexamethasone, beta-glycerophosphate and ascorbic acid. Two modality of cell number 5X10⁶ (Low-cell group, n=6) and 10X10⁶ (High-cell group, n=6) were seeded on beta-tricalcium phosphate block (TCP). These stem cell-TCP composites were cultured with plain DMEM for one day and implanted onto transverse processes of L5 and L6 without decortication. For the control group (n=6), the TCP block alone was implanted with decortication. The spinal segments were harvested at week 12 and subjected to the assessment of manual palpation, microCT and pQCT analysis and undecalcified histology stained with toluidine blue.

Results: In the High-cell group, 67% of samples showed rigid segment fusion contrasting with 0% in the Low-cell and control group by manual palpation. MicroCT 3D reconstructive images of the High-cell group showed bony fusion of the transverse processes. The BMC of transverse processes in High cell group was 60.6% and 55.2% significantly greater than Low-cell and control group. The volume in High-cell group was 20.8% greater than Low-cell group. BMD of the transverse processes in High-cell group was 34.0% and 39.9 % which were significantly greater than the Low-cell and control group respectively. More cancellous bone was also found in the transverse processes near mineralization front of High-cell group.

Conclusion: The higher cell number of MSC-TCP composite enhanced spinal fusion even in the absence of decortication.

Significance: Implantation of bioengineered composite might serve as an alternative method in enhancing posterior spinal fusion without decortication with the distinct advantage of reducing the morbidity associated with decortication and donor site graft harvesting.



E-Poster #37

Posterolateral Fusion vs. Circumferential Fusion Using Local Bone Graft and Hydroxyapatite Granules for Degenerative Lumbar Spine Disease: A Prospective Cohort Study

Osamu Shirado, MD (Saitama Medical University); Tomohisa Nomoto, MD; Keisuke Takahashi, MD; Hiromi Oda, MD; Ken Nakashita, MD

Introduction: The purpose of the current study was to analyze clinical and radiographic outcomes of patients treated by circumferential fusion in comparison with those treated by instrumented PLF.

Methods: A prospective cohort consisted of 72 patients with degenerative lumbar spine disease; 63% with degenerative lumbar spondylolisthesis. There were 34 men and 38 women with a mean age of 62.5 years. Thirty patients underwent PLF with pedicle screw instrumentation, and forty-two patients underwent circumferential spinal fusion by means of PLIF with the use of a titanium cage, followed by instrumented PLF. Local bone harvested during the decompressive procedure, supplemented by hydroxyapatite (HA) granules, was grafted for PLIF and PLF. Clinical outcome measures included JOA score and ODI. Radiographic outcome measures were fusion status, instrumentation failure, and lumbar lordosis on the sagittal plane. Differences between groups were tested by Mann-Whitney U test.

Results: Follow-up was 95.8% of the original study population. Mean follow-up period was 3.6 years ranging 2-7 years. There was no significant difference in gender, age, and preoperative clinical symptoms between two groups. Although significant improvement of JOA and ODI scores was obtained in both groups, there was no statistically significant difference between two groups. There was a significant increase in lumbar lordosis at the follow-up in the circumferential group ($p < 0.05$). Postoperative wound infection and pseudarthrosis occurred in 1 patient of the circumferential group, respectively.

Conclusion: Instrumented PLF and circumferential fusion using local bone graft and HA granules for the degenerative lumbar spine disease equally provided a satisfactory improvement in the JOA and ODI at a minimum 2-year follow-up. Radiographic superiority in circumferential fusion may result in more favorable outcome in long-term follow-up.

Significance: Instrumented PLF and circumferential fusion using local bone graft and HA granules for the degenerative lumbar spine disease equally provided a satisfactory improvement in the JOA and ODI at a minimum 2-year follow-up.

E-Poster #38

Single Stage Total Resection of Aggressive Osteoblastoma of the Cervical Spine

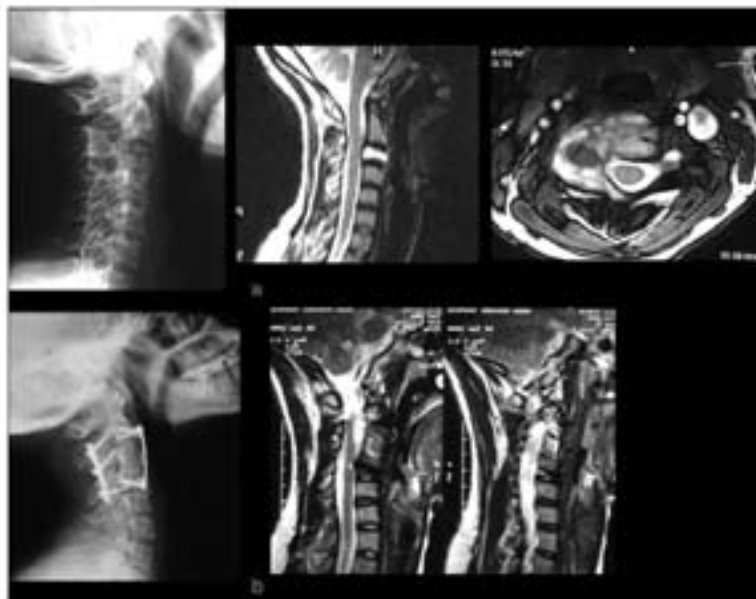
Yasser ElMiligui MD, FRCS (Cairo University); Wael Koptan, MD; Hazem B. Elsebaie, FRCS, MD

Introduction: The spine accounts for 40-50% of all osteoblastomas from which only 20% are located in the cervical spine. Although spinal osteoblastomas were known to arise from the posterior elements, anterior involvement is found. Surgical treatment is a challenge due to the tumor's location, proximity to the near by neural and vascular elements and local aggressiveness. The reported recurrence rate ranges from 10% - 30% of cases despite excision. **Study Design:** A retrospective clinical study. **Objectives:** To analyze a consecutive series of patients with cervical spine osteoblastoma, affecting the majority of the vertebra and treated by a combined front and back approach with total excision and spinal reconstruction.

Methods: Nine patients with aggressive osteoblastoma of the subaxial cervical spine were included. The average age was 18y (range 8 - 26y). There were 5 males and 4 females. All patients presented with persistent pain, limited range of motion of the neck and 3/9 had a neurological deficit. All patients had a sequential front and back total excision. Anteriorly, the tumour was thoroughly resected, the vertebral artery was exposed and vertebral body was reconstructed by an iliac crest strut autograft and instrumented by a locked plate. Three patients had soft-tissue components in the epidural space, necessitating dissection of the tumor from the dura. Posteriorly, the rest of the tumour was totally excised and lateral mass fixation performed when necessary.

Results: Patients were followed for 34 - 52 m. All patients showed improvement in their pain and neurological status. Follow up imaging studies showed cervical alignment was maintained, no tumor relapse and adequate bony healing.

Conclusion: Circumferential resection of aggressive osteoblastoma of the cervical spine is a demanding procedure. Nevertheless, total excision can be performed with adequate spinal reconstruction despite the occasional dural and vertebral artery involvement.



An 18y old female with the tumour at C3. (a) Preoperative (b) 3y follow-up

E-Poster #39

Short Term Mortality and its Association with Independent Risk Factors in Adult Spinal Deformity Surgery

Dhruv Pateder, MD (Steadman Hawkins Clinic Vail/Frisco Spine Surgery); Ricardo Gonzales, MD; Khaled Kebaish, MD; David B. Cohen, MD; John Kostuik, MD

Introduction: Several studies in the literature have examined the relationship between preoperative comorbidities and post-operative mortality. While there is a link between certain risk factors and post-operative mortality, increasing American Society of Anesthesiology (ASA) physical status class has been shown to be one of the best independent predictors of mortality in the general surgery literature. Although mortality after adult spinal surgery is reported to range from 0.03% to 3.52%, there is a general paucity of data on mortality and its associated risk factors after adult spinal deformity surgery.

Methods: 361 adults with spinal deformity underwent 407 corrective procedures. For patients who died within 30 days of the procedure, the following risk factors were examined to determine if each could independently predict mortality: demographic information, ASA classification, operative time, surgical approach, number of fusion levels, primary versus revision surgery, and intraoperative blood loss.

Results: Ten of the 407 procedures resulted in death (2.4% mortality): one intraoperatively secondary to cardiac ischemia, three secondary to sepsis/multiple organ failure, two each secondary to pulmonary embolus, uncal herniation/cerebral edema, and shock. The average preoperative ASA levels for patients who died and patients who survived were 3.0 and 2.3, respectively ($P < 0.0001$). Age, gender, operative time, surgical approach, number of fusion levels, revision status, and estimated blood loss did not have an independently significant correlation to mortality.

Conclusion: There was a strong association ($P < 0.0001$) between increasing ASA class and increasing mortality. The other risk factors could not independently predict postoperative mortality within 30 days after surgery.

Significance: This study demonstrated a significant correlation between increasing ASA class and increasing mortality after adult deformity spinal surgery. While accumulation of comorbidities no doubt increase the risk of post-operative complications and mortality (6-9), none except the ASA class had an independent correlation with mortality in this study. The ASA physical status score is one of the most effective independent factors in predicting post-operative mortality.

Table 3 ASA Class and Mortality Rate

ASA Class	Number of Patients	Number of Deaths	Mortality Rate (%)
1	1	0	0
2	233	2	0.86
3	143	6	4.2
4	3	2	66.7
5	0	N/A	N/A
6	0	N/A	N/A

E-Poster #40

Posterior Vertebral Column Resection and Stabilization using Titanium Mesh in Neurologic Compromised Thoracolumbar Osteoporotic Kyphosis

Jung-Hee Lee, MD (Kyung Hee University); Dae-Woo Hwang, MD; Ki-Tack Kim, MD; Kyung-Soo Suk, MD; Sang-Hun Lee, MD; Jin-Soo Kim, MD

Introduction: Single posterior surgery provides elderly with safer and less invasive surgery for neurologic compromised thoracolumbar osteoporotic kyphosis. Anterior column support is inevitable for solid arthrodesis to osteoporotic kyphosis.

Methods: Twenty-three patients with neurologic compromised thoracolumbar osteoporotic kyphosis underwent PVCR with posterior insertion of titanium mesh. Mean follow-up was 2.9 years (range 2.2-4.3). The results were analyzed including radiographic studies, neurologic status and complications.

Results: The mean kyphosis was 36.1° (range 26-52°) before surgery, 4.0° after surgery. Satisfactory correction was achieved in all patients with solid arthrodesis. The postoperative neurologic improvement using Frankel grades was demonstrated in all patients. There was no new onset or progressive neurologic deterioration, additional surgery or extrusion of mesh.

Conclusion: PVCR with posterior insertion of titanium mesh appear to hold promise for the neurologic compromised thoracolumbar osteoporotic kyphosis, and to maintain the length of anterior column with solid arthrodesis.

E-Poster #41

Should Post-Operative Pulmonary Function be a Criterion that Affects Upper Instrumented Vertebral Body Selection in AIS Surgery?

John Schlechter, DO (Rady Children's Hospital and Health Center); Peter O. Newton, MD; Vidyadhar V. Upasani, MD; Jeff B. Pawelek, BS; Randal R. Betz, MD; Lawrence G. Lenke, MD; Baron S. Lonner, MD; Alvin H. Crawford, MD; Harms Study Group

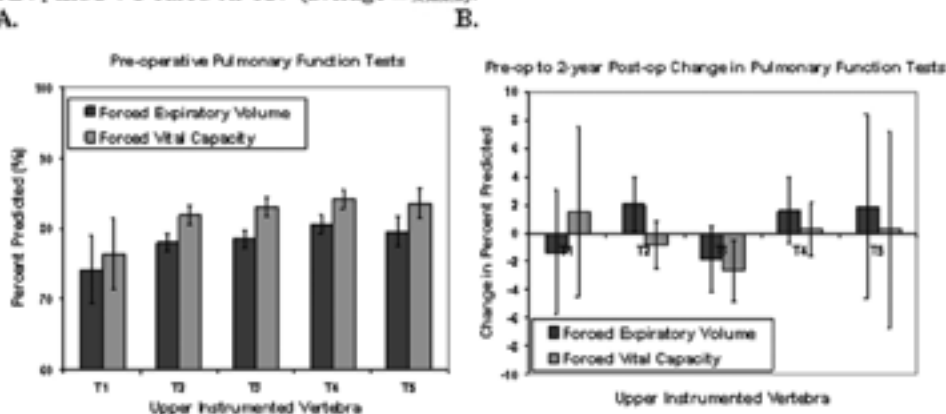
Introduction: Recent reports suggest limiting the proximal extent of a posterior spinal instrumentation and fusion (PSF) into the upper thoracic spine to optimize post-op pulmonary function in patients with AIS. The purpose of this study was to compare pre- and post-op PFT data to determine whether a more proximal upper instrumented vertebra (UIV) negatively impacts pulmonary function.

Methods: A multi-center AIS database was used to evaluate pre-op absolute and percent predicted pulmonary function data prior to a PSF, based on the selected UIV. For those patients with 2-year post-op PFT data, an ANOVA ($p < 0.05$) was used to compare the change in forced expiratory volume (FEV1) and forced vital capacity (FVC) from pre-op to post-op based on the UIV.

Results: 569 patients (434 females) with main thoracic curves (Lenke type 1-4) and a UIV from T1 to T5 were analyzed. The mean age at surgery was 15 ± 2 years, with a proximal thoracic Cobb of $28.6 \pm 11.1^\circ$ and a main thoracic Cobb of $57.2 \pm 14.5^\circ$. Pre-operatively, patients that eventually underwent fusion to more proximal levels had lower percent predicted PFTs ($p < 0.01$; Fig 1A). However, the changes in percent predicted FEV1 and FVC between the pre-op and 2-year follow-up time points (116 patients) were not significantly affected by the chosen UIV ($p > 0.76$; Fig 1B).

Conclusion: Although patients who require fusion more proximally into the thoracic spine seem to have lower PFTs, this exists pre-operatively and is not altered by surgery. There is no justification for limiting the proximal extent of surgery based on concerns of reducing pulmonary function in AIS. Choosing the most appropriate level of fusion in AIS requires a careful analysis of the risks and benefits for the patient in both the long and short term. There is no evidence that concern of limiting pulmonary function should enter into the decision making process when selecting the UIV in AIS.

Figure 1: A) Pre-op percent predicted FEV₁ and FVC based on UIV B) 2-yr post-op changes in FEV₁ and FVC based on UIV (average \pm SEM).



E-Poster #42

Sagittal Balance Correction Assessed with the C7 and Pelvic Tilts in 35 Patients Undergoing Transpedicular Osteotomy for Severe Sagittal Imbalance

Sebastien Charosky, MD (Institut Calot); Ian J. Harding, BA, FRCS (Orth); Raphael Vialle, MD, PhD; Eric Berthonnaud, PhD; Pierre Roussouly, MD; Daniel Chopin, MD

Introduction: The normal sagittal alignment using two angular parameters in the sagittal plane has already been described in a previous report. The objectives of this study were to characterize different types of sagittal imbalance according to these angular parameters and to evaluate the results of a corrective procedure in a cohort of patients operated for sagittal imbalance

Methods: The pre and post op x-rays of 35 patients undergoing transpedicular osteotomy with posterior instrumentation and fusion for severe sagittal imbalance were measured by two of the authors. Pelvic incidence, pelvic tilt, sacral slope, lumbar lordosis, C7 tilt and C7 plumb line were measured. A new classification of sagittal imbalance was designed using the two parameters previously described to define normal sagittal alignment: the C7 and pelvic tilts. A retrospective descriptive study was performed to evaluate the surgical correction comparing it to the normal standards

Results: The mean pre-op/post-op values were: pelvic tilt: 34°/22.4°; C7 tilt: 1.6° /-4.2°; C7 plumb line: 94.7mm/23.6mm respectively. The theoretical ideal pelvic tilt was calculated from the pelvic incidence. With these values we were able to describe 4 different types of sagittal balance. The pre and post-op x-rays were classified according to these 4 types (Table 1) The classification allowed differentiating patients with a normal post-op sagittal balance (type 1: normal trunk and pelvic balance) from those with an insufficient correction and a compensated imbalance (type 2: balanced trunk with pelvic compensation) although the C7 plumb line was within normal ranges (type 2 post op C7 plumb line: 24mm SD 26mm)

Conclusion: This new classification allows a better description of sagittal alignment differentiating patients with a C7 plumb line considered normal but with a compensation at the pelvic level (compensated imbalance) from those with normal alignment in the sagittal plane. This classification is a useful tool in the assessment of sagittal alignment.

Type	C7 tilt	Pelvic Tilt	Balance	N Patients Pre-operative	N Patients Post-op
1	≤ 0°	Pt = ThPt ± SD	Normal	0	11
2	≤ 0°	Pt > ThPt ± SD	Compensated imbalance	17	22
3	> 0°	Pt = ThPt ± SD	Trunk imbalance without pelvic compensation	2	0
4	> 0°	Pt > ThPt ± SD	Global sagittal imbalance	16	2

(Pt: pelvic tilt; ThPT: theoretical pelvic tilt; SD: standard deviation)



E-Poster #43

*The Analgesic Effect of Epidural Clonidine Following Spinal Surgery: A Randomised Placebo Controlled Trial

James Wilson-MacDonald, MB, CHB, FRCS, MCH (University of Oxford); Andrew D. Farmery, MD, FRCA

Introduction: Epidural anaesthesia is widely used for postoperative pain relief. Clonidine is an alpha2 adrenoreceptor and imidazoline receptor agonist which has analgesic, sedative and MAC sparing effects. We assessed its use epidurally.

Methods: 66 patients were recruited and received a standardized general anaesthetic. At the end of surgery group C received a bolus of 1.5 mcg/kg of epidural clonidine followed by an infusion of 25 mcg/h for 36 to 48 hours. Patients in group P received a similar bolus and infusion of saline. Verbal pain scores, morphine consumption by patient-controlled device (PCA), sedation score, haemodynamic variables and the incidence of PONV were recorded for up to 48 hours.

Results: Although the study was designed to minimise differences in pain perception, small but significant differences in pain score were observed in the first 6 postoperative hours. Thereafter pain scores were mostly low and without significant difference. The cumulative Morphine consumption delivered by the PCA device in the postoperative period was 61 (SEM 7) mg in the placebo group and 35 (SEM 7) mg in the clonidine group at 48 hours. The proportional reduction was similar at all time points. There was a small difference in pulse rate and systolic pressure between the groups.

Conclusion: This study has demonstrated that clonidine infused epidurally reduces postoperative analgesic requirement and reduces pain intensity in the early postoperative period.

Significance: Epidural morphine has a very satisfactory postoperative analgaesic effect when used in conjunction with intravenous morphine, and it reduces the demand for morphine delivered in a PCA. Epidural clonidine is probably more effective than intravenous clonidine, and reduces the side effects of intravenous morphine. The side effects are minimal and we can recommend this technique for postoperative pain control in spinal surgery.

E-Poster #44

Incidence and Risk Factors of Neurological Deficits of Correction For Deformities : Analysis of 3311 Patients in France

Prof. Pierre Guigui; Arnaud Blamoutier, MD; Norbert Passuti, MD (Groupe d'étude de la Scoliose Francais);

Introduction: This is a prospective multicentric observationnal study done to assess the incidence of intra-and postoperative complications and indentify favoring factors

Methods: We included 3311 patients who underwent surgery during a 12 months period for deformations in 15 centers in france , defined as idiopathic or secondary scoliosis or kyphosis , pre and intraoperative variables recorded were: epidemiological and morphological data, history of surgery for the same deformation, comorbid conditions, type of deformation treated (nature , localization, severity, reducibility) type of surgery performed (approach , duration of operation, extend and localization of the fusion, associated neurologic release, osteotomies or not, type of graft)

Results: Mean age of the cohort was 27+or- 18 years , isolated posterior approach was used for 72,5% an isolated anterior approach for 6,4% and a combined anteroposterior approach for 21,1%, the incidence of neurologic complications was 1,8 % (30 cases of medullar coplications and 24 cases of radicular problems).Some factors were not correlated with neurologic deficit : age, ASA score, inferior limit of fusion , surgical revision , surgical decompression of neural elements. The incidence was correlated with these factors : the type of deformation (2,1% for kyphosis versus 0,8 % for scoliosis p= 0,0024) localization of the deformation (2 % for combined curves versus 1,7 % for thoracic curves and 0,4 % for TH-L curves p = 0,009) , the angulation (78° versus 57 ° p= 0,001) type of approach (2,6% for combined approach versus 0,5 % for posterior approach and 0,1% for anterior instrumentation p= 0,001) use of osteotomy (2,4% versus 0;8 % without any osteotomy p= 0,0001).

Conclusion: In surgical correction of scoliosis the risk factors for neurological deficits include severity of angulation, the use of one or several osteotomies, combined approach, the general incidence was 1,8 % and that of serious and mild was 0,4 % and 1,4 % respectively.

Significance: This multicentric prospective study confirms the usual and known incidence of neurologic complications and define precisely some significant factors.



E-Poster #45

Analysis of Global Sagittal Balance using Cranial Center of Mass as a Reference Point

Tyler Koski, MD (Northwestern University); Fadi Nasr, MD; Brian A. O'Shaughnessy, MD; Stephen L. Ondra, MD

Introduction: Global sagittal balance is a fundamental component of spinal biomechanics and plays a major role in operative planning. A traditional C7 plumb line has been shown to reliably fall behind the center of gravity line for the body. The relationship of the cranial center of mass (COM) in "global" sagittal balance is a poorly studied concept.

Methods: 100 healthy volunteers were recruited for this study. Inclusion criteria were: age 20-40; no back pain, previous spinal surgery, or neurologic complaints. 76 patients had appropriate standing lateral 36' x-rays completed and were included in the analysis. The COM was estimated by using the center of a line drawn from the nasion to the inion. This is a validated measure for head COM. A plumb line was dropped from the COM and compared to a C2 and a C7 plumb line in reference to the posterior superior aspect of the sacrum.

Results: The cranial COM reliably falls anterior to both C2 and C7 more congruent with the published position of global center of gravity. The mean \pm SD (mm) results were 9.6 ± 31 for COM, -2.3 ± 33 for C2, and -16 ± 32 for C7. The 95% confidence intervals (mm) were 2.5 to 16.7, -9.7 to 5.0, and -8.9 to -23.2 respectively. The correlation coefficients were .93 for C2:C7, and .83 for COM:C7.

Conclusion: Global spinal balance is an evolving concept. Spinal pelvic alignment as well as center of gravity studies have increased our understanding of normal balance. We have added an important parameter of global balance by incorporating center of mass of the head into the equation. Center of mass is easily estimated by using the nasion inion technique. It is more closely correlated with the published values for global center of gravity than the traditional C7 plumb line.

Significance: COM may prove to be an important reference point when determining the amount of correction necessary to appropriately rebalance a pathologic spine.

E-Poster #46

BMI is Changing in Children and Adolescents Presenting for Scoliosis Surgery - The Prospective Pediatric Scoliosis Study Database

Daniel J. Sucato, MD, MS (Texas Scottish Rite Hospital for Children); John P. Lubicky, MD; John F. Sarwark, MD; Spinal Deformity Study Group

Introduction: In pediatric age groups, the incidence of overweight children doubled between 1976-1980 and 1999-2002 (Hedlet et al, JAMA 2004) and associated conditions have tripled. The purpose of this study was to determine changes in BMI of patients undergoing AIS surgery during two different time periods of the past two decades. BMI may have some influence on surgical parameters and complications.

Methods: A multi-center review was conducted of two existing AIS surgical databases, from 1993-2000 and 2002-2007. The IRB approved databases were reviewed and a demographic comparison of two groups of AIS patients over a 2 decade period with appropriate statistical analysis was made.

Results: The early group (1993-1998) consisted of 358 patients while the recent group (2002-2003) had 1958. Females in the early group had a lower BMI compared to the recent female group (20.0 vs 21.1 cm/kg²) (p=0.0001) but BMI was similar in males (20.7 vs 21.5 cm/kg²) (P=0.3). A normal BMI category was most common at both time periods but is comparatively less in the recent group (76.8 vs 71.9%) (p=0.05). A significant trend toward a greater number of children and adolescents who are in the overweight category was seen (5.3 vs 10.1%) (Table). The posterior surgical time was greatest in the overweight patients.

Conclusion: The most common BMI for AIS patients presenting for surgery continues to be normal. Overall, the recent group BMI is significantly higher than the early group and there is a significant trend toward greater number of patients who fall into the overweight category. The incidence of overweight AIS patients is increasing and as this trend continues it may impact their treatment and ultimate outcome.

Significance: This study demonstrates that BMI for those patients undergoing surgical treatment for AIS is increasing with a greater incidence of overweight patients which resulted in greater posterior surgical time. This trend toward larger patients may impact our surgical treatment and ultimately outcome and risk for complications.

Body Mass Index Categories, Comparing Patients Enrolled 1992-2000 to those enrolled in 2002 and Later

	Early		Recent		Total		P
	#	%	#	%	#	%	
Underweight	24	6.7%	110	5.6%	134	5.8%	0.42
Normal	275	76.8%	1407	71.9%	1682	72.6%	0.053
At Risk for Overweight	40	11.2%	243	12.4%	283	12.2%	0.51
Overweight	19	5.3%	198	10.1%	217	9.4%	0.004
Total	358	100.0%	1958	100.0%	2316	100.0%	



E-Poster #47

***TLIF as an Alternative to Formal Anterior Interbody Fusion at the Caudal End of Long Spinal Deformity Constructs: Does it Work?**

Patrick T. O'Leary, MD (Washington University); Lawrence G. Lenke, MD; Christopher R. Good, MD; Mark Pichelmann, MD; Kathryn A. Keeler, MD; Keith H. Bridwell, MD; Brenda A. Sides, MA

Introduction: Transforaminal lumbar interbody fusion (TLIF) has been used extensively in the treatment of degenerative spinal disorders. However, TLIF has not been reported in spinal deformity treatment. We hypothesized that at the caudal end of deformity constructs, TLIF would result in similar fusion rates, maintenance of local lordosis, similar outcomes, and shorter hospital stay compared to formal anterior lumbar interbody fusion (ALIF).

Methods: The senior author has utilized TLIF (TLIF group) in order to obtain structural interbody fusion at the caudal aspect of long deformity constructs (thoracic to L5 or S1). 17 patients had minimum 2-year clinical/radiographic follow-up. A matched cohort of 17 patients who underwent staged formal ALIF (ALIF group) following posterior spinal instrumentation and fusion for deformity. Diagnoses included double major scoliosis (TLIF n=7, ALIF n=8), lumbar scoliosis (n=6; n=5), congenital scoliosis (n=1; n=1), and distal transition syndrome following prior fusion for idiopathic scoliosis (n=3; n=3). Radiographic analysis included local lordosis at interbody levels, overall lumbar lordosis, and A/P fusion grade, as graded by three independent observers.

Results: 17 patients had a total of 24 TLIFs (11-L5/S1, 12-L4/5, 1-L3/4); 17 patients in the matched cohort had a total of 40 ALIFs (15-L5/S1, 15-L4/5, 10-L3/4); all utilized structural cages. Rh-BMP2 (12mg/level) was used in 14/17 TLIFs and 15/17 ALIFs. Age, preop AP lumbar curve, and lumbar lordosis were similar between groups (Table 1). Average operative time for TLIF group was 499 minutes vs 628 for the combined posterior and anterior surgeries in the ALIF group (p=.004). Length of stay was significantly shorter in the TLIF group (7.6 days) vs ALIF (13.5 days) (p<0.0001). Interbody fusion rates were similar between groups with no cases of cage, screw, or rod implant failure at the interbody levels in either group.

Conclusion: TLIF resulted in maintenance of local intervertebral lordosis, similar fusion rates, and similar improvement in Oswestry scores compared to a matched cohort of ALIF patients. Operative times and length of stay were significantly reduced in the TLIF group.

(See table next page)

Table I

	TLIF	ALIF	p value†
Age at Surgery	49.7±13.1	53.3±6.6	0.32
Avg F/U (mos)	30 (24-50)	30 (24-47)	
AP Lumbar Cobb Preop (°)	51.3±18.7	49.3±16.3	0.74
# levels fused	11.2±4.2	10.6±3.3	0.62
Sag C7 plumbline (mm)			
Preop	17.4±50.9	23.2±46.7	0.73
Postop	7.1±35.3	1.6±35.6	0.65
Lordosis (°)			
T12-S1 Preop	-40.9±20.1	-42.6±22.5	0.82
T12-S1 Postop (2yrs)	-54.0±11.1	-50.5±15.7	0.46
Operative Time (min)	498.9±132.1	627.8±107.4	0.004
Estimated Blood Loss (ml)	1576±722	1057±649	0.03
Length of Stay (days)	7.6±1.8	13.5±1.9	<0.0001
Local Lordosis L5/S1 (°)			
Preop	(n=11) -15.6±5.6	(n=15) -12.7±4.65	0.19
Postop (2yrs)	-17.0±4.4	-12.6±2.4	0.01
p value*	0.58	0.95	
Local Lordosis L4/5 (°)			
Preop	(n=12) -6.3±6.6	(n=15) -8.7±5.0	0.30
Postop (2 yrs)	-6.1±2.9	-8.6±3.1	0.04
p value*	0.92	0.97	
Anterior Fusion Grade+			
L5/S1	1.16 (n=11)	1.04 (n=15)	
L4/5	1.23 (n=12)	1.00 (n=15)	
L3/4	1.00 (n=1)	1.03 (n=10)	
Posterior Fusion Grade+			
L5/S1	1.00 (n=11)	1.07 (n=15)	
L4/5	1.08 (n=12)	1.07 (n=15)	
L3/4	1.00 (n=1)	1.06 (n=10)	
Oswestry Disability Index (% of 100)			
Preop	46.2±18.8	33.5±17.6	0.05
Postop	32.6±21.8	22.3±18.6	0.19
p value*	0.03	0.009	
Scoliosis Research Society Outcomes (subscore)			
Preop	3.02±0.57	3.11±0.50	0.64
Postop (2 yrs)	3.59±0.55	3.75±0.62	0.50
p value*	0.002	0.0001	

†p-value compared by unpaired t-test

*p-values tests for change within group by paired t-test

+Fusion grade by three independent observers on scale: 1-definite, 2-probable, 3-probably not, 4-not fused



E-Poster #48

***Safety and Efficacy of Bone Morphogenetic Protein (rhBMP-2) in Complex Pediatric Spinal Deformity at a Minimum Two Year Follow-Up**

Daniel S. Mulconrey, MD (Washington University); Kathryn A. Keeler, MD; Lawrence G. Lenke, MD; Keith H. Bridwell, MD; Christopher R. Good, MD; Patrick T. O'Leary, MD; Mark Pichelmann, MD; Brenda A. Sides, MA

Introduction: Multiple studies have been performed evaluating the use of rhBMP-2 in adult spinal surgery, but no study has addressed the safety and efficacy of rhBMP-2 in pediatric spinal deformity patients.

Methods: Retrospective radiographic analysis was performed on 49 patients (301 fusion levels) less than age 18 (mean 13.1 yrs), who underwent ASF (n=4) or PSF (n=261) spinal fusion with BMP at a minimum 2 yr F/U (mean 2.6 yrs, range 2 to 4.4 yrs). The preoperative diagnoses were: neuromuscular scoliosis (20); hyperkyphosis (13); congenital scoliosis (3); congenital dislocation (2), basilar invagination (1) or high grade (IV/V) spondylolisthesis (10). 29 patients had primary fusions and 20 patients underwent revision surgery for pseudarthrosis. The mean dose of rhBMP-2 was 5.4 mg/level (5.4 mg PSF, 5.1 mg ASF). Mean number of levels in which BMP was applied was 5.1 (2.8 ASF, 5.9 PSF). 22 patients had iliac crest bone graft and 19 patients had fresh frozen allograft included in the fusion material. ASF procedures included BMP on an absorbable collagen sponge (ACS), with an ACS or Tricalcium phosphate/Hydroxapatite used for the PSF procedures. Local bone graft if available was added to the fusion. Postoperative films (AP, Lateral, Oblique) at latest follow-up were evaluated by 3 independent observers and the average fusion grade was recorded (Grade 1- definite fusion, 2-probable, 3-unlikely, 4-not fused, Mean grade < 2 : solid fusion).

Results: With these strict criteria, the overall fusion rate was 96%. One infection occurred (2.2%), which resolved after surgical I&D and retention of the implants. No other complications were noted. No patient required any other type of revision surgery and no instrumentation failure developed. The number of levels fused, presence of pre-operative pseudarthrosis, diagnosis or presence of ICBG did not affect the fusion rate (p>0.05)

Conclusion: RhBMP-2 is safe and effective for spinal fusion in the complex pediatric deformity patient. The absence of ICBG does not affect the ability of BMP to promote a solid fusion. A lesser amount of BMP (5.4mg/level) is necessary to develop a posterior spine fusion in the pediatric population when compared to the reported adult concentrations (20mg/level).

E-Poster #49

Complications of Surgical Treatment of Spinal Deformities: A Prospective Multicentric Study of 3311 Patients

Norbert Passuti, MD (Groupe D'étude de la Scoliose Francais); Prof. Pierre Guigui, Arnaud Blamoutier, MD

Introduction: The purpose of this prospective multicentric study was to assess the incidence of intra-and postoperative complications secondary to this type of surgery to detail the complications and to identify favoring factors.

Methods: For this study we included 3311 patients who underwent surgery during a 12 month period for spinal deformation, defined as idiopathic or secondary scoliosis or kyphosis, irrespective of the localization, severity or type of surgery performed (15 french centers were involved in this study). Four main categories of complications were studied: general, infectious, neurological and mechanical: epidemiological and morphological data, history of surgery for the same spinal deformation, comorbid conditions, type of deformation treated (nature, localization, severity) type of surgery performed (approach, duration of the operation), extent of the fusion, associated neurological release, vertebral osteotomy or not. The analysis was a descriptive analysis to detail the overall incidence of complications and the incidence of each of the four main categories.

Results: Mean age of the cohort was 27, the deformation was scoliosis in 90% and kyphosis in 10%. An isolated posterior approach was used for 72,5% of patients, an isolated anterior approach for 6,4% and a combined anteroposterior approach for 21,1%. 704 patients (21,3%) had one or more complications. The incidence of general, infectious, mechanical and neurologic complications were: 5,7%; 4,7%; 11,5%; and 1,8% respectively. The following factors were found to be significantly associated with complications occurrence: patient age, ASA score, extent of the fusion, presence of vertebral osteotomy, inclusion of the sacrum in the fusion, and initial angle of the treated deformation.

Conclusion: This work enabled us to determine the overall rate of complications after surgery of spinal deformations. Risk factors related with complication occurrence were identified this study should be used to better inform patients and their family about the risks of this type of surgery.

Significance: This prospective study could be very helpful to define some specific risk factors of surgical strategies for correction of scoliosis or kyphosis.

E-Poster #50

***Transforaminal Lumbar Interbody Fusion (TLIF) in the Treatment of Pediatric and Adult Spinal Deformity**

Katsumi Harimaya, MD; Takuya Mishiro, PhD, MD; Patrick T. O'Leary, MD; Lawrence G. Lenke, MD (Washington University); Keith H. Bridwell, MD; Linda Koester; Brenda A. Sides, MA

Introduction: We evaluated the clinical and radiographic results of transforaminal lumbar interbody fusion (TLIF) as an alternative technique in the treatment of spinal deformity.

Methods: Clinical and radiographic data of 32 patients (18 females, 14 males; ave. age 45.4 yrs) with a minimum 2-year follow-up (ave. 40.4 mos) who underwent TLIFs for the treatment of spinal deformity were analyzed. There were 16 patients with isthmic spondylolisthesis (1=L3; 6=L4; 8=L5; 1=L6), 10 scolioses, 4 fixed sagittal imbalance syndromes (FSI), and 2 other diagnoses. 5 patients with adult lumbar scoliosis and 3 with FSI underwent TLIFs at the most caudal levels (7=1 level, 1=3 levels) in long spinal fusions (ave. 7.9 segments, range 6-13). A complete unilateral facetectomy was performed with placement of an appropriate height titanium or PEEK structural interbody cage. All patients had local autograft placed anterior to the cage, and 11 (34%) had collagen sponges with BMP-2. To assess fusion status, AP and lateral radiographs were reviewed by 3 spinal surgeons not involved in the surgical treatment.

Results: Pre to postop segmental disc angles (-3.6 to -7.8°) and Cobb angles (-11.9 to -16.8°) in the sagittal plane at the TLIF levels showed significantly increased lordosis (p<0.05). In isthmic spondylolisthesis patients, postop %slip at ultimate follow-up (16.9%, n=16) was significantly corrected from the preop value of 35% (p<0.001). Segmental disc angles at the TLIF levels in the long spinal fusion group were maintained at ultimate follow-up (preop -10.4°; ultimate follow-up -10.9°). Radiographs showed solid fusions at 33 levels (97.1%) at ultimate follow-up without implant failure at any of the TLIF levels. There were 3 transient partial foot drops in high-grade isthmic spondylolisthesis patients due to instrumented partial reduction and 1 deep wound infection.

Conclusion: For the treatment of spinal deformity, TLIFs can achieve an enhanced segmental lordotic disc angle, a significant reduction in isthmic spondylolisthesis, maintenance of segmental lordosis when performed below long deformity constructs, and a high anterior arthrodesis rate without significant complications.

Radiographic Results of TLIF Procedure in Spinal Deformity Patients

	Preoperative	Ultimate	P value
Segmental angle in all patients			
Disc angle (°)	-3.6	-7.8	p<0.05
Cobb angle (°)	-11.9	-16.8	p<0.05
%Slip in isthmic spondylolisthesis	35.0	16.9	p<0.01

* The FDA has not cleared a drug and/or medical device in use described in this presentation (i.e., the drug or medical device is being discussed in an off-label use). For full information see page 10.

E-Poster #51

Evaluation of Risk Factors for Infection Following Sacral Tumor Resection

Daniel M. Sciubba, MD (Johns Hopkins University); Selim Ayhan, MD; Clarke Nelson, BS; Beril Gok, MD; Jean-Paul Wolinsky, MD; Ziya L. Gokaslan, MD

Introduction: Surgical treatment for sacral tumors has been shown to improve survival since oncologic prognosis is commonly correlated with extent of local tumor control. However, extensive soft tissue resection in close proximity to the rectum may predispose patients to infection. Review of sacral tumor resections over the last five years at a single institution was completed, paying special attention to procedure-related complications.

Methods: Between 2002 and 2007, 47 patients with sacral tumors were treated with surgery. Demographic data, details of surgery, type of tumor, and patient characteristics associated with surgical site infections were collected including presence of diabetes, obesity, smoking, steroid use, previous surgery, previous radiation, cerebrospinal fluid leak, number of spinal levels exposed, instrumentation, albumin level, and combined anterior-posterior approaches. Univariate analysis was implemented to find association of such variables with presence of wound infection.

Results: A total of 47 patients were treated for sacral tumor resections, 21 male and 26 female with an average age of 46 years (11-83 years). Histopathologies included: chordoma in 19, ependymoma in 6, rectal adenocarcinoma in 5, giant cell tumor (GCT) in 4 and other in 13. There were 18 cases of wound infection (38%), and 2 cases of repeat surgery for tumor recurrence (one chordoma, one GCT). Independent predictors for increased likelihood of infection included increasing previous lumbo-sacral surgery (p value = 0.02), plastics closure (p=0.9; odds ratio=3.79), and age (p value=0.08).

Conclusion: Patients undergoing sacral tumor surgery may be at greater risk for developing wound complications due to extensive soft tissue resection, especially with potential for contamination from the neighboring rectum. In this study, it appears that previous lumbo-sacral surgery, age, and extensive soft tissue destruction may predict patients prone to developing postoperative wound complications. Interestingly, albumin level and bowel/bladder dysfunction were not associated with infection.

Significance: History of previous surgery, increasing age, and extensive soft tissue destruction may predict patients more likely to develop post operative infections following sacral tumor resection.



E-Poster #52

Structures at Risk from Pedicle Screws in the Proximal Thoracic Spine: Computed Tomographic Evaluation with Magnetic Resonance Imaging Correlation

Mario J. Cardoso, MD, DC (Walter Reed Army Medical Center); Ronald A. Lehman, Jr., MD; Michael Rosner, MD; Richard P. Moser, III, MD; Norman Gill; Melvin D. Helgeson, MD; Lawrence G. Lenke, MD

Introduction: Optimal fixation in the proximal thoracic spine may include bicortical pedicle screw fixation. An understanding of the potential structures at risk is paramount to safe screw placement.

Methods: Computed tomography was performed on 20 patients (16 male, 4 female), with an average age of 31.2 years (range 18-49 years). All images were analyzed from T1-4 for proximity of major structures at risk from "optimal" pedicle screw placement and position (Fig 1). Five patients also had MRIs and Pearson's r was used to correlate MRI with CT. Descriptive statistics, ANOVAs and post-hoc paired t-tests were used to analyze screw position relative to the esophagus, trachea, aortic arch, carotid and vertebral arteries using an alpha=0.05.

Results: Eighty potential anterior cortical violation positions were analyzed in 20 patients. Correlation between CT and MRI demonstrated a significant ($p < 0.01$) and high positive correlation (Pearson's $r = 0.90$). Left-sided pedicle screws posed a significantly higher risk ($p < 0.05$) to the esophagus (avg. 3.2 ± 2.5 SD mm, range 1-13.6 mm, 95% CI of 2.7-3.7 mm) at T1-T3; in particular the left T2 screw was significantly closer ($p < 0.05$). Right-sided pedicle screws posed a significantly higher risk ($p < 0.05$) to the trachea (avg. 9.4 ± 4.6 SD mm, range 1-28.2 mm, 95% CI 8.4-10.4 mm) at T2-T4; in particular the right T3 screw was significantly closer ($p < 0.05$). The right carotid artery was closest at T3 (9.9 mm). The left vertebral artery was closest at T2 (avg. 11.5 ± 2.6 SD mm). The aortic arch was present at T4 in 70% and was not at risk (avg. 8.4 ± 5.1 SD mm, range 2.5-17.4 mm, 95% CI 5.7-11.1 mm).

Conclusion: Careful preoperative evaluation with CT or MRI is warranted to determine anatomic structures at risk when placing proximal thoracic pedicle screws. Left-sided screws, especially at T2, pose the greatest risk to the esophagus; right-sided screws, especially at T3, pose the greatest risk to the trachea. The carotid and vertebral arteries, along with the aortic arch appear to be at minimal risk. Computed tomography and MRI were highly correlative for detection of potential structures at risk.

Significance: Bicortical fixation in the proximal thoracic spine is probably not warranted as the trachea and esophagus are draped over the anterior vertebral body.

E-Poster #53

The Effect of Multimodality Methods on Transfusion Requirements in Pediatric Spinal Surgery

Stephen Lewis, MD, FRCSC, MSc (Sick Kids); Janet Ahier, APN; Sarah Bacon; Marc Crawford; Christian E. Zaarour, MD

Introduction: The purpose of this study was to determine factors that predict children at increased risk of blood loss during elective spinal surgery and determine methods of blood conservation strategies that reduce the need for non-autologous transfusions.

Methods: The charts of one surgeon's patients 4-18 years of age undergoing posterior instrumentation and fusion for correction of spinal deformity from 2005-2007 were reviewed. 69 patients were divided into 3 sub-groups: Group A-Idiopathic scoliosis, Group B-Neuromuscular scoliosis, and Group C-other. Consistent anaesthesia was maintained. Oral administration of iron was recommended to all patients. Pre-operatively, patients were offered autologous blood donation (ABD), directed donation (DD), and erythropoietin. Data collected included patient's weight, co-morbidity, type of surgery, instrumentation levels, duration of surgery, use of tranexamic acid, ferritin levels, estimated blood loss, cell saver (CS), hemovac drainage and pre-op and day 1 hemoglobin were recorded

Results: All patients were provided prescriptions for pre-operative iron. Tranexamic acid was used on 67/69 (97%) patients. Group A: 41/44 (93%) required no blood transfusion during or after surgery. 19/44(43%) received erythropoietin pre-op. 6/44(13%) received intra-op CS. 3/44 (6.9%) received 1unit of ABD post-op, all 3 had a thoracoplasty(3/8), 2/3 had erythropoietin preop. 1/44 received 1 unit DD blood. Group B: 7/12(58%) received allogeneic transfusions. 8/12(67%) received CS. 1/12(8%) received erythropoietin (1unit) pre-op. Group C: 5/13(38%) received CS, 4/13(30%) had allogeneic transfusions, 3/13(23%) received no blood product, 6/13(46%) had erythropoietin pre-op.

Conclusion: In this series AIS patients not undergoing thoracoplasty did not require blood products. Erythropoietin did not affect the need for blood products. Neuromuscular patients and those undergoing osteotomies had a higher incidence of requiring blood products.

Significance: We therefore recommend use of aggressive peri-operative blood conservation strategies in AIS patients undergoing thoracoplasty and in neuromuscular and osteotomy patients. Erythropoietin did not reduce need for transfusions in these patients.



E-Poster #54

Five-Fold Increased Risk of Pseudoarthrosis or Delayed Infection Following Early Wound Infection in the Neuromuscular Scoliosis Patient

Burt Yaszay, MD (Rady's Children's Hospital); Jeff B. Pawelek, BS; Shunji Tsutsui, MD; Tracey P. Bastrom, MA; Peter O. Newton, MD

Introduction: Compared to adolescent idiopathic scoliosis, patients treated for NM scoliosis have an increased rate of wound infection. It has been suggested this increases the risk of developing a pseudoarthrosis or delayed infection. The purpose of this study was to determine the rate of pseudoarthrosis and/or delayed infection following an early wound infection in NM patients treated at a single institution.

Methods: A retrospective review of surgically treated patients with NM deformity with a minimum of 2 years follow-up was performed at a single institution. The charts were reviewed for evidence of acute (<30 days post-op) or delayed wound infection. Data regarding symptomatic pseudoarthrosis requiring reoperation was also collected. Chi-squared ($p < 0.05$) was used to compare patients with an early infection to the non-infected patients with regard to late pseudoarthrosis and delayed infection.

Results: 115 patients with an average age of 13.6 years and follow-up of 4.2 years were analyzed. There were 13 early post-op wound infections (11%). 9 were considered deep and treated with IV and oral antibiotics. 4 were superficial and treated with oral antibiotics alone. 11 of the 13 patients required surgical drainage. Two of the 9 early deep infections developed a pseudoarthrosis compared with three of the 102 non-infected patients (15.4% vs. 2.9%, $p = 0.04$). The average time to reoperation for pseudoarthrosis repair was sooner for the infected group (42 vs 85 months, $p = 0.29$). There were no active infections at the time of reoperation. Two patients with an early infection developed a delayed deep infection, while none of the initially non-infected group developed a delayed infection ($p < 0.001$). Both infections were initially superficial and treated with oral antibiotics alone.

Conclusion: NM scoliosis patients with an early wound infection are at significantly elevated risk (~5 times greater) of developing pseudoarthrosis and/or delayed infection.

E-Poster #55

Effect of Melatonin on the Proliferative Response of Chondrocytes in Adolescent Idiopathic Scoliosis

Wei Jun Wang, MPHIL; Hiu Yan Yeung, PhD; Chi Wai Gene Man; Kwong Man Lee, PhD; Bobby KW Ng, MD (The Chinese University of Hong Kong); Yong Qiu, MD; Jack Chun Yiu Cheng

Introduction: Abnormal endochondral ossification and melatonin signal pathway dysfunction has been observed in AIS girls. MT2 receptor gene was also found to be associated with AIS occurrence.

Methods: Chondrocytes from 8 AIS and 6 controls were released and cultured. MT1 and MT2 receptor expression were detected by immunocytochemistry. Sub-confluence chondrocytes were treated with different concentrations of melatonin before the cell viability was detected.

Results: Both MT1 and MT2 receptors were detected on the cell membrane of the chondrocytes in AIS and control. Significant inhibition effect on chondrocyte proliferation by melatonin was found in normal controls but not in AIS girls.

Conclusion: Both MT1 and MT2 receptors were detected on the cell membrane of the chondrocytes in AIS and control. Significant inhibition effect on chondrocyte proliferation by melatonin was found in normal controls but not in AIS girls.

Significance: The effect of non-responsiveness of the chondrocytes to melatonin might play an important role in the abnormal bone growth and etiopathogenesis of in AIS patients.



E-Poster #56

Pediatric Cervical Kyphosis: A Comparison of Arthrodesis Techniques

Jeffrey E. Martus, MD (Texas Scottish Rite Hospital); Terri E. Griffith, BS; Jameson C. Dear, BBA; Karl E. Rathjen, MD

Introduction: Retrospective review of 24 pediatric patients treated for cervical kyphosis with posterior spinal fusion (PSF), anterior spinal fusion with strut graft (ASF), or circumferential fusion with strut graft (A/PSF).

Methods: Group I: 9 patients with a non-syndromic diagnosis (8 post-laminectomy, 1 post-traumatic). Group II: 15 patients with a syndromic diagnosis (9 Larsen's syndrome, 2 neurofibromatosis, 1 Gorham's disease, 2 Conradi syndrome, 1 diastrophic dysplasia). Arthrodesis techniques: Group I = 2 PSF, 2 ASF, 5 A/PSF, Group II = 11 PSF, 0 ASF, 4 A/PSF. Mean age: Group I = 10.9 yrs, Group II = 4.5 yrs. Mean kyphosis: Group I = 55°, Group II = 67°. Preop myelopathy: Group I = 4/9, Group II = 5/15. Mean follow-up: Group I = 3.7 yrs, Group II = 7.7 yrs.

Results: Mean kyphosis correction was 55% (55° to 25°) in Group I and 39% (67° to 41°) in Group II. Resolved myelopathy: Group I = 3/4, Group II = 1/5. Late myelopathy with transient quadriparesis: Group I = 0, Group II = 2. Primary union: Group I = 9/9, Group II = 9/15 (5 pseudarthrosis, 1 early loss of fixation). Major complications: Group I (none), Group II - deep infection (2), strut fracture (1), strut displacement (3), pseudarthrosis (5), loss of fixation (1), reoperation (8). Among syndromic patients (Group II) treated with primary PSF (11 pts), mean postoperative residual kyphosis was 32° in 7 patients that achieved primary union and 77° in 4 patients with eventual pseudarthrosis requiring reoperation (p=0.022); 2 of 4 with pseudarthrosis developed late myelopathy with an episode of transient quadriparesis. Primary union was achieved in 3 of 4 syndromic patients with circumferential arthrodesis; pseudarthrosis occurred in the patient with Gorham's disease.

Conclusion: Arthrodesis was effective without major complications in non-syndromic kyphosis. Complications were frequent in syndromic kyphosis. There was a significant association of greater residual kyphosis with pseudarthrosis in syndromic patients treated with PSF.

Significance: Circumferential arthrodesis with strut grafting may decrease pseudarthrosis risk in syndromic patients with severe, rigid kyphosis. PSF alone may be sufficient in syndromic patients with flexible kyphosis when adequate postoperative correction is achieved.

E-Poster #57

Factors Associated with Pedicle Screw Removal Secondary to EMG Pedicle Stimulation Criteria in AIS Surgery

Timothy R. Kuklo, MD, JD (Washington University School of Medicine); Mohammad Diab, MD; Daniel J. Sucato, MD, MS; B. Stephens Richards, III, MD; John B. Emans, MD; Lawrence G. Lenke, MD; Spinal Deformity Study Group

Introduction: Over the past decade, somatosensory (SSEP) and motor evoked potential (MEP) neuromonitoring has become increasingly more popular. However, pedicle screw EMG stimulation is still not universally used. The purpose of this study was to determine the utilization and utility of this technique, and the incidence and factors associated with pedicle screw removal in AIS.

Methods: A prospective pediatric multicenter database was queried to determine the utilization of triggered EMG monitoring of pedicle screws, and to determine the removal rate 2° monitoring. Analysis of contributing factors included body mass index (BMI), gender, EBL, total surgical time, total anesthesia time, curve type, radiographic parameters, and intraoperative complications. Statistical significance was set at $p < 0.05$.

Results: 2,154/2,378 consecutive pts undergoing AIS surgery underwent PSF or ASF/PSF (224 ASF only). Pedicle screws were placed in 1,283 (60%) of the PSF cases. Analysis of neuromonitoring techniques revealed SSEPs and MEPs in 87% and 72% respectively, and EMG triggering in 882 (64%) of the pedicle screw cases. All 3 techniques were used in combination in 704/1,283 (55%) cases. Screws were removed/revision in 92 cases (10.4%) 2° EMG stimulation criteria, with 73 of these screws removed permanently. Perioperative/intraoperative factors associated with pedicle screw removal/revision included increased BMI, increased EBL, total surgical and total anesthesia time (all $p < 0.05$). Gender was not significant. The only associated radiographic factor included a larger TL-L curve ($p = 0.04$); Lenke classification curve type was not associated with pedicle screw removal/revision. There was no association with intraoperative complications and screw removal/revision.

Conclusion: EMG triggering appears to have a significant impact on intraoperative decision making, as in >10% of cases ($n = 92$) triggered EMGs resulted in a “re-look” at pedicle screw placement and removal of 73 screws. Factors associated with screw removal/revision included increased BMI, EBL and operative/anesthesia time – perhaps indicative of “tougher” cases.



E-Poster #58

Congenital Vertebral Anomalies and a Small Spinal Cord: A Risk for Neurologic Sequelae?

Denis S. Drummond, MD (Children's Hospital of Philadelphia); Eric T. Ricchetti, MD; Harish S. Hosalkar, MD, MBMS (Orth), FCPS (Orth); Purushottam Gholve, MD

Introduction: Congenital vertebral anomalies may be associated with intraspinal pathology and neurologic sequelae. We previously reported small and "normal appearing" spinal cords in children with Klippel Feil Syndrome and congenital thoracic scoliosis. The purpose of this study is to analyze a cohort with 22q11.2 deletion syndrome, known to have vertebral anomalies focused at the cranio cervical junction. Our hypothesis was that these patients would have decreased cervical spinal cord dimensions relative to controls.

Methods: 32 patients with a 22q11.2 deletion underwent CT and/or MRI of the cervical spine to assess morphology. Digital MR imaging was available for 27/32 patients to evaluate: space available for the cord (SAC); sagittal diameter of the vertebral body, spinal canal, cerebrospinal fluid (CSF), and spinal cord; and cross sectional area of the spinal canal, CSF, and spinal cord. Measurements were taken at each cervical level (C1-C7) and compared to 29 age-matched controls using univariate analysis of covariance (ANCOVA), with age as the covariate. Possible neurologic sequelae were assessed.

Results: A. We identified 40 pathologies not evident on radiographs. B. Cohort patients had significantly smaller ($p=0.05$) vertebral body, spinal canal and spinal cord dimensions at one or more cervical levels compared to controls. Even when not statistically significant, spinal cord measurements were smaller at nearly every cervical level. C. Intraspinal anomalies were not observed. D. SAC was reduced in only 2 patients. E. 4 patients had neurologic sequelae; 1 needed surgical decompression.

Conclusion: 40 additional spinal anomalies were identified by CT/MRI. Encroachment on the SAC was rare. The "normal appearing spinal cord" was smaller in cohort subjects compared to controls, validating our hypothesis and identifying a potential risk factor for neurologic sequelae.

Significance: A small spinal cord is potentially vulnerable for myelopathy either early or with advanced age. The cause for the reduced size, such as too few or small spinal cord axones, is under further study. For now, the small cord should be considered a primary defect of development associated with potential risk that has important implications for management of congenital spinal deformity.

E-Poster #59

Quality Analysis of Digital Radiographic Software Measures: Evaluation of 29,122 Specific Data Points

Kathy Blanke, RN (Washington University School of Medicine); Timothy R. Kuklo, MD, JD; Lawrence G. Lenke, MD; Ian Cowgill, MS; Brandon McCutcheon; Spinal Deformity Study Group

Introduction: Prior studies have demonstrated good-excellent reliability of digital radiographic process measures. The purpose of this study was to assess via a quality assurance (QA) process the accuracy of previously validated software designed to produce all radiographic measurements for a multicenter prospective pediatric scoliosis study.

Methods: 422 pre and postop digital radiographs from 39 (3% of 1,363) AIS pts were critically reviewed as part of an ongoing QA program designed to ensure data accuracy and integrity. This included a systematic review of 781 data points/pt (11 x-rays - preop, bend, 1st, 1 & 2 yr postop) for a total of 29,122 data points evaluated. (see table) A 5-point scale was used to “grade” accuracy for 28 separate radiographic domains: 5-excellent, 4-very good, 3-good, 2-fair, 1-poor, and a total avg. score (max. 140 = 100%) was calculated. If a “critical error” occurred, the grade was automatically rated as poor (ex: x-ray uploaded backwards).

Results: Evaluation resulted in scores of 56% very good-excellent (n=22, avg score 4.5; 90-100% accuracy), 23% very good (n=9, avg score 4.0-4.4; 80-89% accuracy) and 21% good (n=8, avg score 3.0-3.9; 61-79% accuracy), with no poor to fair scores. There were no “critical errors”. The most commonly seen inaccuracies were: 1) mislabeled vertebrae which did not affect curve type or Cobb measurements, but could affect postop radiographic comparisons; 2) precise point/line placement which could alter Cobb measurements or curve classification, most difficult on preop lateral x-rays (T2-5) and postop x-rays due to instrumentation; and 3) upper & lower instrumented vertebra identification.

Conclusion: A QA process to ensure accurate database entry and management is critical. This detailed analysis of >29,000 data points validates the digital radiographic database integrity of this multicenter study. (79% good-excellent, 21 % good). We recommend this type of QA process for all large multicenter study databases to ensure data integrity/accuracy.

Significance: A QA process is necessary to ensure database integrity in large multi-center studies. Careful QA of the data is vital to ensure that radiographic & clinical measurements are accurately captured & reported.

Table 1 – QA Data Point Assessment

Preop Item:	# of points/labels to place:	Possible score:	Postop Item:	# of points/labels to place:	Possible score:
Vertebral labels – AP & lateral	38 (19 on each)	10 (5 pts each)	Vertebral labels – AP & lateral	38 (19 on each)	10 (5 pts each)
Point placement for vertebral lines – AP & lateral	AP – 75 Lateral – 74	10 (5 pts each)	Point placement for vertebral lines – AP & lateral	AP – 75 Lateral – 74	10 (5 pts each)
UEV/LEV	3 vert. (T1 default for PTC)	5	UIV/LIV – AP & lateral	2 vert. on each	10 (5 pts each)
Apices	3 vertebrae	5		Total: 191 data points	Max. score = 30
Sidebenders – PT, MT, TL/L - Point placement for vertebral lines	12 (4 on each bender)	15 (5 pts each)		# of points/labels to place:	Possible score:
Lenke Classification	3 parts	5	Preop:	208	50
	Total: 208 data points	Max. score = 50	Postop:	573 (3 x-ray sets)	90 (3 x-ray sets)
			Total:	781	140

* The FDA has not cleared a drug and/or medical device in use described in this presentation (i.e., the drug or medical device is being discussed in an off-label use). For full information see page 10.



E-Poster #60

Burst Fractures of the Spine in Children and Adolescents.

Kelly Vanderhave, MD; Michelle Caird, MD (University of Michigan); Frances A. Farley, MD; Michael Stauff, MD; Lee Segal, MD

Introduction: Burst fractures of the spine in children and adolescents are rare injuries. The goal of this retrospective study was to review our experience with this injury, and try to identify risk factors for spinal cord injury (SCI) and assess treatment, and functional outcome in pediatric burst fractures.

Methods: 37 pediatric patients were identified from 2 institutions with burst fractures of the thoracic and lumbar spine from 1991-2006. The patients' medical records and imaging studies were reviewed. SF-36 health surveys were mailed out to the patients to assess functional outcomes.

Results: There were 17 males and 20 females. The mean age of the patients was 14.6 years (range 6-18 years). Mean length of follow-up was 32 months. Thirteen patients sustained SCI (6 Frankel D, 2 C, 5 A). The risk of SCI did not correlate with the degree of canal compromise on CT scans, but did correlate with level of injury (T>TL>L). Six patients recovered at least one Frankel grade at follow-up. Nine patients were treated non-operatively (NO), and 28 had operative intervention (OP). Absolute indications for surgery included neurologic deficit and polytrauma. At follow-up, there was a greater loss of sagittal plane correction in the NO group. Seven patients developed complications leading to additional surgery including proximal junctional kyphosis (1), pseudarthrosis (2) and painful hardware (4). SF-36 data revealed that both the NO and OP groups reported decreased scores for physical function and overall health compared to normative data, the NO group reported more pain and the OP group reported more limitations due to physical health.

Conclusion: The risk of SCI in pediatric/adolescent burst fractures of the spine may be more a reflection of the level of injury than the degree of canal compromise. A third of patients in this series presented with neurological deficit, and all of these patients underwent operative treatment, including spinal cord decompression. Sagittal alignment was better corrected and maintained with operative treatment. The complication rate following surgery is high, and should be discussed preoperatively.

Significance: The risk of SCI in pediatric/adolescent burst fractures of the spine does not significantly differ from adults.

PAPERS READ BY TITLE



SCOLIOSIS RESEARCH SOCIETY



Adolescent Idiopathic Scoliosis

Chinese Growing Rod (PRSS) in Management of Progressive Adolescent and Juvenile Scoliosis

Mark S. Eskander, MD; Patrick J. Connolly, MD; Jonathan P. Eskander, A.B.; Anthony S. Lapinsky, MD; Maribeth Harrigan, APRN-C, NP-C; Dahari D. Brooks, Medical Doctor

To study on the therapeutic mechanism of an innovative instrumentation- Chinese Growing Rod and its effectiveness for the surgical management of adolescent and juvenile scoliosis

Translation and Validation of the SRS-22r for Use in Sweden

Serkan Bilgic, MD; Özkan Köse, MD; Ali Sehirlioglu; Ismail Safaz; Huseyin Ozkan

The SRS-22 questionnaire was translated and validated for use in Sweden. After a minor adjustment, it was shown to be appropriate for use.

The Impact of the Lumbar Spine Modifier and Thoracic Sagittal Profile on the Main Thoracic Curve of Lenke Type 1 Scoliosis

Serkan Bilgic, MD; Zafer Unsal Coskun; Yuksel Yurttas, Assistant Professor; Mustafa Kurklu, Assistant Professor

The flexibility of the structural main thoracic curve is related to the lumbar spine modifier and thoracic sagittal profile. We pay attention to correction of the structural main thoracic curve in the presence of lumbar spine modifier C to limit correction to maintain balance

Comparative Analysis of the Correction of the Instrumented and the Uninstrumented Distal Lumbar Curve: Lumbar Pedicle Screws versus Hooks in Double Major Curves in Adolescent Idiopathic Scoliosis.

David P. Roye, Jr., MD; Jaime A. Gomez, MD; Brian E. Kaufman, BA; Linda J. Addonizio, MD; Joshua E. Hyman, MD; Michael G. Vitale, MD MPH

The objective of this study was to compare the postoperative radiographic results of double major idiopathic scoliosis curves treated with a segmental hook-rod system versus an hybrid system with pedicle screws in the lumbar spine. The use of pedicle screws in the lumbar spine achieved a significantly better correction of the instrumented lumbar curve in the coronal plane, and also a significantly superior balance of the uninstrumented distal lumbar spine in both the coronal and axial plane.

Systematic Analysis of Anterior Thoracoscopic Instrumentation in Adolescent Idiopathic Scoliosis

Michael G. Vitale, MD, MPH; Derek W. Moore, MD; Ronald G. Emerson, MD; Hiroko Matsumoto, MA; Jaime A. Gomez, MD; Whitney A. Booker, BS; Kenneth L. Chambers, M-MPH; Hillard T. Spencer, MD; Edward J. Gallo; Joshua E. Hyman, MD; David P. Roye, Jr., MD

Instrumentation through anterior thoracoscopic surgery (IVATS) for treatment of adolescent idiopathic scoliosis is claimed to be advantageous over conventional instrumentation methods due to its minimal invasive nature. Superiority of IVATS has not been proved so far. We conducted a systematic review on published patient series treated with IVATS. Our study showed that IVATS is comparable to traditional surgery in terms of curve correction. But the advantages of cosmesis and less invasive nature is offset by increased operative time and complication rates with IVATS.

Accuracy and Utility of School Screening for Scoliosis in Hong Kong

Fred A. Sweet, MD

School screening for adolescent idiopathic scoliosis (AIS) remains controversial and evaluation was mostly performed on small cohort or without long follow-up. This study evaluated the school scoliosis screening in Hong Kong, started in 1995, based on a large cohort of children who were followed until the age of 19. The accuracy and utility measures of the screening program were more than 50%.

School Screening in Sivas, Turkey

Prof. Qibin Ye, MD; Xinyu Zhang; Yan Cao; Wenjun Wang
Scoliosis prevalence was found 0,47 % (0,71 % for girls, 0,28 % for boys).

True Assessment of Spinal Flexibility in Adolescent Idiopathic Scoliosis (AIS): Suspension versus Side-Bending Radiography

Iñaki Arroategui, MD, PhD

A new flexibility test consisting in a complete suspension of the subject by a harness was compared to side-bending radiographs in 18 AIS patients. Suspension provided a spinal curve reduction comparable to the one achieved by the side-bending for Cobb angles and better for axial rotations while allowing flexibility calculation. Since there is no correlation between reducibility and flexibility and that suspension is the only test to provide both information, this makes it a better method than side-bending for assessing spine flexibility.

Hooks or Screws – Which is Best for Idiopathic Scoliosis?

Iñaki Arroategui, MD, PhD

This study assessed the correction achieved in 3 types of spinal constructs in patients with adolescent idiopathic scoliosis (AIS). All constructs were comparable in the correction of coronal plane deformity and sagittal balance.

Does the Current Standard of Care Optimize Outcomes Among US Patients with Adolescent Idiopathic Scoliosis (AIS)?

Marco G. Teli, MD; Alessio Lovi, MD; Marco Brayda-Bruno

We used decision-analytic modeling to project health outcomes associated with current standards of care for patients with AIS in the US. We first simulated the likely natural history of spinal curvature based on patient characteristics and then altered that course by simulating treatment effectiveness with bracing and/or surgery.

Validation of a Norwegian Version of the SRS-22 and EuroQol in Patients with Adolescent Idiopathic Scoliosis

Marco Brayda-Bruno; Marco G. Teli, MD; Alessio Lovi, MD

The Norwegian version of the SRS-22 and EuroQol were evaluated in 57 patients with AIS. Range of scores were satisfactory without floor or ceiling effects. Repeatability, internal consistency, and ICC were acceptable. The poor validity compared with EuroQol support the use of a specific questionnaire for assessment of AIS.

Factors Affecting Shoulder Balance after Spinal Fusion in Idiopathic Scoliosis

Alessio Lovi, MD; Marco G. Teli, MD; Marco Brayda-Bruno

Shoulder elevation after selective thoracic fusion for adolescent idiopathic scoliosis (AIS) represents a difficult cosmetic problem. The causes and risk factors for this problem are not well-understood.

Increase in Standing Height Following Posterior Spinal Fusion for Adolescent Idiopathic Scoliosis (AIS)

John M. Olsewski, MD; John K. Czerwejn, Jr., MD

Patients experience an increase in their standing heights following posterior spinal fusions for adolescent idiopathic scoliosis.

Halo-Pelvic Traction in the Surgical Treatment of Severe Scoliosis (more than 100 degrees): Is it Always Necessary

Jonathan H. Phillips, MD; D. Raymond Knapp, Jr., MD; Jose Herrera-Soto, MD; Philip Meinhardt, MD

There were no significant differences between the 2 groups in gender, age, major curve Cobb-angle, curve flexibility, preoperative sagittal balance. The treatment result (major curve correction rate and correction loss) with preoperative main curve less than 120 degrees by Cobb was the same in both groups. But the result of postoperative correction spine deformity more than 120 degrees in patients from HPT/PSFI group was better ($p < 0.01$).

The Role of the Intervertebral Disc in Correction of Scoliotic Curves Treated by Braces or Fusionless Surgery

Prof. Ebrahim Ghayem Hassankhani

A theoretical model of IVD's role in progressive IS pathobiomechanics is proposed. In the model, the imbibed water mainly in the apical IVD but also in the adjacent discs, the diurnal variation in the water content of IVDs, and the Hueter-Volkman law are implicated. Modulating the wedging of the elastic IVD by braces or fusionless surgery in the immature scoliotic spine, the IVD is amended into a "corrective", rather than "progressive", factor of the deformity.

Prospective Comparison of Supine Bending, Push-Prone and Traction Under General Anesthesia Radiographs in Predicting Curve Flexibility and Postoperative Correction in Adolescent Idiopathic Scoliosis

Patrick J. Cahill, MD; Drew E. Warnick, MD; Michael J. Lee, MD; Lawrence C. Vogel, MD; Kim W. Hammerberg, MD; Peter F. Sturm, MD

We prospectively compared supine bending, push-prone and traction under general anesthesia (UGA) flexibility radiographs in 54 patients with adolescent idiopathic scoliosis (AIS). Supine bending and traction UGA correlated best with postoperative correction in structural curves, and push-prone and traction UGA correlated best with postoperative correction in nonstructural curves. Traction UGA is a relatively new technique which may provide a better estimation of overall spinal balance and may be more effective for preoperative planning in AIS.

Morphological Difference in Neural Axis Between Left and Right Thoracic AIS Subjects: Comparison with Normal Controls Using Volumetric MR Imaging

Mark M. Mikhael, MD; Paul M. Huddleston, III, MD, MS

Right and left thoracic AIS had similar morphological changes of the spinal cord with reduced cord to vertebral length ratio and increased apical AP/TS cord ratio when compared with normal controls but there was subtle difference at the brain level that right AIS had a lower cerebellar tonsil while left AIS had reduced white matter density of corpus callosum. Further investigation is warranted to see whether the above discrepancies are related to laterality of the scoliotic curve.

Intermediate-Term Results for Anterior Correction of Thoracic Idiopathic Scoliosis by Instrumentation Ending at T-10

Fred A. Sweet, MD; Christopher D. Sliva, MD; Michael S. Roh, MD

The anterior short segment bone-on-bone technique can predictably save many fusion levels as compared to the standard posterior approach. Most moderate severity ($< 75^\circ$), flexible ($> 50\%$ on stretch film) thoracic idiopathic scoliosis can be managed by instrumenting the apical 5 vertebra and removing the apical 4 discs.

Hanging Total Spine X-Rays in Scoliosis Patients

Prof. Luiz H. Pimenta, MD, PhD; Carlos F. Arias Pesántez, MD; Juliano T. Lhamby, MD; Leonardo A. Oliveira

We evaluated the flexibility of spine with deformity by hanging x-ray. Cobb angles in hanging position were correlated with initial correction angle by brace.

Do Adolescents with a Severe Idiopathic Scoliosis Have Higher Locations of the Conus Medullaris than Healthy Adolescents?

Justin V. Bundy, MD; Samuel R. Schroerlucke, MD; Steve Johnson; Prof. Joseph Sullivan; Norman Chutkan, MD

Through measurements in sagittal spinal MR images, the conus positions and the position distribution of 240 patients with adolescent idiopathic scoliosis (AIS) were similar to 120 healthy adolescents. The conus locations were not associated with age or sex in both group, as well as curve magnitude and pattern in AIS patients.

Selection of the Upper Instrumented Vertebra in the Surgical Treatment of Adolescent Idiopathic Scoliosis: Identification of the Most Influential Determinants

Prof. Alexandr Khoulyaev, MD; Pavel I. Kovalenko, MD; Prof. Vladimir I. Shevtsov, MD; Sergey V. Lyulin

The three most influential determinants when selecting the upper instrumented vertebra in the surgical treatment of adolescent idiopathic scoliosis are the coronal proximal thoracic curve magnitude, T1 tilt, and T5 to T12 kyphosis. A proximal thoracic curve magnitude $\geq 25^\circ$ differentiates between patients treated from T1-T3 versus T4-T5.

Comparison Between 4.0-mm Stainless Steel and 4.75-mm Titanium Alloy Single-rod Instrumentation Systems for Anterior Thoracoscopic Scoliosis Surgery

Prof. Alexandr Khoulyaev, MD; Prof. Vladimir I. Shevtsov, MD; Pavel I. Kovalenko, MD; Sergey V. Lyulin

A comparison between two single-rod anterior thoracoscopic instrumentation systems found that the 4.75-mm titanium alloy construct resulted in improved maintenance of deformity correction at 2-years post-op and a lower incidence of instrumentation related complications (pseudarthrosis, rod breakage and surgical revisions) compared to the 4.0-mm stainless steel construct.

Long Term Results of Anterior Spinal Fusion for Thoracic Scoliosis

Raghavendra Shankar, MS, DNB, AFSA; Daniel Chopin; Sebastien Charosky, MD; Christian Morin

A retrospective review of charts and radiographs was performed on fifteen patients with thoracic scoliosis that underwent anterior spinal fusion from 2000-2003 (mean F/U = 50 months). Five failures due to progression occurred; the ten successes showed statistically significant mean progression of the major curve. Analysis strongly indicated main thoracic curves ≥ 70 degrees with a large thoracic apical deviation are likely to progress to failure after anterior fusion. SRS 30 surveys were administered to available patients (mean score=69%).

Discriminative Validity of the Scoliosis Quality of Life Index in Females with Adolescent Idiopathic Scoliosis (AIS)

Noriaki Kawakami, MD; Tsuji Taichi; Kazuyoshi Miyasaka; Tetsuya Ohara; Ayato Nohara

The discriminative ability of the Scoliosis Quality of Life Index (SQLI) was examined in 95 females with adolescent idiopathic scoliosis. All SQLI domains discriminated among some of the 4 treatment subgroups. Only 'physical activity' and 'satisfaction' discriminated among curve types, and only 'self-esteem' and 'satisfaction' discriminated among Cobb severities. A model including 'satisfaction' correctly categorized 78% of those with Cobb severity above or below 50° . SQLI scores demonstrate poor discriminative ability consistent with high ceiling effects reported by others.

Elbow Skeletal Maturity of Boys and Girls Compared to Their Peak Height Velocity

John R. Dimar, MD; Yiyang Zheng; Yi Ping Zhang; Lisa B.E. Shields, MD; Paul A. Anderson, MD; Prof. Christopher Shields, MD

The timing of the peak height velocity (PHV) is a crucial maturity marker for scoliosis. This study evaluates the elbow skeletal maturity of both boys and girls using the Sauvegrain score compared to the PHV. It finds a close association between the maturity scores and PHV for both boys and girls.

Variation in Vertebral Numbering: Not Everyone with AIS has 12 Thoracic and 5 Lumbar.

Leah Y. Carreon, MD, MSc; Steven D. Glassman, MD; Mladen Djurasovic, MD; John R. Dimar, MD; John R. Johnson; Rolando M. Puno, MD; Mitchell J. Campbell

The accurate counting of vertebral levels in adolescent idiopathic scoliosis (AIS) requires an appreciation of the prevalence of variation in vertebral numbers. To date, this data has not been reported. The purpose of this study was to identify the prevalence of anatomic variation in vertebral number.

Accuracy of an Intraoperative Scoliosis Radiograph to Determine Ultimate Correction and Balance after Deformity Correction: Should it be Mandatory?

Aina J. Danielsson, MD, PhD; Karin Romberg, PT, MSc

Obtaining an intraoperative long cassette scoliosis film after deformity correction has been performed allows the surgeon to accurately determine the ultimate correction on the postoperative standing radiographs.

Does Part-Time Bracing Affect the Quality of Life of the Patients with Idiopathic Scoliosis?

Guy Barham, MB, BS; Ewan M. Davies, BM

How part-time bracing affects the quality of life of the patients with idiopathic scoliosis was investigated. Thirty patients were treated with exercise only, 33 with Milwaukee brace, and 40 with under arm brace. All the braces were prescribed as part-time wearing. In the Milwaukee brace group, the scores for function domain were lower than that of the other two groups, and the scores for pain and mental health domains were lower than that of the under arm brace group.

Change in Time of Radiographic and Balance Parameters for the Operative Treatment of Adolescent Idiopathic Scoliosis: Posterior Pedicle Screw-Only versus Hybrid Constructs

Rubens Jensen, MD; Lynn Letko, MD

In this large series of patients comparing pedicle screw to hybrid constructs in the treatment of AIS, pedicle screw constructs maintained their correction better than hybrid constructs at the 2-yr followup period.

Results after Short Segment Bone-on-Bone Instrumentation for Single Curve Adolescent Idiopathic Scoliosis after Mean Follow-up of 6 Years

Prof. Jun-Young Yang, MD, PhD; Prof. June Kyu Lee; Lawrence G. Lenke, MD; Ho sup Song; Eui Pyo Hong

The goal of operative treatment of idiopathic scoliosis is to obtain a solid fusion with correction of the deformity with restoration of coronal and sagittal plane balance, and correction of the "tilt angle", over as few segments as possible. Currently recommended anterior and/or posterior approaches include "long segment" instrumentation and fusion which, at least, includes all those vertebrae contained within the Cobb angle of the major curve on the preoperative standing posteroanterior radiographs. Our described procedure can be several levels shorter. During this study, supine stretch films were used for preoperative planning, since the stretch film demonstrates the response of the compensatory curves to correction of the major curve, better than any other method.

Discrepancy Between Radiographic Shoulder Balance and Cosmetic Shoulder Balance in Adolescent Idiopathic Scoliosis Patients with a Lenke Type 2 Curve

Shuichiro Ohno, MD; Steven D. Glassman, MD; Keith H. Bridwell, MD; William Horton, MD; Lawrence G. Lenke, MD; Sigurd Berven, MD; Serena S. Hu; Leah Y. Carreon, MD, MSc

This study investigated whether radiographic shoulder balance was quantitatively equal to the cosmetic shoulder balance in adolescent idiopathic scoliosis (AIS) patients with a Lenke Type 2 curve. The results showed that radiographic parameters could only partially reflect the shoulder cosmetic appearances.

The Nutrient Artery Entrance on the Posterolateral Wall of Thoracic Vertebral Bodies: Another Potential Landmark for Vertebral Screw Insertion?

Ankur Gupta, MS - Orthopedics; Raghu Varma, MS(ORTH)DNB; Abhay Nene; Sheetal Mohite; Shekhar Bhofraj; Siddharth A. Badve, MS(Orthopaedics), MBBS

In twenty adult dry spine specimens, the locations of the nutrient artery entrance (NAE) on the posterolateral wall of thoracic vertebral bodies were measured. From T5 to T12, NAEs were all underneath the costal facet, and no significant differences between left and right side were found in terms of anatomic parameters of each vertebral body. The anatomical location of the nutrient artery entrance is found to be relatively constant.

Accuracy of Vertebral Screw Insertion in Thoracic Adolescent Idiopathic Scoliosis Patients: A Comparison Between the Thoracoscopic and the Thoracotomy Approach.

Jonathan Webb, Bachelor of Science; Gilad J. Regev, M.D; Choll W. Kim, MD PhD

The accuracy of thoracic vertebral screw insertion in patients with adolescent idiopathic scoliosis (AIS) was compared between the mini-open thoracotomy and the thoracoscopic approach. Through measurements in CT images, the accuracy of screw insertion is similar in both approaches.

Rib Length Discrepancy in Adolescent with Idiopathic Scoliosis

Philip Giampietro, MD PhD; Nader Ghebraniou, PhD; Cathleen L. Raggio; Lynn Ivacic; Justin Staubli; Elizabeth McPherson, MD; Ingrid Glurich, PhD; James Burmester; Richard M. Pauli; F. Stig Jacobsen; Kristen J. Rasmussen, MS; Thomas Faciszewski; Oheneba Boachie-Adjei, MD; Robert D. Blank, MD PhD

In patients with adolescent idiopathic scoliosis (AIS) and those with scoliosis associated with Chiari malformations, rib length discrepancy was detected, with the ribs on the concave side significantly longer than those on the convex side in the apical vertebral region.

French-Canadian Validation of the Spinal Appearance Questionnaire (SAQ) in Adolescent Patients at a Scoliosis Clinic and its Clinical Application.

Jorge E. Isaza, MD; Steve A. Guillory, PA-C; Felipe Ramirez, MD
A French-Canadian version of the Spinal Appearance Questionnaire was validated in patients at a scoliosis clinic in Quebec. It showed satisfactory internal coherence and convergent validity. SAQ is relevant for clinical use since it can discriminate clinical values while not being influenced by BMI, age, Risser and gender. However, its second part (Q9-Q16) has a U-shaped distribution, and agreement between parents and patients is really lower than for its first part (Q1-Q7).

Does Posterior Multiple Level Release Allow for A Better Correction of Adolescent Idiopathic Scoliosis Curves?

Panagiotis Korovessis, PhD, MD; Thomas Repantis, MD; Georgios Petsinis, PhD, MD

By analyzing two groups, we prove that wide posterior release aids in the correction of main curves in AIS. Using a posterior hybrid instrumentation we are able to obtain a postoperative correction of 68.6%, and final follow-up correction of 60.8%.

The Influence of Thoracic Kyphosis on the Sagittal Balance of the Lumbosacral Spine in Adolescent Idiopathic Thoracic Scoliosis Patients

Morio Matsumoto, MD; Kota Watanabe, MD; Shingo Izuka; Prof. Yoshiaki Toyama; Kazuhiro Chiba, MD, PhD

Through measurements in sagittal standing X-rays of adolescent idiopathic thoracic scoliosis (T-AIS) patients, significant linear correlations were found between each single adjacent shape parameter, and smaller LL and upper arc of lumbar lordosis were found in patients with thoracic kyphosis (TK) less than 10°.

Abnormal Expression and Etiological Significance of Runx2 in Mesenchymal Stem Cells from Adolescent Idiopathic Scoliosis

Franck Accadbled, MD, PhD; Jean Michel Laffosse; Dominique Ambard; Anne Gomez Brouchet; Bruno S. Gomes; Prof. Jérôme Sales de Gauzy; Prof. Pascal Swider, PhD

Through cultures of mesenchymal stem cells (MSCs) obtained from anterior superior iliac spine in adolescent idiopathic scoliosis (AIS) patients, congenital scoliosis (CS) patients, and the controls, the mRNA expressions of Runx2 were evaluated. Increased Runx2 expression was found in AIS patients, while similar expression was found in CS patients and the controls.

Abnormal Expression and Etiological Significance of BMPR-1-IB in Mesenchymal Stem Cells from Adolescent Idiopathic Scoliosis

Yannick Loosli; Daniel Baumgartner; Gianni Bigolin; Beat Gasser; Prof. Paul F. Heini, MD

Through cultures of mesenchymal stem cells (MSCs) obtained from anterior superior iliac spine in adolescent idiopathic scoliosis (AIS) patients and the controls, the mRNA and protein expressions of BMPR-1A/1B were evaluated. Increased BMPR-1A/1B expression was found in AIS patients, while similar expression was found in CS patients and the controls.

A 3D Assessment of Harrington vs Cotrel-Dubousset Instrumentations for the Correction of Adolescent Idiopathic Scoliosis

Michael Kilshaw, MBBS, BSc, MRCS; Jemma C. Rooker, Bm Bch; Ian J. Harding

This study retrospectively measures and compares the 3D changes of spinal shape before and after surgical correction using Harrington or Cotrel-Dubousset instrumentations of 69 subjects with adolescent idiopathic scoliosis (AIS), in order to determine if the claims for improved 3D correction could be substantiated. Significant differences were observed in the 3D correction of the spine based on the orientation and Cobb angles in the planes of maximal curvature, demonstrating that the derotation manoeuvre can produce better 3D correction of scoliosis deformities than distraction alone.

The Effect Size of Surgery on Clinical and Radiological Parameters in Patients with Idiopathic Scoliosis

Leah Y. Carreon, MD, MSc; Steven D. Glassman, MD; Mladen Djurasovic, MD; John R. Dimar, MD; John R. Johnson; Rolando M. Puno, MD; Mitchell J. Campbell

A prospective study including 77 patients operated to treat an idiopathic scoliosis. The effect of surgery is related to correction of the radiological deformity and perception of improved body image. There was a small improvement in pain and no effect on function or psychological status.

Relationship Between Height Increase and Curve Correction by Posterior Surgery for Adolescent Idiopathic Scoliosis

Mauro Volpi; David Gumieiro; Denis Varanda

160 patients with AIS were included for the purpose of evaluating a correlation between curve corrections and height increases by posterior corrective surgery for AIS. The mean age was 15.1±4.5 years. A mean Cobb angle change was 39.8±9.9° after surgery and the mean T1-L5 distance increase was 30.2±10.2 mm. Height increase by posterior surgery had strong positive correlation with Cobb angle change. Enhanced correction of thoracic curve can give a significant increase in height, minimizing loss of height secondary to spinal fusion.

Serum Melatonin Levels in Adolescent Idiopathic Scoliosis Prediction and Prevention for Curve Progression-A Prospective Study

Steven D. Glassman, MD; Leah Y. Carreon, MD, MSc; Mladen Djurasovic, MD; John R. Dimar, MD; John R. Johnson; Mitchell J. Campbell; Rolando M. Puno, MD

We studied 40 patients with adolescent moderate to severe idiopathic scoliosis and 25 age matched control subjects. Our findings suggest that melatonin deficiency play a role in the prognosis of idiopathic scoliosis by determining the degree of spine curvature. Melatonin supplement may help prevent the development of progressive scoliosis especially in mild cases showing less than a 35 degree curve.

The Biomechanical Effects of Thoracic Spine Stapling

Jean Michel Laffosse; Franck Accadbled, MD, PhD; Thierry Odent, MD; Dominique Ambard; Anne Gomez Brouchet; Bruno S. Gomes; Prof. Jérôme Sales de Gauzy; Prof. Pascal Swider, PhD

Biomechanical testing of anterior vertebral stapling in a calf spine model has found that staple insertion causes a small, but significant, decrease in motion segment stiffness measures.

The Role of Routine Magnetic Resonance Imaging in the Preoperative Evaluation of Adolescent Idiopathic Scoliosis

Ruben A. Maenza; Jorge Hokama; Miguel Puigdevall; Santiago Bosio

A total of 249 patients with a diagnosis of idiopathic scoliosis was treated surgically between the years 2002 to 2007. A routine whole spine MRI analysis was performed in all patients. There were 20 (8%) patients (3 males and 17 females) who had neural axis abnormalities on MRI. Three of those 20 patients needed additional neurosurgical procedures before corrective surgery.

Comparison of Selective Anterior versus Posterior Screw Instrumentation in Lenke 5C Adolescent Idiopathic Scoliosis

Ruben A. Maenza; Jorge Hokama; Miguel Puigdevall; Santiago Bosio

To compare the clinical and radiographic results of anterior versus posterior pedicle screw instrumentation in Lenke 5C adolescent idiopathic scoliosis.

Can We Save One More Mobile Segment Distally in the Posterior Surgical Treatment of Adolescent Idiopathic Scoliosis with Double Major Curves: Role of Traction Graphics Taken Under General Anesthesia in Decision Making

Samuel J. Cheurning, MD; Todd S. Jarosz, MD; Hubert L. Gooch, Jr., MD; Kenneth E. Wood, MD; C. Jane Keiger, PhD

In 76 patients with double major curves (Lenke Type 3C and 6C), we have stopped at L3 level instead of L4 even when CSVL does not touch L3. In nearly two thirds of cases, CSVL does not touch L3 and it does not become level at bending radiographs. Traction radiographs taken under general anesthesia are especially helpful in these cases because L3 becomes level, CSVL touches or bisects L3 and L3 is completely in Harrington's stable zone. Thus, you can stop at L3.

Comparative Analysis between Lenke Type 1A, B and C Curve Patterns: Pedicle Screw versus Hybrid Constructs. Which Maintains Correction Better?

Prof. Vincent Arlet, MD; Vasantha Reddi, PhD MHES; Douglas V. Clarke, Jr., BA

Hybrid constructs obtained less correction than pedicle screws for each lumbar modifier for Lenke Type 1 curves. In addition, pedicle screws tended to maintain their curve correction, coronal and sagittal balance better than the hybrid group at all time points.

Detorsion Night Brace in the Treatment of Adolescent Idiopathic Scoliosis (AIS): Results of a Prospective Study

Samuel A. Joseph, Jr., MD; Ketevan Berekashvili, MD MPH; Javed F. Brandoff, MD; Marc S. Menkowitz, MD; Michael Neuwirth, MD; Andrew Casden; Paul Kuflik, MD

This prospective study evaluates the results of detorsion night bracing in the treatment of AIS. Indications for bracing followed the SRS recommendations. 67 patients were included with a mean age of 12.8. Duration of treatment averaged 32 months. Good results were reported in 73% of patients, with less than 4° progression in the frontal balance and restoration of the thoracic kyphosis

Universal Clamp in the Treatment of Adolescent Idiopathic Scoliosis: A Prospective Study at 2-Year Follow-Up

Hiroshi Taneichi, MD; Kota Suda; Tomomichi Kajino; Hiroshi Moridaira; Prof. Yutaka Nohara, MD

The universal clamp is a spinal implant that can be used as an alternative to hooks or pedicular screws at thoracic levels for deformity surgery. This study reports the safety of the method and the corrections obtained at 2 years in 70 patients operated for AIS. Results in the frontal plane are equivalent to the best corrections reported previously with other instrumentations, with shorter operative time and easier postoperative imaging. Correction of sagittal balance is the best reported in literature.

Spontaneous Correction of the Thoracic Curve after Selective Posterior Lumbar Fusion in Double Idiopathic Scoliosis

Chun Fan Lee; Daniel Y.T. Fong, PhD; Prof. Kenneth Man Chee Cheung; Kwok Hang Mak, MB,BS, MSc PH; Prof. Jack Chun Yiu Cheng, MD; Paul Siu Fai Yip; Bobby Kin-wah Ng; Prof. Keith D.K. Luk

A retrospective review of adolescent idiopathic scoliosis (AIS) patients with major lumbar curve and secondary thoracic curve following selective posterior correction and fusion of the major curve.

Shoulder Balance after Surgery in Lenke Type 2 Scoliosis Corrected with the Segmental Pedicle Screw Technique

Steven D. Glassman, MD; Leah Y. Carreon, MD, MSc; Mladen Djurasovic, MD; Mitchell J. Campbell; Rolando M. Puno, MD; John R. Johnson; John R. Dimar, MD

To compare the effects on shoulder balance of segmental pedicle screw correction of Lenke type 2 scoliosis. Lenke type 2 scoliosis with a proximal thoracic side bending curve of more than 25° should be treated with fusion of both the proximal and the distal curves when using a segmental pedicle screws.

Coronal and Sagittal Plane Correction in a Lenke 1 AIS: A Comparison Between Consecutive Pedicle Screw versus Interval Pedicle Screw Constructs on the Correction Sides

Steven D. Glassman, MD; David W. Polly, Jr., MD; Christopher M. Bono; J. Kenneth Burkus; John R. Dimar, MD

To compare the postoperative results of posterior correction and fusion with consecutive pedicle screw versus interval pedicle screw constructs on the correction sides in a Lenke 1 AIS (adolescent idiopathic scoliosis) treated at a single institution.

Reliability and Validity of Adapted Simplified Chinese Version of the Scoliosis Research Society-22 (SRS-22) Questionnaire in Mainland China

Kansu Cilli, MD; Prof. Gunduz Tezeren, MD; Zekeriya Oztemur, MD; Prof. Okay Bulut; Hayati Ozturk; Prof. Tansel Unsaldi

The SRS-22 questionnaire was translated into several languages. But there is no valid adapted simplified Chinese Version of SRS-22 questionnaire in Mainland China. Our study showed that simplified Chinese Version of SRS-22 showed high levels of the reliability and concurrent validity.

The Outcome of Surgical Treatment of Thoracic Scoliosis by Pedicle Screws in Different Flexible Curves

Marie-Ève Lamarre, Bachelor; Stefan Parent, MD, PhD; Prof. Carl-Éric Aubin, PhD, P.Eng.; Hubert Labelle, MD; Julie Joncas; Prof. Yvan Petit, PhD

It's still unknown that in different flexible thoracic curves, do the rates of surgical correction with all pedicle screws remain the same. The aim of this study was to determine the relationship between curve flexibility and the result of posterior correction with thoracic pedicle screws.

The Difference of Physiological Tricuspid Regurgitation in Adolescent Idiopathic Scoliosis with Right Thoracic Scoliosis or Not

Eric J. Wall, MD; Joseph Reynolds; Rich Grant, BS; Donita I. Bylski-Austrow, PhD

Some authors found thoracic deformity (including scoliosis) have impacted valvular anomalies, but which shape of scoliosis has the influence for valvular physiological regurgitation has never reported.

Assessment of Coronal Deformity Correction for Thoracic Scoliosis by Sparse Pedicle Screws using Fulcrum-Bending Radiograph.

Gregory Redding, MD; Amanda Striegl, MD; Maida Chen, MD; Yemiserach Kifle; Kit Song, MD

Sparse pedicle screws is a good method in the surgical treatment of thoracic scoliosis. Fulcrum bending flexibility was lower than operative correction rate by sparse pedicle screws method in main thoracic curves.

Hemivertebra Resection in the Treatment of Congenital Kyphoscoliosis

Eugene L. Wong, MBBS, Masters (OrthoSurg); Leanne Sutherland; Peter Cundy

25 patients with fully segmented hemivertebra treated with hemivertebra resection were reviewed. All the patients underwent MRI, CT, X examination and with hemivertebra resection, fusion and correction with instrumentation. The average operation time was 4.5 hours, the mean blood loss was 850. Scoliosis was corrected from 84.6° (28°-150°) to 38.3° (24-58°), with a correction rate of 53.7%. Kyphosis was corrected from 68° (47°-125°) to 25.3° (13-38°), with a correction rate of 61.5%. At the final follow-up, No pseudoarthrosis and implant failure was noted. There was no neurological complication.

Sagittal Curves of the Cervical Spine in Adolescent Idiopathic Scoliosis

James O. Sanders, MD; Jacques D'Astous, MD; Marcie Fitzgerald, MPAS, PA-C; Joseph G. Khoury, MD; Shyam Kishan, MD; Peter F. Sturm, MD

One-hundred-thirty-three AIS patients were retrospectively reviewed to examine the sagittal curves of cervical spine. The incidence of cervical kyphosis was very high in AIS patients with a typical pattern of angular kyphosis. It was related with thoracic hypokyphosis. However, the cervical kyphosis was not significantly improved though the thoracic hypokyphosis was surgically corrected by the rod derotation, which means the rotation in the thoracic curves also affected the cervical kyphosis.

Surgical Treatment for Asymptomatic Chiari Malformation I Associated with Spinal Scoliosis

Samuel O. VanNorman, MBA; David W. Polly, Jr., MD; Prof. Karen M. Kuntz

18 patients with Chiari malformation I associated with scoliosis were corrected with instrumentation. The surgical procedures which included posterior correction with fusion and instrumentation, anterior release, et al. one or two stage or combined anterior-posterior approach manner based on the level and severity of the deformity were performed. All patients underwent the surgery safely and there were no death or neurological injury occurred.

The Use of a Decision Tree Increases Accuracy when Classifying Adolescent Idiopathic Scoliosis Using Lenke Classification

Jan W. Duncan, MD; Susan L. Wahrenbrock, OPA-C

A computer algorithm based on a decision tree was developed to increase accuracy when classifying adolescent idiopathic scoliosis (AIS) using Lenke classification. A diagram of this algorithm was adapted to be used by clinicians. Its use increased classification accuracy.

Reliability and Effectiveness of Thoracic Pedicle Screw Placement Using Freehand Technique for Scoliosis Surgery: A Clinical, Anatomical, and in vivo Three-Dimensional Image Study

Kyu-Jung Cho, MD; Prof. Seung-Rim Park, MD; Young-Hyun Yun; Suk-Bong Kang, MD; Man-Hee Won, MD

A clinical, anatomical, and in vivo 3-D image study was performed to evaluate the reliability and effectiveness of freehand technique in thoracic pedicle screw placement for scoliosis surgery. There was no difference of anatomical landmark between normal and scoliotic spines. It was reliable and effective when a surgeon correctly understood the anatomy of deformed vertebrae.

The Role of Traction Radiographs Taken Under General Anesthesia in Surgical Decision Making of Treatment of Adolescent Idiopathic Scoliosis

Raphael Adobor, MD; Silje Rimeslåtten; Jens I. Brox, MD, PhD; Anne Keller, PhD, MD

The corrective ability of traction radiographs taken under general anesthesia is superior to side bending, fulcrum and supine traction graphies in determination of flexibility of proximal thoracic (PT) and main thoracic (MT) curves, especially statistically more valuable in main thoracic curves of more than 65 degrees in magnitude. For thoracolumbar/lumbar (TL/L) curves, it is almost equal to side bending in curves less than 65 degrees and more corrective than side bending for curves more than 65 degrees in magnitude.

Spinal Balance in Idiopathic Scoliosis - Do Radiographs Really Reflect the Clinical Picture?

Akira Matsumura, MD, PhD; Hiroyuki Yasuda, MD; Hidetomi Terai, MD, PhD; Tadao Tsujio, MD; Akinobu Suzuki, MD, PhD; Takafumi Maeno; Kazushi Takayama; Sho Dozono; Hiroaki Nakamura, MD

A multicenter AIS database was queried to determine if clinical and radiographic measurements of spinal balance accurately reflect one another. These measurement parameters will be in close approximation (1cm) to one another only half the time. Most measurements of clinical/radiographic balance will be within 2cm of each other. Noting that this variation exists, studies which use measurements of radiographic data to report on the clinical appearance of spinal balance in AIS patients should be interpreted carefully.

Factors Involved in the Decision to Perform a Selective versus Nonselective Fusion of Lenke 5 Curves in Adolescent Idiopathic Scoliosis

Vidyadhara Srinivasa, MS, DNB, MNAMS, FNB; Prof. James Gnanadoss, MS

Surgeons tended to perform nonselective fusion (NSF) in patients with overall larger Cobb magnitudes, larger thoracic rib humps, and greater thoracic apical translations.

Surgical Treatment of Scoliosis by Vertebral Coplanar Alignment (VCA): Effect on Thoracic Kyphosis.

Peter G. Gabos, MD; Gilbert Chan; Dan E. Mason, MD

Surgical treatment by posterior approach with pedicle screws has a tendency to decrease thoracic kyphosis. VCA addresses correction of the sagittal plane by recovering the physiological posterior divergence of anteroposterior (X) axes. Forty five patients were treated by posterior approach with pedicle screws and correction by VCA. Although the average variation of kyphosis was -3.6° for all cases, it was +8.4° in cases with initial kyphosis <20°. No patients had a (-) Lenke sagittal modifier postoperatively.

A Systematic Review and Meta-Analysis of the Clinical Effectiveness of School Scoliosis Screening

Masaaki Chazono, MD, PhD; Shigeru Soshi, MD, PhD; Takeshi Inoue; Yousuke Nakamura; Akira Shimohara; Kurando Hashimoto; Keishi Marumo

We systematically reviewed the current literature on school scoliosis screening and estimated the referral rate for radiography and true positive rate for scoliosis by meta-analysis. All but only one small study did not follow children till skeletal maturity. This underestimated the true positive rate. Future evaluation study should be based on larger cohort with sufficient follow-up.

Comparative Analysis of Sagittal Plane Measures following Posterior Segmental Spinal Instrumented Fusion of Adolescent Idiopathic Scoliosis: Hooks Only vs. Sublaminar Wiring vs. Thoracic Pedicle Screw Instrumentation

Yuji Matsubara; Noriaki Kawakami, MD; Manabu Goto; Tsuji Taichi; Tetsuya Ohara; Kazuyoshi Miyasaka; Ayato Nohara

Radiographic measurements of 352 AIS patients with posterior only segmental spinal instrumentation and fusion demonstrated that thoracic kyphosis change during operative procedure made an significant impact on the proximal junctional angle change, but not on the lumbar lordosis and C7 plumb line at the ultimate follow-up among

A Comparison of the Melatonin and Calmodulin in Paravertebral Muscle and Platelets of Patients with or without Adolescent Idiopathic Scoliosis(AIS)

Yutaka Nakamura, MD; Prof. Toshiro Nagai; Nobuyuki Murakami; Takahiro Iida, MD; Satoshi Asano; Prof. Satoru Ozeki; Prof. Yutaka Nohara, MD

This study investigated the tissue concentrations of melatonin and calmodulin in platelets and paraspinal muscles of patients with AIS and compared with non-scoliotics. It was seen that neither muscle nor platelet concentrations of both molecules were different in AIS population. However, muscle calmodulin concentrations were significantly higher at the convex side of deformity.

Is Local Autograft Bone Enough to Obtain an Adequate Arthrodesis in Thoracic and Double Adolescent Idiopathic Scoliosis Curves?

Kevin Neal, MD; Gang Ye, PhD; Gabriela Ramirez-Garnica, PhD, MPH; R. J. Cummings, MD

Two groups of 20 patients operated on AIS were reviewed. In one group iliac autogenous bone graft was used. In the other only local bone from the surgery site was used. No clinical or radiographic significant differences were found. Complications were slightly fewer in local bone group.

Double Major Adolescent Idiopathic Scoliosis using Pedicle Screw Instrumentation – More than 5 Years Follow-Up

Rex Marco, MD; Vivek Kushwaha

Thirty-eight adolescent idiopathic scoliosis patients with double major curve were retrospectively analyzed to evaluate the outcome of pedicle screw instrumentation with rod derotation after a minimum 5-year follow-up. The distal level of fusion was L2 in 3 patients, L3 in 31 and L4 in 4. The preoperative thoracic and lumbar curves of $46\pm 9^\circ$ and $53\pm 9^\circ$ were corrected to $15\pm 5^\circ$ (67% correction) and $20\pm 10^\circ$ (62% correction), respectively. Pedicle screw instrumentation had satisfactory outcomes with well-maintained correction and preservation of lower lumbar motion segments.

Does Direct Vertebral Rotation Save Distal Motion Segments in Thoracic Adolescent Idiopathic Scoliosis with Lumbar Modifier A?

Prof. Anatolii F. Levytskyi, MD; Volodymyr Plyatsek

Thoracic AIS patients with lumbar modifier A treated with pedicle screw instrumentation were analyzed to determine whether DVR can save distal motion segments. They had a preop neutral vertebra more than two levels distal to end vertebra. We found that DVR can save distal motion segments by one segment. Better results can be obtained when the lower NV is located more than two levels distal to EV.

Postoperative Evaluation of Proximal Thoracic Curve in Lenke Type 1 Adolescent Idiopathic Scoliosis. - Is Lenke Classification Appropriate?

Theodoros B. Grivas, MD; Elias S. Vasiliadis, MD; Georgios Rodopoulos; Nikolaos V. Bardakos, MD; Konstantinos Gatos, MD

The retrospective study on proximal thoracic deformity in Lenke type 1 adolescent idiopathic scoliosis (AIS) was performed. All patients were treated with posterior instrumentation. Patients whose preoperative proximal thoracic Cobb angle was more than 30 degrees or 20 degrees in left bending film were treated with long fusion, namely upper instrumented level was two or more proximal from end vertebra. They had greater postoperative Cobb angle and lower correction rate than short fusion group.

Compare the Cardiac Structures and Function Between Patients with Idiopathic Scoliosis and Those with Congenital Scoliosis

Leah Y. Carreon, MD, MSc; Steven D. Glassman, MD; Mladen Djurasovic, MD; Mitchell J. Campbell; Rolando M. Puno, MD; John R. Johnson; John R. Dimar, MD

Cardiac structure and function indexes were compared between patients with adolescent idiopathic scoliosis (AIS) and with congenital scoliosis (CS). Significant differences were found in those cardiac indexes between AIS and CS patients

Single-Stage Anterior and Posterior Spinal Fusion: Safe and Effective for Severe and Rigid Adolescent Idiopathic Scoliosis in Less Developed Countries

Raymond W. Liu, MD; Andelle L. Teng, MD, MS; Douglas Armstrong, MD; Connie Poe-Kochert, RN, BSN, CNP; Jochen P. Son-Hing, MD, FRCSC; George H. Thompson, MD

Delayed treatment of adolescent idiopathic scoliosis (AIS) leading to severe deformity is not uncommon in regions such as Mainland China. This creates a treatment dilemma in which a high incidence of more complex cases occurs in a region where surgeons have less access to training and experience in the more technically demanding corrective methods.

Successful use of Posterior Instrumented Spinal Fusion Alone for Scoliosis in Neurofibromatosis Type-1

K. Daniel Rieu, MD; Jacob M. Buchowski, MD, MS; Rick C. Sasso, MD; Thomas Zdeblick, MD; Newton H. Metcalf, B.S.; Paul A. Anderson, MD

We evaluated whether long, posterior instrumented fusion alone might be effective for patients with neurofibromatosis type I NF-1 whose scoliosis is less than 90° and who are more than ten years old, if the fusion were performed to include the neutral and stable vertebrae in both the coronal and sagittal planes, any coronal curves more than 40° , and using abundant bone grafts.

Spontaneous Correction of the Thoracic Curve after Selective Posterior Lumbar Fusion in Double Idiopathic Scoliosis

Jorge E. Isaza, MD; Steve A. Guillory, PA-C; Scott E. Wilks, PhD

A retrospective review of adolescent idiopathic scoliosis (AIS) patients with major lumbar curve and secondary thoracic curve following selective posterior correction and fusion of the major curve.

Analysis of Selective Anterior Fusion versus Posterior Fusion of Thoracolumbe-Lumber Curves in Adolescent Idiopathic Scoliosis

Jared F. Brandoff, MD; Ketevan Berekashvili, MD MPH; Navin Subramanian, MD; Valeriy Kheyfits, MD; Kevin Math, MD; Samuel A. Joseph, Jr., MD; Marc S. Menkowitz, MD; Andrew Casden; Paul Kuflik, MD; Michael Neuwirth, MD

Both the two surgical treatments can be conducted in correcting thoracolumbar and lumbar adolescent idiopathic scoliosis, and the percentage correction did not differ significantly between the 2 groups. But the length of surgery was significantly shorter in the posterior group, and fusion levels were longer, the incidence of proximal junctional kyphosis was higher.

Anterior versus Posterior Surgery in Lenke Type V Adolescent Idiopathic Scoliosis

Anton E. Dmitriev, MSc; Melvin D. Helgeson, MD; Patrick B. Cooper, MD; Frederick L. Stephens, II, MD; Ronald A. Lehman, Jr., MD; Michael Rosner, MD;

It is possible to perform posterior surgery instead of anterior surgery in Lenke type V curves by staying at the same instrumentation and fusion levels as anterior surgery to save same number of mobile segments and achieving same rate of correction by avoiding the morbidities of anterior surgery.

Assessment of Vertebral Body Rotation in AIS: Correlation Between Scoliometer and Axial CT Measurements

Bobby Kin-wah Ng; Prof. Winnie C. Chu, MD; Prof. Lin Shi, PhD; Prof. Defeng Wang, PhD; Prof. Tomas Paus; Prof. Alain Pitiot; Prof. Richard. G. Burwell, MD FRCS; Prof. Brian J. Freeman, MD; Chi Wai Gene Man, Bachelor; Annie T. Cheng; Wai Wang Chau, MSc; Benson Yeung, PhD; Kwong-man Lee, PhD; Prof. Jack Chun Yiu Cheng, MD

In a retrospective study, 29 AIS patients with preoperative CT scans and scoliometer measurements were evaluated. There was no statistically significant correlation between vertebral rotation as measured on CT scan and trunk rotation as measured by scoliometer. The scoliometer may not provide an accurate assessment in the evaluation of surgical derotation maneuvers.

Minimum 5-Year Follow-Up of Posterior Pedicle Screw-Only Constructs in the Operative Treatment of Adolescent Idiopathic Scoliosis

Rajat R. Verma, FRCS (Tr & Orth); Robert W. Gaines, Jr., MD
Pedicle screw (PS) instrumentation provides excellent curve correction and restoration of coronal and sagittal balance with maintenance of correction in patients with AIS at five-year follow-up.

Development of Curve Progression Model from AIS Brace Compliance

Mustafa Kurklu, Assistant Professor; Serkan Bilgic, MD; Yuksel Yurttas, Assistant Professor; Huseyin Ozkan; Matthew E. Cunningham, MD PhD; Ali Sehirlioglu

Bracing is the most commonly used non-surgical treatment for AIS. However, prediction of brace treatment outcomes has not been well documented. Twenty subjects with AIS (3M, 17F) and prescribed brace treatment participated into this study. A curve progression model was developed based on brace compliance (quantity and quality of brace usage) and risk of progression. Data from one patient with 3 months of compliance data was used as a case-study validation of the model. The predicted progression was within 1°.

Does Preoperative Brace-Wear Influence Radiographic and Clinical Outcomes of Adolescent Idiopathic Scoliosis Surgery?

Theodoros B. Grivas, MD; Elias S. Vasiliadis, MD; Constantinos Mihas; Christina Mazioutou; Georgios G. Triantafyllopoulos, MD; Panagiotis Alexandropoulos

Via a multicenter prospective database of 470 AIS patients of which 219 underwent some form of preoperative bracing, we compared these two groups in relation to gender, various demographic, radiographic, and SRS Outcome scores following their spinal fusion. We found that whether a patient wears a brace or not prior to surgical intervention really will not have any major effect on the radiographic or clinical outcome of their spinal fusion surgery.

Loop Rectangle and Sublaminar Wires in Surgical Treatment of Adolescent Idiopathic Scoliosis - an Analytical Study of Twenty Five Patients in an Indian Scenario

Chintan Sampat, MD; Peter F. Sturm, MD; Kim W. Hammerberg, MD

Literature popularizes the efficacy of third generation instrumentations in the surgical correction of spinal deformities. A cheap and effective method in scoliotic deformity correction is reviewed in this article. Twenty five patients of Adolescent Idiopathic scoliotic spinal deformities underwent corrective posterior spinal arthrodesis with segmental spinal fixation by indigenously made stainless steel contoured loop rectangle and 20 gauge sublaminar wires. Clinico-radiological evaluation at an average followup of 3 1/2 years (min-2 years). Patient satisfaction along with clinical outcome were accounted. Average preoperative Cobb's angle were 66.48°. Average percentage correction was 69.19% and the degree of correction was 46 degrees. Loss of correction in the whole group was 3.2 degrees at two years and 5.8 degrees in 21 patients beyond 3 years at last follow up. The patients satisfaction index as per the SRS24 questionnaire in 25 patients revealed that 80.2 % of patients were ready to undergo the same surgery if required. [74.2 % agreed to be happy to live for life with present correction]. Segmental spinal fixation with spinal loop rectangle and sublaminar wires is comparable and cost effective as a modality to correct scoliotic spinal deformities in comparison with third generation implants.

Intra and Inter Evaluators Agreement of Proximal Junctional Kyphosis (PJK) at the First and Second Vertebra above the Upper Instrumented Vertebra (UIV).

Kangtaek Lim

The aim was to test the agreement measuring PJK at the first and second vertebra above the UIV. We evaluated 38 radiological images. The agreement for the evaluators in the first vertebra ranged between 0.78 and 0.80, and for the second vertebra between 0.49 and 0.88 (minimum confidence interval: 0.16-0.72) in the postoperative and the follow up periods. No differences were found between evaluators in the concordance on the angles of the first and second vertebra above the UIV.

Comparison of the Lower End Vertebra (LEV) to the Lowest Instrumented Vertebra (LIV) in Adolescent Idiopathic Scoliosis: A Role for the Addition of an LEV Modifier to the Lenke Classification System

Tetsuo Ohwada; Tomoya Yamashita; Kimihiko Onoue; Shozo Suzuki

Although the Lenke Classification System of AIS does categorize operative curves into similar groups, there are still subtle differences due to the lack of a common vertebral landmark. We propose adding the LEV as a third modifier to the Lenke Classification System to not only more thoroughly describe a particular curve pattern, but allow a more detailed postoperative assessment of distal fusion length to aid in postoperative analysis of surgical treatment via comparison of the LIV-LEV score.

Use of the Double Rib Contour Sign to Determine Rib Hump Correction Following Scoliosis Surgery.

Suken A. Shah, MD; Peter O. Newton, MD; Harry L. Shufflebarger, MD; Michael O'Brien, MD; Randal R. Betz, MD; Tracey P. Bastrom, MA; Michelle C. Marks, PT, MA; Harms Study Group

The addition of costoplasty to fusion surgeries for Adolescent Idiopathic Scoliosis improves the correction of the trunk deformity (rib hump).

A Comprehensive Classification of Adolescent Idiopathic Scoliosis

Hiroshi Kuroki, MD; Etsuo Chosa, professor; Naoya Tajima

A comprehensive classification of AIS is presented with three types based on magnitude O-10-29 degrees, B-30-40 degrees, and F->40 degrees.; three groups single curve (S), double curve (D), or triple curve (T); and three subgroups based on apical location, thoracic (T or t), thoraco-lumbar T-l or t-l), or lumbar (L or l). Upper case indicates fusion and lower case unfused. Further specification includes observation subgroups based on angle of trunk rotation 1- <5 degrees ATR, 2- 5 degrees or >ATR, 3- 7 degrees or >ATR; Non-operative subgroups 1- TWIII E / Sauvegrain 0, 2- TWIII F or G / Sauvegrain 1, TWIII H / Sauveg|rain 7; Operative subgroups 1- one curve or spinal region fused, 2- two curves or spinal regions fused, 3- three curves or fusion of a double thoracic curve more than one segment into the lumbar spinal region.

Demineralized Bone Matrix Strips Result in Earlier Fusion for Treatment of Adolescent Idiopathic Scoliosis

Tucker A. Drury, MD; S. Elizabeth Ames, MD; Kerry Costi, BA; Bruce Beynnon, PhD; Jonathan Hall, BS

We compared the clinical and radiographic results of posterior spinal fusion (PSF) with allograft versus demineralized bone matrix (DBM) strip augmentation for the treatment of AIS. DBM strips and cancellous allograft chips are both viable alternative bone grafts for PSF in the AIS population, with DBM resulting in a faster time to fusion.

Multicenter Analysis of the Operative Treatment of Adolescent Idiopathic Scoliosis: Prospective and Consecutive Analysis of 534 Patients

Ignacio Regidor, Staff; Gema de Blas, MD, PhD; Sergio Garcia-Urquiza; Elena Montes; Prof. Carlos Barrios; Eduardo Hevia; Jesus Burgos

This is the largest, most complete, state-of-the-art, digitized AIS multicenter database developed thus far. All patients had preoperative, first follow-up, and a minimum 2-year radiographic and clinical outcomes data as well as perioperative, early, and late postoperative complications reported. PT, MT, and TL/L Cobb correction averaged 40%, 60%, and 63% at 2-year follow-up. Perioperative, early postoperative, and 2-year postoperative complication rates averaged 9%, 11.9%, and 11.9% respectively. Total SRS Outcome scores improved significantly.

Rod Diameter Affects Sagittal but not Frontal Plane Curve Correction: An Analysis of Post Operative Outcomes of 1019 Patients with Adolescent Idiopathic Scoliosis

Xu Sun, PhD; Prof. Winnie C.W. Chu, FRCR; Prof. Jack Chun Yiu Cheng, MD; Prof. Zezhang Zhu, MD; Prof. Bin Wang, MD; Prof. Yang Yu, MD; Prof. Bangping Qian, MD; Feng Zhu, PhD; Weiwei Ma; Prof. Yong Qiu, MD

Retrospective review of radiographs after posterior spinal fusion (PSF) in adolescent idiopathic scoliosis (AIS) demonstrated no significant difference in frontal plane curve correction when comparing different rod construct diameters.

What is the 'Best' Surgical Approach for a Lenke 1 Main Thoracic Curve? Results of a Prospective, Multi-Center Study.

Prof. Matthew B. Dobbs, MD; Farhang Alaei, MD; Lawrence G. Lenke, MD; Keith H. Bridwell, MD; Timothy Kuklo, MD, JD; Scott J. Luhmann, MD; Christina A. Gurnett, MD PhD

A prospective comparison of outcomes for 3 surgical approaches for primary right thoracic curve pattern (Lenke type 1) showed that 2 year post-op outcomes were similar. There were measurable advantages for both the thoracoscopic and posterior approaches compared to the open anterior technique.

What Radiographic and Clinical Factors Appear Crucial for the Decision to Perform a Selective Thoracic Fusion in Lenke 1-King II Adolescent Idiopathic Scoliosis Curves?

Ruben A. Maenza, MD; Santiago Bosio, MD; Miguel Puigdevall, MD; Jorge Hokama

This study highlights the importance of lumbar preoperative TL/L Cobb angle measures, as well as the AVT difference between the MT and TL/L curves as critical components to the decision of whether to perform an ST or NS fusion in Lenke 1C/King II curves. Clinical parameters (scoliometer measurements) seem less important.

Posterior Correction of Adolescent Idiopathic Scoliosis: Which Preoperative Flexibility Radiograph Best Predicts the 2-year Result?

Amer F. Samdani, MD; Ashish Ranade, MD; JahanGir Asghar, MD; Patrick J. Cahill, MD; M. Darryl Antonacci, MD, FACS; David H. Clements, III, MD; Randal R. Betz, MD

No previous study has investigated the ability of preoperative flexibility radiographs to predict final postoperative correction of adolescent idiopathic scoliosis with pedicle screw instrumentation. In this series, the push-prone radiographs provided the most accurate correlation to the 2-year postoperative result. A greater correction is obtained with modern pedicle screw constructs than is predicted based upon flexibility radiographs alone.

Pedicle Screw Constructs Optimize Thoracic and Lumbar Clinical Appearance by Scoliometer Assessment versus Hook and Hybrid Constructs following Adolescent Idiopathic Scoliosis Surgery

Paul M. Tsou, M.D.; Jeffrey C. Wang, MD; Larry Khoo, MD; Langston Holly, MD; A. Nick Shamie, MD

Pedicle screw constructs optimize thoracic and lumbar clinical appearance, via scoliometer readings, versus hook and hybrid constructs. Furthermore, the pedicle screw group outcomes were superior even to those hybrid patients who underwent a thoracoplasty. Pedicle screw constructs provide superior radiographic and clinical correction of AIS at a minimum 2-year follow-up.

Do Variants in the Estrogen Receptor Gene Explain the Increased Incidence and Severity of Adolescent Idiopathic Scoliosis in Girls?

Vidyadhar V. Upasani, MD; Peter O. Newton, MD; Jeff B. Pawelek, BS; Tracey P. Bastrom, MA; Harry L. Shufflebarger, MD; Paul D. Sponseller, MD; Baron S. Lonner, MD; Suken A. Shah, MD; Harms Study Group

Adolescent idiopathic scoliosis (AIS) is generally more severe and occurs 5 times more frequently in girls compared with boys. As part of a genomewide association study single nucleotide polymorphisms in the ESR1 gene were examined for association with adolescent idiopathic scoliosis. No significant associations with adolescent idiopathic were observed.

Adolescents Undergoing Surgery for Adolescent Idiopathic Scoliosis (AIS): Does Surgery and Surgical Technique Affect Patient Outcomes?

Robert M. Campbell, Jr., MD; Andrew E. Auber, MD; Melvin D. Smith, MD; James W. Simmons, III, DO, PhD; Ajeya P. Joshi, MD; Stephen C. Inscore, MD, M.M.M.; Barry R. Cofer, MD; John J. Doski, MD; Robert P. Thomas, MD

Patient outcomes were compared amongst thoracoscopic & posterior instrumented patients, patients who did not have surgery, and normal subjects. Pain scores after surgery were similar to those that did not have surgery but self-image scores after surgery were the same as that of normal subjects. Thoracoscopic surgery compares favorably to that of posterior surgery.

Thoracic Sagittal Curve and Proximal Junctional Kyphosis in Adolescent Idiopathic Scoliosis after Pedicle Screw Instrumentation

Seung Hwan Yoon, MD; Valerie Ugrinow, BA; Vidyadhar V. Upasani, MD; Jeff B. Pawelek, BS; Peter O. Newton, MD

A total of 156 adolescent idiopathic scoliosis patients using pedicle screw instrumentation were analyzed to evaluate the sagittal curve with proximal junctional change. The preoperative thoracic kyphosis of $18.8 \pm 9.8^\circ$ and proximal junctional sagittal angle of $6.9 \pm 5.5^\circ$ were increased to $26.2 \pm 9.9^\circ$ and $8.7 \pm 6.6^\circ$, respectively. Abnormal proximal junctional kyphosis was found in 4 patients (2.5%), 3 of whom had TL/L curve and one had preoperative thoracic hyperkyphosis. Pedicle screw instrumentation restored thoracic kyphosis satisfactorily. The proximal fusion level should be carefully determined in patients with thoracic hyperkyphosis or TL/L curve.

The Role of Halo Extension in the Treatment of AIS

Lawrence L. Haber, MD; Joshua D. Hughes, BA; Jennifer Barr, MD
Retrospective single center study of 20 patients with severe ($>80^\circ$) or rigid (flexibility $<35\%$) AIS treated pre-operatively with halo traction and instrumented with thoracic pedicle screws compared to a multicenter matched control group treated without traction and hybrid instrumentation.

Evaluation of Digital Radiographs for Interobserver and Intraobserver Agreement

Vidyadhar V. Upasani, MD; Reid Chambers, BA; Suken A. Shah, MD; Ronald A. Lehman, Jr., MD; Valerie Ugrinow, BA; Andrew Mahar, MS; Peter O. Newton, MD

Intraobserver and Interobserver data will be collected over a 9 week period by 4 observers and k values determined for digital radiographic measurements obtained on a software program called Radian.

Treatment of Idiopathic Scoliosis at Severe Curves by Only Posterior Approach

Theodoros B. Grivas, MD; Georgios Rodopoulos; Georgios G. Triantafyllopoulos, MD

Twenty seven severe thoracic scoliosis that curves over 70 degrees treated by posterior thoracic fusion with segmental pedicle screw. Posterior instrumentation and fusion can provides sufficient treatment of severe rigid thoracic scoliosis without need any anterior surgery. Our end results are similar with anterior posterior fusion combined method when compared with the literature.

Anthropometry and Body Composition Profile of Girls with Non Surgically-Treated Adolescent Idiopathic Scoliosis

Jun Takahashi, MD; Hiroki Hirabayashi; Hiroyuki Hashidate; Nobuhide Ogihara, MD; Prof. Hiroyuki Kato

Different anthropometric and body composition parameters were measured in girls with AIS and compared with the standards of a healthy age-matched population. Scoliotic girls had a significant lower mean weight and BMI. A 21.2 % of scoliotic girls had BMI below 17.5 which has been considered the limit for anorexia. Somatotype differed also, being higher ectomorphy and lower mesomorphy components in AIS-patients. Idiopathic scoliosis not only disturbs the spine normal growth, but also has implications in the whole corporal development.

Surgical Trunk Rotation Correction in Patients with Moderate Thoracic AIS (< 75°): An All Pedicle Screw Construct with Derotation is Better than Thoracoplasty

Dino Samartzis, DSc, PhD (C), MSc; Jaro Karppinen, MD, PhD; Florence P. Mok, MSc; Daniel Y.T. Fong, PhD; Prof. Keith D.K. Luk; Prof. Kenneth Man Chee Cheung

In a retrospective comparison of the residual rib prominence in patients with direct vertebral body derotation, thoracic curves less than 75° and curve flexibility greater than 50% exhibited a larger percent correction of the rib prominence at two years than a similar group with thoracoplasty.

Immediate In-Brace Correction is a Key Factor for the Effectiveness of Brace Treatment in AIS

Dino Samartzis, DSc, PhD (C), MSc; Jaro Karppinen, MD, PhD; Florence P. Mok, MSc; Daniel Y.T. Fong, PhD; Prof. Keith D.K. Luk; Prof. Kenneth Man Chee Cheung

1024 different brace designs were tested on three patients. A correlation was found between the immediate in-brace correction and the corrective bending moment applied at the apical level. The immediate correction necessary to expect a positive outcome for the treatment depended on the flexibility of the spine. It confirms the importance of immediate in-brace correction because of its capacity to counterbalance the growth deformation process.

Anterior Spinal Fusion for Thoracolumbar Scoliosis: Comprehensive Assessment of Radiographic, Clinical, and Pulmonary Outcomes at 2 Years

Iris Busscher, MD; Albert J. van der Veen, MSc; Prof. Jaap H. van Dieen, PhD; Gerdine J. Meijer, MSc; Prof. Bart Verkerke, Prof. ir.; Prof. Albert G. Veldhuizen

Anterior spinal approaches to thoracolumbar curves facilitate powerful coronal curve correction and derotation, short segment fusions and saving of distal levels, and reduced blood loss. Recent evidence suggests, however, that approach-related pulmonary function impairment may limit the utility of this approach. We report 74% thoracolumbar/lumbar curve correction at 2 years, 42% unfused thoracic curve correction, significant improvements in lordosis, apical trunk rotation, and SRS scores, maintenance of kyphosis, with no changes in per cent predicted FEV1 and FVC.

Traditional Hybrid versus Thoracic Pedicle Screw Instrumentation in Adolescent Idiopathic Scoliosis: A Matched Pair Analysis of Clinical, Radiographic, and Pulmonary Outcomes

Serkan Bilgic, MD; Huseyin Ozkan; Yuksel Yurttas, Assistant Professor; Mustafa Kurklu, Assistant Professor; Matthew E. Cunningham, MD PhD; Ali Sehirlioglu

There is continued concern that the added costs and potential safety issues associated with thoracic pedicle screws (TPS) in the treatment of adolescent idiopathic scoliosis (AIS) may not be worth the incremental radiographic and equivocal clinical benefits over traditional Hybrid posterior spinal fusion. We report that the potential advantages of TPS over Hybrid include saving 1.4 distal levels, greater thoracic and compensatory lumbar curve correction, and slightly greater peak flow at 2 years. No clinical differences were detected.

Genetic Variants in the CHD7 Gene Show No Association in a Large Study of the Genetics of Adolescent Idiopathic Scoliosis (AIS)

Naoatsu Megumi; Koki Uno, MD, PhD; Hiroshi Miyamoto, MD; Yoshihiro Inui; Ko Tadokoro; Yoshiyuki Okada, MD; Sya Norihide

As part of a genomewide association study single nucleotide polymorphisms in the CHD7 gene were examined for association with adolescent idiopathic scoliosis. No significant associations with adolescent idiopathic were observed.

Rib and Lumbar Hump Correction after Selective Thoracic Fusion – A Comparison Between Thoracoscopic Instrumented Fusion and Posterior Instrumented Fusion with Thoracoplasty

Tai-Li Chang; Paul D. Sponseller, MD; Khaled Kebaish; Elliot K. Fishman, MD

This study compares the effect of thoracoscopic anterior instrumentation and conventional posterior instrumented fusion with thoracoplasty. Thoracoscopic instrumented fusion resulted in significant reduction in rib and lumbar hump which is comparable to posterior instrumented fusion with thoracoplasty.

Psychological Aspects of Scoliosis Surgery in Children

Eric H. Buchl, MPAS, PA-C; Chantelle M. Freeman, B.S.; Richard A. Hostin, MD; Eric Sims, MPAS; Shaun M. Shore, MS Physician Assistant Studies; Alexis P. Shelokov, MD

Spinal deformity which requires surgical intervention touches a considerable portion of the child and youth population. Children on the surgery ward rarely have the possibility of meeting with a psychologist to get support in this often difficult situation. As we know, not all children can manage their pain on their own and release the anger born out of their situation in a constructive way

Proximal Thoracic Curve Behavior and Coronal Balance after Thoracoscopic Instrumented Fusion for Adolescent Idiopathic Scoliosis - A Longitudinal Study with 2 Year Followup

Jim S. Yeom, MD; Jacob M. Buchowski, MD, MS; Hong Xing Shen, MD; Gabriel Liu, MB Bch MSc FRCSEd(orth); Torphong Bunmaprasert, MD; K. Daniel Riew, MD

Thoracoscopic instrumented fusion resulted in sustained spontaneous proximal thoracic curve (PT) correction. The magnitude of main thoracic curve correction strongly influenced PT-curve correction. Side-bending radiographs were not predictive of post-operative PT-curve correction. No patient had more than 2cm of C7 translation post-operatively.

Comparison Continuous Bupivacaine Wound Infiltration with Intravenous Analgesia in Postoperative Pain Treatment after Scoliosis Procedure

Hong Xing Shen, MD; Jacob M. Buchowski, MD, MS; Jim S. Yeom, MD; Gabriel Liu, MB Bch MSc FRCSEd(orth); K. Daniel Riew, MD

Operations of the spinal curvatures depends on correcting and spine deformation and putting stable orthopedic fixation. All these procedures persist long time, traumatize tissue with high range and induce a lot of blood loss. Post operative treatment of consist also pain management.

A Review of Alternative Non-Surgical Treatment Options for Adolescent Idiopathic Scoliosis (AIS) on the Internet

Lauren Winslow, BS; Michael J. Bolesta, MD; Kevin Gill, MD
There is a wide range of alternative non-surgical treatment options for AIS advertised on the internet. However, high level evidence supporting their effectiveness is lacking.

Are Bicortical Pedicle Screws Safe?

Yongjung J. Kim, MD; Keith H. Bridwell, MD; Lawrence G. Lenke, MD; Youngbae B. Kim; Young-Joon Ahn

Bicortical pedicle screws can be used in a safe manner with no risk to major organs or vessels.

Optimization of the Fluid Management and Blood Transfusion Strategies during Adolescent Scoliosis Surgery

Eric C. Parent, P.T., MS c., PhD; Daniel L. Wong; Douglas L. Hill, P.Eng, MBA; Marc Moreau, MD FRCS(C); James Mahood; Jim Raso, M.A.Sc.; Edmond Lou, PhD

Optimization of the fluid management and use of the other blood conservation techniques allows early extubation, significant decrease in postoperative complications and elimination of homologous blood transfusion in adolescent idiopathic scoliosis correction with pedicle screws.

Antero-Posterior vs Posterior-Only Surgery in Thoracic AIS Curves Exceeding 60 Degrees. Results of a Match Pair Analysis

Sarah D. Hans, BA; Daniel R. Cooperman; James O. Sanders, MD

Currently, there is still no consensus regarding the indication of ASR in large and rigid curves. This is the first study comparing the radiographic outcome between a staged antero-posterior surgery and a single posterior approach with concave thoracoplasty (CTP). Our analysis showed, that there was no significant difference of the correction rate between the APSF and the PSF group.

3D Torso Surface Topography Corrections Related to Surgical Treatment of Scoliosis For Idiopathic-Type Curves

Bidre Upendra, MS; Pankaj Kandwal, MS; Ajay Kumar, MS; Prof. Arvind Jayaswal, MS

Surface deformity is often the primary patient complaint in scoliosis, and surgical treatment may not satisfactorily correct the surface deformity. This study assessed changes in 3D torso surface topography (ST) associated with scoliosis correction (13 subjects). Using a torso imaging system, changes in 11 ST indices - corresponding to Cobb angle changes resulting from scoliosis correction - were evaluated. Curve correction (35 degrees) was primarily correlated to transverse ST indices. Only 32% of torsos were corrected within a normal range.

Efficacy of All Screw Constructs in Correcting Rib Hump in Idiopathic Scoliosis

Arnaud Soubeiran, PhD; Lotfi Miladi, MD; Thierry Odent, MD; Vincent Cunin; Prof. Jean Dubousset

This is a prospective study of 36 patients with AIS showing mean of 68% correction of rib hump deformity with all screw constructs without costoplasty.

Patient-Parent Perceptions of Shoulder Imbalance Following Surgical Correction For AIS

Jean-Paul Wolinsky, MD; Matthew J. McGirt, MD; Prof. Ziya L. Gokaslan, MD

In a large consecutive series of patients undergoing AIS surgery, there is general agreement between the patient and parent with respect to shoulder balance preoperatively. Parents and patients demonstrate improved satisfaction with shoulder discrepancy following surgical treatment and this correlates to the surgeon's assessment of shoulder discrepancy as well as radiographic parameters especially of the PT and MT curve.

Prognostic DNA Test Predicts Progression of Adolescent Idiopathic Scoliosis Regardless of Lenke Curve Pattern

Douglas G. Orndorff, MD; Aaron S. Dumont, MD; Prof. Vincent Arlet, MD

We tested whether a panel of DNA markers which can be used to predict progression of adolescent idiopathic scoliosis regardless of Lenke curve pattern. We found that the genetic markers used in this study predict a general tendency for AIS progression rather than a tendency to develop a particular curve pattern.

Autologous Cell Salvage as Part of a Total Blood Conservation Policy in Instrumented Correction and Fusion for Scoliosis.

Brett A. Freedman, MD; Timothy Kuklo, MD, JD; Lawrence G. Lenke, MD; B. Stephens Richards, MD; Daniel J. Sucato, MD MS; David W. Polly, Jr., MD

Avoidance of homologous blood transfusion during the peri and postoperative period during scoliosis surgery is a desirable goal for all scoliosis surgeons. We report on the use of an autologous cell salvage drain (Bellovac™, Astra Tech, UK) in the six hour post operative period following instrumented scoliosis correction and fusion as a means of minimising the need for homologous blood transfusion.

Comparison of Cobb Angles in Idiopathic Scoliosis on Standing Radiographs and Supine Axially Loaded MRI.

Brett A. Freedman, MD; Takahiko Hamasaki, MD; JinHwan Kim, MD, PhD; Timothy Kuklo, MD, JD; Prof. William C. Hutton, DSc; William Horton, MD; S. Tim Yoon, MD, PhD

Children and adolescents with idiopathic scoliosis are exposed to repeated radiographic examinations which may pose risks for serious pathologies later in life. Supine MRI with axial loading gives similar Cobb angles as standing x-rays. This may be a way to follow scoliosis patients without exposure to radiation.

Direct Vertebral Rotation (DVR) Provides Better 3-D Correction of the Apical Vertebrae than Rod Translation in Adolescent Idiopathic Scoliosis

Ronald A. Lehman, Jr., MD; Lawrence G. Lenke, MD; Kathryn A. Keeler, MD; Melvin D. Helgeson, MD

Three dimensional correction of deformity is a desired goal of scoliosis surgery. Different maneuvers have been utilized to achieve this goal. This a retrospective study comparing two different techniques utilizing all pedicle screw constructs.

Factors that Influence Retention in a Prospective Paediatric Scoliosis Surgery Study

Ronald A. Lehman, Jr., MD; Melvin D. Helgeson, MD; Jeanne Patzkowski, BS; Michael Rosner, MD

Patient retention is essential to study validity. We evaluate the Prospective Pediatric Scoliosis Study (PPSS), a prospective, consecutive, multicenter database of 1655 patients who underwent surgical correction of adolescent idiopathic scoliosis, for factors associated with patient retention.

Effect of Vertebral Location and Rotation on Screw Placement

Tsuji Taichi; Noriaki Kawakami, MD; Kazuyoshi Miyasaka; Tetsuya Ohara; Ayato Nohara

The cephalocaudal foundation screws and periapical screws were reviewed for placement. 52 patients were studied. The study found the cephalad foundation had more malpositioned screws.

Results of the Canadian Pediatric Spinal Deformity Study Group of Surgical Techniques and Peri-Operative Care for Adolescent Idiopathic Scoliosis

Suken A. Shah, MD; Paul D. Sponseller, MD; Peter O. Newton, MD; Mark F. Abel, MD; Lynn Letko, MD; Daniel J. Sucato, MD MS; Randal R. Betz, MD; Harms Study Group

Significant variation exists in techniques and philosophies in care of pediatric AIS. A questionnaire was sent to members of the CPSDS to determine individual practices and areas of controversy (AOC). AOC were identified in bone graft techniques, blood conservation strategies, neuromonitoring, radiographs, drains, instrumentation used, and indications for anterior surgery. This questionnaire provides useful information in the practices of surgeons treating pediatric spinal deformity. Highlighted AOC provide potentials for multi-centered research.

Combined Antero-Posterior Compared to Posterior-Only with the Use Of Skull-Skeletal Traction in the Correction of Adolescent Idiopathic Scoliosis Curves Greater than 75 Degrees

Toru Maruyama, MD, PhD; Tomoaki Kitagawa; Katsushi Takeshita, MD

Intra-operative skull-skeletal traction has been used to facilitate correction of large scoliotic deformities. A retrospective review of 20 consecutive AIS patients undergoing anterior/posterior corrections were compared to 16 consecutive patients treated with intra-operative traction and posterior-only correction. Anterior-posterior correction is associated with significantly more morbidity and need for transfusions than posterior-alone with traction for high magnitude AIS curves. There was no significant difference in the final Cobb angle amongst these groups.

Perioperative Differences Between Hybrid Instrumentation and All Pedicle Screw Instrumentation in AIS

Melvin D. Helgeson, MD; Ronald A. Lehman, Jr., MD; Ryan Sieg, BS, MS; Michael Rosner, MD; Carlo Bellabarba; Patrick B. Cooper, MD

This retrospective study found that pedicle screw systems were superior for perioperative parameters when compared to hybrid systems.



Multivariate Analysis of Factors Associated with Kyphosis Maintenance in AIS Surgery

Frank J. Schwab, MD; Ashish Patel, MD; Virginie Lafage, MD; Nicola Hawkinson, BSN, MA, NP; Jean-Pierre Farcy, MD

Kyphosis maintenance or restoration is an important goal of AIS surgery. In a multivariate analysis we noted anterior approach and lesser magnitude of kyphosis preoperatively were associated with greater increases in kyphosis and longer fusions were associated with loss of kyphosis.

Segmental Pedicle Screw Fixation with Convex Direct Vertebral Rotation for Correction of Adolescent Idiopathic Scoliosis

Ronald A. Lehman, Jr., MD; Lawrence G. Lenke, MD; Timothy Kuklo, MD, JD; B. Stephens Richards, MD; Keith H. Bridwell, MD; Spinal Deformity Study Group; Melvin D. Helgeson, MD

To examine the efficacy of pedicle screw fixation and direct vertebral rotation (DVR) utilizing convex pedicle screws as treatment of right thoracic adolescent idiopathic scoliosis (AIS).

Are Radiographic Measurements of Spine and Chest Deformity Predictive of Pulmonary Function in Severe Idiopathic Scoliosis?

Virginie Lafage, MD; Frank J. Schwab, MD; Ashish Patel, MD; Nicola Hawkinson, BSN, MA, NP; Jean-Pierre Farcy, MD

Although many patients with severe idiopathic thoracic scoliosis have pulmonary impairment a significant portion maintain normal capacity. When curves are large, small changes in the distance between the spine and lateral chest wall can significantly diminish the space for the convex lung and thus impair pulmonary function.

ADULT SPINAL DEFORMITY

Degenerative Scoliosis: Long Constructions through Minimally Invasive Lateral Approach Using a Lateral Plate

Frank J. Schwab, MD; Virginie Lafage, MD; Ashish Patel, MD; Jean-Pierre Farcy, MD; Keith H. Bridwell, MD; Steven D. Glassman, MD; Michael Shainline, MS

Symptomatic adult scoliosis deformity presents as a difficult problem to solve, we show 44 patients who underwent to XLIF procedure to correct this deformities with short surgical time, indirect decompression and early recuperation with an increased satisfaction overall.

Scoliosis Management Using External Fixator

Harry L. Shufflebarger, MD; Angel Macagno, MD; Michael O'Brien, MD

Distraction osteosynthesis method is applied in treatment of patients with scoliosis. Before surgery all patients had radiographic, esthesiometric and electromyographic examination. External respiration function was also studied. Surgery was performed in 2-3-4 stages. In evident cosmetic defect, subperiosteal rib hump resection was performed during the first stage. In the second stage of surgery screw rods were inserted transpedicular above and below apex of scoliotic arch. Then three-dimensional correction of spinal deformity was performed using the external fixator. At the third stage of treatment the surgery was performed for stabilization of achieved correction.

Outcomes after Surgical Correction of Spinal Deformity in Adults with Concomitant Hip Osteoarthritis

Chan W. Peng, MD; John A. Bendo, MD; Jeffrey Goldstein, MD; Matthew M. Nalbandian, MD

The presence of hip pain in patients with adult spinal deformity affects the clinical outcomes of these patients after surgical correction of their deformity. Hip pain should be evaluated and treated pre-operatively to optimize improvement in outcomes after deformity correction in the adult patient.

Comparative Radiographic Analysis of the Sagittal Spinopelvic Alignment Between 100 Asymptomatic Adults and 100 Sagittally Imbalanced Patients: What are the Critical Radiographic Parameters?

Rick C. Sasso, MD; John G. Heller, MD; Paul A. Anderson, MD; Stephen Papadopoulos; Richard G. Fessler, MD, PhD

Sagittal standing radiographs of the whole spine and pelvis in 200 adults (100 asymptomatic volunteers, 100 sagittally imbalanced patients who had a subsequent balancing operation) demonstrated useful parameters for the evaluation of sagittal imbalance as well as considerations for correction of sagittal imbalance. The T12-horizontal angle and summation of pelvic incidence, thoracic kyphosis, and lumbar lordosis were the most correlative.

Predicting Surgical Outcome by Change in Critical Parameters of Thoracolumba-Lumbar Spinal Deformity in Adults

Debdut Biswas; Jesse E. Bible, BS; Peter G. Whang, MD; Andrew K. Simpson, MD; Jonathan N. Grauer, MD

Surgery for treatment of adult spinal deformity carries significant risk. To determine which patients can benefit from surgery it is important to build models for predicting post-operative outcome. This study demonstrates that patients most disabled before surgery, and who experience Classification category change (structural improvement) are most likely to report improved function two years after surgery. The ability to model and predict outcomes will offer reliable treatment algorithms for these complex patients in the future.

Sacropelvic Fixation using the Transilial Bar Technique in Adult Spinal Deformity

Dzung H. Dinh, MD, MBA

The transilial bar technique is an easy, safe and effective method for achieving and maintaining sacral pelvic fixation in long posterior spinal instrumented fusion for adult deformities.

Results of Surgical Treatment of Adult Scoliosis with Spinal Stenosis

Takashi Kusakabe; Robert W. Gaines, Jr., MD

Lumbar spinal stenosis usually presents with a combination of neurogenic claudication and radiculopathy, associated to back pain and progression of the deformity. We evaluated 28 adult patients who underwent elective surgery for spinal stenosis and scoliosis with an average follow-up of 8 years. Improvement of the deformity was obtained both coronal and the sagittal plane. Significant pain relief, functional improvement and satisfaction with the surgery can be achieved and maintained over the long term in the properly selected patients.

The Pedicle Screw Fixation with Vertebroplasty Augmentation in the Surgical Treatment of Lumbar Spinal Stenosis Associated with Deformity in the Presence of Severe Osteoporosis

Hitesh N. Modi, MS, Orthopedics; Prof. Seung-Woo Suh, MD, PhD; Jae-Hyuk Yang, MD

The clinical and radiological results of pedicle screw fixation augmented by vertebroplasty using polymethylmetacrylate in severely osteoporotic patients undergoing surgery due to lumbar spinal stenosis associated with deformity in 27 patients between the years 2004-2006 showed 75% correction in scoliosis and complete relief of their nerve compression symptoms.

Proximal Junctional Kyphosis after Posterior Spinal Fusion in Idiopathic Thoracolumbar Scoliosis: Is it Safe for Sagittal Plane to End at the Lower Thoracic Region?

Xusheng Qiu, PhD; Weiwei Ma; Weiguo Li, PhD; Prof. Bin Wang, MD; Prof. Yang Yu, MD; Prof. Zezhang Zhu, MD; Prof. Bangping Qian, MD; Feng Zhu, PhD; Xu Sun, PhD; Bobby Kin-wah Ng; Prof. Jack Chun Yiu Cheng, MD; Prof. Yong Qiu, MD

For this retrospective study, preoperative and postoperative radiographs of posterior spinal fusion for idiopathic thoracolumbar/lumbar curve were reviewed

Evidence Based Indication for a PEEK Flexible Rod for Dynamic Stabilization

Prof. Yong Qiu, MD; Biyu Rui, PhD; Prof. Zezhang Zhu, MD; Feng Zhu, PhD; Prof. Bin Wang, MD; Prof. Yang Yu, MD; Prof. Bangping Qian, MD; Weiwei Ma; Xu Sun, PhD

PEEK rods were evaluated in instrumented lumbar fusions with no loss of sagittal balance, lumbar lordosis, and no evidence of any effect on adjacent levels with an apparent earlier fusion of both the interbody and posterolateral gutter seen

Self Reported Measures of Health Status and Disability as Predictors of Operative vs. Conservative Management of Scoliosis in the Elderly.

Prof. Yong Qiu, MD; Prof. Zezhang Zhu, MD; Wei Jun Wang, mphil; Feng Zhu, PhD; Prof. Bin Wang, MD; Prof. Yang Yu, MD

The decision whether to pursue operative or conservative management for adults with scoliosis is complex and has not been fully characterized, especially for elderly patients who often present with the poorest health and greatest disability. Herein we investigate whether the degree of disability and self reported measures of health status among elderly patients with scoliosis are predictive of whether operative or nonoperative management will be pursued.

Short Segment Coronal Plane Deformity after Two-Level Lumbar Total Disk Replacement: Report of Three Cases

Guangquan Sun; Zhen Liu, PhD; Prof. Yong Qiu, MD; Prof. Zezhang Zhu, MD; Feng Zhu, PhD; Prof. Bangping Qian, MD; Prof. Yang Yu, MD; Prof. Bin Wang, MD; Xu Sun, PhD

We present our experience with three cases of failed two-level Charite disc arthroplasty due to coronal imbalance. The two cases from within our own state represent 28% of all two-level Charite arthroplasties performed with the state.

Novel Minimally Invasive Percutaneous Multilevel 360 Degree Fusion for Adult Lumbar Degenerative Scoliosis – Feasibility, Technique and Early Results

Satoshi Inami, MD; Hiroshi Taneichi, MD; Takashi Namikawa, MD, PhD; Daisaku Takeuchi; Nakayuki Katou; Takahiro Iida, MD; Yutaka Nakamura, MD; Tomoaki Kitagawa; Prof. Yutaka Nohara, MD

Minimally invasive technology was used to successfully perform multisegment deformity correction in the elderly

Minimally Invasive AxialLIF L5-S1 Interbody Fusion for Anterior Column Support at the End of a Long Segment Fusion

Gianluca Maestretti; Philippe Otten

Novel fusion technique successfully used for L5-S1 fusion at end of long construct

Extreme Lateral Interbody Fusion (XLIF) Safely Improves Segmental and Global Deformity in Large Adult Lumbar Scoliosis; Preliminary Results on 13 patients

Prof. Yang Yu, MD; Zhen Liu, PhD; Prof. Zezhang Zhu, MD; Feng Zhu, PhD; Prof. Bangping Qian, MD; Prof. Bin Wang, MD; Prof. Yong Qiu, MD

Extreme Lateral Interbody Fusion (XLIF) is a viable technique that safely allows interbody access to the scoliotic lumbar spine in a less invasive manner than traditional open multi-level lumbar approach. Early results show improved clinical outcomes as well as segmental and global correction for adult lumbar scoliosis. Postoperative transitory approach related leg symptoms resolved in all patients who had 6 months follow-up. There were no visceral or vascular complications associated with XLIF.

An Analysis of Presentation and Surgical Strategies in Spinal Instability in Ankylosing Spondylitis – a Review of 12 Cases

Hiroyuki Hashidate; Jun Takahashi, MD; Hiroki Hirabayashi; Nobuhide Ogihara, MD; Prof. Hiroyuki Kato

In ankylosing spondylitis unstable spinal lesions are common and may follow minor trauma. Incidence of neurological deficit is high. Occult nature of these lesions associated with the pain and deformity makes the diagnosis difficult. Surgical management though difficult may be rewarding, if performed judiciously. Results are comparable to those of the general population.

Reliability Analysis for Manual Radiographic Measures of Rotatory Subluxation or Lateral Listhesis in Adult Scoliosis

Konstantinos Kafchitsas; Prof. Michael A. Rauschmann

Rotatory subluxation (RS) is a hallmark of adult lumbar scoliosis, yet little has been written about its measurement. The purpose of this study was to test the inter- and intra-rater reliability of three specific measurement methods. Rotatory subluxation (RS) is a hallmark of adult lumbar scoliosis, yet little has been written about its measurement. The purpose of this study was to test the inter- and intra-rater reliability of three measurement methods. Of these, the centroid method tended to be most reliable; however, all three measures demonstrated excellent reliability, but yielded values which were significantly different for the same level measured ($p < 0.01$). Thus, spine surgeons should use one of these methods and remain consistent.

Reliability and External Validity of an Instrument to Assess Functional Effects of Stiffness Following Lumbar Spine Fusion

Per Ekman, MD; Hans Möller, MD, PhD; Adel Shalabi, MD, PhD; Prof. Yang Xiao Yu, MD; Prof. Rune Hedlund

To assess the impact of spinal stiffness on activities of daily living following lumbar fusion, we developed a questionnaire (Lumbar Stiffness Disability Index, LSDI) seeking information on these effects and assessed its reliability and external validity. The LSDI was administered to 32 participants. The LSDI demonstrated excellent internal consistency and retest reliability. This study demonstrates that the questionnaire is a reliable and valid instrument for assessing functional effects due to stiffness following lumbar spine fusion.

A Comparative Analysis of Thoracic Pedicle Pilot Hole versus Pedicle Screw Insertion Using A Novel Morphologic Landmark

Stefan Parent, MD, PhD; Marjolaine Roy-Beaudry, MSc; Marie Beausejour; Julie Joncas; Martin Forcier, MS c.; Sara Bekhiche; Guy Grimard; Hubert Labelle, MD

To describe a consistent morphologic landmark for thoracic pedicle pilot hole placement and to determine the relative accuracy of this technique for differing surgical skill levels. To correlate the accuracy of the pilot hole preparation with the final screw position for differing surgical skill levels.

Risk Factors for a Adjacent Level Disease after Long Thoracolumbar Fusions.

Javier Pizones, Consultant; Prof. Enrique Izquierdo, MD PhD; Felisa Sanchez-Mariscal, Consultant; Lorenzo Zuñiga; Patricia Alvarez, MD; Alejandro Gomez-Rice, Resident

33 patients with de novo scoliosis were analyzed after long thoracolumbar fusion for a adjacent level disease. Failure was associated with advanced age, higher pelvic incidence and change in thoracic kyphosis.

The Concept of the Minimal Clinically Important Difference: How Meaningful is it?

Gang Yin; Prof. Yong Qiu, MD; Zhen Liu, PhD; Feng Zhu, PhD; Prof. Ze Zhang Zhu, MD; Prof. Yang Yu, MD; Weiwei Ma; Prof. Bangping Qian, MD; Xu Sun, PhD; Prof. Bin Wang, MD

The minimum clinically important difference (MCID) represents the smallest improvement considered worthwhile by a patient. The concept of the MCID is offered as a new standard for determining the effectiveness of a given treatment. The primary aim of this study is to establish the threshold at which the MCID occurs for patients with spinal deformity on the SF-36, SRS-30, and ODI.

Minimally Invasive Correction of Spinal Deformity

Zhen Liu, PhD; Prof. Bin Wang, MD; Prof. Yong Qiu, MD; Qiang Sun, PhD; Xu Sun, PhD; Weiwei Ma; Feng Zhu, PhD; Prof. Bangping Qian, MD; Prof. Ze Zhang Zhu, MD; Prof. Yang Yu, MD

This paper demonstrates that adult spinal deformity can be successfully treated with minimally invasive approaches and achieve similar correction goals to open surgical techniques.

Spinopelvic Alignment and Implications for Iatrogenic Flatback Deformity

Prof. Bin Wang, MD; Zhen Liu, PhD; Prof. Yong Qiu, MD; Qiang Sun, PhD; Xu Sun, PhD; Weiwei Ma; Feng Zhu, PhD; Prof. Bangping Qian, MD; Prof. Ze Zhang Zhu, MD; Prof. Yang Yu, MD

Recent studies demonstrated that abnormalities in spinopelvic parameters, including elevated pelvic incidence, contribute to deformities including spondylolysis with progressive spondylolisthesis. This study evaluated whether abnormalities in spinopelvic alignment are present in 18 patients with an iatrogenic flatback deformity. Compared with age-matched control patients, patients in the iatrogenic flatback deformity group had a specific spinopelvic profile with elevated PI; increased PT, which reflects increased pelvic retroversion, a compensatory mechanism to limit overall kyphosis; and reduced TK to also limit kyphosis. Overall, elevated PI may be a risk factor for developing flatback deformity.

Restoration of Lumbar Lordosis Following Transforaminal Lumbar Interbody Fusion (TLIF)

Mladen Djurasovic, MD; Steven D. Glassman, MD; John R. Dimar, MD; Mitchell J. Campbell; Rolando M. Puno, MD; John R. Johnson; Leah Y. Carreon, MD, MSc

The ability of the TLIF operation to restore lumbar lordosis is controversial. This study examines the short- and long-term efficacy of TLIF in lordosis correction.

Evaluation and Management of Abdominal Lymphoceles Following Anterior Lumbar Spine Surgery

Samuel Kadoury, M.Eng.; Marie Beausejour; Farida Cheriet, PhD; Ian A. Stokes; Hubert Labelle, MD

This paper examines the management of lymphoceles following thoracolumbar spine surgery

Clinical and Radiographic Evaluation of Sagittal Imbalance: A New Radiographic Assessment

Todd Ritzman, MD; Claire Robertson, BS; Andrew Mahar, MS; Peter O. Newton, MD

A case series study describes a new radiological evaluation of the sagittal imbalance. The purpose of the current study was to review the clinical and radiological assessment of the sagittal imbalance and to introduce a new radiological evaluation that helps in ruling out hip flexion contracture as the primary cause of the sagittal imbalance and the type and level of spinal osteotomy required to regain the sagittal balance.

A Comparison between Thoracic Pedicle Subtraction Osteotomy and Posterior Vertebral Column Resection for the Treatment of Fixed Sagittal Deformity

Juan Bago, MD, PhD; Francisco J.S. Perez-Gruoso; Esther Les, RN; Pablo Hernandez, MD

In the proximal and midthoracic spine, thoracic VCR is a more powerful corrective technique than thoracic PSO. In the distal thoracic spine, there is less of a difference between PSO and VCR, and therefore either may be performed to achieve a significant focal sagittal correction. Both procedures can be performed safely and neurophysiologic monitoring should be utilized.

Hip Spine Syndrome: Coronal and Sagittal Spinopelvic Alignment

Matthew D. Hepler; Hyung-Soon Park; Jason Hsu; Prof. Li-Qun Zhang, PhD

Two hundred seven patients of hip spine syndrome (HSS) were evaluated coronal and sagittal alignment by coronal and sagittal spinopelvic alignment technique. The spinopelvic alignment technique was found to be very effective for the assessment of the HSS. In this study, it was shown that there was the significant correlation between pelvic morphology and lumbar lordosis, and the secondary HSS had various coronal and sagittal spinopelvic alignments as well as the alignments were originally reported by Macnab.

Rigid Neglected Scoliosis – Management Strategies.

Geoffrey A. Cronen, MD; Lawrence G. Lenke, MD; Lukas P. Zebala, MD; Daniel S. Mulconrey, MD; Peter S. Rose, MD; Keith H. Bridwell, MD

In developing and underdeveloped countries there is still a large chunk of scoliosis that present late – about 30-40% in our practice. Long standing curves become rigid (little or no flexibility), have increased cobb's angle (>80°) and are grossly rotated at the apex. These are not only cosmetically bad but are also difficult to correct. The management of these severe and rigid curves is often a challenge for the surgeon.

AGING SPINE

Spine Surgery in the Patient 80 Years of Age and Older

Frank L. Acosta, Jr., MD; Henry E. Aryan, MD; Christopher P. Ames, MD

Cervical and lumbar spine surgery for patients age 80 and older with stenosis carries very favorable results. The improvement in both neurologic deficits, as well as quality of life compares favorably to similar surgeries in younger populations.

Thoracic Laminoplasty using Artificial Lamina for Ossification of Yellow Ligaments

Jay Shapiro, Medical Doctor; John Williams, MD; Michelle Prince, MD; Kevin McHorse, PT, SCS, Cert. MDT; Jennifer Calaway, MSPAS; Suzanne Yandow, MD; Hassie E. Cooper

Twenty-nine cases of Th-OYL had been operated by thoracic laminoplasty using artificial lamina. All the cases had improvement soon after the operation. Radiological examination showed no progression of local kyphosis at the operated segments.

The Biomechanical Impact of Lumbar Pedicle Screw Re-Direction Following Lateral Wall Breach.

Matthew F. Gornet, MD; J. Kenneth Burkus; Anastasia K. Skipor, MS; Joshua J. Jacobs, MD

Lumbar pedicle screw (LPS) malpositioning occurs in >5-10% of cases, with lateral cortical breaches being most common. When a breach is detected intraoperatively, screw redirection is the most common corrective maneuver. This human cadaveric study shows that a redirected screw still maintains significant mechanical integrity, however, in comparison to a screw originally placed correctly (center-center) there is a significant reduction in screw purchase (~25%; p <.047)

Quantifying the Effects of Degeneration and Other Patient Factors on Lumbar Segmental Range of Motion Using Multivariate Analysis

Frances A. Farley, MD; Kelly Vanderhave, MD; Robert N. Hensinger, MD; Michelle S. Caird, MD

Multivariate analyses were utilized to assess the relationship between clinical variables and segmental ROM throughout the lumbar spine. Age had a significant negative association with ROM at L1/L2, L2/L3, L3/L4, and L4/L5. BMI had a significant negative association with ROM at L2/L3, L3/L4, and L4/L5. Degeneration at the level of interest had significant negative association with ROM only at L5/S1. Degeneration at adjacent levels, gender, weight, height, and smoking did not have a significant association with ROM at any level.

Posterior Instrumented Fusion in Elderly Spinal Deformities Over Age 60

Kota Watanabe, MD; Noriaki Kawakami, MD; Tsuji Taichi; Morio Matsumoto, MD

Thirty-three consecutive patients treated from 1993 to 2004 were included in this study: 30 females and 3 males. 21 patients were affected by a degenerative scoliosis, 6 presented a fixed sagittal imbalance, and 6 a flat back syndrome after previous instrumentation. In patients 60 years of age and older undergoing major spinal deformity surgery, overall outcomes were not adversely affected by age, comorbidities and complications.

Can Radiographic Measurements of Degenerative Lumbar Scoliosis Predict Clinical Symptoms?

Kota Watanabe, MD; Morio Matsumoto, MD; Noriaki Kawakami, MD; Tsuji Taichi; Prof. Yoshiaki Toyama; Kazuhiro Chiba, MD, PhD

This study correlates radiographic and clinical parameters of patients with degenerative lumbar scoliosis. Sagittal imbalance and moderate to severe rotatoryolisthesis are the most significant abnormalities affecting symptomatology of these patients.

Clinical Study of Transitional Syndrome after Long Instrumentation for Angular Kyphosis due to Osteoporotic Vertebral Collapse in Thoracolumbar region

Philip Neubauer, MD; Richard Skolasky, Sc.D.; Khaled Kebaish

This is a retrospective review of 8 patients with angular kyphosis and osteoporosis treated combined reconstructive surgery with a minimum 2-years follow-up.

Basic Science

Macroscopic Permeability of the Vertebral End Plate: Influence of Location, Fluid Flow Direction and Tissue Maturity

Panagiotis Korovessis, PhD, MD; Thomas Repantis, MD; Spyridon Zacharatos, MD

An experimental animal study of vertebral end plate macroscopic permeability is presented. The authors demonstrated the influence of location, fluid flow direction and tissue maturity on permeability

Effects of Dexametasone in Posterolateral Fusion on Lumbar Spine. Experimental Study in Rabbits.

Paul C. McAfee, MD; Prof. Bryan W. Cunningham, MSc; Mike Donohue, MD; Erin Shucosky, RN

Posterolateral lumbar spine fusion is a commonly used surgery. However, several facts may interfere in the bone fusion resulting in failure. Corticosteroids are among the substances which may alter the results of such surgery. It was experimentally observed which was the role of these drugs on the results of posterolateral fusion on lumbar spine. Twenty-one Norfolk adult rabbits were used. Through a medial skin incision at spine column it was reached transverse processes L5-L6 bilaterally. The transverse process were decorticated and corticocancellous bone graft was removed from the iliac crest and then put over the transversal processes. The animals were divided into two groups. Group I (control) was given saline solution, daily, for six weeks. Group II was given 0,10mg of dexametasone, daily, for six weeks. Three parameters were evaluated: radiological, manual palpation and mechanical testing. It was observed at manual palpation as well as at mechanical testing that dexametasone had a negative influence on posterolateral lumbar spine fusion in rabbits.

Influence of Posterior Asymmetrical Tethering on Macroscopic Permeability of the Vertebral End Plate

Paul C. McAfee, MD; Prof. Bryan W. Cunningham, MSc; Fred H. Geisler, MD, PhD

Nine skeletally immature pigs were instrumented with left pedicle screws and compression rod. The influence of a compression strain on the permeability of the vertebral end plate (VEP) has been investigated.

Anatomic Safe Zone for S2-Alar Screws

Paul C. McAfee, MD; Prof. Bryan W. Cunningham, MSc; Andrew Cappuccino, MD, BES

S2-alar screws can be safely and consistency placed as an alternative to iliac screws. The safe zone includes a lateral arc of 25-40° directed at the arcuate line of the sacral ala (30-45° in the sagittal plane). A complete understanding of the complex anatomy and critical structures, however, is important.

Identification of SRS 22r Domains Using Factor Analysis

Methodology

Masafumi Machida, MD; Prof. Jean Dubouset; Prof. Thoru Yamada, MD; Prof. Jun Kimura, MD

The structure of the domains of the SRS 22r health related quality of life questionnaire was studied using a principal component analysis with orthogonal rotation. This methodology confirmed the appropriate domain construct of the four non-management domains with good to excellent internal consistencies (0.8-0.9).

Smad-3 Null Mouse Exhibits Thoracic Kyphosis, Osteopenic Spine, and Degenerative Disc Changes

David L. Skaggs, MD; Gerald Bushman; Todd Grunander, MD; Pierre C. Wong, MD; Wudbhav N. Sankar, MD; Vernon T. Tolo

Evaluation of phenotypic abnormalities in the spine of smad3 KO mice revealed thoracic kyphosis, osteopenia, abnormal maturation of endplate chondrocytes and aberrant differentiation of annulus cells. These findings may model spine deformity and disc degeneration.

Magnesium in a Polyethylene Glycol Formulation Provides Neuroprotection after Acute Spinal Cord Injury

Mark Shillington, MBBS; Clayton J. Adam; Geoffrey N. Askin; Robert D. Labrom, MD

Magnesium's anti-excitotoxic properties have made it an attractive therapeutic candidate for a variety of neurotrauma conditions. In an animal model of acute spinal cord injury, we evaluated magnesium within a polyethylene glycol formulation. We observed that this magnesium formulation promoted functional recovery and reduced secondary damage within the cord (versus saline and methylprednisolone-treated animals), and was effective when administered as late as 4 hours post-injury. These promising findings have spurred the initiation of a clinical trial in acute human SCI.

Melatonin is Associated with the Activity of Osteoblast and Osteoclast in a Pinealectomized Experimental Scoliosis

Robert F. Heary, MD; Sanjeev Kumar, MD; Arvin Khetarpal, BS

We investigated that melatonin affect bone growth of vertebra bone for inducing scoliosis. The activity of osteoblast and osteoclast in posterior part of vertebra increased as compared with anterior part.

Architectural Studies of the Lumbar Paraspinal Muscles: Insights Into Muscle Design and Function

Prof. Yong Min Kim, MD, PhD; Byung Ki Cho, MD; Se Hyuk Im, MD

The lumbar spine is surrounded by a large group of muscles whose individual function is still unknown. Detailed microarchitectural studies in human multifidus, longissimus, iliocostalis, and psoas muscles are used to elucidate the design features of each muscle in an effort to better understand their individual roles in spinal motion and stability. The architectural design of the human multifidus muscle is to create large forces over short distances. Furthermore, in vivo sarcomere length measurements indicate that the multifidus muscle becomes stronger as the spine is flexed forward. These results suggest that the multifidus muscle is a major dynamic stabilizer of the human lumbar spine, exerting its maximal effect when the lumbar spine is in its most vulnerable position. The stiffness of the various muscles are predominantly determined by the surrounding connective tissue micro-environment and not the single fiber. These connective tissue is greatly affected by fatty infiltration of the muscle, which occurs with muscle injury during surgery.

The Initial Proteome Characterization of the Spinal Growth Plates in Idiopathic Scoliosis

Kei Watanabe, MD, PhD; Jose Miguel Lumawig, MD; Akiyoshi Yamazaki, MD; Tomohiro Izumi; Atsuki Sano

Study Design: proteomic analysis of growth plate of AIS
Methods: Growth plate cartilage was obtained from the curved bilateral with top column of the spine of the AIS and from normal region in congenital scoliosis (CS) patients in the intraoperatively. Cartilage preparation, extraction, mini-protease inhibitor cocktail (Roche) with shaking Insoluble material was removed by centrifugation. Cartilage extract prefractionation, 2-DE analysis and protein identification by MS/M. Result: Almost 110 spots were excised from the gels and analyzed using MALDI-TOF or MALDI-TOF/TOF. The analysis leads to the identification of 36 spots that represent 10 different proteins from all the identified proteins: Cofilin, Slingshot (SSH), Calgranulin B, Destrin, annexins I, vimentin, transgelin, cathepsin D, heat shock protein 47, and mitochondrial superoxide dismutase ect were more abundant in AIS than in normal person. Conclusion: Up-regulated protein of the spinal growth plates in AIS participate and as metabolic program of chondrocytes is altered in spinal growth plates. This proteomic map is an important tool for future studies on these pathologies.

Proteome Research of Acute Spina Injury by Two-Dimensional Gelelectrophoresis Analysis and Mass Spectrometry Identification

Jun Takahashi, MD; Hiroki Hirabayashi; Hiroyuki Hashidate; Nobuhide Ogihara, MD; Prof. Hiroyuki Kato

We performed proteomic analysis using 2-DE and MS to describe total proteins and differential proteins expression between normal group and SCI group. The study discovered 430 total proteins and analyzed 119 and 170 proteins from normal and injured group, respectively. There are up-regulated 29 proteins, 21 proteins showed reduction or disappear in the SCI group. We have identified 40 protein during the spinal cord injury, changed of the up-regulation, down regulation, and to disappear were play important role in the spinal cord injury.

Eliminating the SRS 30: Conversion of the SRS-24 and 23 to the SRS-22r Using Regression Modeling

Mehmet Aydogan; Cagatay Ozturk; Meric Enercan; Mehmet Tezer; Omer Karatoprak; Azmi Hamzaoglu

A prospective regression modeling analysis of the SRS 22r, SRS 23, and SRS 24 established conversion equations to estimate the SRS 22r from the earlier instruments with good to excellent R2 values

Assessment of Extraction Torque for Dual Acid Etched Lateral Mass Screws Inserted in Osteoporotic Sheep Cervical Spine

Marcelo Valacco; Marcelo Gruenberg; Carlos Solá; Matias Petracchi

The purpose of this study is to evaluate whether applying the DAE surface treatment to lateral mass screws can improve fixation at the bone screw interface in an osteoporotic sheep model.

L5 Segmental Artery Analysis Using Contrast-Enhanced 3Tesla MRA

Cagatay Ozturk; Mehmet Aydogan; Mehmet Tezer; Marco Brayda-Bruno; Neslihan Aksu; Azmi Hamzaoglu

This study uses 3 Tesla, contrast-enhanced MRA to evaluate the lumbar segmental arteries. 33% of the subjects demonstrated at least one normal or stenotic L5 segmental and only 2 of 36 subjects demonstrated bilateral (and both normal) L5 segmental arteries.

How Does Nucleus Pulposus Control The Annulus Fibrosis During Aging?

Mehmet Aydogan; Cagatay Ozturk; Marco G. Teli, MD; Murat Tonbul; Mehmet Tezer; Azmi Hamzaoglu

Our study provides a spatial and temporal map of expression of cell signaling pathways in the mouse intervertebral disc.

Cell Signaling Pathways For Maintenance And Closure Of Vertebral Growth Plates

Hitesh N. Modi, MS, Orthopedics; Prof. Seung-Woo Suh, MD, PhD; Jae-Hyuk Yang, MD

Our study provides a spatial and temporal map of expression in postnatal vertebrae, of signaling components known to be involved in fetal long bones.

MRI analysis of Rabbit Intervertebral Disc Degeneration Following Removal of Nucleus Pulposus cells

Prof. Ming Li, MD; Jianqiang Ni, MD; Suxi Gu; Xiaodong Zhu; Jingjie Wang; Shisheng He; Yongfei Zhao; Xiutong Fang, MD; Chuanfeng Wang

Removal of nucleus pulposus cells from the IVD of young rabbits resulted in degeneration of the disc as analyzed by MRI.

Bone Grafting

RhBMP-2 vs. Iliac Crest Bone Graft for Lumbar Spine Fusion: A Randomized Controlled Study in Patients over 60 Years of Age

Azmi Hamzaoglu; Cagatay Ozturk; Meric Enercan; Mehmet Tezer; Omer Karatoprak; Marco Brayda-Bruno

A randomized trial of rhBMP-2/ACS vs ICBG for posterolateral fusion in patients over 60 years old showed similar clinical outcomes in both groups. Lower fusion rates, more complications and revisions for nonunion were reported in the ICBG group. The mean total cost over two years was \$40,131 in the rhBMP-2/ACS group and \$42,574 in the ICBG group. RhBMP-2/ACS is a safe and cost-effective bone graft replacement for posterolateral fusions in older patients.

rhBMP-2 vs. Iliac Crest Bone Graft for Lumbar Spine Fusion in Patients over 60 Years of Age: A Cost-Utility Study

Ronald A. Lehman, Jr., MD; Lawrence G. Lenke, MD; B. Stephens Richards, MD; Timothy Kuklo, MD, JD; Keith H. Bridwell, MD; Spinal Deformity Study Group; Melvin D. Helgeson, MD

A cost-utility analysis was done using data from a prospective randomized controlled trial of rhBMP-2/ACS compared to ICBG. More complications, greater need for additional treatment and revision surgery for nonunion in patients receiving ICBG was seen compared to rhBMP-2/ACS. This may account for higher costs and lower improvements in utility seen in patients receiving ICBG compared to rhBMP-2/ACS. The cost of using rhBMP-2/ACS was \$39,967 with 0.11 improvement in SF-6D; for ICBG the cost was 42,286 with 0.10 improvement in SF-6D.

A Descriptive Analysis of Reactions with the Use of BMP in Posterior Interbody Fusions

Mohammad E. Majd, MD; Richard A. Kube, II, MD; Richard T. Holt, MD

This paper describes three types of reactions seen in posterior lumbar interbody fusions with the use of bone morphogenetic protein (BMP). The first reaction is an acute inflammatory reaction that presents with radicular symptoms. The second is described as cystic formation and the third as lytic lesions around the vertebral endplates. The paper further describes the demographics of the patients involved and the incidence of the three reactions.

A New DBM for instrumented spinal fusion PROGENIX An ongoing study for its use in instrumented Posterolateral Lumbar Fusions

John P. Lubicky, MD; Daniel J. Sucato, MD MS; John F. Sarwark, MD; Spinal Deformity Study Group; Elizabeth H. Riley, MIS, MLS
Progenix DBM is a new entrant in the field of DBM with the only one with proven clinical outcomes and radiographic confirmation of trabecular new bone formation and fusion in an instrumented spine fusion model.

Deminerilised Bone Matrix (DBM) as an Effective Adjuvant to Autograft in Spinal Fusion- Results Of Prospective Randomised Trail.

Timothy Kuklo, MD, JD; Mark Pichelmann, MD

Effectiveness of bone graft substitute as an adjuvant in achieving better spinal fusion rates.

Early and Mid Term Histological Events During Single-Level Posterolateral Intertransverse Process Fusion with rhBMP--ACS and a Ceramic Bulking Agent in a Non-Human Primate Model: Implications for Bone Graft and Fusion Bed Preparation

Hong Zhang, MD; Daniel J. Sucato, MD MS; Pamela Nurenberg, MD; Anna McClung, RN

rhBMP-2/ACS combined with osteoconductive bulking agents is capable of inducing posterolateral fusion. However, early histological events of rhBMP-2 induced bone formation with various bulking agents and preparation techniques have not been reported. Our results demonstrate de novo bone formation as early as 4-weeks with significant bone formation and ceramic remodeling at 12-weeks, in all rhBMP-2 groups.

Bone Morphogenetic Protein-2 (BMP2) And Bone Morphogenetic Protein-7 (BMP7): Combined Use In Complex Reconstructive Spine Surgery

Peter O. Newton, MD; Vidyadhar V. Upasani, MD; Christine L. Farnsworth, MS; Reid Chambers, BA; Shunji Tsutsui; Michael A. Slivka, MS c.; J. Riley Hawkins

A retrospective review of patients who received a combination of BMP2 and BMP7 in a posterolateral thoracolumbar fusion.

Use of BMP-2 in Posterior Cervical Fusion.

Prof. Bryan W. Cunningham, MSc; Nianbin Hu, MD; Jun Kikkawa, MD; Paul C. McAfee, MD

Use of BMP-2 to augment posterior cervical spinal fusion has not been tested. In this cohort, no significant complications were noted while obtaining increased fusion rate.

Patella Allograft for Anterior Cervical Interbody Reconstruction

Cagatay Ozturk; Mehmet Tezer; Mehmet Aydogan; Omer Karatoprak; Neslihan Aksu; Azmi Hamzaoglu

Patella allograft is a useful interbody device for the reconstruction of cervical deformity via an anterior approach.

Trends of On- and Off-Label INFUSE Use for Medicare and Non-Medicare Patients 2004-2007

Kariman Abelin; Brice Ilharreborde, MD; Yan Lefevre; Etienne Morel; Prof. Georges-françois Penneçot; Prof. Keyvan Mazda

Since 2003, INFUSE usage has more than tripled. In 2007, >169,000 units were used for spine fusions, at a cost of \$761 million dollars. INFUSE usage has grown for NON-Medicare patients since 2003; in 2007, this cohort represented 89.6% of units sold. Off-label use, more prevalent with non-Medicare patients, accounts for 17.3% of total INFUSE usage. In 2007, off-label use equated to more than \$128 million dollars.

Assessment of Collagen-Ceramic Composites as Graft Extenders in a Rabbit Spine Fusion Model

Leah Y. Carreon, MD, MSc; Steven D. Glassman, MD; Sigurd Berven, MD; Raja Rampersaud, MD, FRCSC; Michael Shainline, MS

The purpose of this study is to determine if a collagen-ceramic composite (CCC; Medtronic Sofamor Danek, Memphis, TN) mixed with bone marrow aspirate (BMA) is a suitable bone graft extender in a rabbit lumbar intertransverse fusion model.

Assessment of Progenix DBM Putty Bone Substitute in a Rabbit Posterolateral Fusion Model

Brice Ilharreborde, MD; Yan Lefevre; Etienne Morel; Franck Fitoussi; Prof. Georges-françois Penneçot; Prof. Keyvan Mazda

The purpose of this study is to determine the performance characteristics of Progenix DBM putty as a bone graft extender, enhancer, and substitute in a rabbit posterolateral spine fusion model.

Cervical Reconstruction

The Efficiency of Multislice Helical CT in the Diagnosis of Pharyngovertebral Fistula Due to Loosening of Anterior Screw-Plate Construct

Timothy Kuklo, MD, JD; Melvin D. Helgeson, MD; Michael Rosner, MD; Ross R. Moquin, MD; Ronald A. Lehman, Jr., MD

Late dysphagia is a rare condition due to hardware failure in anterior spine surgery patients. Dysphagia should be evaluated to find out the possible underlying causes. Videofluoroscopic swallowing study and MHCT are efficient and complementary tools in the evaluation of late dysphagia.

Morphology of the C1 Posterior Ring and its Implication for Lateral Mass Fixation

Frank L. Acosta, Jr., MD; Jordan M. Cloyd; Christopher P. Ames, MD

A study designed to investigate the feasibility of placement of a 3.5mm screw via the posterior arch and lateral mass of the atlas. 107 cervical spine were evaluated. The posterior arch was measured at its shortest axis in both cranio-caudal, as well as, transverse diameter. The width of the posterior arch at the location of vertebral artery groove and the width of lateral mass are broad enough to hold a 3.5 mm screw.

Therapeutic Strategy for Spinal Reconstructive Surgery in Treatment of Cervical Spine Injuries

Lawrence G. Lenke, MD; Ronald A. Lehman, Jr., MD; Anton E. Dmitriev, MSc

71 consecutive patients with fracture/dislocations in the cervical spine were reviewed. Rate of respiratory/pulmonary management by tracheotomy (RPMT) was 0-30% according to injury types. Total incidence of injury with high-risk of RPMT was 54%. Although teardrop and burst fracture is a good indication for anterior reconstruction, anterior plate should be carefully indicated because of potential risk for RPMT. Even in unstable dislocations in which combined anteroposterior reconstruction should be indicated, anterior plate may not be used by the same reason.

Anatomical Consideration for Manual Cervical Pedicle Screw Placement Safety Using the Synthetic Cervical Spine Models

Prof. Ming Li, MD; Jingjie Wang; Shisheng He; Chuanfeng Wang; Suxi Gu; Yongfei Zhao

We identified the optimal range of pedicle transverse angle (PTA) and pedicle diameter (PD) that would maximize the CPS placement accuracy using synthetic cervical spine models. From the anatomical viewpoint, this study suggests that safety of CPS placement is optimal when PTA is 35-40 degrees or PD is 6mm or greater. Manual technique can be reliable for CPS placement on certain anatomical conditions.

Cervical Disc Arthroplasty versus Arthrodesis for Myelopathy: A Prospective, Randomized, Multi-Center IDE Trial

Prof. Ming Li, MD; Jianqiang Ni, MD; Xiutong Fang, MD; Xiaodong Zhu; Suxi Gu

A cross sectional analysis of two large, prospective, randomized multi-center trials was performed to evaluate the efficacy of cervical disc arthroplasty in the treatment of myelopathy due to single-level pathology localized to the disc space. Our results indicate that both the arthroplasty and arthrodesis groups improved following surgery; furthermore, improvement was similar between the groups with no worsening of myelopathy in the arthroplasty group.

Predictive Value of Subaxial Cervical Spine Injury Numeric Severity Scores for Surgical Intervention

Prof. Ming Li, MD; Xiutong Fang, MD; Xiaodong Zhu; Suxi Gu; Jianqiang Ni, MD

Subaxial cervical spine injury severity scores were utilized to predict the need for surgery.

Effect of a Fibrin Sealant on Drain Output and Length of Stay after Multi-Level Anterior Cervical Fusion

Donald Kucharzyk; Robert Swanson; Dennis Graham; Brian Fuertges

In order to determine if fibrin sealants can decrease hospital length of stay and postoperative drain output following multi-level anterior cervical fusions, a retrospective matched pair analysis was performed on thirty pairs of patients who underwent anterior cervical fusion 3 levels. Our results indicate that the application of fibrin sealant at the end of the procedure can significantly decrease both the length of stay and postoperative drain output.

Pseudarthrosis in Multi-Level Anterior Cervical Fusion with rhBMP-2 and Allograft: Analysis of 127 Cases with Minimum 2-Year Follow-Up

Prof. Ming Li, MD; Xiutong Fang, MD; Xiaodong Zhu; Suxi Gu; Jianqiang Ni, MD

In order to determine the pseudarthrosis rate in rhBMP-2 augmented multilevel (3 levels) anterior cervical fusions, 127 consecutive patients who underwent a 3-, 4-, or 5-level stand-alone anterior cervical fusion and plating and had a minimum 2-year follow-up were prospectively analyzed. The pseudarthrosis rate was 10.2% and the only statistically significant risk factor for developing a pseudarthrosis was the number of fusion levels.

Radiographic Results from the BRYAN Cervical Disc IDE Study

Prof. Ming Li, MD; Chuanfeng Wang; Shisheng He; Suxi Gu; Jingjie Wang

The Bryan disc treatment, on average, maintained flexion/extension range of motion without degradation over 24 months. No ectopic bridging ossification was seen in any of the Bryan discs and no subsidence or displacement of the Bryan disc occurred.

An Examination of Cervical Pedicle Morphology; Comparison Between Computed Tomography and Computer-Assisted Image-Guidance System

Donald Kucharzyk; Robert Swanson; Dennis Graham; Brian Fuertges

This study was designed to assess the cervical pedicle diameter size between computed tomography (CT) and computer-assisted image-guidance system (Navigation) measurement. The pedicle diameter was increased in Navigation group significantly without the C6 pedicles. Computer-assisted image-guidance system could be applied even a preoperative planning as well as a safe and accurate placement for cervical pedicle screw.

Sagittal Decompensation is Significant after Occipito-Cervico-Thoracic Fusions

Prof. Zou Dewei

We report our experience in 23 patients undergoing occipito-cervico-thoracic (OCT) fusion for a variety of indications. Although a 96% fusion rate was obtained, an average sagittal balance decompensation of +2.3cm occurred during follow-up, resulting in 65% of patients being satisfied with head position at last follow-up, compared with 91% initially.

Cervical Radiculopathy Treated with PEEK spacers versus Allograft—Are we Using the Appropriate Control for Cervical Arthroplasty Studies?

Xiaodong Zhu; Prof. Ming Li, MD

The PEEK/ Bone Marrow Aspirate treatment successfully allowed good radiographic visualization of trabecular bridging bone within the cage, absence of motion on flexion-extension radiographs, and no reoperations in this series of 100 consecutive procedures.

Absence of Bias between Training Cases and Randomized Cases in Prospective Randomized FDA Studies of Cervical Disk Replacement—788 cases.

Donald Kucharzyk; Robert Swanson; Dennis Graham; Brian Fuertges

The “intent to treat” population and tabulation of outcome instruments and adverse events in these three studies was able to increase by 214 subjects of $214 / 783 = 27\%$, or more than $\frac{1}{4}$ the amount of additional information.

Lower Incidence of Dysphagia with Cervical Arthroplasty Compared to ACDF in a Prospective Randomized Clinical Trial.

Xiaodong Zhu; Prof. Ming Li, MD; Suxi Gu

Time to resolution of the dysphagia. An increase in dysphagia severity at either the 6 week or 3 month follow-up visit was reported in 35 (42%) PCM and 29 (64%) ACDF subjects ($p=0.228$). Long-term resolution of these symptoms was noted in 74% (26/35) of the PCM subjects as compared to 41.4% (12/29) of the ACDF subjects ($p=0.015$). For all visits, the mean incidence of dysphonia was 9.03 ± 15.4 for the PCM arthroplasty and 13.1 ± 18.8 for ACDF controls ($p=0.185$). However the number of visits in which patients claimed a moderate to severe amount of hoarseness (40/100 or higher) was $16/338 = 4.73\%$ for PCM arthroplasty patients compared to $16/180 = 8.88\%$ for the ACDF patients ($p=0.097$).

Stable Reconstruction Using Halo-Vest for Unstable Upper Cervical Spine and Occipito-Cervical Instability

Xiaodong Zhu; Prof. Ming Li, MD; Yong Hu; Prof. Kenneth Man Chee Cheung

For unstable upper cervical spine and occipito-cervical instability, halo-vest was useful for preoperative reduction of subluxation in conscious state and posterior occipito-cervical (thoracic) spine reconstruction. Reduction of Atlantoaxial subluxation (AAS) and Vertical subluxation (VS) were achieved and neurological symptoms were improved.

Occipitocervical Fixation Using Cervical Pedicle Screws: Is it Feasible to Obtain and Maintain Anatomical Reduction?

Prof. Zou Dewei

Ten consecutive patients (4 male, 6 female; mean age of 58.4 years) underwent occipitocervical reconstruction using cervical pedicle screw as an anchor by a same spine surgeon. An average of 3.5 year follow-up demonstrated the satisfactory result in terms of clinical and radiographic outcomes. It was feasible to obtain and maintain an anatomical reduction to some extent when cervical pedicle screws were utilized in occipitocervical fixation.

A Lateral Fluoroscopic Guide to Prevent Occipito-Cervical and Atlanto-Axial Joint Violation during C1 Lateral Mass Screw Placement

Sang-Min Lee, PhD; Prof. Se-Il Suk, MD, PhD; Weon Wook Park

In order to identify a simple lateral fluoroscopic landmark to prevent C0-C1 and C1-C2 joint violations during C1 lateral mass screw insertion we used 154 CT scans and screw trajectory software to simulate screw insertion. We conclude that when a C1 screw is directed $0-15^\circ$ medially, it can be inserted without joint violation if the screw trajectory lies between 20-40% of the total height of the anterior atlas arch with 100% representing the cranial and 0% the caudal border, respectively.

Predicting SF-6D Scores from the Neck Disability Index and Numeric Rating Scales for Neck and Arm Pain

Phebe S. Ko, B.S.; Paul D. Sponseller, MD; Paul G. Jameson, II, BS; Tai-Li Chang

In 2080 patients who had cervical fusion for degenerative disorders, strong, consistent and predictable correlations were seen between paired observations of NDI and the SF-6D. Using regression modeling, a validated method of estimating the SF-6D from the NDI was determined. This is useful for economic evaluations of treatments in trials where NDI is available but utility scores were otherwise not collected.

Is a Cervical Collar after Anterior Cervical Fusion with Plating Necessary?

Prof. Zou Dewei

Patients in an FDA-regulated, multicenter trial treated with decompression and arthrodesis using allograft and an anterior cervical plate were divided into those who received a brace and those that did not. Clinical outcomes, fusion rates and return to work rates between patients who were braced and those who were not were similar. The use of a cervical brace does not improve the clinical outcomes, the fusion rate or return-to-work rates of patients undergoing anterior cervical fusion with plating.

Circumferential Cervical Osteotomy and Reconstruction

Philippe Phan, M.D; Neila Mezghani, PhD; Stefan Parent, MD, PhD; Prof. Jacques A. de Guise, PhD; Hubert Labelle, MD

Correction of a circumferentially fixed cervical deformity has traditionally required multiple releasing procedures from both anterior and posterior approaches before correction and instrumentation can be achieved in a physiological alignment. We describe a technique in which significant anterior and posterior column resection can be achieved through an anterior approach by mobilization of the vertebral artery.

Circumferential Osteotomy for Fixed Cervical Kyphosis: Novel Surgical Technique.

Osamu Shirado, MD; Tomohisa Nomoto, MD; Masaru Hirai, RPT; Keisuke Takahashi, MD; Hiromi Oda, MD; Masabumi Nagashima, MD

Acquired fixed cervical kyphosis is a complex problem, associated with chronic neck pain and neurologic deficit. Currently, there is no consistent surgical method to treat this condition. A novel surgical technique is described and the initial results in 12 patients.

A Retrospective Radiographic Analysis of Subaxial Sagittal Alignment after Posterior C1-2 Fusion

Tsutomu Akazawa, MD; Yoshinori Otsuka; Akira Katsumi; Masamichi Tahara, MD; Shohei Minami, MD; Toshiaki Kotani, MD

Subaxial sagittal alignment following C1-2 posterior fusion was investigated retrospectively. A retrospective review was conducted for 63 patients who underwent C1-2 fusion. The mean angles of C1-2 before surgery in kyphotic group and lordotic group were 20.6° and 19.1°, respectively. Those at the final follow-up were 23.7° and 19.5°, respectively. There were statistically significant differences in those of two groups. These results indicated that C1-2 fixation in a hyperlordotic position led to a subaxial kyphosis after surgery.

Substantial Cervical Fixation Rod Deformity Under Physiologic Loads

Prof. Yong Min Kim, MD, PhD; Prof. Dong Soo Kim, Master; Byung Ki Cho, MD; Se Hyuk Im, MD

The amount of deformity imposed upon cervical fusion rods by the weight of the head and cervical spine muscle forces has yet to be quantified and may be important in dictating the overall rigidity of upper spinal constructs. We used a benchtop biomechanical model to quantify rod deformity under physiologic load levels for an occiput-T3 fusion construct. Our results showed non-trivial levels of rod deformity (9.5 to 15 degrees).

Salvage of C2 Pedicle Screw Fixation with a Novel Technique of a Lateral Offset Connector for Atlantoaxial Fixation

Kai-Ming Fu, MD, PhD; Justin S. Smith, MD, PhD; Christopher I. Shaffrey, MD

In an instability model, C2 pedicle screws proved superior in both axial rotation and lateral bending compared to intralaminar screws with/without lateral offset connectors. Addition of a crosslink to the lateral offset connectors resulted in similar stability to pedicle screws. Therefore, if transpedicular insertion fails or is contraindicated, this technique presents an alternative for salvaging C2 fixation.

Improvement in Efficacy and Stability with PCM-V Cervical Disc Prosthesis Compared to Standard-PCM in Cervical Arthroplasty: a 2-Year Follow-Up Study.

Sayaka Hamamura; Koki Uno, MD, PhD

Our results suggest better clinical outcomes in patients with the new PCM-V cervical disc prosthesis compared to those implanted with the standard PCM.

Comparison of BRYAN Cervical Disc Arthroplasty with ACDF: Clinical Results of a Randomized Controlled Clinical Trial

Ravinder Gangone, MBBS, MS (Orthopaedics), MRCS; Prabhat Lakkireddi, MBBS, MS (ortho) MRCS; Gavin Marsh, FRCS(Tr & O)

The investigational group patients treated with the artificial disc had a statistically superior improvement in Neck Disability Index scores and had a significantly higher rate of overall success than the control group.

Does Excision of the Posterior Longitudinal Ligament During Anterior Cervical Corpectomy and Reconstruction Effect Stability?

Richard P. Baker, MB.ChB, MSc, MRCS; Michael Kilshaw, MB.BS, B.Sc., MRCS; Richard Gardner; Sebastien Charosky, MD; Ian J. Harding

The stabilizing role of the PLL following a complete cervical corpectomy and reconstruction with a strut graft and plate is unknown. In our biomechanical cadaveric study, excision of the PLL during corpectomy did not effect the post-reconstruction stability.

Complications

Injury of an Aberrant Vertebral Artery during a Routine Corpectomy. A Case Report and Literature Review.

Nobuhide Ogihara, MD; Jun Takahashi, MD; Hiroki Hirabayashi; Hiroyuki Hashidate; Prof. Hiroyuki Kato

This is a case report of a 58-year-old man who sustained a laceration of his left vertebral artery during a routine corpectomy for cervical myelopathy.

The Effect of Post-Operative Infection on Spinal Deformity Progression

Ravinder Gangone, MBBS, MS (Orthopaedics), MRCS; Prabhat Lakkireddi, MBBS, MS (ortho) MRCS; Gavin Marsh, FRCS(Tr & O)

Progression of spinal deformity is associated with the decision to remove the implants. If the implants are removed after an infection, there is a clinically significant progression averaging 33 degrees in 64% of the patients. Only 12% of the patients who retained their hardware had progression.

Complication of External Trans-Pedicular Fixator Osteosynthesis in Patients with Scoliosis

Prabhat Lakkireddi, MBBS, MS (ortho) MRCS; Ravinder Gangone, MBBS, MS (Orthopaedics), MRCS; Gavin Marsh, FRCS (Tr & O)

Complications were observed in 14 (5,8%) cases and distributed as following: disorder of the spinal blood flow in Adamkevich's artery – 1 case, implant migration to the spinal canal – 1 case, unsatisfactory position of screw-rods – 12 cases. Distribution according to neurologic disorders: severe paraparesis (1 patient), medium paraparesis (2 patients), light paraparesis (3 patients), medium monoparesis (3 patients), disorder of pelvic organs function (3 patients) liquorrhea (6 patients). CT examination after operation allows to decide either to remove or to reinsert fixator. Urgently we reduce compressing factor and perform restorative treatment, including vascular medications, noortopics, spasmolytics, massage, exercises, electrostimulation. Neurologic disorders were eliminated in 12 patients completely, in 2 patients – partially.

Confessions of a Spine Surgeon about Adverse Events and Complications – Initiation of the Spine Complication Registry

Alastair Hudd; Jason Bernard, MD; Sean Molloy

To determine the incidence of adverse events and clinical complications in variety of spine surgeries and the implication of this data towards the improvement of the services delivered to the patients and the need of the spine complication registry

A Retrospective Review of Complications Associated with the Use Of BMP in Anterior Cervical Fusion Patients

Azmi Hamzaoglu; Cagatay Ozturk; Murat Tonbul; Gursel Saka; Meric Enercan; Ayhan N. Kara

Several recent studies have evaluated the use of BMP in anterior cervical fusions and have documented varying results. This study compared BMP to allograft in one level cervical fusions. There was no increase in complication rates in the BMP group. We speculate that the combination of lower BMP dosing and peri-operative steroid use offset the previously reported BMP related complications

Superior Mesenteric Artery Syndrome Following Spinal Deformity Correction in Pediatric Patients.

Joselito L. Lazaga, Doctor of Medicine; Mario R. Ver

Superior Mesenteric Artery Syndrome (SMAS) is a known complication associated with surgical correction of scoliosis. We report 4 cases of SMAS with an incidence in our study group of 1.1%. Three patients had a preoperative weight and two a preoperative body mass index below the 25th percentile for their age. Average curve magnitude was 70.8 degrees preoperatively and 32 degrees postoperatively. The average amount of correction was 38.8 degrees (54.8%). Conservative management achieved resolution of symptoms in all four patients.

Incidence, Risk Factors and Treatment of Symptomatic Stress Fractures after Lumbar Spinal Fusion with Pedicle Screw Instrumentation.

Prof. Seung-Woo Suh, MD, PhD; Hitesh N. Modi, MS, Orthopedics; Jae-Hyuk Yang, MD

Lumbar fusion with the use of rigid hardware raises the stress at adjacent levels. In our review of patients who underwent pedicle screw instrumentation and fusion of the lumbar spine, symptomatic stress fractures were found in 2% of patients. Multivariate analysis found increased age as a risk factor for stress fractures. Once diagnosed, stress fractures can be treated effectively with extension of the fusion.

Pseudarthrosis at L5-S1 after Posterior-Only Fusion for Degenerative Lumbar Spine

William Cross, III, MD; David W. Polly, Jr., MD; Jonathan P. Braman, MD; Andrew Schmidt, MD; Greg Sherr, MD, MPH; Walter Galicich, MD

Eighty-nine patients with degenerative lumbar spinal disease were reviewed with a minimum 2 year follow-up. The rate of pseudarthrosis at L5-S1 was 25% (22 of 89 patients). At other levels, it was 10% (9 of 89 patients). The pseudarthrosis was closely related to a halo sign of the sacral screws, and hypermobile angulation on flexion-extension radiographs. There was no risk factor of pseudarthrosis found at L5-S1.

How Does Surgeon Experience Effect The Accuracy Of Placement of Thoracic Pedicle Screws in Adolescent Idiopathic Scoliosis (AIS)?

Rudolf Bertagnoli, MD

Thoracic screw placement in the deformed spine poses unique challenges, including a steep surgeon learning curve. In this study, we compared pedicle screw breach rates as assessed by postoperative CT for surgeons with varying levels of experience. We established an overall breach rate of 12.5% and found a trend toward fewer breaches for the most experienced surgeons. In addition, this group demonstrated a markedly lower medial breach rate.

Complications of Lumbar Spinal Stenosis (LSS) Surgically Treated Patients in a General Orthopaedic Department.

B. Stephens Richards, MD; Daniel J. Sucato, MD MS; Charles E. Johnston, II, MD; Lawrence G. Lenke, MD; Timothy Kuklo, MD, JD; David W. Polly, Jr., MD; James O. Sanders, MD; Study Group Spinal Deformity

In this report, the complications of surgical treatment of LSS in 42 patients are presented. The preoperative evaluation, the operative treatment and the preoperative, intra-operative and postoperative complications were studied. In this series of patients the following complications were recorded and treated: tear of the dura 4.76%, postoperative hypovolemic shock 2,3%, infection 7,1%, and hematoma 2,3%. No death or neurological deficit was recorded.

Mechanical DVT Prophylaxis and Ultrasound Screening is not Effective in Preventing Pulmonary Embolism in Adult Spinal Deformity Surgery

Rudolf Bertagnoli, MD

The incidence of pulmonary embolus (PE) following adult spinal deformity surgery demonstrated that >5% of patients suffered a PE, confirmed by chest computed tomography angiogram (CTA), despite mechanical deep venous thrombosis (DVT) prophylaxis and negative DVT ultrasound screening. Risk factors for PE included higher American Society of Anesthesiologist (ASA) score, and longer hospital stay. Additional research regarding PE prophylaxis in adult spinal deformity surgery is warranted.

Adjacent Vertebral Body Osteolysis with Bone Morphogenetic Protein Use in Transforaminal Lumbar Interbody Fusion

James T. Guille, MD; Linda P. D'Andrea, MD; Mark F. Abel, MD; Tracey P. Bastrom, MA; Randal R. Betz, MD; Peter O. Newton, MD; Alvin Crawford, MD

We found a significant incidence of adjacent level vertebral body osteolysis when BMP was used in an interbody device. Spine surgeons need to be aware of this complication and its implications.

Shortening of Growing Rod Spinal Instrumentation Reverses Acute Cardiac Failure

Safdar N. Khan, MD; Prof. Jeffrey M. Toth, PhD; Steven D. Glassman, MD; Munish C. Gupta, MD

This is a case report of cardiac failure following growing rod lengthening.

Predicting Complications of Multilevel Thoracolumbar Spinal Fusion in Elderly Patients

Daniel J. Sucato, MD MS; Neel Srikishen, BS; Steven Sparagana, MD; Patricia Rampy, MS, CNIM; Elizabeth M. Van Allen, MS, CNIM; Anna McClung, RN

We conducted a retrospective review to analyze the perioperative and radiographic complication rates in elderly persons undergoing multilevel (5) thoracolumbar fusion and to determine factors predictive of such events. Complication rates were not statistically significantly different from those of younger patients. Number of comorbidities was predictive of a perioperative complication with an odds ratio of 1.8, while age was not. Overall health status may be more important than age in determining the risk for complications of multilevel thoracolumbar fusions.

Routine Postoperative CT Scans may Detect Potentially Hazardous Thoracic Screw Breaches in AIS Fusion Surgery Prior to Development of Clinically Significant Sequelae

Prof. Zhaomin Zheng, MD PhD; Binsheng Yu, MD PhD; Hui Chen
Review of postoperative CT scans in 145 consecutive patients with AIS undergoing spinal fusion identified a small number of pedicle screw breaches impinging neighboring neural and vascular structures, leading to subsequent revision. Since such screws were clinically undetected by standard evaluation, routine CT may identify potentially hazardous screws prior to clinical sequelae.

Extreme Lateral Interbody Fusion (XLIF) In Obese Patients

Daniel J. Sucato, MD MS; Anna McClung, RN; Jeffrey Hopkins, RN, BSN; Mark Lee, MD; Joshua Meier, MD; John Dale, BS; Dinesh Thaurani, MD; Bryan Tompkins, MD
The safety and utility of the XLIF technique in treating obese patients is evaluated.

Post-Operative Infection in Spinal Deformity Surgery: Analysis of 1772 Cases in One Center in China

John P. Lubicky, MD; Elizabeth H. Riley, MIS, MLS
In 1772 cases of spinal deformity surgery in one center, the incidence of post-operative wound infection is about 1.69%, deep infection 1.19% and superficial infection 0.45%. Bacterial culture showed staphylococcus aureus was the predominant bacterium. For superficial infection, debridement and primary wound closures with parental antibiotics was effective, while for deep infection, implant removal is sometimes required to clear infection.

Epidural Spinal Cord Compression with Neurologic Deficit Associated with Intrapedicular Application of FloSeal During Pedicle Screw Insertion

Amer F. Samdani, MD; Daniel M. Sciubba, MD; JahanGir Asghar, MD; Patrick J. Cahill, MD; M. Darryl Antonacci, MD, FACS; David H. Clements, III, MD; Randal R. Betz, MD
In order to demonstrate the dangers associated with intrapedicular application of FloSeal during pedicle screw insertion, we present two cases where the intrapedicular application of FloSeal to decrease the blood loss associated with pedicle screw insertion resulted in epidural spinal cord compression and neurologic deficit. In both cases an urgent decompression and evacuation of FloSeal was required, but with the appropriate treatment, both patients fully recovered.

Bone Morphogenetic Protein-2 Induced Radiculitis following Transforaminal Lumbar Interbody Arthrodesis

Frank L. Acosta, Jr., MD; Dean Chou, MD; Christopher P. Ames, MD
We performed a retrospective study of 68 patients, comparing bone morphogenetic protein (BMP) versus autograft via a transforaminal lumbar interbody fusion (TLIF) with a cage. The incidence of post-operative radiculitis was 23% with use of BMP-2 versus 3% with iliac crest autograft.

Inherited Coagulopathic States as a Risk Factor for Complications in Pediatric Spine Patients

Jesse E. Bible, BS; Debut Biswas; Peter G. Whang, MD; Glenn R. Rechtine, MD; Jonathan N. Grauer, MD

We present 4 cases of children with inheritable hypercoagulable syndromes and either spontaneous paralytic episode, major perioperative complication associated with spinal surgery, or planned spinal surgery. All were detectable by a careful family history looking for thrombotic episodes.

Musculoskeletal Injuries Among Spine Surgeons: Results of a Survey of the SRS Membership

John Flynn, MD; Norman Ramirez; Frances C. Torres, PhD
Anecdotal evidence suggests that spine surgeons are at an increased risk for common "overuse" injuries related to performing spine surgery. An online survey was completed by 36% (300/843) of the SRS surgeon membership and revealed that compared with estimates of disease prevalence in the general population, spine surgeons are at an increased relative risk (RR) for cervical HNP with radiculopathy (RR 1.6-3.8), lateral epicondylitis (RR 5.7-17.0), carpal tunnel syndrome (RR 2.9-4.1), and lumbar HNP with radiculopathy (RR 4.0-6.7).

Outcome of Pulmonary Function in Patients Undergoing Surgical Correction of Scoliosis

David H. Clements, III, MD; David H. Clements IV, BS; Prof. Kurosh Darvish, PhD; Mehdi Shafieian, MSE; Randal R. Betz, MD; Harms Study Group

In patients undergoing thoracotomy there is significant acute decline in pulmonary function, and it does not recover to preoperative levels by one year.

Remote Cervical Spinal Cord Infarction Following Scoliosis Surgery

Jeremy R. Tesar; Jean H. Mullins, BA; Jonathan R. Sales, MD; Tim Bahnney, BSME; Prof. Brian K. Bay; Robert A. Hart, MD

We report 4 cases of cervical spinal cord infarction following corrective surgery for scoliosis. All patients developed incomplete quadriplegia after surgery. MRI scans revealed extensive spinal cord signal change within the cervical cord. At mean follow up of 3.3 years, three patients had persistent significant neurological deficit

Outcome Based Classification for Assessment of Pedicular Screw Placement in Scoliosis

Alvin Crawford, MD; Samir Parikh; Twee T. Do, MD; Dennis Roy, MD; Gregory L. Cox

The concept of acceptable screw placements makes the thoracic pedicle screw assessment results differentiate between the benign marginal misplacements (acceptable) and those with dangerous placements (unacceptable).

Closely Coupled “Quad Rod” Spinal Instrumentation Technique to Fix or Prevent Rod Breakage.

Michelle S. Caird, MD; Robert N. Hensinger, MD; Kelly Vanderhave, MD; Martin K. Gelbke, MD; Frances A. Farley, MD

A new surgical instrumentation technique has been developed and implemented to revise posterior instrumentation, due to rod breakage at thoracolumbar junction. The new “Quad Rod” technique uses a closely-coupled second rod on each side, running one level above and below the level of unstable fracture, and connected to the main rod with three strong rod to rod connectors usually used for extension instrumentation.

Iliac Wing Instrumentation Decreases Hardware Loosening, but may Increase Rod Fracture at Lumbosacral Junction

Jerome Sales de Gauzy; Franck Accadbled, MD, PhD; Philippe Violas; Jerome Briot; Erik Estivalezes, Ph. D.; Prof. Pascal Swider, PhD

Iliac wing instrumentation has dramatically decreased the incidence of pseudarthrosis and hardware loosening at lumbosacral junction. However, this strong foundation appears to shift loads to increase incidence rod fracture.

Surgical Outcomes of Anterior versus Posterior Spinal Fusion in U.S. Children’s Hospitals

Daniele A. Fabris Monterumici, MD; Riccardo Sinigaglia, MD

The purpose of this study was to examine the frequency of spinal fusion surgery by anterior vs. posterior surgical approach and to compare length of stay (LOS), in-hospital infection, and surgical complication rates in children who underwent surgery in a U.S. children’s hospital during a three-year period (2004-2006).

Variability in Surgical Outcomes for Spinal Fusion Surgery in U.S. Children’s Hospitals

Alexander Ching, MD; Robert A. Hart, MD

The purpose of this study was to examine length of stay (LOS), in-hospital infection rates and surgical complication rates in children with or without neurological impairment (NI) who underwent spinal fusion surgery in U.S. Children’s Hospital during a three year period (2004-06).

Complications in Spinal Fusion for Duchenne Muscular Dystrophy.

Mario J. Cardoso, MD, DC; Anton E. Dmitriev, MSc; Ronald A. Lehman, Jr., MD; Melvin D. Helgeson, MD; Michael Rosner, MD

A major postoperative complication rate of 22.5% was seen in a series of forty patients undergoing spinal fusion for DMD. Major complications included wound infection, DVT, dural tear and prominent instrumentation. 1 of 40 patients required intubation for 3 weeks, although the average period of intubation was 1.5 days. Cardiomyopathy was not seen in patients undergoing operation during the early teen years.

Congenital Scoliosis

The Importance of Three-Dimensional Analysis in Vertebrectomy for Congenital Spinal Deformities via a Single Posterior Approach

Timothy J. Hatlen; David B. Shurtleff, MD; Kit Song, MD

The clinical significance of three-dimensional preoperative analysis of the anomalous vertebral morphology for vertebrectomy via a single posterior approach was evaluated in 51 patients. Compared with the simple anomalies (unison type), it was difficult to judge the target vertebrae for removal in seven patients with discordant vertebral anomalies because of discrepancies between the anterior and posterior structures. It was necessary to check 3D-CT images repeatedly during the operation to prevent disorientation.

Comparison of Effectiveness of Halo-Femoral Traction after Anterior Spinal Release in Severe Idiopathic and Congenital Scoliosis

Farhaan Altaf, MBBS, MRCS, BSc(hons); A. Sivaraman, FRCS (orth); Waleed Hekal; Hilali Noordeen, MA.BM.BCH(OXON). FRCS(ORRTH)

The effectiveness of Halo-femoral traction after anterior spinal release was assessed in the staged surgical management for severe idiopathic scoliosis (IS) and congenital scoliosis (CS). After Halo-femoral traction, four patients experienced brachial plexus palsy and complete nerve functional restoration was achieved at two months follow-up. Patients with IS displayed higher correction rate of major curve and better sagittal restoration than CS patients.

Instrumented and Uninstrumented Spinal Fusion for Children with Congenital Scoliosis

Gabriel Piza Vallespir, MD, PhD; Jesus Burgos; Ignacio Sanpera Trigueros; Eduardo Hevia; Pedro Domenech; Juan Carlos Rodriguez Olaverri; Manuel Garcia Alonso; Rafael Ramos Galea; Antonio Perez Francisco; Beatriz Rodriguez de Paz; Javier Vicente Thomas; Pedro Gutierrez Carbonell; Jose Ignacio Maruenda Paulino; Prof. Carlos Barrios; Oscar Riquelme Garcia

Children with congenital scoliosis had improved postoperative outcomes after an instrumented spinal fusion compared with an uninstrumented spinal fusion.

BMI is Changing in Children and Adolescents Presenting for Scoliosis Surgery—The Prospective Pediatric Scoliosis Study Data Base

Wael Koptan, MD; Yasser ElMiligui, MD, FRCS; Prof. Hazem B. Elsebaie, FRCS, MD

The body habitus of children presenting for scoliosis surgery is changing over time. In pediatric age groups, the incidence of overweight children doubled between 1976-1980 to 1999-2002, Hedlet et al, JAMA 2004. Associated conditions have tripled—overweight children have associated adverse consequences with 60% of overweight 6-10 year olds having 1 risk factor for cardiovascular disease.

Posterior Hemivertebra Resection with Short Transpedicular Instrumented Fusion in the Treatment of Congenital Kyphoscoliosis caused by a Fully Segmented Hemivertebra

Farhaan Altaf, MBBS, MRCS, BSc(hons); Ken Mannan; Marco Sinisi; Prof. Rolfe Birch

Thirty cases of congenital kyphoscoliosis patients caused by a fully segmented hemivertebra were treated with posterior hemivertebra resection with short transpedicular instrumented fusion, the surgical results showed this technique is safe and effective, and can preserve more mobile segments.

Corrective Surgery with Vertebral Column Resection for Congenital Kyphoscoliosis in Skeletally Matured Patients

Jui-Teng Chien, MD; Chang-Chen Yang; Wen-ming Su, MD; Ching-Hsing Lin

We demonstrate technical notes and short term outcomes of corrective surgery with vertebral column resection for skeletally matured severe congenital kyphoscoliosis.

Variability in Treatment Decision for Early Onset Scoliosis

John P. Lubicky, MD; Elizabeth H. Riley, MIS, MLS

Cases of patients with early onset scoliosis were given to 12 experienced pediatric orthopaedic surgeons. Wide variability and reliability was found on treatment decision for this complicated group of patients.

Diagnostic Methods

Common Respiratory Abnormalities in Children with Thoracic Insufficiency Syndrome (TIS) During Sleep

Kazumasa Watanabe, MD; Prof. Koji Kanzaki; Kei Tateno

Twelve children with TIS (9 with scoliosis and 3 with hypoplastic thoraces) underwent overnight polysomnograms (PSGs) to determine frequency and nature of breathing abnormalities during sleep. The Apnea-Hypopnea Index (AHI) was abnormal in 11/12 children. Nadir oxygen-hemoglobin saturation (SaO₂), reflecting hypoxemia, correlated with increased AHI values. Neither AHI nor nadir SaO₂ correlated with Cobb angle in the children with scoliosis.

The Characterization of the Thoracic Biomechanics of Respiration in Thoracic Insufficiency Syndrome by Dynamic Lung MRI: A Preliminary Report

Alastair Hudd; Jason Bernard, MD

Dynamic lung MRI can selectively quantify the adverse effects of spinal deformity on the chest wall and diaphragm contributions to respiration and will enable a better understanding of the disruption of thoracic biomechanics due to spinal disease.

Grading Apical Vertebral Rotation without a CT Scan: A Simple System Based on the Radiographic Appearance of Bilateral Pedicle Screws

Farhaan Altaf, MBBS, MRCS, BSc(hons); A. Sivaraman, FRCS (orth); Prof. Thomas Carlstedt; Hilali Noordeen, MA.BM. BCH(OXON).FRCS(ORRTH)

A trigonometric model to measure vertebral rotation based on the radiographic appearance of bilateral pedicle screws was found to significantly correlate with CT measures of vertebral rotation ($r=0.96$, $p < 0.001$), and was used to develop a simple, post-operative grading system for apical vertebral rotation in patients with adolescent idiopathic scoliosis (AIS).

What is an Optimal Side-Bending Radiograph in Scoliosis?

Prof. Kazuhiro Hasegawa, MD, PhD; Ko Kitahara, PhD; Prof. Toshiaki Hara, PhD; Ko Takano; Haruka Shimoda; Takao Homma

Reproducibility and reliability of the side-bending radiographs are still unclear. 198 consecutive patients with AIS who were surgically treated were evaluated. The averaged age was 14.9 ± 2.1 years. If side-bending PT angle was greater than that of standing PT angle, correction of main thoracic angle was significantly increased. In the optimal side-bending radiograph for MT, Cobb angles of PT are greater than that of standing angle.

Image Fusion in Spine Fracture: A New Diagnostic Technique for Acute Vertebral Fractures in Osteoporosis Patients

Neel Anand, MD; Eli Baron; Gowriharan Thaiyananthan, MD

The purpose of this study was to examine the utility of image fusion MRI for identifying acute vertebral fractures in osteoporosis patients. MRI scans were performed on their thoracolumbar spine in the early phases. Fusion images were made from the T1 and STIR images using medical imaging software. Fusion images clearly indicated the sites of acute vertebral fractures even if there were multiple previous fractures.

Radiographic Analysis of Proximal Thoracic Spine Lamina for Determining Optimal Implant Placement

Neel Anand, MD; Eli Baron; Richard Wupperman, MD

This is the first study to evaluate the anatomical parameters allowing for placement of intralaminar screws into the proximal thoracic lamina. There were no significant differences between T1 and T2 lamina thickness measured on CT in young adult patients or post-mortem cadaveric segments obtained from elderly donors. The lamina is large enough to contain a 4.5mm screw.



Quality of Data Entry by Patients Completing the SF-36 Questionnaire

Osamu Shirado, MD; Tomohisa Nomoto, MD; Keisuke Takahashi, MD; Hiromi Oda, MD

The SF-36 questionnaire has been validated as a research tool. We report how well patients fill it in during a spinal outpatient clinic appointment, with the aid of a clinic nurse and translator if needed. Question 6 was best answered, but questions 4 and 5 are poorly answered. White British patients made fewer errors than other ethnic origins. The SF-36 may need certain questions redesigning if its use as a clinical tool is to be maximised.

Quantitative Assessment of Curve Flexibility in Adolescent Idiopathic Scoliosis

Prof. Dong-Eun Shin, PhD; Eun-Soo Moon; Eun-Kyeong Ahn; Jung-Won Ha; Dong-Jun Shim, MD; Hwan-Mo Lee; Joo-Young Kim; Jin-Oh Park; Hak-Sun Kim, MD

We have developed a quantitative traction method for the assessment of the curve flexibility in AIS patients. Nine AIS patients were included in this study. Under monitoring by image intensifier, vertical traction was applied to the patients in standing position using halter traction device equipped with a digital scale. Images during traction were recorded as digital data and the flexibility (deg/Nm) of main curve was calculated. The flexibility was -16.3 ± 8.1 deg/Nm on average. The flexibility had a highly positive correlation with postoperative correction rate ($R=0.82$). This method is less invasive to the patients and had higher reliability for the prediction of the postoperative curve correction.

A Clinical Study of Intraobserver and Interobserver Error in the Measurement of the Cobb Angle on -20 X-Ray Dose CR Imaging Films

Scott W. Zehnder, MD; Dirk H. Alander, MD; Prof. Carol V. Ward, PhD; Austin J. Crow

The Cobb angle difference was measured on 6 scoliosis 1/20 X-ray dose CR imaging films. Three observers measured each film independently and on two separate occasions to determine intraobserver and interobserver error. The 95 per cent confidence limit for intraobserver variance on 1/20 dose CR imaging films was 4.3 degrees for observer A, 5.7 degrees for B, and 4.5 degrees for C. That for interobserver variance on 1/20 dose CR imaging films was 4.3 degrees between observer A and B, 4.6 degrees between A and C, and 4.1 degrees between B and C. Our 1/20 X-ray dose CR imaging was useful and safety for whole spine imaging method.

Visualization and Evaluation of Pre- and Post-Operative Spinal Geometry in Scoliosis Using Ultra Low-Dose Radiation 2-3D Imaging: Significance of Apical Plane View Based on Preliminary Clinical Data

Jesse E. Bible, BS; Andrew K. Simpson, MD; Debdut Biswas; Prof. John W. Emerson, PhD; Jonathan N. Grauer, MD

Preliminary clinical data for a new ultra low-dose 2D/3D imaging in scoliosis is presented based on 10 patients before and after surgical correction using multi-anchors and rods system. Artifact-free, semi-automatic 3D reconstructions and automatically calculated parametric values were routinely available for pre- and postoperative evaluation and objective comparative analysis. Significance of the ability to routinely visualize and parametrically evaluate positional and rotational deformities of each vertebra, especially in apical plane view, is discussed.

Transverse Plane Pelvic Rotation following Rotationally Corrective Instrumentation of Idiopathic Scoliosis Double Curves

Wael Koptan, MD; Prof. Hazem B. Elsebaie, FRCS, MD; Yasser ElMiligui, MD, FRCS

Eight of 21 (38%) consecutive patients with adolescent idiopathic scoliosis double curves (Lenke 3 & 6) instrumented with lumbar pedicle screw anchored constructs had transverse plane pelvic rotation (TPPR) change of approximately 5° or more post-operative. In 88% (7/8) the TPPR was in the same direction as the corrective load to the thoracolumbar spine. At follow-up TPPR had resolved or was < 5° from neutral in 63% (5/8) and did not affect clinical outcome.

Diffusion Tensor Imaging and Quantification of Cervical Spondylosis

Stephen Lewis, MD, FRCSC, MSc; Laura M. Holmes, BScH, CNIM; Subir Jhaveri; Samuel Strantzias; Christian E. Zaarour, MD

Conventional MRI can have a poor correlation with the clinical symptoms of cervical spondylosis. DTI can more specifically identify damaged areas of the cervical spinal cord. This study demonstrates that DTI can objectively detect and quantify areas of spinal cord damage with significant values when comparing normal subjects vs. those with severe cervical spondylosis.

CT Scan Analysis of Pedicle Screw Placement: Measurement of Breach Is Not Reliable

Scott W. Zehnder, MD; Howard M. Place, MD

CT scan is widely used to assess the accuracy of pedicle screw placement. An evaluation of 597 screw placements by 6 surgeons demonstrated poor inter-rater agreement. Care should be taken when making clinical decisions based on an individual CT evaluation.

Evaluating the Influence of Patient Positioning on the Accuracy of Ortelius 800 Measurements for Scoliosis

Prof. Jianguo Zhang; Prof. Guixing Qiu; Bin Yu, Master; Prof. Yipeng Wang

One method of using surface topography to estimate the spinal curves in adolescent scoliosis patients, the Ortelius 800, has been shown by this researcher to be less reliable than expected. This study will analyze whether the reliability of measurements can be improved with a positioning and spine marking technique.

Morphological Evaluation of a New Pedicle Channel Classification using CT scans

Kota Watanabe, MD; Morio Matsumoto, MD; Shingo Izuka; Eijiro Okada; Prof. Yoshiaki Toyama; Kazuhiro Chiba, MD, PhD

We defined four pedicle types: Type A - "Large Cancellous Channel, Type B - "Small Cancellous Channel", Type C - "Cortical Channel", and Type D - "Absent or Slit Channel". 21 AIS patients (390 pedicles) who were surgically treated with thoracic pedicle screws were included in this study. Our results indicated that Types A and B are wider at the isthmus with more cancellous bone, while Types C and D are narrow with very little cancellous bone, thus verifying this classification.

A Prospective Evaluation of Osseous Pedicle Morphology: How many Thoracic Scoliotic Pedicles have Cancellous Channels?

Behrooz A. Akbarnia, MD; Vikas V. Varma, MD; Shay Bess, MD; Ramin Bagheri, MD; Sormeh Mahjouri; Juliano T. Lhamby, MD; Victor Hsu, MD; Pooria A. Salari, MD

We have developed a novel osseous morphologic pedicle description (Types A, B, C, and D) based on intraoperative findings for pedicle screw placement in the scoliotic thoracic spine. Surprisingly, 90% of pedicles had a distinct cancellous channel (Types A and B) vs. a cortical channel (Type C), or absent channel (Type D). This description provides important information for the spine surgeons to aid in safe pedicle screw placement.

Modified Lenke Classification System for Infantile and Juvenile Idiopathic Scoliosis

Daniel Y.T. Fong, PhD; Chun Fan Lee; Prof. Keith D.K. Luk; Prof. Jack Chun Yiu Cheng, MD; Kwok Hang Mak, MB,BS, Msc PH; Paul Siu Fai Yip; Bobby Kin-wah Ng; Prof. Kenneth Man Chee Cheung

There is no universally acceptable system for the classification of IIS and JIS. We developed a new system by modifying the current Lenke Classification System for adolescent idiopathic scoliosis (AIS). The frequency of curve patterns is remarkably similar to the AIS population. The ultimate goal is to allow organization of IIS and JIS curve patterns to objectively evaluate various treatment methods.

O-Arm 3-Dimensional Imaging in Spine Surgery: Does it Change the Surgical Procedure?

Koki Uno, MD, PhD

The O-arm intraoperative CT imaging system was used in 100 spine surgical procedures. Most common indications for imaging were assessment of posterior spinal instrumentation (74%) and adequacy of decompression (39%). In 18% of cases, the imaging information led to changes in the surgical procedure. These findings suggest that the O-arm is a useful intraoperative imaging tool in spine surgery.

New Method of Scoliosis Deformity Assessment: ISIS 2 System.

Takao Nakajima; Toshiya Ieda; Kazufumi Minami; Masabumi Miyamoto; Hiromoto Ito

The aim of this study was to confirm that ISIS 2 three-dimensional back shape measurements are valid and confident method in diagnosis and follow up of patients with scoliosis.

Adolescent Idiopathic Scoliosis: The True Sagittal Thoracic Profile

Yongjung J. Kim, MD; Lawrence G. Lenke, MD; Keith H. Bridwell, MD; Oheneba Boachie-Adjei, MD; Youngbae B. Kim; Naobumi Hosogane

Assessment of the true sagittal thoracic plane rotated out of the frontal plane may be accomplished with the use of a 3 D reconstructed CT

A Novel Quantitative Measure of Facet Joint Integrity using T1rho MRI

Yongjung J. Kim, MD; SeungChul Rhim; Samuel K. Cho, MD; Youngbae B. Kim

Advances in diagnostic methods and biomarkers of facet arthrosis are needed as motion-preserving technologies to treat spinal deformities emerge. Our previous studies have demonstrated the correlation between T1rho and proteoglycan content in the nucleus, and the ability to use this technique as a noninvasive biomarker for early disc degeneration. The current study demonstrates that T1rho correlates well with clinician grading and suggests the feasibility of using T1rho MRI to provide a quantitative measure of proteoglycan loss and early facet degeneration.

The Inter-Observer and Intra-Observer Reliability of Assessing Thoracic Pedicle Screw Position Based on Computed Tomography

Emre R. Acaroglu, MD; Ibrahim Akel, MD; Prof. Ahmet Alanay; Prof. Muharrem Yazici, MD; Sevilay Karahan, MD; Prof. Ralph Marcucio, PhD;

In a review of 20 patients with AIS and a postoperative CT to assess pedicle screw breach, there was poor inter-observer reliability with moderate intra-observer reliability of the Kim et al. definition for pedicle screw breach. Our data calls into question the efficacy of these criteria.

Validation of Capasso's Method vs Conventional Measurement Tools in Evaluation of Cobb Angle For Scoliosis

Hak-Sun Kim, MD; Hyang. Kim; Eun-Soo Moon; Hwan-Mo Lee; Prof. Dong-Eun Shin, PhD; Jin-Oh Park; Dong-Jun Shim, MD

Measurements obtained from radiographs play an integral part in clinical decision making in the management of scoliosis. Cobb's method reported in 1948 is still considered as gold standard although numerous researchers have highlighted its limitations. Capasso's method, though less popular is considered to be most sensitive tool of quantifying the magnitude of scoliosis as it is geometrically more valid. We hereby validate the Capasso's method versus Cobb angle measured by standard measurement tools and discuss clinical decision-making implications thereof.

Intraoperative O-Arm CT Scan Assessment of Pedicle Screw Position: Does it Prevent Unacceptable Screw Placement?

Felisa Sanchez-Mariscal, Consultant; Prof. Enrique Izquierdo, MD PhD; Javier Pizones; Patricia Alvarez, MD; Lorenzo Zuñiga; Alejandro Gomez-Rice, Resident

The O-arm intraoperative CT scanner was used to assess the position of 572 pedicle screws in 76 surgeries. The added information derived from intraoperative 3-dimensional imaging prompted surgeons to revise 13 screws (2.3%) in 10/76 surgical procedures (13.2%). These findings suggest that the O-arm is a useful imaging system for screw position assessment, and its intraoperative use allows surgeons to perform timely appropriate intervention.

Diagnostic Sacroiliac Joint Injections: The Dilemma of Interpretation

Marco Sassi; Maurizio Fornari, Neurosurgery; Alessandro Ortolina; Andrea Cardia; Francesco Costa; Giovanni Luccarelli

Pain relief responses to 90 sacroiliac joint injections were reviewed. Employing the low (50%) and high (100%) ends of recommended threshold values that define a positive response, variability in result interpretation was found to be 41%. The wide variability stemming from lack of consensus on what constitutes a positive response is a critical issue and should be addressed in future studies.

Dosimetric Evaluation of a New Bi-planar Low-Dose Radiographic System.

Akiyoshi Yamazaki, MD; Kei Watanabe, MD, PhD; Tomohiro Izumi; Atsuki Sano

A new low-dose radiographic system (EOS™) was compared with a standard digital radiographic system for dose reduction and image quality. The EOS system reduced radiation exposure by a factor of up to 9.2 while maintaining image quality and diagnostic capability.

Screw Adjacent to the Aorta: Is Prone CT Scan Helpful?

Kei Watanabe, MD, PhD; Akiyoshi Yamazaki, MD; Tomohiro Izumi; Atsuki Sano

Prone CT scans were performed in patients with questionable relationship of the pedicle screw to the aorta found on routine post op CT scans. A change in the relationship of aorta with respect to the tip of pedicle screw was noticed with change in patient position.

Etiology-Natural History

Natural History of Congenital Kyphoscoliosis: 23 Years of Follow Up

Szabolcs Somoskeoy, MD; Prof. Jean Dubousset; Tamás S. Illés, MD, DSc

We report a case of natural history of congenital kyphoscoliosis with progressive neurological compromise. The patient was first seen at the age of 3 month, with a failure of formations of T5 (Type I). Seventeen years later the patient was seen again with an important progression of his spinal deformity and paraplegia with a sensory level at the seventh thoracic dermatome with no sphincter control.

Risk for Curve Progression in Risser 0 and 1 Adolescent Idiopathic Scoliosis Patients with Curves Between 15-30°

Prof. Massimo Balsano, MD; Prof. PierPaolo Mura, Chief

In a large cohort of skeletally immature patients with small curves, the risk for curve progression 5° was approximately 50%. Specific risk factors for curve progression are female gender, menarchal status and peak height velocity in females, an open triradiate cartilage and the modified Oxford score. These can be utilized in determining appropriate treatment and follow-up for these patients.

Demographic Composition of Patients in the Prospective Pediatric Scoliosis Study (PPSS) Database.

Prof. Se-Il Suk, MD, PhD; Prof. Jin-Hyok Kim, MD, PhD; Sung-Soo Kim, MD; Kook Jin Chung; Nak-Yong Jung, MD; Chang-Won Jeong

Patients in the PPSS sample tended to be shorter compared to the national norm. Average age at the time of surgery was 14.2 years. Boys were older, taller, and heavier than girls at time of surgery. PPSS females tended to weigh more and had a higher body mass index (BMI). A higher percentage of males in the study group were black compared to females as most were white. Curve size was greater in patients in the 1st quartile of weight per/age compared to those in the 3rd quartile but curve magnitude was not differentiated by BMI. For all female study patients, age at menarche was not significantly different from national norms, with Black and Asian's experiencing menarche at a younger age.

The Comparison Shows the Angle of Pelvic Retro-Inclination of the Hip OA Without Dysplasia is Larger than that with Dysplasia.

Norberto Ventura, M.D,PhD; Anna M. Ey Batlle, Dr; Ramon Navarro, MD

The purpose of this study is to evaluate the sagittal alignment of the whole spine of the patients with hip osteoarthritis (OA) treated surgically with total hip arthroplasty (THA). The sagittal alignment was evaluated by the Jackson method statistically. And we also checked degenerative lumbar disease. The etiology of hip OA is different between cases with dysplasia and cases without dysplasia.

US and European Risser Grading Systems: Which One Best Predict the Curve Acceleration Phase in Adolescent Idiopathic Scoliosis?

Jim S. Yeom, MD; Jacob M. Buchowski, MD, MS; Kun-Woo Park, MD; Bong-Soon Chang, MD; Choon-Ki Lee, MD; K. Daniel Riew, MD

Two grading system exist for the Risser sign. The curve acceleration phase begin at a digital skeletal age (DSA) score of 400 - 425. The objective was to asses the disagreement between both grading system and evaluate the best estimator of the curve acceleration phase. 103 adolescent idiopathic scoliosis (AIS) patients were included. Risser sign (US and European) and DSA were calculated. Kappa statistic was 0.674 between the two syste Risser 1 was the best predictor of the curve acceleration phase.

The Comparative Study of Sagittal Alignment between Japanese Adult Volunteers and American Adult Volunteers

Prof. Se-Il Suk, MD, PhD; Prof. Jin-Hyok Kim, MD, PhD; Nak-Yong Jung, MD; Dong-Ju Lim, MD; Chang-Won Jeong

The purpose of this study is to evaluate the sagittal alignment of healthy adult volunteers from Japan comparing that of American volunteers according to Roger Jackson's analyzing method. There was a significant difference in sagittal alignment of the whole spine between Japanese adult volunteers and American adult volunteers. Japanese adult volunteers have less curved spine and C7 plumb line exists posterior rather than American adult volunteers.

Experimental Disruption of Spinal Muscle Tensegrity Has More Impact than Costotransversectomy on Induction of Scoliosis

Thanet Wathanaapisith, MD; Sarij Srisuparb, MD; Pumibal Wetpiriyakul; Surin Thanapipatsiri

Four different models of spinal tensegrity breakage with and without injury of the posterior paraspinal muscle were experimentally investigated on a pig model. Costotransversectomy with minimum or no damage of the posterior paraespinal muscles was enable to induce scoliotic deformity. Only those animals undergoing desinsertion of the paraespinal muscles with or without CTT developed scoliotic curves. Damage of the posterior muscle-ligamentous structures breaking muscles spine tensegrity was found to be decisive for scoliotic curve progression.

Evoked Potentials

Risk Factors for Spinal Cord Injury during Spinal Deformity Surgery: A Detailed Analysis of Somatosensory and Motor Evoked potential(SEP and MEP) in 162 Consecutive Patients

Prof. Se-Il Suk, MD, PhD; Prof. Jin-Hyok Kim, MD, PhD; Nak-Yong Jung, MD; Dong-Ju Lim, MD; Chang-Won Jeong

A total of 162 spinal deformity correction surgeries were reviewed and neuromonitoring analyzed. SSEP and MEP are affective to prevent neurological injuries. Rapid intervention after and 'EP event' can avoid significant complications. Patients with cardiopulmonary comorbidities have higher risks of having an 'EP event'.

Intraoperative Compound Muscle Action Potential Monitoring in the Treatment of Spinal Deformity

Takuya Yamamoto; Noriaki Kawakami, MD; Tsuji Taichi; Kosei Ijiri

We present the use of Compound Muscle Action Potential (CMAP) monitoring during surgery for spinal deformity in 347 cases. Although CMAP monitoring during surgery for spinal deformity demonstrated a relatively high percentage of false positive findings, most of them were easily recognized as a technical error and CMAP monitoring was found to be a very sensitive and reliable modality to prevent neurological deficits in the surgical treatment of spinal deformity

Assessment of Cervical Myelopathy Using Transcranial Magnetic Stimulation and Prediction of Prognosis after Laminoplasty

Prof. Jung-Hee Lee, MD; Prof. Ki-Tack Kim, Dr; Prof. Kyung-Soo Suk, MD, PhD; Prof. Sang-Hun Lee, ; Jin-Soo Kim

This study investigated the clinical usefulness of motor evoked potentials (MEPs) produced by transcranial magnetic stimulation of the brain for cervical myelopathy patients.

Effectiveness of Intraoperative Spinal Cord Monitoring in Patients with Scheuermann's Kyphosis: A Comparison to AIS Patients

Jack E. Zigler, MD; Rick B. Delamarter, MD; Jeffrey M. Spivak, MD; Raymond J. Linovitz, MD; Guy O. Danielson, MD; Thomas T. Haider, MD; Frank P. Camissa; Jim Zucherman, MD; Richard Balderston, MD; Scott H. Kitchel, MD; Kevin Foley, MD; David S. Bradford, MD; James J. Yue, MD; Michael Kropp, MD; Jeffrey Goldstein, MD

A retrospective analysis of intraoperative neuromonitoring (IONM) compared patients undergoing surgery for Scheuermann's kyphosis to those with AIS. Patients with Scheuermann's kyphosis were less likely to have isolated baseline MEP or SSEP data and were even less likely to have both MEP and SSEP (63.2 vs. 88.4%) data when compared to patients with AIS. There was a trend toward greater incidence of critical deviations from baseline monitoring in the Scheuermann's patients; however, this was not significant.

Intra-Operative Motor Evoked Potential Changes in Children Treated with Intra-Operative Skull-Skeletal Traction for Severe Coronal Plane Deformities

Wm B. Rodgers, MD; Curtis S. Cox, MD; Edward J. Gerber, PA-C
Retrospective review was performed of prospectively collected data of 41 consecutive patients undergoing scoliosis correction with intra-operative traction to facilitate correction of large scoliotic deformities. 12/28 AIS, 1/8 NMS, and 4/4 syndromic demonstrated traction-related changes in the MEP monitoring for a total of 17/40. Appropriate intra-operative measures were taken with reversal of the changes. There were no SSEP changes in any of the cases. We recommend the use of MEP monitoring when skeletal traction is used in this manner.

The Effect of Bone Mineral Density on Pedicle Screw Triggered EMG Threshold: A Comparative Study

Bin Yu, Master; Prof. Jianguo Zhang; Prof. Guixing Qiu; Prof. Yipeng Wang
Triggered EMG testing reliably assesses pedicle screw placement. However, the positive predictive value (PPV) of a low threshold value in osteopenic and osteoporotic individuals is very low. Low thresholds in this population are much less likely to indicate a pedicle breach than a normal bone density group of patients.

Multi-Pulse Stimulus-Evoked EMG for Detecting Medial Malplacement of Thoracic Pedicle Screws

Marie-Lyne Nault, MD, MSc; Stefan Parent, MD, PhD; Hubert Labelle, MD; Marjolaine Roy-Beaudry, MSc; Prof. Michèle Rivard
Intraoperative multi-pulse stimulus-evoked EMG is effective and safe in detecting medial malplacement of thoracic pedicle screws

Intraoperative Spinal Cord Mapping during Posterior Spinal Fusion for Scoliosis.

Georgios Bakaloudis; Mario Di Silvestre; Francesco Lolli; Prof. Patrizio Parisini
Spinal cord mapping using direct-cord motor evoked potentials is a feasible, useful and practical method for detecting localized corticospinal tract conduction aberrations during posterior spinal fusion for scoliosis.

Transcranial Motor Evoked Potential Monitoring for Scoliosis Surgery in Children. Learning Curve in our First 140 Cases

Junichi Ochiai; Prof. Koji Kanzaki; Kei Tateno; Keizo Sugizaki; Kyosuke Shiohara; Yohei Ishihara
TcMEP has gained increasing acceptance in pediatric spinal surgery. We evaluated positive signal changes and found a significant correlation to time since onset of use of the technique, age of the child, hypotension, high propofol infusion levels and anesthetic agent used.

Genetics

Mutations in T (Brachyury) Contribute to the Development of Vertebral Malformations

Romina Corrado, MD; Prof. Carlos Tello, MD; Santiago Balderrama; Eduardo Galaretto, MD; Mariano A. Noel, MD; Alejandra Francheri Wilson, Jr.; Ernesto S. Bersusky, MD
The vertebral patterning gene, T, was sequenced in a cohort of 50 patients with congenital vertebral malformations (CVMs). A c.1013C>T substitution resulting in a predicted Ala338Val missense alteration in exon 8 was identified in 3 unrelated patients with diverse congenital vertebral malformations spanning the entire length of the vertebral column. The mutation was also present in a clinically unaffected parent of each patient harboring the mutation, but was not observed in an ethnically diverse, 443-person control population. We infer that the observed T mutation is pathogenic and increases vertebral malformation risk.

Genetic Linkage Localizes the Adolescent Idiopathic Scoliosis and Pectus Excavatum Gene to the 18q Chromosome

Prof. Jianxiang Shen, MD; JinQian Liang, Doctor
Adolescent idiopathic scoliosis (AIS) and pectus excavatum (PE) are common musculoskeletal conditions known to have a genetic component. Our linkage analysis data of a single large family suggests that an AIS and PE susceptibility gene resides on chromosome 18q. In the near future, genome-wide association studies including hundreds or thousands of AIS and PE patients may confirm our linkage findings and allow for the identification of the genetic basis for these relatively common musculoskeletal disorders.

Role of CHD7 Gene in the Etiology of Familial and Sporadic Idiopathic Scoliosis Patients in Hong Kong

Prof. Patrizio Parisini; Francesco Lolli; Mario Di Silvestre; Georgios Bakaloudis
CHD7 gene, causing a familial syndrome of CHARGE, was recently associated with familial form of idiopathic scoliosis (IS). This study examines the common CHD7 genetic polymorphisms predispose to familial and sporadic IS in the Chinese population. Among the sporadic cases, SNP rs1483207 showed a borderline association at genotypic analysis ($p=0.03$) but it was not significant at allelic analysis ($p=0.6$). The absence of association with CHD7 gene in this study indicated that common variants in CHD7 might play only a minor role in genetic predisposition to sporadic IS, at least in the Chinese population. However, we cannot exclude the presence of family-specific (private and rare) mutations in CHD7 causing familial IS by this approach.

Evaluation of 97 Patients with Prader Willi Syndrome. Incidence, Evolution, Treatment, and Complications in Patients who Developed Deformity.

Michael D. Roth, BS; Anne M. Padberg, MS, CCCA; Keith H. Bridwell, MD; Lawrence G. Lenke, MD; Timothy Kuklo, MD, JD
Prader Willi syndrome is a congenital disorder. Retrospective charts and X-rays review of 97 patients with Prader Willi syndrome. 18.5 % of Prader Willi patients had scoliosis and 50% of them underwent surgical treatment. All cases of surgical scoliosis had an early onset at a mean age of 4.10 years. Surgical treatment is associated with an incidence of complications as high as 61%. Complications were most severe in patients who underwent anterior approaches.

Evaluation of 74 Patients with Diagnosis of Spinal Muscular Atrophy (SMA). Incidence, Evolution, Treatment, and Complications in Patients with SMA Type II who Developed Deformities.

Marc A. Asher, MD; Douglas C. Burton, MD; Sue-Min Lai, PhD, MS MBA; Jeff L. Gum; Brandon B. Carlson, BS
SMA is characterized by progressive symmetric muscular weakness. Retrospective charts and X-rays review of 74 patients with diagnosis of SMA. 50% of the patients had SMA type II. 83% of the patients developed scoliosis of who 65% required surgical treatment. 100% of SMA type II patients who needed a wheel chair before the age of 11 years developed progressive scoliosis requiring surgical treatment. Surgical treatment was associated with a low rate of complications (4%).

The Effects of Transforming Growth Factor-1 on Aggrecan Synthesis and Cellular Proliferation on Intervertebral Disk Cells In-Vitro

Guney Yilmaz; Prof. Muharrem Yazici, MD; Gokhan H. Demirkiran; Kenan Daglioglu; Gazi Huri; Cenk Ozkan
Transforming growth factor -1 (TGF -1) belongs to a family of growth factors that influences cellular activities including growth, differentiation and extracellular matrix synthesis. This study suggests that TGF -1 has a stimulatory effect on proteoglycans synthesis in the intervertebral disc.

Growing Spine

Cotrel Derotation Casting for Progressive Infantile Scoliosis

Yushu Bai; Xiutong Fang, MD; Suxi Gu; Prof. Ming Li, MD
Serial casting using the Cotrel derotation technique is one of several potential treatments for progressive infantile scoliosis. This study reviews our early experience of 53 patients with progressive infantile scoliosis undergoing serial casting. The Cotrel technique of derotation casting appears to play a role in the treatment of progressive infantile scoliosis with cures in young patients and reductions in curve size with a delay in surgery in older and syndromic patients.

Prior Fusion Surgery to Make Secure Foundation for Instrumentation in Treatment of Severe Spinal Deformity in Young Children

Melvin D. Helgeson, MD; Ronald A. Lehman, Jr., MD; Anton E. Dmitriev, MSc; Scott J. Luhmann, MD
Six children treated with prior fusion surgery to make secure foundation for instrumentation were reviewed. In all patients, secure anchor points which could stand enough corrective force were obtained .

Characterize Vertebral Growth in Normal Pediatric Patients Using Magnetic Resonance Imaging

Prof. Ming Li, MD; Yushu Bai; Xiutong Fang, MD; Suxi Gu
A retrospective study was done to determine the pedicle, vertebral body, and spinal canal morphology and growth in the normal infantile and juvenile patients using MRI. It provided significant information for the treatment of early onset spinal deformities.

Are There Psychological Effects of Repeated Spinal Surgery in Children?

Shisheng He; Jianqiang Ni, MD; Suxi Gu; Prof. Ming Li, MD
Repeated spinal surgery in children does not seem to disturb the child's psychological health.

Orthopaedic Management of Caudal Regression Syndrome

Prof. Carlos Tello, MD; Mariano A. Noel, MD; Romina Corrado, MD; Eduardo Galaretto, MD; Alejandra Francheri Wilson, Jr.; Ernesto S. Bersusky, MD
Caudal Regression Syndrome (CRS) is characterized by the absence of the entire sacrum and variable amounts of the lumbar and occasionally thoracic spine accompanied by a number of congenital visceral abnormalities. The condition is described by means of an interesting case and discussion is made of the challenging and often controversial management of the associated abnormalities with a review of literature.

Blood Hemoglobin Levels Improve after Treatment of Congenital Scoliosis and Rib Fusions with VEPTR. Hemoglobin Level may be a Useful Surrogate Measure of Respiratory Function in TIS and Early Onset Scoliosis

Sheetal Mohite; Raghu Varma, MS(ORTH)DNB; Abhay Nene; Shekhar Bhojr.aj
Treatment of patients with congenital scoliosis and fused ribs by VEPTR (Vertical Expandable Prosthetic Titanium Rib) and expansion thoracostomy improved blood hemoglobin levels.

Design and Animal Study of a Growth-Preserving Spinal Instrumentation with Sliding Ring Pedicle Screw

Douglas C. Burton, MD; Marc A. Asher, MD; Sue-Min Lai, PhD, MS MBA
A animal test in vivo of a new developed sliding pedicle screws and rod system designed for early onset spine deformity.

Pedicle Screw Tethering Scoliosis Model in Immature Goat: The Feasibility Reliability and Complications

Guy Klein; Charles T. Mehlman, DO, MPH; Mary McCarty, BS
To observe that unilateral pedicle screws asymmetric tethering in concave side in combination with convex rib resection for creating idiopathic-type deformity

New Spinal Growing Rod Expandable Without Surgery: Preliminary Results about 15 Cases

Avraam Ploumis, MD, PhD; Amir A. Mehbod, MD; Ensor E. Transfeldt, MD;

Preliminary results about 15 cases treated with the Phenix M. Rod, a new spinal growing rod expandable with an external magnet activating an internal one fitted inside the device. We show that this new approach preserves spine and thoracic growth, uses less surgery, achieves a lower complication rate and improves the quality of life more than current progressive spinal deformities treatments in young children.

Growing Rod Instrumentation and Vertebral Body Growth. A Radiological Investigation in Immature Pigs

Leah Y. Carreon, MD, MSc; Mitchell J. Campbell; Steven D. Glassman, MD; Michael Shainline, MS

The aim of this study is to evaluate the vertebral body growth under distraction forces in immature pigs treated with growing rod technique. The vertebral growth continues during growing rod instrumentation. Distraction forces might stimulate also apophyseal growth of axial skeleton.

Iatrogenic Thoracic Outlet Syndrome as a Complication of VEPTR

Shisheng He; Jianqiang Ni, MD; Suxi Gu; Prof. Ming Li, MD

This study identifies potential etiologies for compression of the brachial plexus in individuals who undergo the VEPTR procedure, and suggests strategies to reduce the incidence of this complication.

The Effect of a New Modification of the Growing Rod Technique on the Success Rate: Distal and Proximal Pedicle Screw Fixation, Dual Rod Application and Routine Lengthening at Every 6 Months

Mehmet Aydogan; Cagatay Ozturk; Mehmet Tezer; Meric Enercan; Omer Karatoprak; Azmi Hamzaoglu

As shown in 14 EOS patients instrumented with dual growing rods with pedicle screws as anchors, this modification of the technique controls deformity better in all planes, maintains vertebral growth and lowers complication rates.

Infection

Primary Paraspinal Hydatid Cyst Treated with PAIR Technique

Mitchell J. Campbell; Leah Y. Carreon, MD, MSc; Vincent C. Traynelis, MD; Paul A. Anderson, MD

En bloc resection without inducing rupture and spreading the daughter cyst is recommended and accepted to be curative for intramuscular hydatid cyst. We report a case of primary hydatid cyst of the erector spinae muscle which was treated successfully with ultrasonography guided puncture, aspiration, injection of 95% ethanol and re-aspiration (PAIR) technique.

Postoperative Spine Fusion Infections Following the Use of Either Irradiated Allograft, Non-Irradiated Allograft, or Autograft

Thuc-Quyen Nguyen; Jennifer Buckley; Prof. Jeffrey Lotz; Christopher P. Ames, MD; Vedat Deviren, MD

This study reports the incidence of post-operative infection following the use of irradiated allograft, nonirradiated allograft and autograft in spine fusion procedures. 1435 patients with a minimum potential 1-year follow-up were identified. Irradiated allograft was used in 144 patients, non-irradiated allograft in 441, and autograft in 850. Risk factors such as smoking, diabetes, steroid use, and local radiation were also noted. No significant difference ($p=0.51$) in the rate of infection was observed between the three groups. Infections were significantly more prevalent among smokers ($p=0.004$).

Safety and Efficacy of Adjunctive Local Application of Vancomycin Powder for Infection Prophylaxis in Posterior Instrumented Thoracic and Lumbar Spine Surgical Wounds Compared to Intravenous Antibiotics.

Naresh S. Kumar, Dr, MBBS;MS(Orth);DNB(Orth);FRCSEd;FRCS(Orth);DM(Orth); Veda Gowda, , MBBS: MS(Orth); FRCS; Aravind Kumar, Dr, MBBS;FRCS Ed; FRCS

A retrospective evaluation of infection rates for instrumented thoracic and lumbar fusions with and without adjunctive local vancomycin powder in 652 consecutive cases.

Single Stage Posterior Alone Global Instrumented Fusion Surgery with Local Bone Grafts in the Treatment of Instability or Deformity following Spinal Tuberculosis – Report on Initial Sixteen Cases.

Frank L. Acosta, Jr., MD; Vincent Wang; Christopher P. Ames, MD

Single stage posterior alone global instrumented fusion surgery with local bone grafts in the treatment of instability or deformity following spinal tuberculosis has resulted in good clinico-radiological outcome in a pilot study of sixteen patients. Although the surgery is technically demanding, and requires good anaesthesia back-up, all the problems due to the disease are tackled in one go.

Early Diagnosis of Surgical Wound Infection Following Spinal Instrumentation Surgery

Siddharth A. Badve, MS(Orthopaedics), MBBS; Shekhar Bhojraj; Abhay Nene; Raghu Varma, MS(ORTH)DNB; Sheetal Mohite; Shailesh Hadgaonkar, MSOrth, D.Orth., FCPS.Orth; Ankur Gupta, MS - Orthopedics; Rahul D. Choudhari, MS(Orthopaedics)

Less than 10% of the percentage of lymphocytes, 800/ μ l of the number of lymphocytes and more than 80% of the percentage of neutrophils on Day 4 are early diagnosis of surgical wound Infection after spinal Instrumentation surgery.

Sterility of C-Arm Fluoroscopy During Spinal Surgery

Jack E. Zigler, MD; Rick B. Delamarter, MD; Richard Balderston, MD; Jeffrey M. Spivak, MD; Raymond J. Linovitz, MD; Jim Zucherman, MD; James J. Yue, MD; Thomas T. Haider, MD; Scott H. Kitchel, MD; Frank P. Camissa; Guy O. Danielson, MD; Michael Kropp, MD; Jeffrey Goldstein, MD

We analyzed the sterility of twenty-five C-arm drapes after their use in spine surgery. Sterile culture swabs were used to sample five defined locations on the C-arm drape postoperatively. Samples were assessed for bacterial growth on 5% sheep blood agar using a semiquantitative technique. The uppermost portions of the C-arm drape developed significantly greater contamination than negative controls. Contamination of these sites most likely occurs from contact with undraped portions when the unit is rotated to obtain lateral images.

Do Preoperative Steroid Injections Increase the Risk of Postoperative Infection?

Patrick J. Cahill, MD; Amer F. Samdani, MD; Ashish Ranade, MD; Jennifer Brey, MD; M. Darryl Antonacci, MD, FACS; JahanGir Asghar, MD; David H. Clements, III, MD; Randal R. Betz, MD

In this series, ESI is associated with an increase in postop infection, especially when receiving 3 or more injections.

Management of Lumbar Pyogenic Spondylitis with Posterior Decompression and Interbody Fusion Using Transpedicular Screws

Jean A. Ouellet, MD; Prof. Vincent Arlet, MD

Fourteen patients with lumbar pyogenic spondylitis who underwent posterior decompression and lumbar interbody fusion were investigated retrospectively. There was no recurrence of infection and breakage of instrument. Stable interbody fusion was achieved in all the cases. Postoperative interval to achieve normal CRP was 28.7(10-64) days. Ambulation was started on 5.8(2-19)th day. Loss of correction at final follow-up showed less than 1 degree. Posterior instrumentation seems to be an effective method both in stabilizing the spinal column and eradicating the infection in lumbar pyogenic infection.

Outcome of Surgery for Scoliosis in Patients with Myelomeningocele

John T. Smith, MD; Melissa S. Smith, BS RN

We performed retrospective review of spinal fusion surgeries for children with myelomeningocele using a comprehensive registry of all patients followed at our institution over 35 years. Malnourished patients with preoperative active urinary tract infections or those with urinary tract infections alone had significantly greater rates of major and minor complications ($p=0.001$ and $p=0.002$) with wound infections accounting for the majority of these.

Radical Debridement and Kyphosis Correction Using Titanium Mesh Cages in Resistant Tuberculous Spondylodiscitis of the Cervical Spine. Is it Safe?

Kathryn A. Keeler, MD; Ronald A. Lehman, Jr., MD; Lawrence G. Lenke, MD; Keith H. Bridwell, MD; Brenda A. Sides, MA

Twenty one patients with cervical spondylodiscitis and advanced kyphus deformity had radical debridement, decompression and instrumentation by a self-locking plate. The anterior column was reconstructed with a titanium mesh cage in 12 patients (Group 1) and an autogenous iliac bone strut graft in 9 (Group 2). Group 1 showed a better sagittal profile and local kyphosis correction. Group 2 showed a higher incidence of graft related complications. Group 1 patients showed a solid bony fusion without recurrence of infection.

Transforaminal Lumbar Interbody Fusion (TLIF) in the Treatment of Pyogenic Spondylodiscitis

Michael Faloon, MD; Arash Emami, MD; Ki Soo Hwang, MD; Faisal Mahmood; Kumar Sinha, MD; Edward Milman

Adequate removal of the infected bones, endplates, and abscesses in the anterior and posterior spine can be successfully achieved with TLIF, thus avoiding the morbidity associated with the anterior approach. Via a single posterior approach alone, TLIF using local bone grafts augmented by pedicle screw fixation can provide satisfactory results in pyogenic spondylodiscitis of the lumbar spine.

Late-Developing Infection Following Posterior Instrumented Surgery for Scoliosis

Brett A. Freedman, MD; William Horton, MD; John M. Rhee, MD; David Wootten, PhD; Charles Edwards, II, MD; Timothy Kuklo, MD, JD

From a total of 540 patients who underwent posterior-only fusion for idiopathic scoliosis from 1993 through 2005, fifteen patients (2,77%) were surgically revisioned due to a late-developing post-operative infection. There were 6 males and 9 females, average age at initial surgery 22,8 years (range,14-27), average age at revision procedure 29,1 years(19-35), with infection occurred at a mean 70 months (15-195) after the index procedure. Late-developing postoperative infection in scoliosis surgery can be treated only by means of a complete removal of the implant, continuous drain and short-term adequate antibiotic therapy anti-biogram-based.

Use of the Vacuum Assisted Closure in Pediatric Scoliosis Patients with Deep Spinal Infections

Mary McCarty, BS; Charles T. Mehlman, DO, MPH; Twee T. Do, MD; Junichi Tamai, MD; Alvin Crawford, MD; Guy Klein; Jun Ying, PhD; Cassie L. Kirby, BA

Post-operative deep infections are still relatively common in instrumented spinal deformities of children affected by spinal dysraphism or other chronic debilitating conditions. When it does occur, it can result in considerable morbidity, cost, and compromise of correction. The use of wound VAC system has gained increasing popularity in the management of acute, sub acute and chronic wounds

Delayed Dressing Change Does not Lead to Increased Infection Rate.

Edmond Lou, PhD; Douglas L. Hill, P.Eng, MBA; Eric C. Parent, P.T., MS c., PhD; Marc Moreau, MD FRCS(C); Douglas Hedden, MD, FRCSC; Jim Mahood; Jim Raso, M.A.Sc.

Leaving post-operative dressings in place for 4-5 days post-op; 1) does not lead to increased infection rates; 2) can substantially decrease effort spent on dressing changes; 3) and may decrease infection risk.

Is Atlanto-Axial Tuberculosis Different? Its Altered Biomechanics and Management Strategies.

Anton E. Dmitriev, MSc; James L. Chappuis, MD; Melvin D. Helgeson, MD; Philippe E. Pare, M.A.Sc.; Allison C. Gasperut, Bachelors of Science; Raja Rampersaud, MD, FRCSC; Ronald A. Lehman, Jr., MD

Specific anatomy and osseoligamentous structures make atlanto-axial junction vulnerable to instability. Tuberculosis leads to significant osseoligamentous destruction leading to instability. This clinico-radiological classification of atlanto-axial tuberculosis has been formulated which helps in deciding management. The type and extent of fixation is guided by this classification. In case of significant destruction occipito-cervical fusion is the only answer. Grading of the atlantoaxial tubercular pathology and its management according to the tested protocol would deliver a long lasting beneficial result.

Early Mobilization and Pain Control in Spondylodiscitis Using Percutaneous Instrumentation

Toshiaki Kotani, MD; Shohei Minami, MD; Hiroyuki Motegi; Tetsuharu Nemoto; Tsutomu Akazawa, MD; Shigeyuki Nagaya

Review of 30 consecutive cases of active thoracolumbar spondylodiskitis treated with posterior percutaneous pedicle screw instrumentation for spinal immobilization and/or debridement for surgically indicated cases was conducted. Patients mobilized without a brace at 2.3 days and were discharged at an average of 7 days. Significant Reduction in Narcotic Requirements were noted.

Posterior Transdiscal Three Column Shortening Osteotomy in the Surgical Treatment of Vertebral Osteomyelitis

Warren D. Yu, MD; David Goodwin, BA; Joseph R. O'Brien, MD, MPH; Josue Gabriel, MD; Kingsley R. Chin, MD

Posterior-only three-column transdiscal resections in 5 patients requiring surgical treatment for discitis/osteomyelitis with minimum 2 year follow-up were retrospectively reviewed. Local sagittal correction was 31.4°. There were no pseudarthrosis or infection recurrence at the affected level. All patients reported improvement of ODI and VAS scores. No neurologic deterioration was reported, 2 patients improved from ASIA B to D and E respectively. This technique provides fusion and deformity correction in a single approach without the need for long anterior strut grafts

Innovative Methods

Transforaminal Anterior Release as an Alternative to Pedicle Subtraction Osteotomy for Sagittal Deformity Correction and Spondylolisthesis Reduction.

Harvey E. Smith, MD; Theresa Freeman, PhD; Bala T. Susarla, PhD; Thomas P. Schaer, VMD; Aviva Symes, PhD; D. Greg Anderson, MD; Todd J. Albert, MD; Irving M. Shapiro, PhD; Makarand V. Risbud, PhD

A transforaminal approach for anterior annular release is described and example cases presented for sagittal and coronal deformity.

Results of Spine to Rib Cage Distraction in the Treatment of Early Onset Scoliosis

Masaya Ishida; Prof. Koji Kanzaki; Kei Tateno; Keizo Sugizaki; Kyosuke Shiohara; Junichi Ochiai; Yohei Ishihara; Yusuke Oshita

The use of spine-to-rib growing rods for the treatment of EOS provides similar correction and complication rates to those published in the series considering traditional single or dual growing rod systems. Due to the high rate of instrumentation failure the Authors recommend revision of the implant design.

Continued Spinal Growth in EOIS: Single Rod Instrumentation Without Fusion

Matthew M. Kang, MD; Joshua Marcus; Anthony K. Frempong-Boadu, MD

Technique of single rod pedicle screw instrumentation without fusion

Ball-Tip Probe Method for Placement of Thoracic Pedicle Screws in Adolescent Idiopathic Scoliosis Surgery

Woojin Cho, MD & PhD; Chunhui Wu, PhD; Amir A. Mehdob, MD; Ensor E. Transfeldt, MD

Use of a flexible ball-tip probe in screw hole preparation for pedicle screw placement in the thoracic spine significantly enhances the accuracy of screw placement compared with conventional method.

Establishing a (Standard) Nomenclature for Procedures Designed to Address Anterior Spinal Pathology Through a Posterior-Only Approach

John A. Bendo, MD; Martin Quirno, MD; Mary Cunningham; Jonathan R. Stieber, MD; Jonathan R. Kamerlink, MD

Various authors have reported their results of vertebral body resections and osteotomies with numerous name modifications of the "Eggshell Procedure". This presentation reviews the history, maturation process, and technical improvements in these procedures over the past 60 years. Additionally, common terminology is presented.

Spinal Hemiepiphyodesis by Modified Staple Induces Curvatures

Jacob M. Buchowski, MD, MS; Christopher R. Good, MD; Lawrence G. Lenke, MD; Keith H. Bridwell, MD

Spinal hemiepiphyodesis using a staple-like implant and thoracoscopic procedures which were modified for possible clinical trial induced spine curvatures in a porcine model.

The Uniplanar Screw: A New Tool in the Surgical Treatment of AIS

Kenneth R. Gundle, BA; Jean H. Mullins, BA; Stephan L. Pro, MD; Lynn M. Marshall, ScD; Robert A. Hart, MD

Restoration of thoracic kyphosis in patients who are typically hypokyphotic or lordotic is an important consideration in the surgical correction of AIS. While surgical techniques such as rod contouring and derotation may also be important, the choice of vertebral anchors appears to affect the outcome of post operative thoracic kyphosis. The uniplanar screw provides similar coronal plane correction as fixed angle and polyaxial screws while facilitating improved restoration of thoracic kyphosis.

Low Profile Pelvic Fixation: Anatomic Parameters for Sacral Alar-Iliac Fixation vs Traditional Iliac Fixation

Bradford A. Wall, MD; Alan Moskowitz, MD; M. Camden Whitaker, MD; Teresa L. Jones, MPH, MT(ASCP); Catherine Maben, LRTRCT

Compared to traditional iliac fixation of insertion through the posterior superior iliac spine (PSIS), insertion of iliac anchors through the S2 ala may provide nearly equal length with a starting point that is more in-line and 1.9cm deeper. Three-dimensional radiographic analysis describes an ideal pathway of approximately 40 degrees of caudal and lateral angulation for this technique.

A Technical Report on the Phenix M Rod, an Expandable Rod Linkable to the Spine, Ribs or the Pelvis and Controllable at Home by Hand Through the Skin with a Palm Size Permanent Magnet for the Treatment Of Scoliosis

Lawrence G. Lenke, MD; Timothy Kuklo, MD, JD; B. Stephens Richards, MD; Daniel J. Sucato, MD MS; Keith H. Bridwell, MD; Spinal Deformity Study Group;

The Phenix M rod is an expandable rod linkable to the spine, ribs or the pelvis and controllable by hand with a permanent magnet that was developed and implanted in 16 children. Its growth potential can be up to 60mm by 1/60 of mm increments. Easy incremental lengthening allows pain free gradual home lengthening of the rod. It may spare surgeries, improve correction, quality of life, lower costs and attenuate the frontier between flexible and rigid curvatures.

Endoscopic Transcervical Ventral Decompression of Craniocervical Deformities

Alphonse Lubansu; Prof. Pirotte Benoit; Michael Bruneau, MD; Prof. Dewitte Olivier, MD, PhD

The endoscopic transcervical approach (ETA) is a novel minimally invasive treatment for irreducible compression of the brainstem and spinal cord and has been previously described by us. This approach avoids complications associated with transoral routes. 12 patients underwent the ETA and showed improvement in Ranawat and JOA scores with minimal complications.

Assymetric Posterior Thoracic Vertebral Column Resection (VCR) in Complex Pediatric Spinal Deformity: A New Procedure.

Woojin Cho, MD & PhD; Chunhui Wu, PhD; Prof. Serkan Erkan, Assistant Professor; Amir A. Mehbod, MD; Ensor E. Transfeldt, MD
Assymmetric posterior thoracic VCR is a safe effective method of correction of severe spinal deformity in the pediatric age group.

A Novel Cervical Disc Replacement Device BAGUERA C: Design and Biomechanical Characteristics.

Prof. Serkan Erkan, Assistant Professor; Prof. Tackin Ozalp; Prof. Huseyin Yercan; Prof. Guvenir Okcu

Anterior treatment options for cervical degenerative disc disease (DDD) were limited to fusion. The potential for spinal arthroplasty in the treatment of cervical DDD has been recently supported by clinical data.

Footprint Analysis Following Thoracolumbar Corpectomy and Reconstruction

Prof. Serkan Erkan, Assistant Professor; Chunhui Wu, PhD; Amir A. Mehbod, MD; Woojin Cho, MD & PhD; Ensor E. Transfeldt, MD

An analysis of the amount of vertebral endplate coverage following thoracolumbar corpectomy was performed.

Effect of Intra-Operative Tensioning of an Anterolateral Spinal Tether on Spinal Growth Modulation in a Porcine Model

James A. Sanfilippo, MD; Joon Y. Lee, MD; Ahmad Nassr, MD; Jeffrey A. Rihn, MD; Todd J. Albert, MD; Alan S. Hilibrand, MD;

An anterolateral spinal tether has been used previously to modulate spinal growth in animal models and has been proposed as a non-fusion treatment strategy for idiopathic scoliosis. In this study, intra-operative tensioning of the tether created a significantly greater immediate post-op coronal deformity, as well as a greater ultimate deformity and vertebral body wedging at 6-months post-op, without evidence of failure at the bone-screw interface.

The Role of PEEK Hourglass for Segmental Lordotic and Sagittal Balance Reconstruction of the Interbody Space in Instrumented Lumbar Fusions

Joseph I. Krajchich, MD; Federico Canavese, MD; Sanjeev Gupta; Khaled M. Emara, MD

A Study was performed to see the efficacy of a PEEK implant for stabilization of the lumbar disc space with good clinical and radiographic outcomes with no subsidence, no implant failure and only two cases of graft migration

Safe Entry of Thoracic Pedicle Screws: A Morphometric Analysis

Ryan C. Goodwin, MD; Premjit S. Deol, DO

We analysed 62 CT scans to assess whether thoracic pedicle screws could safely be introduced using a novel anatomical landmark. We found that this is safe in 99.7% of thoracic pedicles.

Comparison of Accuracy of Pedicle Screw Placement Between Radiography Assisted versus Image Guidance Surgery During Instrumented Posterior Thoracic and Lumbosacral Spine Surgery

Jean-Francois Caubet, MD, MS; John B. Emans, MD; John T. Smith, MD; Norman Ramirez; John Flynn, MD; Michael G. Vitale, MD MPH; Tricia St. Hilaire, BS

Complications from malpositioned pedicle screws include construct instability and neural tissue damage. Aside from sound surgical skills, use of radiography to assist screw positioning remains a standard in some centers. However screw malplacement is still very high even with use of radiography. Image-guided surgery (IGS) offers better visualization of spinal anatomy for more accurate screw positioning. IGS was shown to significantly reduce intraoperative pedicle screw malpositioning in thoracic and lumbosacral pedicle screw insertion compared with adjunct use of serial radiography.

Multilevel Posterior Vertebral Osteotomy for Correction of Severe and Rigid Neuromuscular Neuromuscular Scoliosis— A Preliminary Study

Prof. Nelson L. Tang; Hiu Yan Yeung, PhD; Harris Fan; Hoi Kei, Rachel Kwok; Vivian W. Hung; Kwong Man Lee; Tsz-ping Lam, M.B.,B.S.; Bobby Kin-wah Ng; Prof. Yong Qiu, MD; Prof. Jack Chun Yiu Cheng, MD

For correction of severe and rigid scoliotic curve, combined or posterior vertebral column resection procedures are used. Anterior release is a burden for patient with already compromised pulmonary functions and posterior column resection carries a high risk of neurologic damage and massive intraoperative bleeding. Therefore, authors developed a new technique, which avoids both.

Iliizarov External Fixator for Severe Congenital Spinal Deformity. Report of 7 Cases

Jean A. Ouellet, MD

We describe the technique and evaluate the results of 7 severe and rigid congenital scoliosis patients. Cobb angle before operation was 97 degrees and 45 degrees after operation (55% correction). No major complications such as death or paraplegia excluding one deep infection case. External fixator correction is a safe, well-tolerated method of applying gradual, sustained traction to maximize postoperative correction in this difficult population.

What is Ideal Starting Point and Trajectory for Pedicle Screw Placement? CT Analysis of Pedicle Screw Placed Using a Novel Simple Guide-Pin

Brian K. Kwon, MD, PhD; Josee Roy, PhD; Jae H. Lee, BSc; Anthea M. Stammers, MSc; Jeffrey Marx, PhD

Postoperative CT scans of 173 titanium pedicle screws (77 lumbar and 96 thoracic) placed into 2 cadaver spines and 18 patients using a novel simple, safe, and effective guide-pin demonstrated very accurate PS placement without preoperative CT scan and intraoperative fluoroscopic assistance

A Novel, Percutaneous Bilateral Facet Augmentation Device for Lumbar Degenerative Disc Disease (DDD): Early Results

Cary Idler, MD; Ravinder Bains, MD; Kurt VanPeteghem, MD; Timothy Huang, MD; Andrew Slucky, MD; Josef Gorek, MD

This is a prospective, non-randomized study to investigate safety and efficacy of a new percutaneous device, PercuDyn, for patients presenting mild/moderate DDD and concordant X-ray/MRI who have failed conservative treatment for at least 6 months. Safety is assessed by documenting any intra-operative and post-operative vascular and neurological complications. Effectiveness is evaluated by recording pre-op and post-op, at 6w, 3m, 6m, 12m and 18m, ODI and VAS scores. In addition, operation time and the length of hospital stay were recorded.

Posterior Thoracotomy a Two-Step Spinal Thoracic Approach; Evaluation of 35 Cases

Warren D. Yu, MD; Joseph R. O'Brien, MD, MPH; David Goodwin, BA; Thomas E. Mroz, MD; Kingsley R. Chin, MD

to assess the range of possibilities and complications associated with an approach that allows for the combination of a two-step surgery through a single posterior skin incision.

Accuracy and Safety of Percutaneous Lumbosacral Pedicle Screw Placement Utilizing Intra-Operative Dual-Planar Fluoroscopy

Mauricio A. Campos Daziano, Medical Doctor; Bobby Tay, MD; Vedat Deviren, MD; Christopher P. Ames, MD; Sigurd Berven, MD; Shane Burch;

This is a retrospective case series evaluating the percutaneous placement of lumbosacral pedicle screws in 87 consecutive patients. The procedures were performed percutaneously using intra-operative dual-planar fluoroscopy. We reviewed lumbosacral pedicle screw position using radiographs and computed tomography. We then analyzed the data for accuracy of screw placement and patient safety. Interobserver reliability was calculated.

Assessment of Computed Tomography-Generated Virtual Endoscopy of the Spinal Canal.

Richard J. Bransford, MD; David W. Stevens, MD; Carlo Bellabarba; Prof. Jens R. Chapman, MD

The applicability of virtual endoscopy to the diagnosis of lesions of the spine was investigated using CT in 14 patients with degenerative lumbar disease, spinal injury, or spinal deformity. Virtual endoscopy provided three-dimensional visualization of intraspinal anatomic structures. The results of this study demonstrated the ability of virtual endoscopy to provide more extensive visualization of intraspinal structures compared with conventional cross-sectional images.

Prospective Evaluation of the Interest of a Free-Hand Electrical Conductivity Measuring Device to Reduce Radiation Exposure During Fluoroscopically Assisted Pedicle Screw Fixation

Cary Idler, MD; Ravinder Bains, MD; Josef Gorek, MD; Kurt VanPeteghem, MD; Andrew Slucky, MD; Timothy Huang, MD;

Fluoroscopically assisted pedicle screw fixation is associated with high amounts of irradiations for patient and surgical staff. Strategies to reduce this exposure are recommended. This study suggests that a free-hand electrical conductivity measuring device, used to prevent pedicle cortical breaches and optimizing positioning of screws, allows significant reduction of the amount of radiation exposure to the patient and therefore to the spinal surgeons during posterior pedicle screw fixation.

Cervico Acetabular Angle: A Radiological Marker to Help in Achieving Sagittal Balance in Spinal Deformity Surgery

Shekhar Bhojr.aj; Abhay Nene; Sheetal Mohite; Raghu Varma, MS(ORTH)DNB; Siddharth A. Badve, MS(Orthopaedics), MBBS

A novel radiological marker is describe and has been check for reliability using 30 patients having undergone posterior spinal fusion for AIS. The angle from the center of the hips to C7 and the vertical axis measure 4 and represents the cervico acetabular angle. This value remains constant in patients in sagittal balance

Anatomic and Radiographic Landmarks for the "Iliac Pedicle": Intraoperative Identification of the "Iliac Teardrop" Facilitates Placement of Iliac Screws During Spinal Reconstruction

Kit Song; Klane K. White, MD, MSc.; Nathan Frost; Joe Eichinger; Dana C. Matthews, MD

Intraoperative fluoroscopic identification of the "Iliac Teardrop" allows access to the "Iliac Pedicle" for safe and efficient placement of iliac screws

A Versatile Approach for Lesions of Dorsal Spine

Shekhar Bhojr.aj; Abhay Nene; Raghu Varma, MS(ORTH)DNB; Sheetal Mohite; Siddharth A. Badve, MS(Orthopaedics), MBBS

Dorsal spine can be approached by various described approaches. Usually for direct anterior and posterior procedures we need to do surgery by different positioning of patient and by using separate incisions may be under same sitting or staged procedure. The described versatile approach is unique in combining the advantages of different described approaches and modifying it to allow surgeon to perform decompression, correction, reconstruction and stabilization under direct vision using single incision, in a single position in, shorter time frame.

Reliability and Validity of 3D Body Scanner Technology for Measuring Axial Skeletal Alignment

Yutaka Sasao, MD, PhD; Haruyasu Kato; Prof. Haruhito Aoki; Yoshiaki Torii; Atsushi Kojima

The 3D body scans of twenty three participants without axial skeletal deformity were compared to 20 participants with deformity before and after PSIF. AP and ML shift and rotation of an ellipse of best fit for each slice were calculated. Within day reliability and discriminative validity were demonstrated. 3D scanner technology is a promising technology to reliably and objectively document axial skeletal deformity and its response to treatment.

Early Clinical Results of a Novel Posterior Dynamic Stabilization System for Degenerative Lumbar Spinal Disorders

Prof. Yan Wang; Xuesong Zhang, MD; Zheng Wang; Songhua Xiao

A novel pedicle screw/rod based dynamic stabilization system was used in 70 patients with degenerative disorders in the lumbar spine requiring stabilization. Significant improvement in ODI and VAS scores was observed and no implant failures were observed at a mean follow-up of 7.2 months.

A New Technique of Three-Dimensional Deformity Correction by Direct Vertebral Rotation and Translation with Uniaxial Extended Tab Reduction Pedicle Screw Fixation in Adolescent Idiopathic Scoliosis

Yonggang Zhang; Prof. Yan Wang; Zheng Wang; Guoquan Zheng
Uniaxial extended tab screws implants are available for the correction of spinal deformity. These implants combine both de-rotation and translation through the application of forces via the uniplaner extended tab screw head. A retrospective radiographic evaluation was performed of 41 Lenke type I AIS patients treated with segmental pedicle screw fixation utilizing uniaxial extended tab reduction screws. Excellent instrumented correction of all of the radiographic parameters was achieved. Uniaxial extended tab reduction screws provide a high degree of coronal and sagittal deformity correction in AIS.

A Comparison of Infection Rates in Minimally Invasive vs. Open TLIF's – A Single-Surgeon Retrospective Review

Xuesong Zhang, MD; Prof. Yan Wang; Songhua Xiao; Yonggang Zhang
Recent technical advances have allowed surgeons to perform Transforaminal Lumbar Interbody Fusions (TLIF's) through a minimally invasive paramedian approach using tubular retractors. One of the many perceived advantages is reduction in infection rates. This study represents a single surgeon's consecutive experience of both minimally invasive and open TLIF's. Infection rates – as defined by need for surgical irrigation and drainage – were significantly higher in the open vs. minimally invasive TLIF's, 3.6% vs. 0.0%. We believe that this represents a previously unreported advantage of minimally invasive lumbar fusion surgery.

The Impact of Gravity Line on the Quality of Life in Patients with Spinal Deformity

Keya Mao; Prof. Yan Wang; Xuesong Zhang, MD; Zheng Wang
A new technique for evaluating gravity line (GL) was used to prospectively evaluate coronal and sagittal balance in patients with adolescent idiopathic scoliosis (AIS) and in adults with spinal deformity. Sagittal GL was correlated with quality of life in adult deformity patients, suggesting that assessment of GL is clinically relevant in these patients. The absence of correlation between GL and quality of life in AIS suggests that these patients better compensate for disturbance in GL location.

Monoaxial Screws vs. Uniaxial Extended Tab Reduction Screws in the Surgical Correction of AIS

Songhua Xiao; Xuesong Zhang, MD; Prof. Yan Wang; Zheng Wang; Keya Mao

A retrospective radiographic analysis comparing the correction capacity of monoaxial to uniaxial extended tab screws in AIS patients. Both monoaxial and uniaxial pedicle screws provided excellent coronal deformity correction. Uniaxial extended tab screws have certain technical advantages over monoaxial screw in that it allows for combined derotation and translation with reduction manoeuvre thereby allowing for improved sagittal correction and simplified rod reduction.

A Novel Non-Threaded Locking Mechanism for Pedicle Screws in Adult and Pediatric Spinal Deformities: Clinical and Radiographic Outcomes.

Lotfi Miladi, MD; Arnaud Soubeiran, PhD; Prof. Jean Dubousset;
Pedicle screw instrumentation has emerged as the primary mode of fixation for deformity correction in adult and pediatric scoliosis. Threaded locking mechanisms for screw-to-rod coupling are limited by the potential for cross-threading and breakage, the significant rod reduction required to engage the threads, and screw head prominence to accommodate threads.

Local Effect of a Fusionless Device that Modulates Growth to Control Vertebral Wedging

Prof. Carlos Barrios; Oscar G. Riquelme-García, MD, PhD; Jesus Burgos; Eduardo Hevia; José L. González-López; Carlos Correa;
A new fusionless vertebral epiphyseal device was designed with the objective of modulating vertebral growth by compressing the epiphyseal ring without spanning the disc. The device achieved local growth control of the vertebral bodies (vertebral wedging up to 13° and Cobb angle up to 35°) with the advantage of maintaining spinal mobility and disc dynamics while achieving consistent and effective osseointegration. This device may provide a minimally invasive fusionless technique option to correct scoliotic deformities in growing children and adolescents.

The Aperius Perclid System, a New Percutaneous Stand-Alone Lumbar Interspinous Decompression System.

Masato Tanaka, MD; Kazuo Nakanishi; Haruo Misawa; Prof. Toshifumi Ozaki

The Aperius Perclid system is a new percutaneous stand-alone interspinous system. We treated 6 patients for Modic 3 or 4 lumbar discopathy. Mean age 58 years.; mean follow-up w 11 months. Results: Operating time was very short, 15-20 minutes average. Neither o major complications nor lumbar moving limitation was observed. Compared with other interspinous decompression devices Aperius Perclid appears to be worthier because of percutaneous access.

Percutaneous Lumbar Spine Pedicle Screw Fixation in Degenerative Disease

Angel Macagno, MD; Esteban Cuartas; Michael O'Brien, MD; Harry L. Shufflebarger, MD

Percutaneous spinal stabilization demonstrated a similar stiffness when compared with open pedicle screw fixation. 11 patients suffering for degenerative lumbar disease were treated with percutaneous fixation. Blood loss was dramatically lower and recovery time was faster. Minimizing the operative trauma percutaneous lumbar spine stabilization allows patients to restore daily activity faster. Unfortunately because of the technical limits of the percutaneous implants nowadays disposable, only a few level -3 or 4 segments maximum- can be fused up to now.

Rapid Prototyping Technology (RPT) for Spinal Deformity: A Case Report

Guray Yilmaz; Prof. Muharrem Yazici, MD; Gokhan H. Demirkiran; Gazi Huri; Kenan Daglioglu; Cenk Ozkan;

Rapid prototyping (RP) is the application of engineering principle wherein a real physical 3D model is generated using computer software generated display images based on CT/MRI scans. They serve as important learning tools for understanding anatomy and rehearsing complex surgeries which have steep learning curve. Our experience of this technology in surgical management of congenital scoliosis is being described.

VEPTR Spine to Spine Constructs (Growing Rods) for Infantile and Juvenile Neuromuscular Scoliosis. Early Results.

Richard A. Klein, MD; P. Justin Tortolani, MD; John Seftor, DO; Nianbin Hu, MD; Jun Kikkawa, MD; Paul C. McAfee, MD; Prof. Bryan W. Cunningham, MSc

We performed 14 VEPTR spine to spine (growing rod) constructs for infantile and juvenile neuromuscular scoliosis. In 8 cases there was prior failure of either a conventional VEPTR construct or of another growing construct.

A Comparison of 3 Spondylolysis Repair Techniques

Cristina Sacramento-Domínguez, MD, PhD; Raquel Vayas-Díez; Luis Coll-Mesa;

Osteotomy of the pars interarticularis significantly increased rotational displacement. The degree of rotation was least among native spines, followed by instrumented spines, and most among spines with bilateral pars defects. Trends show a rotational stabilizing effect in all three repair methods. However, only the pedicle-screw-hook-rod and arch plate significantly decreased rotational range of motion compared to pars defect conditions. Eventual implementation with spondylolytic patients may provide increased lumbar spine stability with decreased complication risks.

Usefulness of a Navigation System in Surgery for Scoliosis

Manish S. Kawade, MBBS; Prof. Sudhir K. Srivastava, MBBS MS(ORTH); Kshitij M. Agrawal, MBBS;

There are many difficulties with the insertion of pedicle screws, especially in the case of scoliosis with rotated vertebrae and pedicles. We have used a CT-based navigation system for a segmental pedicle screw fixation method. Only 11 (4.2%) of the 264 inserted screws were classified as total deviation, with grade 2 or higher in the Neo classification system. There were no neurovascular complications in this series. We report the usefulness of a navigation system in surgery for scoliosis.

Preliminary Results of Safety and Efficacy of Minimally Invasive Correction of Spinal Deformity In Adolescent Idiopathic Scoliosis.

Randal R. Betz, MD; Amer F. Samdani, MD; John P. Gaughan; Stewart Bailey, MD FRCS can; Courtney Brown; JahanGir Asghar, MD; Patrick J. Cahill, MD; Linda P. D'Andrea, MD; Prof. Maurice Bourlion

A preliminary report on 5 cases with the diagnosis of AIS which were treated by minimally invasive corrective surgery using pedicle - screws and rods.

Minimally Invasive TLIF For Short Segment Degenerative Lumbar Conditions

Jim A. Youssef, MD; Jeffrey C. Wang, MD; Isador H. Lieberman, MD, MBA, FRCS; Darrel S. Brodke, MD; Carl Laurysen, MBChB; Stephen Haynesworth, PhD; Catherine A. Patty, MS; George F. Muschler, MD; Alan S. Hilibrand, MD

Effective fusion via TLIF follows an experience curve affecting estimated bloods and operative time. However, fluoroscopy uses does not appear to significantly change once experience has been established.

Open vs Percutaneous Stabilization of Thoracic and Lumbar Fractures in Ankylosing Spondylitis and DISH

Peter D. Masso, MD; George Gorton, III, BS; Prof. Joseph Hamill, PhD

This two center series demonstrated that spinal stabilization for pathologic fracture in AS and DISH by Open Techniques resulted in greater perioperative morbidity and mortality than Percutaneous (CIP and UP) Techniques. Unconstrained techniques reduced instrumentation and wound complications by lower rod profile and greater flexibility with segmental fixation placement and less implant prominence.

Thoracic Disc Herniation; Minimally Invasive Lateral Transthoracic Approach

Kshitij M. Agrawal, MBBS; Prof. Sudhir K. Srivastava, MBBS MS(ORTH); Manish S. Kawade, MBBS;

This case series details the minimally invasive lateral transthoracic approach in 8 consecutive patients who underwent minimally invasive transthoracic, transpleural decompression for thoracic disc herniation.

Percutaneous Instrumentation of Thoracic and Lumbar Injuries via a Novel Unconstrained-Steerable Rod: Preliminary Results

Patrick T. Knott, PhD, PA-C; Steven Mardjetko, MD, FAAP; Megan Dunn; Daniel Johnson; Stephen Cruze; Juliette Moore;
Percutaneous Instrumentation via Neutralization and Tension Band constructs in the treatment of Thoracic and Lumbar can be effected with limited exposure morbidity and limited complications.

Kyphosis

The Role of Hyperextension Fulcrum Graphies Taken Under General Anesthesia in the Evaluation of Flexibility of Kyphosis in Scheuermann Disease

Eric J. Wall, MD; David L. Glos, BS; Frank E. Sauser, MS; Vivek Sharma, MD; Alvin Crawford, MD; Donita I. Bylski-Austrow, PhD
Sixteen adolescents with Scheuermann disease undergoing surgery were studied. The mean preoperative kyphosis angle was 86.5 degrees. The flexibility of kyphosis was 35% with preoperative hyperextension fulcrum graphies and 58% with intraoperative hyperextension fulcrum graphies taken under general anesthesia (HFGUGA) ($p < 0.05$). The mean postoperative kyphosis angle was 30.7 (65% correction ratio). HFGUGA is the best radiological modality in decision making of surgical technique in Scheuermann kyphosis.

Primary Posterior Fixation and Stabilization Improves Regional Lordosis Following Lumbar Corpectomy

Jeffrey D. Coe, MD; Scott H. Kitchel, MD; Christopher P. Ames, MD; Prof. Finn B. Christensen, MD PhD; Prof. Tae-Ahn Jahng; Prof. Hans J. Meisel, MD, PhD; Mark Schnöring, MD; Charles H. Wingo, MD

The effect of the sequence of anterior vs. posterior fixation on kyphosis correction and lordosis after lumbar corpectomy and reconstruction remains unknown. In a retrospective analysis of 85 patients with destructive pathology of a lumbar vertebra causing loss of lordosis and/or kyphosis treated with corpectomy with or without initial posterior stabilization, we found that patients who underwent initial posterior stabilization demonstrated a more significant restoration of regional lordosis compared to patients who underwent corpectomy followed by posterior fixation.

Functional Outcomes of Traumatic Thoracolumbar Spine Fractures with Extreme Kyphosis

Ahmad Nassr, MD; Peter F. Sturm, MD; Steven Mardjetko, MD, FAAP

Based on evaluation of traumatic thoracolumbar vertebral body fractures at the T10 to L2 juncture, follow-up kyphotic fracture angle of any degree is not predictive of a worse functional outcome.

Transpedicular Wedge Resection Osteotomy for Correction of Kyphotic Deformity in Ankylosing Spondylitis

Daisaku Takeuchi; Hiroshi Taneichi, MD; Satoshi Inami, MD; Takashi Namikawa, MD, PhD; Nakayuki Katou; Prof. Yutaka Nohara, MD

To study the method and results of transpedicular lumbar wedge resection osteotomy for correction of kyphotic deformity in ankylosing spondylitis.

Complications of Pedicle Subtraction and Smith-Petersen Osteotomies: An Analysis of 151 Patients

Patrick T. Knott, PhD, PA-C; Fernando Techy; Steven Mardjetko, MD, FAAP; Megan Dunn; Tara Pullara; Janelle Kennedy; Tom McCall

In this study, we compared the complications in 151 pedicle subtraction (PSO) and Smith-Petersen osteotomy (SPO) procedures. When comparing PSO to SPO, there was a significantly higher complication rate in patients undergoing PSO: 14% vs. 37%. Specifically, there was a significantly higher neurologic complications in the patients undergoing SPO: 1% vs. 8%. This study adds to the paucity of studies and information related to pedicle subtraction and Smith-Petersen osteotomies emphasizing on the incidence of complications in each technique.

Lumbar Degenerative

Interspinous Device to Treated Lumbar Pathology

Johnny Eguizabal; Thuc-Quyen Nguyen; Prof. Jeffrey Lotz; Jennifer Buckley; Christopher P. Ames, MD

The number of patients suffering from progressive lumbar spinal stenosis with symptomatic neurogenic intermittent claudication is projected to increase. Unfortunately, these patients are limited to a choice between nonsurgical conservative care and more invasive decompressive surgical procedures such as laminectomy with or without fusion.

Can One-Year Outcomes Predict Two-Year Outcomes after Lumbar Fusion Surgery?

Prof. Serkan Erkan, Assistant Professor; Chunhui Wu, PhD; Amir A. Mehbod, MD; Brian Hsu, MB BS, FRACS; Ensor E. Transfeldt, MD

Individual clinical outcomes are different at one and two years after lumbar fusion. One year outcomes are only fairly predictive of clinical outcomes two years after surgery.

Navigation-Assisted Fluoroscopy in Minimally Invasive Direct Lateral Interbody Fusion: A Cadaveric Study

Ronald A. Lehman, Jr., MD; Anton E. Dmitriev, MSc; Norman Gill; Mario J. Cardoso, MD, DC

The direct lateral interbody fusion technique (DLIF) is a new MIS surgery procedure. This study assesses the use of computer-assisted navigation for the DLIF procedure compared to standard fluoroscopy, as well as the accuracy of this technique in a cadaveric model.

Are Pre-Operative HRQOL Scores Predictive of Clinical Outcomes after Lumbar Fusion?

Juan Carlos Rodriguez-Olaverri, MD; Nael Shanti, MD; Carl Paulino, MD; Andrew Merola, MD; Greg Khounghanian, MD; Jim Tuchi, MD; Claude Scott, MD

Patients with good pre-op MCS and poor ODI scores who are not on worker's compensation are more likely to improve after lumbar fusion. Non-modifiable pre-operative factors, operative and post-operative events may also affect clinical outcomes after lumbar fusion. Threshold values for MCS, PCS and ODI that are predictive of a patient achieving minimum clinically important difference for PCS and ODI could not be determined.

Lumbar Fusion Outcomes Stratified by Specific Diagnostic Indication

Donald J. Blaskiewicz, MD; Igor R. Yusupov, MD; Mohamed M. Abdulhamid, MD; Catherine Murtagh-Schaffer, RPA-C; Ross R. Moquin, MD

A primary difficulty in evaluating lumbar fusion is that, outside of spondylolisthesis, specific diagnostic indications for surgery are poorly defined. This study reports on prospectively collected HRQOL measures, stratified by diagnosis, in 327 patients with DDD whose treatment included lumbar fusion. Greatest ODI and SF-36 PCS improvements were in patients with Spondylolisthesis, Scoliosis, and Disc Pathology, and least in patients with Nonunion. This study demonstrates that added diagnostic specificity is critical to building an improved evidence-base for lumbar fusion.

Outcome of Lumbar Fusion in Patients Over 65 Years Old

Ensor E. Transfeldt, MD; Amir A. Mehdod, MD; Stanley Skinner, MD; Brian Hsu, MB BS, FRACS; Chunhui Wu, PhD; Prof. Serkan Erkan, Assistant Professor; David Rippe, MD

Clinical outcomes for lumbar fusion in older versus younger patients from the control arm (ICBG) of an FDA regulated, IDE trial of rhBMP-2 matrix for single-level posterolateral lumbar spine fusion were compared. Improvement in ODI, SF-36, Numeric Rating Scales for Back and Leg Pain, and fusion rates in patients older than 65 years were similar to those in patients younger than 65 years. Medicare age patients undergoing single level lumbar decompression and instrumented fusion have similar or better results compared to younger patients.

Displacement of Interbody Spacers in TLIF Surgeries

Roger P. Jackson; Anne C. McManus, RN

A larger than expected number of spacer displacement (16.6%) was found in 102 consecutive cases of TLIF surgery. The highest displacement (23.9%) occurred with unilateral fixation.

Radiographic Evaluation of Segmental Instability in Degenerative Lumbar Scoliosis (DLS)

Kota Watanabe, MD; Lawrence G. Lenke, MD; Morio Matsumoto, MD; Prof. Yoshiaki Toyama; Kazuhiro Chiba, MD, PhD

We evaluated segmental instability in DLS with radiographic parameters compared with lumbar spinal canal stenosis (LCS). The present study indicated that a vertebral body in DLS moved with an inclined axis because of the asymmetric degeneration of a disc, and greater wedging caused subluxation of the facet joint and led to lateral slip. Therefore, we speculated that segmental instability in DLS occurs because of asymmetric disc degeneration and leads to subluxation of the facet joint or lateral slip.

Change in Neuroforaminal Dimensions after Lumbar Interbody Fusion

Melvin D. Helgeson, MD; Ronald A. Lehman, Jr., MD; F. Marshall Moore, MD; Romney C. Andersen, MD; Patrick B. Cooper, MD; Michael Frisch

Lumbar interbody fusion (LIF) is a commonly employed technique for the treatment of numerous degenerative conditions of the lumbar spine. Prior biomechanical and cadaveric studies suggest that interbody fusion techniques can increase the size of the neuroforamen (NF), but few clinical studies exist. We examine the effects of anterior lumbar interbody fusion (ALIF) and posterior transforaminal lumbar interbody fusion (TLIF) on NF size.

Spondylolisthesis in Patients with Neurogenic Claudication Effects Functional Performance and Self Reported Quality of Life.

Dinah Baria; Esteban Cuartas; Ted Milne; Prof. Loren Latta, PhD; Harry L. Shufflebarger, MD

Symptomatic lumbar spinal stenosis limits a patient's health and function. We conducted a study to determine if spondylolisthesis was more disabling than other forms of spinal stenosis. Validated outcome measures were used to evaluate patients, as well as a walking test. We found that the outcome measures accurately reflect a patient's level of disability, while the presence of spondylolisthesis was no more disabling than other causes of spinal stenosis.

Epidemiology and Risk Factors Associated with Lumbosacral Juvenile Degenerative Disc Disease (JDDD)

Christopher I. Shaffrey, MD; Toomas Anton, MD; Kasandra Dassoulas, B.S.; Jay Jagannathan, MD

As part of the largest population genetic-based study in Southern Chinese (N=1,989), subjects aged 13 to 21 years were grouped into JDDD and non-JDDD cases to assess the epidemiology and risk factors associated with JDDD of the lumbosacral spine. T2-weighted MRI findings, subject demographics, and clinical profiles were assessed. In non-spinal deformity cases, individuals with lumbosacral JDDD were noted to be more symptomatic, have higher BMIs, and a significant history of previous lumbar injury in comparison to non-JDDD subjects.

“Skipped” Level Disc Degeneration of the Lumbar Spine: Prevalence and Associated Risk Factors

Joshua S. Rovner, MD; James D. Schwender, MD; Brian Hsu, MB BS, FRACS;

This study addressed the prevalence and associated clinical and radiological features of non-consecutive (“skipped”) levels of lumbar degenerative disc disease (SLDDD) as part of a large population-based analyses of Southern Chinese (N=1,989). Subjects exhibiting DDD of more than two levels were grouped into SLDDD and non-SLDDD. To our knowledge, this was the first study to describe SLDDD. While its etiology remains unknown, altered spinal biomechanics associated with SLDDD might account for less pronounced clinical symptoms. The understanding of SLDDD may shed light on the cause of back pain.

Extreme Lateral Lumbar Interbody Fusion (XLIF) for Lumbar Junctional Stenosis

Jean-Marc Mac-Thiong, MD, PhD; Ensor E. Transfeldt, MD; Amir A. Mehdod, MD; Joseph H. Perra, MD; Francis Denis, MD; Timothy Garvey, MD; John E. Lonstein, MD; Robert B. Winter, MD

The minimally invasive, retroperitoneal trans-psoas extreme lateral interbody fusion (XLIF, Nuvasive, Inc.) is a very effective surgical approach for junctional stenosis. We demonstrated retrospectively the effectiveness of the XLIF procedure for junctional degeneration and stenosis with short operating time, less blood loss, quick recovery, and short hospital stay.

A Prospective Randomized Study on the Long-Term Effect of Lumbar Fusion on Adjacent Disc Degeneration.

Melvin D. Helgeson, MD; John Tis, MD; Anton E. Dmitriev, MSc; Ronald A. Lehman, Jr., MD

The RCT compared pre- and post-treatment radiographs with a minimum of 10 years FU (range 10-17 years) obtained from 80 patients treated with lumbar fusion (63) or physiotherapy (17). Three radiographic methods of adjacent segment degeneration (ASD) quantification were used showing accelerated degeneration after fusion compared to natural history. Outcome was only affected in the unfrequent severe forms of ASD.

Health Related Outcomes in Revision Lumbar Fusion Surgery

Renuka Reddy Kuruvalli, MS, MRCS; Andrew S. Wajick, FRCS

We examined the results of lumbar fusion in patients who had undergone prior lumbar surgery. Patients with post-decompression disc degeneration demonstrated modest results while those with adjacent level stenosis and nonunion were poor. Determining pre-operatively which patients are likely to improve is challenging and unpredictable.

Successful Use of an Interspinous Implant to Reduce Adjacent Segment Degeneration Above Short Instrumented Lumbar Fusion

Kelly Vanderhave, MD; Michelle S. Caird, MD; Frances A. Farley, MD; Robert N. Hensinger, MD; Greg Poulter; Gregory P. Graziano, MD

In this prospective randomized controlled study the Wallis interspinous implant was used cephalad to 2-4 level lumbar instrumented fusion to test the hypothesis of reduction of adjacent segment degeneration (ASD). This investigation showed that Wallis changed the natural history and prevented the adjacent unfused vertebra from fusion, while it lowered the radiographic ASD incidence until to 5 years postoperatively.

Dose-Dependent Inhibition of Diclofenac Sodium on Posterior Lumbar Interbody Fusion Rates in Adult Patients

Melvin D. Helgeson, MD; Anton E. Dmitriev, MSc; Frederick L. Stephens, II, MD; Patrick B. Cooper, MD; Michael Rosner, MD; Ronald A. Lehman, Jr., MD

Dose-dependent inhibitory effect of diclofenac sodium on fusion rates in 273 adult patients who underwent 1-2 level instrumented PLIF using local autogenous bone graft only was investigated. No significant correlation was seen between age, sex, L5-S1 vs. other levels fused and smoking history when compared to spine non-union. 2-level lumbar fusions showed a significant negative correlation to spine fusion compared to 1-level fusions. Diclofenac sodium showed a dose-dependent inhibitory effect towards spine fusion especially when used during the immediate post-operative period.

Comparison of Cosmetic and Functional Outcomes after Anterior Paramedian versus Anterolateral Retroperitoneal Approaches in Lumbar Spinal Stenosis Surgery

Qingan Zhu, PhD; Eyal Itshayek, MD; Claire F. Jones, MSc; Timothy D. Schwab, MASC; Chadwick R. Larson; Lawrence G. Lenke, MD; Peter A. Cripton, PhD

Anterior interbody fusion with anterior paramedian approach was done in 27 and anterolateral retroperitoneal approach was done in 14 patients with the diagnosis of lumbar spinal stenosis combined with posterior surgery. Patients undergoing anterior paramedian approach to lumbar spine have higher quality of life and cosmetic outcomes compared with patients having anterolateral retroperitoneal approach.

Predicting SF-6D Scores from the Oswestry Disability Index and Numeric Rating Scales for Back and Leg Pain

Juan Carlos Rodriguez-Olaverri, MD; Nael Shanti, MD; Carl Paulino, MD; Andrew Merola, MD; Greg Khounganian, MD; Jim Tuchi, MD; Claude Scott, MD

In 2640 patients who had lumbar fusion for degenerative disorders, strong, consistent and predictable correlations were seen between paired observations of ODI and the SF-6D. Using regression modeling, a validated method of estimating the SF-6D from the ODI was determined. This is useful for economic evaluations of treatments in trials where ODI is available but utility scores were not collected.

A Randomised Control Trail of Decompression of Lumbar Spine versus Decompression and Wallis Ligament

Lawrence G. Lenke, MD; Timothy Kuklo, MD, JD; Daniel J. Sucato, MD MS; B. Stephens Richards, MD; John B. Emans, MD; Keith H. Bridwell, MD; Charles E. Johnston, II, MD; Brenda A. Sides, MA

The purpose of this prospective randomized, ethically approved, trial is to demonstrate efficacy of Wallis implant in improving low back pain and functional alone disability compared with decompression of spine alone

Abnormalities of the Lumbar Spine in the Coronal Plane on Plain Abdominal Radiographs.

Alvin Crawford, MD; Mohd AlfawReh, MD; Baron S. Lonner, MD; Randal R. Betz, MD; Linda P. D'Andrea, MD; James T. Guille, MD; Amer F. Samdani, MD

The incidence of degenerative scoliosis in the lumbar spine is not known. 2276 radiographs were analysed for the incidence of degenerative lumbar scoliosis and lateral vertebral slips in patients who are 20 years old. Degenerative lumbar scoliosis starts to appear in the third decade of life and increases in frequency every decade thereafter, affecting almost a third of patients in the ninth decade. It is more common in female patients and has a greater magnitude.

Long Term Follow-Up Experience with Lumbar Pfirmann Grade V Discopathy Treated with the I-Fly Cage

Alvin Crawford, MD; Shannon B. Anteker, MD; Lori Aronson, MD; Michael O'Brien, MD; Harry L. Shufflebarger, MD; Suken A. Shah, MD;

A new lumbar interbody cage has been developed in order to make it possible to achieve a solid bone fusion by a stand alone posterior device.

Fusion Rate after Multi-Segmental Lumbar Fusion Including the Sacrum

Donald A. Deinlein, MD

The overall fusion rate was 85%, and it decreased as the number of fusion levels increased. Non-union was seen mainly at L5/S and the most cranial levels. The fusion rate at L5/S was increased as the number of screws or rods penetrating the anterior cortex. However, as the fusion rate at L5/S increased, it decreased at the most cranial levels.

Clinical Outcomes of a Multilevel Posterior Lumbar Interbody Fusion using Local Autogenous Bone Graft for Adult Spinal Deformity and Lumbar Stenosis

Kota Watanabe, MD; Lawrence G. Lenke, MD; Katsumi Harimaya; Yongjung J. Kim, MD; Marsha Hensley

Radiographic and clinical outcomes of 3-5 level posterior lumbar interbody fusion (PLIF) using local autogenous bone graft only in 49 adult spinal deformity patients were investigated. Lumbar lordosis in fused segments was maintained, and clinical symptoms were improved ($p < 0.0001$) at the ultimate follow-up. There were 7 pseudarthroses (14%) causing poor clinical outcomes, and 23 adjacent segment diseases (53%). While a multilevel PLIF can be a viable treatment option for complex spinal deformity or foraminal stenosis, pseudarthrosis and adjacent disease in the lower lumbar spine cause severe clinical symptoms, and lead to more revision surgery.

Correlation of Pelvic Incidence with Lumbar Degenerative Kyphosis

John R. Dimar, MD; Justin Esterberg, MD; Venu Vemuri, DO; Jennifer M. Howard, BA; Leah Y. Carreon, MD, MSc

Pelvic incidence (PI) was significantly higher in patients with lumbar degenerative kyphosis (LDK) as compared with controls and had significant difference in its subtype.

5-Year Results of the Prospective, Randomized, Multicenter, FDA Investigational Device Exemption (IDE) ProDisc®-L TDR Clinical Trial

Melvin D. Helgeson, MD; Ronald A. Lehman, Jr., MD; F. Marshall Moore, MD; Romney C. Andersen, MD; Michael Frisch

These are the 5-year results of the FDA ProDisc®-L clinical trial.

Results of the Prospective, Randomized, Multicenter, FDA Investigational Device Exemption (IDE) Study of the ProDisc®-L Total Disc Replacement versus Circumferential Fusion for the Treatment of 2-Level Degenerative Disc Disease

Joshua M. Pahys, MD; Amer F. Samdani, MD; Linda P. D'Andrea, MD; David H. Clements, III, MD; Randal R. Betz, MD

These are the results of the FDA ProDisc®-L 2-level clinical trial.

Radiological Evaluation of Lateral Movement of Lumbar Spine in Degenerative Lumbar Disease

P. Justin Tortolani, MD; Paul C. McAfee, MD; Prof. Bryan W. Cunningham, MSc; Michael Donahue, DO

The purpose of this study is to evaluate the movement of the lumbar spine in lateral bending X-ray in degenerative lumbar disease cases. We evaluated 50 consecutive patients with degenerative lumbar disease, but they have no limitation of the motion in lumbar spine. All patients were evaluated by X-ray of A-P view in standing position with lateral bending motion. There was no significant difference between the range of whole spine motion in right side bending and left side bending. There was no lateral movement in L5/S1 level. We observed the large range of motion in upper lumbar spine. Three patients who showed lateral slip were degenerative lumbar scoliosis. There was no lateral movement in the level of degenerative spondylolisthesis.

The Reliability of CT and MRI Grading of Lumbar Facet Arthropathy in TDR Patients

Michael G. Vitale, MD MPH; Jaime A. Gomez, MD; Hiroko Matsumoto, MA; Randal R. Betz, MD; Robert M. Campbell, Jr., MD; John B. Emans, MD; John Flynn, MD; Norman Ramirez; Brian D. Snyder, M-PhD; Peter F. Sturm, MD; Kit Song; John Flynn, MD; John T. Smith, MD; Jeffrey Shilt, MD; David P. Roye, Jr., MD

Interest has arisen in the evaluation of the lumbar facet joints and their degree of arthropathy. Magnetic Resonance Imaging (MRI) and Computed Tomography (CT) are commonly utilized to evaluate facet arthropathy. This study compares the interrater and intrarater reliability of MRI and CT for grading of facet arthropathy as well as determining if there is a contraindication to Total Disc Replacement (TDR).

Osteoprogenitor-Enriched Allograft in Lumbar Spinal Fusion: Preliminary Findings From a Two-Year Prospective Multi-site Study

Dinah Baria; Esteban Cuartas; Prof. Loren Latta, PhD; Ted Milne; Harry L. Shufflebarger, MD

A prospective, multi-center, IRB-approved study evaluating clinical and radiographic outcomes of autologous osteoprogenitor-enriched allograft for instrumented posterolateral lumbar fusion. Fifty-one subjects undergoing lumbar fusion at one to 3 levels. Forty-four subjects completed final follow-up at an average of 21 months. Seven subjects were lost to final follow-up. Outcome Measures used included SF-36, Visual Analog Scale, Oswestry Disability Index and plain radiograph assessment at baseline and final follow-up.

Segmental Fusion in the Treatment of Degenerative Low Back Pain

Mark Driscoll, B.Eng.; Eliane Schmid, M.A.Sc.; Prof. Carl-Éric Aubin, PhD, P.Eng.; Alain Moreau, PhD; John F. Sarwark, MD; Stefan Parent, MD, PhD;

A prospective study of 47 patients underwent segmental fusion of the lumbosacral spine for back pain due to degenerative disc disease, with average follow up 24 months. ALIF in 18 patients, PLIF in 19, Posterolateral fusion in 10. Results showed significant difference between preoperative and final follow up scores of VAS, ODI, SF-36 with $P < 0.001$. Analysis of variance of change in scores for three different types of fusion did not show significant difference. Our results support segmental fusion for degenerative low back pain.

Restoration of Lumbar Lordosis: A Comparative Study of Anterior Lumbar Interbody, Transforaminal Interbody and Posterolateral Fusion Techniques

Lawrence G. Lenke, MD; B. Stephens Richards, MD; Timothy Kuklo, MD, JD; Daniel J. Sucato, MD MS; John B. Emans, MD; Charles E. Johnston, II, MD; Keith H. Bridwell, MD; Brenda A. Sides, MA; Spinal Deformity Study Group Medtronic

This study compared radiographic sagittal plane parameters from pre-operative, immediate post-operative and latest follow-up lateral radiographs in patients who underwent single-level ALIF, TLIF or PSF for degenerative disc disease. No difference was seen in the amount of lumbar lordosis correction achieved with ALIF, TLIF or PSF. A greater increase in anterior disc height was seen post-operatively in patients who had ALIF, but this increase was not maintained on follow-up.

Minimally Invasive Lumbar Posterolateral Fusion with Transcutaneous Pedicle Screws for Degenerative Spondylolisthesis. With Emphasis on Perioperative Invasiveness and Quality of Life

Wael Koptan, MD; Yasser ElMiligui, MD, FRCS; Prof. Hazem B. Elsebaie, FRCS, MD;

Although there have been several reports regarding minimally invasive lumbar interbody fusion, the minimally invasive posterolateral fusion has not been reported. The surgical technique we utilize obviates the need for interbody fusion even in minimally invasive approach. The dramatical decrease of perioperative invasiveness and successful bony fusion were demonstrated in this study.

Single-Stage Anterior Lumbar Decompression and Artificial Disc Replacement in 15 Patients with Concomitant Chronic Discogenic Lower Back Pain and Radicular Leg Pain.

Michael G. Vitale, MD MPH; Hiroko Matsumoto, MA; Daniel E. Prince, MD; Jaime A. Gomez, MD; Ariadne A. Avellino, BA; David P. Roye, Jr., MD; Spinal Deformity Study Group

To evaluate outcome in patients with longstanding DDD and acute lumbar disc herniation, receiving lumbar decompression and artificial disc replacement via a single retroperitoneal anterior surgical approach.

Adjacent Segment Degeneration Following Transforaminal Lumbar Interbody Fusion

Peter O. Newton, MD; Michelle C. Marks, PT, MA; Randal R. Betz, MD; David H. Clements, III, MD; Baron S. Lonner, MD; Alvin Crawford, MD; Harry L. Shufflebarger, MD; Michael O'Brien, MD; Tracey P. Bastrom, MA

A prospective clinical and radiological study of adjacent segment degeneration (ASD) in 112 patients who underwent transforaminal lumbar interbody fusion (TLIF) was conducted. A relatively high rate of ASD (30%) was found at mean follow-up of 33 months. Although the majority of cases were radiographic ASD, there was a subset of patients with clinical ASD that could not be picked up on routine radiographs. Those with radiographic ASD had significantly poorer North American Spine Society (NASS) back pain disability score.

Outcome of Revision Discectomies Following Recurrent Lumbar Disc Herniation. Comparison Between Conventional Discectomy and Microendoscopic Discectomy as a Primary Surgery.

Lawrence G. Lenke, MD; Timothy Kuklo, MD, JD; Daniel J. Sucato, MD MS; B. Stephens Richards, MD; John B. Emans, MD; Keith H. Bridwell, MD; Spinal Deformity Study Group Medtronic

Twenty-two revision surgeries were performed after conventional discectomy (C-group) and 8 after microendoscopic discectomy (M-group). Their mean Japanese Orthopaedic Association score increased from 7 to 21 points with the recovery rate of 67% in C-group, and from 9 to 25 with the rate of 79% in M-group. Seventeen in C-group and 6 in M-group returned to their previous work status, 5 in C-group and 2 in M-group did not return to work. The improvement rate between two groups was not significant.

Comparison of Total Disk Replacement with Lumbar Fusion Surgery

Stephan L. Pro, MD; Jean H. Mullins, BA; Kenneth R. Gundle, BA; Lynn M. Marshall, ScD; Robert A. Hart, MD

The objective of this prospective randomised controlled trial was to compare the clinical outcome of lumbar total disc replacement (TDR) with fusion for the treatment of discogenic pain at one or two levels in the lumbar spine. Follow up rate was 100%. At one year TDR was found to be superior to spinal fusion in terms of clinical outcome. After two years there was still a difference regarding global assessment.

Antiadhesion Barrier Gel Improves Clinical Outcome in Lumbar Discectomy Patients: A Prospective Randomised Trial of Oxiplex Barrier Gel 24 Month Follow Up Results

Takuya Mishiro, PhD, MD; Lawrence G. Lenke, MD; Linda Koester; Prof. Matthew B. Dobbs, MD; Scott J. Luhmann, MD; Keith H. Bridwell, MD;

This is a study about patients undergoing lumbar decompression discectomy to evaluate the effectiveness of Oxiplex/Medishield in improving patient clinical outcome. It was found that it is effective.

Miscellaneous

Surgical Correction of Spinal Deformities after Heart Transplantation: A Case Series Report

Kate Deisseroth, MD; Shannon L. Hiratzka, MPH; Jean H. Mullins, BA; Robert A. Hart, MD

Heart transplantation has been reported to be a major risk factor for the development of spinal deformity. This study is a case series of six patients that underwent scoliosis correction surgery after a heart transplant. It attempts to demonstrate that spine deformity surgery can be successfully performed in children and adolescents who have undergone a heart transplant.

Surgical Treatment (Coccygectomy) for Coccydynia (Outcomes Analysis)

Daniel S. Mulconrey, MD; Lukas P. Zebala, MD; Lawrence G. Lenke, MD; Keith H. Bridwell, MD

Twelve patients with coccydynia underwent surgical treatment (Coccygectomy). Mean age was 34/5 years (Range from 17 to 53). Eight Patients (66/6%) were female and four patients (33/4%) male. Mean post operative Follow-up of the patients was 28 months (Range from 16 to 63 months). Nine (75%) patients had excellent results and three (25%) good results. The PROLO scale improved from 10 to 18 (p < 0/001) after coccygectomy.

The Use of Abbreviations in Spinal Surgery.

Lawrence G. Lenke, MD; Timothy Kuklo, MD, JD; Daniel J. Sucato, MD MS; Mark A. Erickson, MD; John B. Emans, MD; B. Stephens Richards, MD; Charles E. Johnston, II, MD; Keith H. Bridwell, MD; Spinal Deformity Study Group Medtronic

Abbreviations are commonly used in presentations and publications. This study comparing the use of abbreviations in general orthopaedic and spinal literature has found that abbreviations are poorly defined and overused. This is a particular problem in the spinal literature reviewed.

Surgical Treatment of Dystrophic Type of Spinal Deformity in Neurofibromatosis: The Effect of Augmentation with an Anterior Strut Bone Graft from the Concave Side

Lesa M. Nelson, BS; James W. Ogilvie, MD; Kenneth Ward, MD
Thirty-two patients with dystrophic change (DC) of the spinal deformity who were treated surgically, were reviewed to evaluate postoperative progression of DC and the effectiveness of augmentation. Augmentation with an anterior strut bone graft from the concave side (ASBG) of the spinal deformity was demonstrated to be stable and to play an important role for supporting the spinal column although it could not completely prevent the progression of DC.

Apical Vertebrae in Scoliosis – Orientation of Pedicles and Body in Relation to Laminae

Danielle Geula, BS, BA; Vedat Deviren, MD; Sibel Demir-Deviren, MD; Sigurd Berven, MD

The concept of describing the pedicle and vertebral body orientation in relation to lamina gives valuable information for pedicle screw insertion in scoliosis.

Instrumentation Patterns in Operative Treatment for Pediatric Scoliosis

Jonathan N. Sembrano, MD; David W. Polly, Jr., MD

Three instrumentation groups were studied including a pure hook/rod construct a hybrid group (hooks, wires, cables, screws, rods) and a group of pure screw/rod construct. There were no significant differences in demographics. Frontal correction was better in the pure screw/rod constructs. Coronal balance tended to improve with time. Pure screw/rod constructs created a flatter thoracic kyphosis. Pure hook/rod constructs were more kyphotic. The pure screw/rod construct group had more lumbar lordosis. There were no differences levels instrumented, neurological complications, or differences in surgery time. Hook constructs had the most implants per construct.

Postoperative Bracing after Spine Surgery – A Questionnaire Study

Jonathan N. Sembrano, MD; Edward Rainier G. Santos, MD; H. Dennis Mollman, MD PhD; David W. Polly, Jr., MD

The objective of this study was to report the bracing frequencies and preferences of spine surgeons after specific spinal procedures based on their responses to a standardized questionnaire. The results indicate that although a majority of the respondents brace post-operatively, there is a lack of consensus regarding the appropriate indications for bracing. The complexity of a surgical case as well as lack of instrumentation appears to sway the surgeon to employ some form of orthosis.

How Often is Low Back Pain Not Coming From the Back?

Brian Hsu, MB BS, FRACS; Amir A. Mehbod, MD; Ensor E. Transfeldt, MD; Francis Denis, MD; Joseph H. Perra, MD; Timothy Garvey, MD; Manuel R. Pinto, MD; James D. Schwender, MD; Daryll C. Dykes, MD, PhD; John E. Lonstein, MD; Robert B. Winter, MD

368 patients were seen at a spine surgery clinic, and 200 of them had low back pain with no previous surgery. After obtaining a thorough history, physical examination, and appropriate diagnostic workup, 25% of patients were found to have non-spinal causes of pain, with or without a spinal pain source. 10% still had an undefined pain source even after workup.

Gray-Scale Assessment of Bone Induction Following Direct Lateral Interbody Fusion with rh-BMP 2 and Self-Distracting PEEK Cage

Arjun Srinath; Vishwas Talwalkar, MD; Janet Walker, MD; Reid Wilson, MD; Henry Iwinski, Jr., MD; Todd Milbrandt, MD, MS
Hounsfield measurement of 4 and 10 CT scans assess gray scale in and around interbody cages. Statistical analysis finds significant increase that vary with time.

Sacral Tilt: An Etiological Factor in Idiopathic Scoliosis?

Adnan Zubovic; Neville Davies; Fiona Berryman; Nasir A. Quraishi, FRCS; Prof. Christopher Lavy; Gavin Bowden; James Wilson-MacDonald, MB CHB FRCS MCH; Prof. Jeremy Fairbank
This preliminary study revealed significant association between sacral tilt and hemipelvis hypoplasia independent from age. Being independent from age in the current study suggested that it may have a primary role in the etiology.

Motion Preservation

Are Elastic Interspinous Devices Able to Modify the Outcome of Decompression for Lumbar Spinal Stenosis?

A. Atiq Durrani, MD; Rasesh R. Desai, MD; M. Arif Khan, MD; Albert Chavanne

In a prospective case-control study with minimum 2 years follow-up, the results of lumbar laminotomy for single level degenerative lumbar spinal stenosis (LSS) were compared to those of lumbar laminotomy plus implantation of an elastic interspinous device. No significant differences in outcome measures (VAS and ODI scores) were observed. Complications were evenly distributed between groups.

A Porcine Model for Progressive Scoliotic Deformity

Yoshihisa Kotani, MD; Prof. Kuniyoshi Abumi; Manabu Ito, MD, PhD; Masahiko Takahata, MD; Hideki Sudo; Norihiro Hojo; Prof. Akio Minami

Optimal development of non-fusion techniques for treatment of adolescent idiopathic scoliosis requires a reliable large animal model that consistently achieves a progressive three dimensional (frontal, sagittal, axial) deformity. This study establishes a porcine model for progressive scoliotic deformity with significant remaining skeletal growth for testing of growth-modulating therapies for correction.

Computed Tomography Three Dimensional Analysis of the Porcine Scoliosis Model

John N. Ruiz, MD; Hayley Hernstadt; Wei Ting Lee; Ying Mei Wong; Lim Ling; Gabriel Liu, MB Bch MSc FRCSEd(orth); Prof. Hwan Tak Hee, MD; Prof. Hee-Kit Wong

Development of non-fusion techniques requires an animal model with all the attributes of a scoliotic curve including: frontal and sagittal deformity, axial rotation, and true vertebral dysplasia within the curve. This study measures the true vertebral dysplasia induced in the Porcine Scoliosis Model using computed tomography scans. This is the first study to report accurate morphologic changes induced by growth modulation in creating scoliosis, and are certain to enhance our understanding of the complex spinal dysplasia. This will form a basis for detailed study of non-fusion treatments and their three dimensional impact.

Influence of the Lumbar Disc Replacement on the Height of the Intervertebral Space and on Facet Joint Articulation.

Choll W. Kim, MD PhD; Gilad J. Regev, M.D; Akihito Tomiya, MD PhD; Samuel R. Ward, PT, PhD; Prof. Richard L. Lieber, PhD

Thirty lumbar segments were instrumented on ten cadavers. Lumbar disc replacement showed on cadavers not only a significant increase of the lumbar disc height, but also a significant increase of the height of the corresponding facet joint and a reduction of the facet joint overlap.

Serum Metal Levels in Patients with Cobalt-Alloy Metal-on-Metal Lumbar Disc Replacements

Prof. Zhongli Gao; Prof. Xiaoyu Yang, Prof; Prof. Qingsan Zhu, Prof; Rui Gu, doctor; Zhaoyang Yin; Shanyong Zhang

Metal ion levels 12 months after TDR with Maverick Disc.

Results of Non-Fusion Method in Thoracolumbar and Lumbar Fractures

Gilad J. Regev, M.D; Lina Chen, M.D; Samuel R. Ward, PT, PhD; Mallika Dhawan; Choll W. Kim, MD PhD

Twelve patients with thoraco-lumbar and lumbar spine fractures were managed by non-fusion method. Implants were removed at mean 9.2 months. At final follow-up, the mean segmental motion was measured 10.5° in sagittal plane, 10.9° in coronal plane. Most patients were satisfied for final gross appearance and functional outcomes. The author's non-fusion method seemed to be effective in achieving stability and sagittal alignment as well as regaining segmental motion of fixed segments especially for young active persons.

Dynesys as a Dynamic Stabilization Device: Does it Preserve Lumbar Motion?

Prof. Viviana F. Paliotta, MD

Dynesys has been used off label as a motion preservation device. We measured lumbar motion in 44 patients status post Dynesys implantation with minimum of 2 years follow-up. We determined that less motion occurs than that seen in a normal spine, but more motion occurs than that seen with fusion.

Biomechanical Evaluation of a Transforaminal Lumbar Disc Arthroplasty Device. Does Implant Position Effect Operative Level Kinematics and Center of Intervertebral Rotation? An In-Vitro Human Cadaveric Model.

Prof. Se-Il Suk, MD, PhD; Prof. Jin-Hyok Kim, MD, PhD; Sung-Soo Kim, MD; Kook Jin Chung; Nak-Yong Jung, MD; Dong-Ju Lim, MD

The current study provides a biomechanical basis for total disc arthroplasty performed using a transforaminal approach for surgical reconstruction of the degenerative lumbar disc.

Functional Dynamic Stabilization in Lumbar Spinal Stenosis with COFLEX® Interspineous Implant – 2-Year Results.

Prof. Viviana F. Paliotta, MD

Interspineous implant with promising clinical results in treatment of lumbar spinal stenosis with simple minimally invasive surgery

Lumbar Pedicle Based Dynamic Stabilization System (DSS®) – Preliminary Results

Aziz Daye, MD; Lynn Letko, MD; Rubens Jensen, MD; Harms Study Group

Posterior dynamic stabilization with new biomechanical properties that is easy to apply

Effect of Total Lumbar Disc Replacement on Segmental and Lumbar Sagittal Balance and Movement

Prof. Xiaoyu Yang, Prof; Prof. Qingsan Zhu, Prof; Prof. Hu Zang, Prof; Prof. Yuanhai Jing; Shanyong Zhang; Zhaoyang Yin; Prof. Zhongli Gao

Our prospective non-randomized clinical study analyzed consequences for segmental and lumbar sagittal balance and movement after TL

Direct Repair of Spondylolysis Following Correction of Adolescent Idiopathic Scoliosis

Lynn Letko, MD; Thomas Welk, MD; Rubens Jensen, MD; Harms Study Group

Eight patients with spondylolysis presented after an average of 3m from correction of their idiopathic scoliosis with pain not responding to conservative therapy. The surgical technique consisted of debridement of the defect, grafting and rigid fixation by either pedicle screws and a V-shaped rod or a cable-screw construct. The mean age at operation was 16 years. Seven patients had an excellent result. Follow up radiographs and CT revealed healing of defects in 7 cases with no implant related complications.

The Potential Impact of New Technologies in Spine Surgery

Yasser ElMiligui, MD, FRCS; Wael Koptan, MD; Prof. Hazem B. Elsebaie, FRCS, MD;

The study examines patient eligibility for new nonfusion posterior devices in a cohort of patients currently undergoing lumbar surgery. The potential impact of these device categories on spine surgery is assessed.

Delayed Treatment of Atlantoaxial Rotatory Subluxation with Intermittent Traction.

Geoffrey Lesage, Resident; Robert Hes; Bart Conix; Carl Brabants; Guido Dua

Case report of Successful treatment of chronic atlantoaxial rotatory subluxation in a six year old girl with intermittent head halter traction

Clinical Outcomes of BRYAN Cervical Disc Arthroplasty of Single Level: A Prospective Controlled Study

Geoffrey Lesage, Resident; Robert Hes; Guido Dua;

Non fusion is better than fusion in cervical degenerative disease?

Direct Repair of Multiple Level Lumbar Spondylolysis by a Cable Screw Construct

Nanjundappa S. Harshavardhana, MS(Orth), Dip. SICOT; Prof. Brian J. Freeman, MD; Vaibhav B. Bagaria, MBBS, MS, FCPS, DO; Harshad Dabke, FRCS; Ujjwal K. Debnath, FRCS; Prof. Abhaykumar M. Kuthe, PhD;

Nine patients with multiple-level spondylolysis of lumbar spine were treated with segmental fixation by a cable screw construct and autogenous tricortical iliac crest grafting after thorough debridement of the defect. The condition involved 2 levels in 7 patients and 3 levels in 2 patients. Clinical outcome was determined according to Mancab's criteria, and reported 'excellent' in 7, 'good' in 1 and 'fair' in 1 patient. Follow up radiographs and CT scans revealed fusion of all defects in 8 patients.

Assessment of Standing Alignment and Trunk Range of Motion in Adolescents Following Spinal Fusion for Idiopathic Scoliosis using Motion Analysis

Prof. Stephen Ondra, MD; John Liu, MD; David Moller, MD; Fadi Nasr, MD; Brian A. O'Shaughnessy, MD; Tyler Koski, MD; Richard G. Fessler, MD, PhD

Twenty-six patients with adolescent idiopathic scoliosis were evaluated pre- and post-op spinal fusion with Motion Analysis to assess trunk alignment and trunk range of motion. Findings included a loss of trunk mobility, especially in trunk rotation.

Does Temporary Spinal Instrumentation Alter Disc Morphology? An MRI-Based Analysis.

Seng-Yew Poh, MBBS, MRCSed, MMed (Ortho); Wai-Mun Yue, MBBS, FRCSed, FAMS(ORTHO SURG); John L. Chen, MBBS BCh (Ire) FRCS Ed; Chang-Ming Guo; Prof. Seang-Beng Tan

Motion of the disc is essential for its nutrition because of the pressure dependent fluid exchange. Temporary transpedicular segment immobilization was shown not to cause new onset or accelerated disc degeneration as assessed by MRI.

Evaluation of a Novel Dynamic Stabilization System 'Transition' in Motion Preservation in the Lumbar Spine

Rick C. Sasso, MD; John G. Heller, MD; Paul A. Anderson, MD; Stephen Papadopoulos; Richard G. Fessler, MD, PhD

A novel dynamic stabilization system Transition™ was tested on cadaveric lumbar spine, in two different test protocols. Motion-priority protocol showed the flexibility is reduced, mostly at the expense of the abnormal Neutral Zone (NZ) motion, redistributing motion through the adjacent segments. Load-priority protocol showed actual increase in stiffness was minimal, due to the dampeners in the system.

Dynamic Stabilization after Total Facetectomy

Douglas C. Burton, MD; Marc A. Asher, MD; Sue-Min Lai, PhD, MS MBA;

Total facetectomy has been a relative contraindication in the use of posterior dynamic stabilization system. This study reviews a series of patients that received dynamic stabilization and required total facetectomy at one or more levels.

Neuromuscular Scoliosis

Frequency and Characteristic of Scoliosis in Prader-Willi Syndrome (PWS)

Donald A. Deinlein, MD; Michael Conklin; Joseph G. Khoury, MD; Shawn Gilbert; Scott Doyle

We analyzed scoliosis in PWS focusing on 1) frequency, 2) characteristics, 3) relationship with growth hormone (GH) use.

A Preoperative Coronal Traction Radiograph Predicts Improvement in Pelvic Obliquity in Neuromuscular Scoliosis after Instrumented Posterior Spinal Fusion

Thanet Waithanaapisith, MD; Surin Thanapipatsiri; Pumibal Wetpiriyakul; Phichai Sansawat, MD

The goal of instrumented spinal fusion in neuromuscular scoliosis with pelvic obliquity is improved sitting tolerance. A preoperative traction film can help predict the postoperative pelvic obliquity.

Pelvic Fixation in Cerebral Palsy Scoliosis: Do the Benefits Outweigh the Costs?

Thomas E. Mroz, MD; Isador H. Lieberman, MD, MBA, FRCS
Nonambulatory patients with cerebral palsy (CP) scoliosis and pelvic obliquity are well managed with fixation to the pelvis; this results in better restoration of pelvic obliquity, sitting ability and a lower reoperation rate. Caregiver satisfaction is high and the complication rate is low.

Evaluation of Pelvic Fixation in Neuromuscular Scoliosis: A Retrospective Study in 55 Patients

Ross R. Moquin, MD; Miriam L. Donohue, B.S.; Catherine Murtagh-Schaffer, RPA-C; Blair Calancie, PhD

There has been always a controversy about pelvic fixation in neuromuscular scoliosis in literature. Some authors advocate pelvic fixation while others do not feel necessity of pelvic fixation. In addition, the indications for pelvic fixation are also different.

Accuracy of Pedicle Screw Placement in Neuromuscular Scoliosis with Free Hand Technique

Prof. Carlos Tello, MD; Eduardo Galaretto, MD; Ernesto S. Bersusky, MD; Alejandra Francheri Wilson, Jr.; Mariano A. Noel, MD; Santiago Balderrama; Luis Muratori

All studies regarding accuracy of pedicle screw in scoliosis represents idiopathic scoliosis using various techniques for screw insertion like free-hand, navigation, image intensifier etc. Anatomy of vertebrae and pedicle are distorted in neuromuscular scoliosis and hence accurate placement of pedicle screw is prerequisite for surgery.

Transverse Pelvic Obliquity Complicates Scoliosis in Cerebral Palsy

Oren N. Gottfried, MD; Michael D. Daubs, MD; Darrel S. Brodke, MD;

Over half of patients with severe scoliosis and cerebral palsy (CP) had significant asymmetry of the pelvis in the transverse plane. This was greatest above the acetabulum and correlated most with the adducted hip, if severely windswept, or with the direction of the curve.

Long Term Results of Spinal Fusion in Patients with Severe Spastic Quadriplegic Cerebral Palsy in One Institution

XueCheng Liu, MD, PhD; Robert Rizza, PhD; John Thometz, MD; Channing Tassone, MD; Roger M. Lyon

A retrospective review of adult patients with severe spastic quadriplegic CP with and without spinal fusion were compared to determine long term outcomes. Parameters evaluated included sitting tolerance, oxygen requirement, mode of feeding, pain, decubitis problem A parental/caregiver satisfaction questionnaire was also performed. Results from this study correlated with the documented literature in that caregiver satisfaction was high but there was no statistical significance in other parameters.

Comparison of Surgical Outcomes between Muscular Dystrophy and Spinal Muscular Atrophy

Temel Tacal, MD; Mehmet N. Ermis; Osman Cimen; Umit Tuhanioglu; Huseyin E. Akdeniz

There is one incomplete report of comparative surgical outcomes between MD scoliosis and SMA scoliosis. We compared the results objectively. % PFVC abruptly reduced after surgery, however, mean ETCO₂ mmHg were showed little improvement in SMA. after surgery, subjective respiratory questionnaire, self-image, and positive opinions were more prevalent in SMA group.

Comparison of Bone Mineral Density between Neuromuscular Scoliosis and Adolescent Idiopathic Scoliosis

Prof. Carlos Barrios; Sandra Cortés; Cristina Pérez-Encinas; M. Dolores Escrivó; Jesus Burgos; Eduardo Hevia

There is no report of compare the BMD between NM scoliosis and AIS. We evaluated the degree of osteoporosis of AIS and NM scoliosis respectively with comparison of BMD between each scoliosis type. The BMD (Z value) of femur was $0.755 \pm 0.073 \text{g/cm}^2$ and vertebra $0.826 \pm 0.068 \text{g/cm}^2$ (-0.891 ± 0.66984) in AIS patients. The BMD (Z value) of femur was $0.525 \pm 0.136 \text{g/cm}^2$ (-3.374 ± 1.033) and vertebrae was $0.612 \pm 0.174 \text{g/cm}^2$ (-2.204 ± 1.531) in NM scoliosis patients. There was significant difference between two scoliosis types in analyzing BMD

Scoliosis Correction in Patients with Duchenne Muscular Dystrophy: Sublaminar Wires and versus Pedicle Screws Segmental Instrumentation.

Eduardo Galaretto, MD; Prof. Carlos Tello, MD; Ernesto S. Bersusky, MD; Alejandra Francheri Wilson, Jr.; Mariano A. Noel, MD; Eugenia Roble;

A comparison of two groups of patients with Duchenne Muscular Dystrophy (DMD) that underwent surgery for scoliosis correction was performed. We found that patients treated with pedicle screw constructs had similar radiological results to the ones operated using sublaminar wires. Nevertheless, the former group seemed to have less complications and lower hospital costs.

Neuromuscular (NM) Scoliosis Corrected by Pedicle Screw Instrumentation- With or Without Posterior Vertebral Column Resection (PVCr)

JahanGir Asghar, MD; Amer F. Samdani, MD; Daniel M. Sciubba, MD; David H. Clements, III, MD; Patrick J. Cahill, MD; M. Darryl Antonacci, MD, FACS; Randal R. Betz, MD; Harms Study Group

Neuromuscular (NM) scoliosis treated by pedicle screw instrumentation with or without posterior vertebral column resection (PVCr) were retrospectively analyzed. The results showed that pedicle screws can be applied effectively with satisfactory results in the treatment of NM scoliosis. PVCr is indicated for severe, rigid deformity with improving results.

M-W Pelvic Fixation Provides Greater Correction for Neuromuscular Spino-Pelvic Deformities than Standard Iliac Galveston Screws

Joshua D. Auerbach, MD; Chenyang Wang, BS; Andrew H. Milby, BS; Heather L. Guerin, PhD; Jill H. Heinly; Baron S. Lonner, MD; Dawn M. Elliott, PhD; Prof. Arijitt Borthakur, PhD

A Retrospective review of 48 neuromuscular scoliosis demonstrated that the M-W segmental sacropelvic fixation comprising of iliac screws with a coupled iliosacral bolt allows for 84% correction of severe pelvic obliquity in contrast to 68% when using Galveston iliac screws.

Treatment of Progressive Spinal Deformity using the VEPTR Device with a Bilateral Percutaneous Rib to Pelvis Technique in Non-Ambulatory Children with Neuromuscular Disease

Temel Tacal, MD; Mehmet N. Ermis; Ahmet S. Kilinc; Ozgun Ercelik; Akif Albayrak

A new bilateral percutaneous rib to pelvis technique using the VEPTR device was used to manage progressive scoliosis in growing children with significant neuromuscular disease avoiding early fusion. Early outcomes were encouraging in this complex, challenging population.

Spinal Instrumentation in Duchenne Muscular Dystrophy: A Comparison of Two Techniques

Julien Clin, MS c.A; Prof. Carl-Éric Aubin, PhD, P.Eng.; Stefan Parent, MD, PhD; Hubert Labelle, MD

Treatment of scoliosis associated with Duchenne Muscular Dystrophy using a technique of Dunn-McCarthy rods and selective anchors resulted in a significant reduction in intra-operative blood loss when compared to a technique utilizing Galveston rods and sublaminar wiring. Pelvic obliquity and scoliosis correction were the same between the two groups.

Poor Compliance of Thoracolumbosacral Orthosis (TLSO) Wear in Children with Spinal Cord Injury (SCI)

Joshua D. Auerbach, MD; Baron S. Lonner, MD; Firas Chamas, MD, PhD; Matthew Vorsanger, BA; Kristin E. Kean, BA

Previous work has found that prophylactic bracing reduces the need for or delays spinal fusion in children with scoliosis secondary to SCI. We sought to determine TLSO compliance using a temperature monitor in two groups of children undergoing high- and low-dose prophylactic bracing and found both groups to be non-compliant.

Scoliosis in Spinal Muscular Atrophy: Natural History and Comparison between Operative and Conservative Treatment

Mehmet B. Balioglu; Temel Tacal, MD; Mehmet F. Yagmurlu; Mehmet N. Ermis; Mehmet A. Kaygusuz

Spinal muscular atrophy (SMA) is an autosomal recessive neuromuscular disorder characterised by motoneuron degeneration in the anterior horn of the spinal cord and in the bulbar nuclei. To evaluate prevalence and evolution of scoliosis in SMA type II and III, and to compare surgery vs conservative treatment, were retrospectively evaluated 145 patients and the results seem to show that the spinal surgery is the only effective treatment to prevent worsening of scoliosis and improve quality life.

Surgical Treatment in Neuromuscular Diseases with a Modified Spinopelvic Trans Iliac Fixation.

Baron S. Lonner, MD; Joshua D. Auerbach, MD; Kristin E. Kean, BA; Matthew Vorsanger, BA

Sometime is questioned the surgery choice in neuromuscular scoliosis and useful of spinopelvic fixation too. Moreover is not clear if there is a difference in outcomes of spinal surgery between spastic or flaccid paresis. Results of this study showed the important role of spinal surgery and suggest a modified spinopelvic transiliac fixation that seems to be easier for surgeon. Moreover was analysed that there are no difference between flaccid or spastic paresis in terms of spinal imbalance after surgery.

Surgical Treatment of Progressive Spine Deformity in a Young Female with Calpainopathy and Rigid Spine Syndrome (RSS).

Roger P. Jackson; Anne C. McManus, RN

Case report of an extremely rare but complex spinal deformity in a patient with a calpainopathy and rigid spine syndrome. Failed conservative treatment with development of a fast progressive deformity led to a two staged front back spinal correction from C2 to the pelvis with successful two year outcome. The disease itself precludes a conservative treatment and only a surgical correction seems suitable for this kind of deformity.

Kinematic and Kinetic Aspects of Sitting in Neuromuscular Spine Deformity. Comparison with Normal Controls and Pre and Post Surgery.

Carl Paulino, MD; Martin Quirno, MD; Baron S. Lonner, MD; Thomas J. Errico, MD; Prof. Daniel Grande

Non-radiographic methods to document results of spine deformity surgery have mostly been qualitative. The used optoelectronic movement analysis system enables quantitative documentation of changes in body balance and dynamic sitting as compared to normal controls and pre and post surgery.

Other

A Long Term Review of Patients with Scoliosis Associated with Syringomyelia and Chiari Malformations.

Igor R. Yusupov, MD; Donald J. Blaskiewicz, MD; Mohamed M. Abdulhamid, MD; Catherine Murtagh-Schaffer, RPA-C; Ross R. Moquin, MD

Patients with scoliosis associated with syringomyelia and/or CM present with long C shaped, left sided or kyphotic curves, though an 'idiopathic-like' curve is not unknown. This study evaluates the long term results of scoliosis treatment in these patients. Correction of the curve can be achieved safely after neurosurgical decompression

Back Surface Asymmetry in Children Aged 3 to 9 Years Old

Mary Jane Mulcahey; Christina Calhoun; Ross Chafetz, DPT, MPH; Louis Hunter, PT, MS; Lawrence C. Vogel, MD; Amer F. Samdani, MD; Randal R. Betz, MD

It is axiomatic, that any screening procedure for abnormality is based on knowledge of normality. This report based on the scoliometer readings in both standing and sitting forward bending position (FBP) of 3301 children provides information on the variability of back surface asymmetry in "normal" Mediterranean juveniles and present data which describe the evolution of trunk asymmetry from early childhood to adolescence. This information is worth knowing when a child is examined for juvenile scoliosis

Spinal Surgery in Jehovah's Witnesses

Joshua D. Auerbach, MD; Zachary D. Weidner, BA; Andrew H. Milby, BS; Mohammad Diab, MD; Baron S. Lonner, MD

In Jehovah's Witnesses, surgical intervention is restricted as they refuse blood transfusions. We experienced five cases with spinal disorders including scoliosis in whom we achieved one- or two-stage surgeries due to the preoperative plan. In several cases, autologous transfusion using cell saver and isovolemic hemodilution were agreed to use by patients. Therefore in all cases, we safely performed surgical interventions without applying allogeneic blood transfusion and pre-deposit autologous blood transfusion.

Treatment of Severe Scoliosis with Posterior Operation by Stages

Reginald Q. Knight, MD; Pedro Vieco, MD; Jim Robinson, MD; Jeffrey S. Roh, MD

32 patients with severe scoliosis were treated with posterior operation in two stages. The average preoperative Cobb major angle was 97.3° (82-170°). The first stage surgery were performed with posterior mini-incision and propped up. Posterior correction with osteotomy, arthrosis release, shave abnormality excision and fusion were performed in second stage surgery 3-6 months later. The postoperative correction of major curve was 36.7° (25-66°). The imbalance of the trunk and shoulders were improved distinctly. All patients underwent the surgery safely and there were none server complications occurred.

Evaluation of the Surgical Outcomes for Spinal deformity in Neurofibromatosis- Comparison of Short-term Clinical, Functional and Radiological Outcomes-

Louis Hunter, PT, MS; Randal R. Betz, MD; Mitell Sison-Williamson; Anita Bagley; Lawrence C. Vogel, MD; Craig McDonald; Amer F. Samdani, MD; Mary Jane Mulcahey

We investigated the relation between surgical outcomes for spinal deformity in neurofibromatosis and patient perception of their deformity and quality of life measures using the SRS-24, the SF-36 and the WRVAS. These results suggest that the residual spinal deformities after surgery and the residual pain may affect the scores of SRS-24 and WRVAS. Patient's satisfaction and improvement of QOL might be expected by an early prophylactic surgery especially for this kind of patients.

Internet Usage In Obtaining Information On Degenerative Lumbar Spine Disease And Its Influence On Decision Making by Patients.

Nanjundappa S. Harshavardhana, MS(Orth), Dip. SICOT; Ujjwal K. Debnath, FRCS; Harshad Dabke, FRCS; Prof. Brian J. Freeman, MD; Hossein Mehdian, FRCS, MD

Role of internet in patient awareness of Degenerative Lumbar spine condition and making informed decisions on its management.

Spinal Deformities in Neurofibromatosis

Jay Jagannathan, MD; Christopher I. Shaffrey, MD

Neurofibromatosis is an autosomal dominant hereditary disorder characterized by an abnormal proliferation of cells from the neural crest.. Two clinical forms exists – neurofibromatosis 1 (peripheral neurofibromatosis) and neurofibromatosis 2 (central neurofibromatosis). Two types of scoliosis have been identified – according to the presence or absence of dystrophic changes. Non dystrophic curves present like idiopathic curves. However they present at an earlier age and are more likely to progress than idiopathic curves. These are less aggressive as compared to dystrophic ones. Dystrophic curves are short sharply angled curves. They develop at earlier age. These curves require early and aggressive surgery and are known to progress despite spinal arthrodesis. Also hyperkyphosis is always associated with severe progression of deformity.

Functional Difficulties with Activities of Daily Living due to Stiffness after Lumbar Spinal Fusion are Not Strongly Correlated with ODI Scores.

Brian K. Kwon, MD, PhD; Lise Belanger, RN, BSN, MSN; Donna Chan, RN; Arlene Bernardo, RN; Gerard Slobogean, MD; Michael C. Boyd, MD, MSc; Scott C. Paquette, MD; Hamed Umedaly, MD; Mitch Giffin, MD; John Street, MD; Charles Fisher, BSc, MHSc, MD, FRCS; Armin Curt, MD; Marcel F. Dvorak, MD

Stiffness-based disability assessed with LSDI was not strongly correlated with ODI scores. Increasing numbers of fusion levels led to higher LSDI scores, while ODI scores remained relatively flat.

Incidence and Trends of Post-Traumatic Stress Disorder Symptoms in Orthopedic Patients Following Lumbar Spinal Fusion Procedures

Jay Jagannathan, MD; Toomas Anton, MD; Prof. Vincent Arlet, MD;

The incidence of PTSD is 20% following lumbar fusion surgery, resolving in most patients by 6 months postoperatively.

Spinal Deformity in Patients with Sotos Syndrome (Cerebral Gigantism)

Athanasios I. Tsirikos, MD, FRCS, PhD; Sheila P. Howitt; Michael J. McMaster, MD, FRCS

We followed 5 consecutive patients with Sotos syndrome and spine deformity to skeletal maturity. The pattern of deformity was variable with 3 patients developing a scoliosis, one developing a kyphoscoliosis, and the remaining patient developing a pure kyphosis. Three patients underwent surgical correction of their deformity with a good outcome.

One Size Does Not Fit All: Variations in Pelvic and Other Sagittal Parameters as a Function of Race in AIS

Prof. Yong Qiu, MD; Haibo Li, PhD; Prof. Bin Wang, MD; Prof. Yang Yu, MD; Prof. Zezhang Zhu, MD; Xu Sun, PhD

Differences in pelvic parameters and lumbar lordosis were found in this AIS population between Black and White races.

Spinal Biomechanics

Reduce Screw Migration due to Vertebral Body Augmentation for two Different Loading Scenarios

Kit Song; Nathan Frost; Joe Eichinger; Klane K. White, MD, MSc
Bone augmentation increases pedicular screws performance for osteoporotic vertebrae. Relevance and quantification of the benefit supplied by this method has been investigated using two different caudocephal compression test setups with stepwise increase of the load. Both setups have revealed significant improvement of the screw bearing capacity (up to 58.7%).

Do Expandable Cages Improve Segmental Stability Following a Lumbar Corpectomy? An In-Vitro Biomechanical Study

Athanasios I. Tsirikos, MD, FRCS, PhD; Nestor Demosthenous, MBChB; Michael J. McMaster, MD, FRCS

Results from the current study indicate that circumferential fixation coupled with an expandable anterior cage is the most effective construct in reducing post-operative ROM at the level of the corpectomy.

Biomechanical Characteristics of Different Regions of the Spine: an In Vitro Study on Multi-level Spinal Segments.

Faisal Mahmood; Arash Emami, MD; Ki Soo Hwang, MD; Michael Faloon, MD; Kumar Sinha, MD

An In Vitro study was done on biomechanical characteristics of different regions of the spine. Flexibility of 24 porcine spinal segments was tested in 4 directions and quantitative information was acquired. Flexibility of the spinal regions was significantly different in all directions.

Segmental Fixation and a 5.5 mm Rod Approaches the Stiffness of a 6.35 mm Rod: A Biomechanical Study

Hong Zhang, MD; Daniel J. Sucato, MD MS; William A. Pierce, BS

Increasing both rod diameter and number of pedicle screw connections in a porcine model increased construct stiffness in physiologic torsional loading. Using a smaller 5.5 mm ultra high strength rod with segmental screw fixation approached the stiffness of a 6.35 mm non-segmental construct.

Transforaminal Lumbar Interbody Fusion: Biomechanical Evaluation of Stability and Intervertebral Pressure

Lesia M. Nelson, BS; Rakesh Chettier, MS; James W. Ogilvie, MD; Kenneth Ward, MD

The TLIF is a popular treatment of lumbar disorders but there are no studies evaluating how various TLIF techniques effect stability and intervertebral pressure. This study evaluates the biomechanical stability and intervertebral pressure of anterior and posterior graft placement with unilateral and bilateral fixation.

Use of a Dynamic Stabilization System on Distal Adjacent Kinematics for Anterior Spinal Fusion

Brian G. Smith, MD; Jeffrey D. Thomson, MD; Sylvia Ounpuu, MS

Anterior spinal fusion for the treatment of thoracolumbar/lumbar scoliosis allows shorter constructs to achieve similar correction as a posterior spinal fusion. However, this exerts significant stress on levels directly caudal to the fused segments. A flexible "transition" bumper placed distally to an ASF construct demonstrated a controlled diminution of adjacent level range of motion to motion values equivalent to or lower than the intact state.

Biomechanical Effect of the Iliac Screw Insertion Depthon Lumbo-Iliac fixation Construct

Panagiotis Korovessis, PhD, MD; Georgios Petsinis, PhD, MD; Thomas Repantis, MD; Despina Deligiani

Spino-pelvic reconstruction remains a challenge to spine surgeon. Despite many fixation methods are reported, Spino-pelvic reconstruction using iliac screw seems most favorable. However, various sizes of iliac screws are applied in surgical treatment, and none has biomechanical evidence.

The Effect on Pedicle Screw Pullout Strength of Optimizing Pedicle Fill Using a Tool to Size and Dilate the Pedicle

Prof. Arvind Jayaswal, MS; Bidre Upendra, MS; Ajay Kumar, MS; Lalit Sharma, MS; Buddha Chowdhury; Abrar Ahmed

A biomechanical study of the significant increase in pullout strength that occurs when pedicle screw diameter is selected to maximally fill the pedicle by using a tool to size and dilate the pedicle. Screw pullout of the optimally filled pedicle was compared with a standard diameter screw in cadaver spines.

Relationship of Donor Variables and Graft Dimension to Biomechanical Performance of Femoral Ring Allograft

Yutaka Sasao, MD, PhD; Takehiko Miura; Prof. Haruhito Aoki; Yoshiaki Torii; Atsushi Kojima

For optimal clinical function, structural allograft bone must be able to support substantial loads. Ten matched femoral pairs from five cadaveric donors were obtained and tested in axial compression. Load to failure was correlated with several variables. Cortical wall thickness and diameter were correlated significantly with load to failure. These results demonstrate that several structural parameters affect the ultimate failure load of structural femoral ring allograft.

Lumbar Disc Volume and Hydration after Scoliosis Surgery

Jayanth Paniker, MBBS; Shahid Khan, FRCS; David S. Marks, FRCS; Jonathan B. Spilsbury; Alistair G. Thompson

28 adolescents operated for scoliosis had preoperative MRI and postoperative MRI. 3D disc reconstruction and volume computation were achieved. Surgery induced a significant volume increase in disc below the arthrodesis. The disc hydration increased post-operatively and showed some stabilization or reduction between 3 months and 12 months

The Effect of Dilatation of Pedicles on Pull-Out Strength of the Screws in Immature Pig Model

Prof. Arvind Jayaswal, MS; Bidre Upendra, MS; Devkant Meena; Buddha Chowdhury; Abrar Ahmed

The aim of this study is to evaluate the biomechanical stability of screws placed in expanded pedicles and to compare with the non-expanded ones in an in vivo immature pig model and to investigate the effect of possible pedicle remodelling on screw stability. We found no statistically significant difference between the two groups. This study demonstrated that the biomechanical stability of the same size screws inserted at the expanded and non-expanded pedicles are the same after three months

Predictive Ability of Tapping Insertional Torque on Pedicle Screw Fixation Strength and Optimal Screw Size

Selvon St. Clair, MD, PhD; Juay Seng Tan, PhD; Isador H. Lieberman, MD, MBA, FRCS; Mark Kayanja, MD, PhD

Tapping IT directly correlates with the screw IT, and therefore can be used intraoperatively to judge fixation strength. Additionally, sequential tapping offers further guidance towards determining optimal screw size. Using 2.5 in-lbs. as a threshold for tapping IT appears to be a viable predictor to obtain optimal screw placement in the thoracic spine.

Vitallium® has Greater Fatigue Strength than Titanium for Curved Posterior Fusion Rods

Edward Rainier G. Santos, MD; Jonathan N. Sembrano, MD; Joseph Turner, MS; Benjamin Mueller, MD; Rex Armstrong; David W. Polly, Jr., MD

Compression fatigue testing was performed on lumbar bilateral corpectomy models made of contoured Vitallium, titanium or stainless steel rods.

Pull-Out Resistance Provided by a New Fenestrated Pedicle Screw in Vertebrae with Compromised Bone Mineral Density

Rolando F. Roberto, MD; Bobby Dezfuli

Results from a cadaver study indicate that a cement-augmented fenestrated pedicle screw significantly improves pull-out resistance in osteoporotic vertebrae.

Comparison of Cage Designs for Transforaminal Lumbar Interbody Fusion: A Biomechanical Study

Jonathan N. Sembrano, MD; Edward Rainier G. Santos, MD; David W. Polly, Jr., MD;

Biomechanical comparative study among different TLIF cage designs showed that they do not affect biomechanical properties when they are used with posterior fixation.

Is it Safe to Remove Pedicle Screws with Cement Augmentation?

Edward Rainier G. Santos, MD; Jonathan N. Sembrano, MD; Joseph Turner, MS; Benjamin Mueller, MD; Rex Armstrong; David W. Polly, Jr., MD;

Removal of pedicle screws after bioresorbable cement augmentation is safe regardless of the insertion timing of screw into cement.

Biomechanical Comparison of Transpedicular versus Extrapedicular Vertebroplasty Using Polymethylmethacrylate

Jonathan N. Sembrano, MD; David W. Polly, Jr., MD

Cement can be injected through either an extrapedicular or transpedicular approach in both vertebroplasty and kyphoplasty procedures. The objective of this study is to compare the biomechanics of transpedicular and extrapedicular approaches in terms of height restoration, strength, and stiffness. Both extrapedicular and transpedicular techniques increased strength but reduced stiffness compared with the intact condition. The extrapedicular technique achieved greater height restoration possibly attributed to its easier access to the fracture site

Spinal Hemiepiphyodesis Affects Compressive Stresses in Intervertebral Joint

J. Navesh-Babu; Prof. Huiyen Tao; Yan Peng; Gabriel Liu, MB Bch MSc FRCSEd(orth); Prof. Hwan Tak Hee, MD; Prof. Hee-Kit Wong;
Spinal hemiepiphyodesis increased compressive stresses in the intervertebral disc using a staple-like implant in both in vivo and In Vitro porcine models.

Sagittal T1 Tilt Angle and the Correlation with Various Sagittal Balance Parameters

Magda Janowska; Ryszard Tomaszewski
The goal of this study is to evaluate and quantify multiple factors that influence sagittal balance.

Biomechanical Evaluation of a New AxialLIF Technique for Two Level Lumbar Fusion

Haruo Misawa; Masato Tanaka, MD; Kazuo Nakanishi; Prof. Toshifumi Ozaki
In this study, the biomechanics of L4-S1 motion segments instrumented with the AxialLIF 2L transsacral rod was evaluated. It is important to align the extension rod during insertion into the sacrum to prevent stripping of the rods threads at L4 and L5 vertebral bodies and maintain coronal balance. Standalone AxialLIF reduced intact motion at both levels. Both facet screw and pedicle screw fixation provide high construct stability.

Morphology of the Pelvis Regulates the Pelvic Radius Angle and Sagittal Spinal Profile

Jonathan N. Sembrano, MD; Megan K. Raverty, B.A.; Blake A. Johnson, MD; David W. Polly, Jr., MD
The Pelvic Radius Angle and vertebral endplate slope provide important clinical information regarding pelvic morphology and the sagittal profile without having to identify and register the entire sacral endplate.

Torsional Rigidity of Long Scoliotic Constructs: Hooks versus Screws

Taku Nakakohji; Satoshi Kawasaki
The gold standard for treating scoliosis and preventing the crankshaft phenomenon is anterior fusion and a posterior hook construct. It has been hypothesized, that a pedicle screw fixation alone can provide similar torsional rigidity with a single step procedure. This study attempts to validate the claim that a pedicle screw fixation provides as much stiffness as the gold standard.

Biomechanical Analysis of Four Modern Lumbosacral Fixation Techniques

Akiva Korn, MMedSc; Michael Fishkin; Aviel Silbiger, MD; Prof. Shlomo Wientroub, MD; Dror Ovadia, MD
Iliac screws and S1 screws both increase the stability of long posterior constructs. The use of a crosslink increases stiffness, however the position of the iliac connector provides no clear advantage.

Biomechanical Importance of the Anterior Longitudinal Ligament in a Corpectomy Model

J. Navesh-Babu; Prof. Huiyen Tao; Yan Peng; Gabriel Liu, MB Bch MSc FRCSEd(orth); Prof. Hwan Tak Hee, MD; Prof. Hee-Kit Wong
In a corpectomy model, circumferential instrumentation provides significantly more stability compared to an anterior stand-alone plate. Additionally, the structural stability offered by an intact ALL can be overcome by using an expandable cage.

Torsional Rigidity of Long Scoliotic Constructs: Screws at T7

Antonello Montanaro; Francesco Turturro; Luca Labianca, Medical Doctor; Daniele Paravani; Alberto Bonifazi; Prof. Andrea Ferretti
The treatment of scoliosis with a pedicle screw fixation has become a standard practice. In this study we try to determine the importance of placing one or two screws at T7, the apex of a scoliotic curve.

Change in Intervertebral Pressure Distribution Following the Implementation of a Fusionless Device

Lloyd A. Hey, MD, MS; Jaclyn Wagner, PA-C; Brittany Harris, PA-C
The intravertebral pressure in 7 goat spines with a spring device were measured during tensile loading. The computer model developed from the in-vitro goat spine testing predicted a positive relationship between instrument stiffness and pressure distribution between vertebral bodies, which will be critical in determining the impact of stiffness on the growth plate.

Global Spinal Balance and Segmental Vertebral Body Alignment Around the Vertical Pelvic Hip Axis: Rational for Hip Axis Coordinate Based Assessment

Hossein Elgafy, MD, MCh, FRCSEd, FRCSC; Hassan Semaan, MD; Prof. Theodore Wagner, MD; Richard J. Bransford, MD
The Hip Axis should be considered a key parameter for assessing standing spinopelvic posture in 3-planes. For compensated balance, the T4 centroid should always be behind the L4 centroid and the Hip Axis.

Biomechanical Evaluation of a New Pedicle Screw- Rod-link Reducer Posterior Instrumentation System for Severe Spinal Deformities

Francesco Turturro; Antonello Montanaro; Luca Labianca, Medical Doctor; Alessandro Carcangiu, resident; Russalka Hoedemaeker; Prof. Andrea Ferretti
A novel pedicle screw / rod-link reducer posterior instrumentation system has been developed to provide a safer, easier and improved deformity correction, as well as shorter surgical time for the PVCR of the severe spinal deformity. Biomechanical evaluation of this system demonstrated spinal stability throughout the surgical procedure to reduce the risk of spinal cord injuries.

How Rigid Should a Pedicle-Screw Instrumentation be, to Provide Spinal Fusion and Avoid Adjacent Segment Disease? A Mechanical Comparative Study of a Rigid vs. Semirigid and Flexible Fixation in Short Lumbar Fixation

Prof. Paul F. Heini, MD

“In vitro” mechanical comparative study of three different lumbar pedicle-rod constructs of different stiffness [“rigid”(R), “semirigid”(S) and “flexible”(F)] to answer to the dilemma often posed to spine surgeons: How rigid should be an instrumentation to safeguard spinal fusion and avoid adjacent segment disease?

An Evaluation of the Kinematics and Mode of Failure of Transpedicular Lumbar Interbody Fixation

Ryszard Tomaszewski; Urszula Izwaryn

A biomechanical study was carried out to compare kinematics between transpedicular lumbar interbody fixation (TPLIF) and instrumentation with pedicle screws and rod (PS) and no significant difference was found. Failure was found to occur under lower loads in flexion than in extension for both TPLIF and PS. With TPLIF, failure occurred at the ventral screw bone interface without pedicle fracture.

What is the Best Iliac Screw Size and Trajectory?

Mark A. Erickson, MD; Allison Kempe, MD, MPH; Elaine H. Morrato, DrPH, MPH; Brenda Beaty, MSPH; Kathryn Benton, MSPH; Elise Benefield, RN BSN

There is great variability in iliac screw fixation in terms of screw trajectory and diameter. This cadaveric biomechanical study investigated the insertional torque generated by iliac screws. Two trajectories (supra-acetabular and anterior-inferior iliac spine trajectory) and two screw diameters (9.5 mm and 7.5 mm) were used. Results showed no significant difference in insertional torques between the trajectories. The 9.5 mm diameter screws generated higher insertional torques. Image-guided surgery and intra-operative CT scanning led to a more precise placement of iliac screws.

What is the Best Iliac Screw Size and Trajectory?

Ryan Chau, BM BS; Ian Nelson; John Hutchinson

This cadaveric biomechanical study investigated the insertional torque generated by iliac screws using two trajectories (supra-acetabular and anterior-inferior iliac spine trajectory) and two screw diameters (9.5mm and 7.5 mm). Results showed no significant difference in insertional torques between the trajectories. The 9.5 mm diameter screws generated higher insertional torques. Image-guided surgery and intra-operative CT scanning led to a more precise placement of iliac screws.

Comparison of Mechanical Characteristics of Fixation Rods in Spinal Constructs

Alok D. Sharan, MD; Terry Amaral, MD; Adam L. Wollowick, MD; Vishal Sarwahi, MD

CoCr’s clinical history indicates more potential for use as a stiffer longitudinal element in spinal constructs for demanding deformity corrections. Using CoCr rods with Ti screws could be an effective, economical solution to the challenges of treating these patients. This work is a first step in evaluating the relative merits of its use in these applications.

Spinal Osteoporosis and Metabolic Bone Disease

Do Kyphoplasty and Vertebroplasty have Different Outcomes in the Treatment of Painful Osteoporotic Vertebral Compression Fractures?

Hubert Labelle, MD; Pierre Roussouly; Stefan Parent, MD, PhD; Daniel Chopin; Eric Berthonnaud, PhD; M. T. Hresko, MD; Michael O’Brien, MD

In a group of patients followed up prospectively, KP failed to prove safer or more effective than VP in the treatment of symptomatic osteoporotic VCFs after 3 years from treatment.

SL (Spiral-Lead) Tube for Kyphoplasty

Mark A. Erickson, MD; Allison Kempe, MD, MPH; Elaine H. Morrato, DrPH, MPH; Brenda Beaty, MSPH; Kathryn Benton, MSPH; Elise Benefield, RN BSN

Nowdays, Kyphoplasty are popularized in the treatment of osteoporotic compression fracture, pathologic fracture and other benign condition. complications following kyphoplasty are very rare and this procedure are known to be very safe. but patients can suffer back pain during procedure.

Does Timing Matter in Performing Kyphoplasty? Acute Period versus Chronic Period in Osteoporotic Vertebral Fractures

Takayuki Yamashita, MD; Krzysztof Siemionow, M.D; Thomas E. Mroz, MD; Isador H. Lieberman, MD, MBA, FRCS

The objective of this study is to compare clinical and radiological outcomes of symptomatic acute (<12 weeks) to chronic (> 16 weeks) osteoporotic vertebral compression fractures treated with kyphoplasty. Restoration of the vertebral height and local kyphosis were better accomplished by kyphoplasty in the acute period compared to the chronic period. However, clinical improvement was found to be the same in both periods. Timing of kyphoplasty does only matter in radiological improvement in patients with osteoporotic vertebral fracture.

Utility of Calcitonin in the Treatment of C2 Fractures. Case Series.

Michael G. Vitale, MD MPH; Jaime A. Gomez, MD; David M. Privitera, MD; Hiroko Matsumoto, MA; Joshua E. Hyman, MD; David P. Roye, Jr., MD

Addition of calcitonin to standard management of C2 fractures is safe and effective option.

3-Dimensional O-Arm Imaging in Kyphoplasty: Ensuring Success, Avoiding a Mess

Svante Berg, MD; Hans Tropp, MD, PhD

The O-arm intraoperative CT imaging system was used to perform 8 kyphoplasty procedures. Three-dimensional imaging was able to give additional information that was not readily appreciated on standard 2-dimensional imaging. This included finding a misplaced trocar that was medial to the pedicle, and confirming proper balloon placement in a vertebral body with thin expanded walls. This initial experience suggests that the O-arm is a useful imaging tool that may help improve the performance of kyphoplasty procedures.

Spondylolisthesis

Comparison of Film and Digital Measurements of Radiographic Parameters in Degenerative Lumbar Spondylolisthesis

Brian A. O'Shaughnessy, MD; Timothy Kuklo, MD, JD; Tyler Koski, MD; Patrick C. Hsieh, MD; Prof. Stephen Ondra, MD

The accuracy of digital and film measurements of degenerative lumbar spondylolisthesis is comparable; digital measurements may be used clinically and in clinical research.

New Conservative Approach to Patients with Spondylolysis or Spondylolisthesis and Associated Back Pain using a Modified Pediatric Mechanical Physical Therapy Evaluation and Treatment Program

Marina Moguilevitch, MD; Terry Amaral, MD; Alok D. Sharan, MD; Adam L. Wollowick, MD; Vishal Sarwahi, MD

This is a retrospective evaluation of a new conservative treatment for back pain in spondylolysis and spondylolisthesis to evaluate the patients' initial response to therapy and the time it took them to return to activity.

Biomechanical Characteristics of the Segmental Instability in Lumbar Degenerative Spondylolisthesis

Douglas C. Fredericks, BS; James V. Nepola, MD; Joseph D. Smucker, MD;

The segment of lumbar degenerative spondylolisthesis (DLS) is not always unstable. The biomechanical characteristics were, however, lower stiffness in flexion and higher neutral zone (NZ) compared to normal segments.

Radiographic Assessment of Lumbar Facet Distance Spacing and Pediatric Spondylolysis

Haluk Berk; Azmi Hamzaoglu; Cagatay Ozturk; Murat Tonbul; Mehmet Tezer; Omer Karatoprak;

Spondylolytic defects have been previously shown in an adult population to be associated with decreased interfacet spacing when compared to normal controls. We explore this relationship in a pediatric population. The AP lumbar radiographs of 41 patients are compared to age- and sex-matched controls. We discover that a similar relationship holds true in a pediatric population in that an insufficient increase in interfacet spacing as one moves caudally is observed in patients with spondylolytic defects.

Non-Operative Treatment of Spondylolysis and Grade I Spondylolisthesis in Children and Young Adults: A Meta-Analysis of Observational Studies

Axel Hempfing, MD; Heiko Koller, MD; Prof. Claus Carstens, Prof. Florian Geiger; Luis Ferraris

A meta-analysis of non-operative treatment of spondylolysis with Grade I spondylolisthesis in children and young adults was conducted. Non-operative treatment resulted in a successful clinical outcome in 83.9% of cases. Bracing does not appear to influence this outcome. Lesions diagnosed at the acute state were more likely to heal after non-operative treatment as were unilateral defects when compared to bilateral defects.

Pars Repair Technique & Rationale of Treatment in adults.

Douglas C. Fredericks, BS; James V. Nepola, MD; Joseph D. Smucker, MD;

Pars interarticularis defect is asymptomatic is most adults. When adults with this defect have activity related back pain then one must try and work out the pain source which could be - the adjoining degenerate disc or the lysis defect. With doing a lysis block and/or discography one could be more certain of the pain source and can even offer 'lysis repair' to adults with a good outcome.

Spondylolisthesis: Intra and Inter-Observer Variability in the Measurement of Percent Slip

Douglas C. Fredericks, BS; James V. Nepola, MD; John Manocchio; Joseph D. Smucker, MD

Our results indicated that orthopaedic surgeons can evaluate slip% in spondylolisthesis patients through utilization of PACS software line tools and a standard set of instructions with high intra/inter-observer reliability.

Outcome of Direct Pars Repair in Competitive Athletes.

Houman Ahmadiadli, resident; Z. Deniz Olgun; Prof. Muharrem Yazici, MD;

This is a prospective study of 43 adolescent athletes with spondylolysis/ grade 1 spondylolisthesis who were treated by direct pars repair and showed excellent results at one year follow up.

Transforaminal Lumbar Interbody Fusion in Postlaminectomy Spondylolisthesis

Axel Hempfing, MD; Heiko Koller, MD; Oliver Meier; Luis Ferraris
Twenty three patients with postlaminectomy spondylolisthesis included. The average age was 41y. Twelve were at L4/5 and 11 at L5/S1 levels affected. MRI revealed recurrent disc lesions in 14 patients. Standard TLIF was performed including factectomy, discectomy, cage insertion and instrumentation. The medium of the Oswestry Disability Index decreased from 32 to 11 points. Sagittal translation was reduced from 29% to 12% and the fusion rate was 93%. Disc space height improved by 29%. There were 4 postoperative complications.

Trans-Sacral Mesh Cage with Partial Reduction for Treatment of High-Grade Spondylolisthesis.

Jason J. Howard, BEng, MD, FRCSC; Samantha Swanson; Prof. Janet L. Ronsky, PhD; Paolo Antonio R. Punsalan, MD; Rhiannon Evison, BSc.; David L. Parsons; Prof. Ronald F. Zernicke, PhD
A clinical retrospective study to evaluate both radiographic and clinical outcome of partial reduction, followed by trans-sacral interbody fusion using titanium mesh cage for high-grade spondylolisthesis in adults.

Can Surgical Reduction Correct Spino-Pelvic Alignment in L5-S1 Developmental Spondylolisthesis?

Sylvain Deschesnes, PhD; Stefan Parent, MD, PhD; Guy Charron, PhD; Gilles Beaudoin, PhD; Hubert Labelle, MD; Marie-Claude Miron; Josée Dubois, MD
In a retrospective analysis of 73 subjects with grade 2 or higher spondylolisthesis, spino-pelvic alignment was measured on X-rays at an average 1.9 years after reduction and posterior fusion with spinal instrumentation or cast. Globally, no changes were found in pelvic balance, but after sub-classifying subjects into balanced and retroverted pelvis, pelvic balance and lumbar spinal shape were significantly improved. These results support the contention that reduction techniques might be considered for subjects with a retroverted pelvis.

Surgical Complications

Periradicular Fibrosis. What To Do ?

Adam L. Wollowick, MD; Beverly Thornhill, MD; Terry Amaral, MD; Alok D. Sharan, MD; Vishal Sarwahi, MD
Observations on Fibrosis: Extent of fibrosis depends on patient to patient variation due to inflammatory response, vascular condition, and surgical approach/technique.

Surgical Complications in Early Onset Scoliosis: The Steep Part of the Learning Curve or the Thin End of the Wedge?

A. Atiq Durrani, MD; Albert Chavanne; M. Arif Khan, MD; Rasesh R. Desai, MD
Between March 2002 and July 2005 a total of 44 surgical procedures were performed in 20 young scoliosis patients involving the use of unfused instrumentation. All patients received either ISOLA growing rod instrumentation or VEPTR. There was an alarmingly high rate of deep infection which occurred early in the VEPTR group and late after many lengthenings in the growing rod group.

Impact of Spinal Cord Displacement in Thoracic Pedicle Screws Stimulation Thresholds during Scoliosis Surgery.

Girts Murans, MD; Elena M. Gutierrez-Farewik, PhD; Helena Saraste, MD
Triggered electromyographic stimulation for precise insertion of thoracic pedicle screws is controversial. There is a lateral displacement of the spinal cord towards the concavity of the scoliotic curve in patients going to surgery. Stimulation thresholds of intrapedicular screws placed in the concavity of the scoliotic curve are significantly lower than thresholds of intrapedicular screws in the convexity of the curve. Spinal cord displacement is a source of error using triggered EMG to assess pedicle screw placement.

Peri-Operative Complications of Anterior Lumbar Surgery in Obese versus Non-Obese Patients

Vance Gardner, MD; Jeffrey E. Deckey, MD; Gregory D. Carlson, MD; Shadfar Bahri, MD
Obesity is not related to increased risk of complications in anterior lumbar surgery. Although obese patients have significantly longer duration of anterior exposure, longer duration of entire anterior surgery, longer length of anterior incision, more depth from skin to fascia and from fascia to spine compared to non-obese patients, there is no significant difference in the blood loss, total PCA morphine used, length of hospitalisation, length of time to ambulation and complication rates.

The Influence of Gender on Adult Spinal Deformity Surgery: A Comparison of Radiographic Outcomes and Complication Rates

A. Atiq Durrani, MD; John M. Racadio, MD; Rasesh R. Desai, MD; Albert Chavanne; M. Arif Khan, MD
Although radiographic and functional outcomes following operative spinal deformity correction have been studied, all cohorts consist of females as the predominant gender. A retrospective, matched, comparative analysis was performed to evaluate the differential functional and radiographic outcomes between male (N=25) and female (N=23) deformity patients. The male group presented with larger curves, required longer operative times, and experienced greater blood loss.

Risks for Spinal Cord Injury from Electrocautery Coagulation Around Thoracic Nerve Roots.

Mark Dekutoski, MD; Andrew Utter; Laurie Mihalik, CCRP
Electrocautery was used near or directly on the dural root sleeves, 6-8 mm away from the spinal cord of 5 pigs at different time intervals. After 20 seconds of EC, EMG/MEP changes were observed in 83% of the cases. After 21-55 seconds, permanent loss of MEP occurred in 100% of the cases. One must use the cautery for short intervals to allow tissue cooling thus avoiding heat damage to the spinal cord.

The Role of Tranexamic Acid and Increased Bovie Setting in Blood Loss and Transfusions During Posterior Spinal Fusions for Adolescent Idiopathic Scoliosis

Daniel J. Sucato, MD MS; B. Stephens Richards, MD; Charles E. Johnston, II, MD; Lawrence G. Lenke, MD; Timothy Kuklo, MD, JD; James O. Sanders, MD; Spinal Deformity Study Group
TXA and an increased Bovie setting can significantly decrease intraoperative blood loss in posterior spinal fusions.

Location of the Lumbar Ventral Nerve Roots and the Retroperitoneal Large Vessels with Respect to Minimally Invasive, Lateral Interbody Fusion Technique, in the Normally Aligned and Deformed Spines.

Reginald Q. Knight, MD; Jeffrey S. Roh, MD
Among the potential risks during minimally invasive direct lateral fusion is inadvertent injury to the exiting nerve root or to the retroperitoneal vessels. MRI studies were used to identify the anatomic location of these anatomic structures and to assess whether their location is affected by spinal deformity. 337 intervertebral segments from 52 females and 48 males were measured, using X-rays and MRI images. The measured intervertebral segments were divided into 4 groups: Group 1 (n=247) consisted of normally aligned vertebrae and disc space. Group 2 (n=19) consisted of degenerative spondylolisthetic segments. Group 3 (n=52) consisted of segments showing severe disc degeneration and a collapsed disc space. Group 4 (n=19) consisted of apex segments from spines with degenerative lumbar scoliosis. The ratio between the nerve root position (B) and the vertebral body diameter (A), gradually increases from 9.48% at the L1-2 level to 24.27% at the L4-5 level. The overlap ratio between the retroperitoneal blood vessels (C) and the vertebral body diameter (A) also increases from 7.63% on the right side and 1.22% on the left at the L1-2 level to 19.48% and 6.48% accordingly at the L4-5 level. Neither of the degenerative deformities significantly changed the anatomic location of the nerve root in relation to the vertebral body. The location of the exiting nerve root becomes progressively anterior at each level going from L1-2 to L4-5 while the overlap of the retroperitoneal blood vessels over the AP aspect of the vertebral body increases. The safe corridor for making the disectomy and inserting the intervertebral cage thus becomes narrow at the L4-5 level.

Neurological Deficit Resulting from Segmental Vessel Ligation in Patients Undergoing Anterior Spinal Deformity Surgery

Kenneth Ward, MD; James W. Ogilvie, MD; Rakesh Chettier, MS; Lesa M. Nelson, BS
This large retrospective review of 325 consecutive primary anterior spinal procedures for deformity correction revealed only one instance of paraplegia related to segmental vessel ligation. Segmental vessel ligation appears to have no risk of causing neurological compromise, unless performed in patients with complex congenital spinal deformities occurring primarily in the thoracic spine, associated with spinal dysraphism at the same level and treated with vertebral column resection and/or spinal osteotomy.

Shoulder Functional Assessment after Anterior Spinal Fusion for Thoracic Scoliosis: Comparison among Thoracotomy, Mini-open Thoracotomy and Thoracoscopic Approaches

Mark Dekutoski, MD; Prof. Ralf Gahr
At a minimum follow-up of 1 yr, the ipsilateral and contralateral shoulder function of fifty-seven thoracic scoliosis patients receiving anterior fusion was assessed with the Constant score. No compromise in the function of the shoulder at the same side of anterior approach suggests there might be minimal influence of the approaches of anterior thoracic spinal fusion on the shoulder function.

Pedicle Screw Placement after Pediatric Spinal Deformity: Do Non-idiopathic Patients Have Higher Misplacement Rates?

Beverly Thornhill, MD; Adam L. Wollowick, MD; Terry Amaral, MD; Alok D. Sharan, MD; Vishal Sarwahi, MD
This is a prospective study of screw misplacement as measured by postoperative computerized tomography scan (CT) in 43 pediatric patients after spinal deformity correction using pedicle screw constructs. The overall screw misplacement rate was 8.9%. Larger curves, larger degrees of correction, and younger patients demonstrated significantly higher rates of misplacement.

Consideration of Vertebral Rotation Improves the Accuracy of Pedicle Screw Placement: A Prospective Study Using Post-Operative CT Scans

Ashish Khurana; Abhijit Guha, MBBS, MS(Orth), FRCS; A. Jones, FRCS(orth); J. Howes; P. Davies; S. Ahuja;
Previously, we defined a relationship between the Nash-Moe rotation grade on supine and standing radiographs and the actual degree of rotation as determined using axial CT scans. We utilized this information intra-operatively to assist in pedicle screw placement and prospectively assessed the incidence of misplacement. As a result, our incidence of malaligned pedicle screws decreased significantly from 10% to 4%.

Disfunctional Uterine Bleeding Following Scoliosis Correction Surgery

Christopher J. Dare; James W. Douglas, MBBS, B.Sc., MRCS; Evan M. Davies, BM;

We evaluate the association of scoliosis correction surgery with altered menstrual bleeding in the immediate post operative period.

Trauma

The Effect of Prophylactic Use of Heparin in Acute Cervical Spinal Cord Injury

Rolando F. Roberto, MD; Braden Boice, B.S.; Hosun Hwang, MD; Andrew Skalsky, MD

Heparin administration may be beneficial following a mild cervical spinal cord injury with no detrimental effect following moderate or severe cord injury.

Double Rod Anterior Reconstruction in Tumour, Fracture, Infection: Unique Use of Non-Linked Standard Spinal Implants

Anand Agarwal, MD; Alan Hammer

We present a retrospective follow-up study demonstrating the safety and efficacy of an independently constructed non-linked double rod system for anterior column reconstruction.

Kyphoplasty with Calcium Phosphate and Short Minimal Invasive Fixation for Fresh Burst and Severe Compression Lumbar Fractures

Richard W. Woods; Christopher Straight; Michael Barrus; Oheneba Boachie-Adjei, MD; John Kostuik

Objective of this prospective study was to evaluate the efficacy of minimal invasive surgery for acute lumbar fractures by means of balloon kyphoplasty with Calcium phosphate plus segmental short posterior instrumented fusion. Eighteen consecutive patients were included and followed for an average 22 months after index surgery. Posterolateral radiological fusion was achieved within 6-8 months after index operation. There was no instrumentation failure or loss of sagittal curve and vertebral height correction.

Less-Invasive Treatment of Unstable Thoracolumbar Burst Fractures With and Without Neurologic Deficits: Is Corpectomy Still Warranted?

Per Wessberg; Barbro I. Danielsson, MD, PhD; Jan Willen, MD, PhD

Unstable burst fractures with and without neurologic deficits were decompressed and circumferentially stabilized using posterior instrumentation and anterior column reconstruction with calcium phosphate cement through a posterior incision. The need for corpectomy was eliminated, which decreased surgical trauma and operative time. Near-anatomic reduction and circumferential reconstruction decreased the incidence of instrumentation failure associated with posterior instrumentation alone. Decompression of the thecal sac allowed all patients to maintain or regain neurologic function.

Coccygectomy With or Without Periosteum Preservation

Anand Agarwal, MD; Robert Pflugmacher; Alan Hammer

Surgery may be indicated for coccydynia in patients who have severe persistent pain. The purpose of our study was evaluate the results of coccygectomy in patients with persistent coccydynia and to determine whether the periosteal closure has an effect on the outcome. Surgery was performed in 25 patients who had traumatic coccydynia and who did not respond to conservative treatment after at least six months. In 11 patients, resection of all mobile coccygeal and/or sacrococcygeal segments including the periosteum were removed. Resection was performed subperiostally sparing the periosteum in the other 14 patients. We showed that periosteal closure provides a better outcome concerning patients' satisfaction and postoperative complications.

Burst Fracture of the Lumbar Vertebrae due to a Landmine Injury

Tokumi Kanemura, MD; Go Yoshida; Masashi Kawasaki; Noriaki Kawakami, MD; Yukiharu Hasegawa

In this report, we present a military member who had suffered from an L2 vertebra burst fracture along with right below knee and left above knee traumatic amputations, multiple skin lacerations and a large left forearm skin injury. To the best knowledge of the authors, this is the first report of a vertebral fracture after a landmine injury and we therefore draw attention of medical staff towards such a clinical condition.

Clinical Relevance of the "Reverse Cortical" or "Pseudo Reverse Cortical" Sign in Thoracolumbar Burst Fracture

Laury Cuddihy; Terry Amaral, MD; Adam L. Wollowick, MD; Alok D. Sharan, MD; Vishal Sarwahi, MD

Discriminate the "pseudo-reverse cortical" from the true "reverse cortical sign" when evaluating canal compromise in burst fractures. Such distinction will help to differentiate burst fractures that can respond to posterior ligamentotaxis from others where ligamentotaxis remain a contraindication.

Low Lumbar Burst Fractures: A Unique Fracture Mechanism Sustained in Our Current Overseas Conflicts

Prof. Arvind Jayaswal, MS; Bidre Upendra, MS; Ajay Kumar, MS; Abrar Ahmed; Anand Agarwal, MD; Buddha Chowdhury

Low lumbar burst fractures have an increased incidence and are more common than thoracolumbar burst fractures in the casualties returning from Iraq and Afghanistan.

Spinal Injuries Sustained in the I-35W Bridge Collapse: August 1, 2007

Vedat Deviren, MD; Murat Pekmezci; Gregory Poulter; Danielle Geula, BS, BA; Bobby Tay, MD

On August 1st, 2007, in the midst of rush hour traffic the I-35W Bridge in Minneapolis, MN, collapsed 60 feet. The two closest hospitals to the disaster treated the majority of patients – 51. Seventeen sustained spine injuries (33%). The majority were treated non-operatively. Future disaster preparation should emphasize modalities for non-operative treatment of spinal trauma (i.e. Orthotists).

Isolated Alar Ligament Disruption in Children: Cause of Persistent Torticollis and Neck Pain after Injury

Dilip K. Sengupta, MD; Aditya Ingalhalikar; Paul C. McAfee, MD
We describe isolated alar ligament disruption - an unusual cause of torticollis and neck pain after injury in children.

Severe Brachial Plexus Injuries in Rugby: Mechanisms and Management.

Paul M. Huddleston, III, MD, MS; Mark Dekutoski, MD; Neel Anand, MD; Joseph Riina; Kurt M. Eichholz, MD; Robert E. Isaacs, MD; Laurie Mihalik, CCRP; Prof. Ralf Gahr
Mechanisms of injury to the brachial plexus sustained during rugby were studied. Seven cases of injury to the brachial plexus caused by tackling underwent operation. Early repair by nerve transfer enabled some recovery in two patients. Decompression of lesions in continuity was followed by extensive recovery. The pattern of nerve lesion was found to be related to the posture of the neck and the forequarter at the moment of impact and the benefits of early decompression were clearly demonstrated.

Intradural Repair of Lumbar Nerve Roots for Traumatic Paraparesis leading to Functional Recovery

Mohammad Diab, MD; Danielle Geula, BS, BA; Brenda A. Sides, MA; Lawrence G. Lenke, MD
Lumbar nerve root injuries are often associated with a poor prognosis and are generally managed conservatively. Many patients suffer loss of function, sometimes together with classic burning dysesthesia and causalgia, for which management is difficult. We describe the outcomes of the surgical repair of traumatic lacerations of lumbar nerve roots.

Evaluation of the Effectiveness of a New Classification System for Lower Cervical Spinal Injuries

Reginald S. Fayssoux, MD; Amer F. Samdani, MD; JahanGir Asghar, MD; Randal R. Betz, MD; Mary Jane Mulcahey
The recently proposed SCISS (subaxial cervical injury severity score) by Moore and Vaccaro has been shown to have excellent intra- and inter-observer reliability. In addition to adding reliability data from our own institution, we assess the teachability of this classification system to orthopedic surgery residents at various levels of training. Our data indicates that this system is easily teachable and reproducible at all levels of residency training and furthermore is an effective predictor of treatment.

Traumatic Spondylolisthesis of L5-S1 with Cauda Equina Syndrome

Stephen Lewis, MD, FRCSC, MSc; Tomoaki Kitagawa; Raja Rampersaud, MD, FRCSC; Marcus Timlin, FRCS(TR&Orth)
In this case we treated by open reduction and fusion L5-S1 successfully, and completed neurologic recovery and no limitation of daily activity

Fracture-Dislocation of the Cervical Spine in a Newborn. A Case Report

Terry Amaral, MD; Laury Cuddihy; Beverly Thornhill, MD; Adam L. Wollowick, MD; Alok D. Sharan, MD; Vishal Sarwahi, MD
Showed a case of fracture dislocation in cervical spine with survival

Halo Rings with Vests in Cervical Spine Trauma: Success and Causes of Failure

Stephen Lewis, MD, FRCSC, MSc; Sarah A. Bacon, completing BScH; Reinhard Zeller, MD, FRCSC, ScD; Ron El-Hawary, MD, MSc, FRCS(C); Peter Jarzem
Halo vest immobilization is an effective treatment option in the management of cervical spine trauma and most will complete the anticipated prescribed time-frame.

Posterior Closing Modified Wedge Osteotomy Procedures in Patients with Posttraumatic Thoracolumbar Kyphosis

Chitra L. Dahia, PhD; Eric Mahoney; A. Atiq Durrani, MD; Prof. Christopher Wylie
To evaluate the outcome of posterior closing modified wedge osteotomy procedures in patients with posttraumatic thoracolumbar kyphosis.

Sacral Kyphosis as a Cause of Sacral Nerve Impingement in Lumbosacral Dissociations

Kit Song; Klane K. White, MD, MSc.; Jefferson Slimp; Nathalia Jimenez, MD, MPH; Anthony Avellino; Daniel Emerson, M.D; Adam Bergeson, MD; Scott M. Skjei;
High energy lumbopelvic dissociations must be evaluated for sacral kyphosis with consideration given for operative fixation. In our case series, two patients treated nonoperatively with greater than 20 degrees of kyphosis progressed, while no patients treated with sacroiliac screw fixation or posterior spinal fusion progressed.

Pediatric Subaxial Cervical Spine Fractures Treated with Anterior Fusion and Instrumentation.

Chitra L. Dahia, PhD; Eric Mahoney; A. Atiq Durrani, MD; Prof. Christopher Wylie
Cervical spine fractures are uncommon in pediatric patients. A retrospective review of nine pediatric patients with subaxial cervical spine fractures treated with anterior fusion/instrumentation was conducted. Seven underwent discectomy and fusion and two required corpectomy, plating and fusion. Mean preoperative kyphosis was 16.4. At followup mean kyphosis was 1.2 degrees and all were fused. Anterior instrumentation and fusion can be considered for stabilization of pediatric subaxial cervical spine fractures. Kyphosis is reliably corrected and maintained, and complication rate appears low.

Retrospective Review of Lumbosacral Dissociation Injuries in High Energy Blast Injuries

Stephen Lewis, MD, FRCSC, MSc; Subir Jhaveri; Shaf Keshavjee; Gail Darling; Stefan Parent, MD, PhD

We have seen an increased incidence of lumbopelvic dissociations in patients sustaining high energy, combat-related traumatic injuries. While the treatment of this complex injury has varied, patients at high perioperative risk have been adequately treated with percutaneous sacroiliac screw fixation in our series.

Minimally Invasive Pedicle Screw Fixation with using Standard Instruments Designed for the Open Approach

Chitra L. Dahia, PhD; Eric Mahoney; A. Atiq Durrani, MD; Prof. Christopher Wylie

To evaluate outcome and potential advantages of a percutaneous posterior approach to vertebra fractures with conventional pedicle screws. One superior and one inferior vertebrae (at one patient 2 below 2 above) were stabilized with pedicle screws used transmuscularly from nearly 2 cm incision, and rods were inserted into the screws from end incision. using standard instruments is feasible and safe for posterior stabilization of the thoraco lumbar spine. Also has economical advantage.

Neurological Examination and Classification of Spinal Cord Injury: Reliability in Children and Youth

Dirk Leu, MD; Paul D. Sponseller, MD; Jeff B. Pawelek, BS; Peter O. Newton, MD

Clinicians should apply the International Standards of Neurological Classification of Spinal Cord Injury (ISCSCI) as the standard neurological evaluation of children over age 5, as it has shown very good utility in this study.

Cerebrospinal Fluid Drainage and Pressure Monitoring after Acute Human Spinal Cord Injury

Stephen Lewis, MD, FRCSC, MSc; Sarah A. Bacon, completing BScH; Omprakash Sharma; Douglas Hedden, MD, FRCSC

A prospective randomized trial was conducted to evaluate the drainage of cerebrospinal fluid (CSF) to reduce intrathecal pressure and improve cord perfusion pressure after acute spinal cord injuries. 20 patients were randomized to drainage vs no drainage. No serious adverse events were noted. Cord perfusion pressure was not significantly altered by drainage. CSF pressures unexpectedly increased significantly after spinal decompression and in the early post-operative period, indicating that the mean arterial pressure does not accurately reflect cord perfusion pressure post-operatively.

Ballon Kyphoplasty in the Treatment of High Velocity Vertebral Wedge Compression Fractures-Prospective Trial 3 Years Follow Up

Baron S. Lonner, MD; Joshua D. Auerbach, MD; Paul D. Sponseller, MD; Michael O'Brien, MD; Peter O. Newton, MD

Our study shows Ballon kyphoplasty is helpful in the treatment and stabilisation of anterior defect of acute high velocity fractures of the spine

Children with Chronic Spinal Cord Injury: Does MRI Correlate with the International Standards for Neurologic Classification of Spinal Cord Injury?

Michael D. Daubs, MD; Alpesh Patel, MD; Darrel S. Brodke, MD;

Although adequate relationships between the standardized exam for persons with SCI (ISCSCI) and MRI were found in children with SCI over 8 years old, only fair relationships were identified in those under 8. These results call into question the ability of the ISCSCI to properly classify young children, a critical requirement for appropriate placement into clinical trials. These findings support the need for the development of a reliable method of classifying neurological injury in young children with SCI.

Tumors

Recurrence in Surgically Managed Patients of Giant Cell Tumor of the Spine

Melanie A. Gambassi, Pediatric Nurse Practitioner; Alok D. Sharan, MD; Terry Amaral, MD; Adam L. Wollowick, MD; Vishal Sarwahi, MD

To study the recurrence rates in surgically managed patients of Giant cell tumor of the spine.

Pathological Fracture of Thoracic Spine with Cord Compression from Angiosarcoma

Warren D. Yu, MD; David Goodwin, BA; Joseph R. O'Brien, MD, MPH;

Angiosarcoma is very rare tumor, most of them came from heart. there are few report on spine

Aneurysmal Bone Cyst of the Lumbar 1 Vertebra: A Case Presentation

Baron S. Lonner, MD; Suken A. Shah, MD; Tracey P. Bastrom, MA; Joshua D. Auerbach, MD; Paul D. Sponseller, MD; Michael O'Brien, MD; Peter O. Newton, MD

With severe back an groin pain and neurologic deficit in young adults, bony tumors around the neural arch should be considered. Not only vertebral lesions it can be misdiagnosed like an abdominal or groin pathology. 23 years old male patient had severe back and groin pain nearly one year. Because of this symptoms it was decided an inguinal herni and underwent an operation in another medical center.

A Prospective Analysis of Prognostic Factors in the Patients with Spinal Metastases –Use of the Revised Tokuhashi Score

James Bennet

All patients diagnosed with any form of spinal metastases were enrolled to this study. This was a prospective non-intervention observational study. The relation between the revised Tokuhashi score and survival was investigated. Severe cancer type, the existence of major organ metastases, and less total revised Tokuhashi score demonstrated less survival in the patients with spinal metastases. Lung cancer and metastases to lung were also related to less survival.



Posterior Column Reconstruction with Autologous Rib Graft Following en-bloc Tumour Excision

*Anthony A. Scaduto, MD; Kimberley K. Caputo; Bryan J. Correa,
BS; Richard E. Bowen, MD*

Large defects encompassing 2-5 vertebral levels are created following en-bloc tumor resections. We describe a technique of posterior column reconstruction using autologous rib graft after en-bloc tumor resection of spinal tumors. 10 males and 3 females with a mean age of 57 years (27-75) underwent this procedure. Serial CT scan demonstrated fusion in all cases surviving beyond six months. The ability of obtaining fusion across large defects may prevent instrumentation failure in patients undergoing potentially curative resections

ABOUT SRS



SCOLIOSIS RESEARCH SOCIETY



Scoliosis Research Society Mission Statement

The purpose of Scoliosis Research Society is to foster the optimal care of all patients with spinal deformities.

Goals and Aspirations of the Scoliosis Research Society

The Scoliosis Research Society is composed of physicians and scientists who, prior to becoming members, have concentrated on the problems of spinal deformities and who, as members, make a continuing commitment to solve the problems of spinal deformity, to participate in research and to contribute toward the Society's educational and service efforts. The business of the Scoliosis Research Society is knowledge. The Society is concerned with the development of new knowledge, the continuing education of its members, and the communication of knowledge to others. Because knowledge brings responsibility, members are committed to the highest standards of ethical practice and professional service to the Society and the community.

Research, education and care of patients are the central activities through which members channel their expertise. It is expected that members will be active to some extent in each of these areas, but with different emphasis based on individual interests and talents.

Research

It is not by accident that the word "research" occupies a central place in the name of our Society. The members of the Society are committed to research in spinal deformities.

All members participate in some research activity which leads to increased knowledge. The one Society-sponsored research project in which every member can participate is the Morbidity and Mortality Report. This project has produced more useful information for the Society than any other single research program.

Other means of participation in research include individual basic scientific or clinical studies, inter-institutional studies or Society-sponsored projects. In all forms of research, members strive for objectivity and meticulous honesty.

Education of Members

New data and new techniques evolve rapidly in the medical and surgical care of spinal disorders. The members of the Scoliosis Research Society take responsibility for their own continuing medical education. In addition, the Society provides structured educational experiences through printed material, courses and the Annual Meeting. These educational efforts are focused on the members of the Society, who already possess a high degree of expertise, and their value depends on the member's willingness to participate. Members contribute to the education of others by reporting on cases from their own practices in the open forum of the Annual Meeting.

Education of Residents and Fellows

We believe that the possession of specialized knowledge and expertise carries with it the responsibility to transmit this to others. The members of the Society, collectively and individually, will participate in the design and structuring of residency and fellowship programs. We expect Society members to be active in AAOS and comparable educational programs in spinal deformities for orthopaedists.

Public Education

The Scoliosis Research Society recognizes a responsibility to public education and the need for effective liaison with lay organizations dedicated to some aspect of the prevention and treatment of spinal deformities. We believe that we have a responsibility to be the leading resource for information and encouragement to these groups.

The Society has dedicated time and resources to the development of educational programs for the public. We expect members to support and participate locally in those programs with which the Society cooperates.

Ethical Practice

The members of the Scoliosis Research Society are dedicated to the highest standards of ethical practice. Members strive to:


1. Develop thoughtful diagnoses and treatment plans based on common sense, scientific principles and data.
2. Recognize personal, technical and cognitive limitations.
3. Charge fair and appropriate fees for the services performed and assist in providing health care to all members of the community.
4. Distinguish appropriate alternative treatment plans from ill conceived ones when giving opinions and not disparage physicians who recommend other acceptable treatments.
5. Recognize that the assessment of evolving technology is difficult and therefore maintain a degree of caution about new techniques, using these to improve patient care rather than to gain a competitive advantage.

Acknowledging Support

The Society as a whole and individual members have benefited from the generous support of private and corporate sponsors. We will give full acknowledgment for this support without concern that such recognition of assistance may be misinterpreted.



- | | | |
|---|---|--|
| 1. William J. Kane, M.D., Minneapolis, MN | 13. Anthony J. Bianco, Jr., M.D., Rochester, MN | 25. George Cottrell, M.D., Portland, OR |
| 2. David B. Levine, M.D., New York, NY | 14. C. McCollister Everts, M.D., Rochester, NY | 26. Ronald L. DeWald, M.D., Chicago, IL |
| 3. William F. Donaldson, M.D., Pittsburgh, PA | 15. Robert Kaiser, M.D., Carol Gables, FL | 27. Joseph D. Godfrey, M.D., Buffalo, NY |
| 4. Jacquelin Perry, M.D., Downey, CA | 16. Charles Hollenberg, M.D., Winnipeg, Canada | 28. James W. Tupper, M.D., Seattle, WA |
| 5. John H. Moe, M.D., Minneapolis, MN | 17. Allan M. McKelvie, M.D., Washington, D.C. | 29. Gordon Armstrong, M.D., Ottawa, Canada |
| 6. John E. Hall, M.D., Toronto, Canada | 18. Walter P. Blount, M.D., Milwaukee, WI | 30. Robert B. Winter, M.D., Minneapolis, MN |
| 7. Louis A. Goldstein, M.D., Rochester, NY | 19. Marr P. Mullen, M.D., Seattle, WA | 31. Loren J. Larsen, M.D., San Francisco, CA |
| 8. Paul R. Harrington, M.D., Houston, TX | 20. G. Dean MacEwen, M.D., Wilmington, DE | 32. Edward J. Riseborough, M.D., Boston, MA |
| 9. Frank Wilson, M.D., Vancouver, BC, Canada | 21. Richard M. Kilfoyle, M.D., South Weymouth, MA | 33. James E. Holmblad, M.D., Schenectady, NY |
| 10. Albert C. Schmidt, M.D., Milwaukee, WI | 22. Warren G. Stamp, M.D., Charlottesville, VA | 34. L. Ray Lawson, M.D., Dallas, TX |
| 11. Frank H. Stelling III, M.D., Greenville, SC | 23. John H. Doherty, M.D., New York, NY | 35. Lawrence Noall, M.D., Portland, OR |
| 12. Daniel Riordan, M.D., New Orleans, LA | 24. Allen S. Edmonson, M.D., Memphis, TN | |



SRS Past Presidents

Year(s) Served

1 G. Dean MacEwen 1971-72	13 Clyde Lester Nash, Jr., 1983	25 Edward H. Simmons 1976
2 Harry L. Shufflebarger .. 2000	14 John P. Kostuik 1987	26 William J.Kane 1980
3 Vernon T. Tolo 1996	15 John H. Moe 1966-68	27 Gordon W.D. Armstrong 1981
4 John E. Lonstein 1991	16 Daniel R. Benson 1992	28 Alvin H. Crawford 2001
5 Theodore R. Waugh 1982	17 Allen S. Edmonson 1985	29 Edgar G. Dawson 1995
6 Robert N. Hensiger 1989	18 David S. Bradford 1984	30 Jessie H. Dickson 1990
7 James W. Ogilvie 2004	19 Kenton D. Leatherman .. 1975	31 John Carlisle Brown 1993
8 Randal R. Betz 2005	20 Denis S. Drummond 2002	32 John E. Hall 1960-70
9 Paul R. Harrington 1973	21 Ronald L. DeWald 1988	33 R.Kirclin Ashley 1977-78
10 Behrooz A. Akbarnia 2006	22 Robert B. Winter 1974	34 Donald P.K. Chan 1998
11 Gordon L. Engler 1994	23 Marc A. Asher 1997	35 Courtney W. Brown 1999
12 Wilton H. Bunch 1986	24 Keith H. Bridwell 2003	36 David B. Levine 1979



1ST Annual Meeting

October 2-4, 1966 – Minneapolis, MN, USA

President	John H. Moe
Secretary-Treasurer	William J. Kane
Directors	William F. Donaldson Louis A. Goldstein John E. Hall Paul R. Harrington David B. Levine Jacquelin Perry

2nd Annual Meeting

1967 – Minneapolis, MN, USA

President	John H. Moe
President-Elect	John E. Hall
Secretary-Treasurer	William J. Kane
Directors	William F. Donaldson Louis A. Goldstein Paul R. Harrington David B. Levine Jacquelin Perry

3rd Annual Meeting

1968 – Houston, TX, USA

President	John H. Moe
President-Elect	John E. Hall
Secretary-Treasurer	William J. Kane
Directors	William F. Donaldson Louis A. Goldstein Paul R. Harrington David B. Levine Jacquelin Perry

4th Annual Meeting

Sept. 4-6, 1969 – Anaheim, CA, USA

President	John E. Hall
President-Elect	G. Dean MacEwen
Secretary-Treasurer	William J. Kane
Past President	John H. Moe
Directors	Allen S. Edmonson Richard M. Kilfoyle Jacquelin Perry James W. Tupper

5th Annual Meeting

Sept. 10-12, 1970 – Toronto, ON, CANADA

President	John E. Hall
President-Elect	G. Dean MacEwen
Secretary-Treasurer	William J. Kane
Sec.-Treas.-Elect	David B. Levine
Past President	John H. Moe
Directors	Robert P. Keiser Theodore R. Waugh, Jr. Robert C. Zuege

6th Annual Meeting

Sept. 8-10, 1971 – Hartford, CT, USA

President	G. Dean MacEwen
President-Elect	Paul R. Harrington
Secretary-Treasurer	David B. Levine
Past President	John E. Hall
Directors	Charles H. Herndon John C. Kennedy John H. Moe Frank C. Wilson, Jr.

7th Annual Meeting

1972 – Wilmington, DE, USA

President	G. Dean MacEwen
President-Elect	Paul R. Harrington
Secretary-Treasurer	David B. Levine
Treasurer-Elect	James H. Hardy
Past President	John E. Hall
Directors	Kenton D. Leatherman Lawrence Noall Albert C. Schmidt

8th Annual Meeting

1973 – Gothenburg, SWEDEN

President	Paul R. Harrington
President-Elect	Robert B. Winter
Secretary	David B. Levine
Treasurer	James H. Hardy
Past President	G. Dean MacEwen
Directors	Gordon W.D. Armstrong Kenton D. Leatherman Lawrence Noall

9th Annual Meeting

Sept. 11-13, 1974 – San Francisco, CA, USA

President	Robert B. Winter
President-Elect	Kenton D. Leatherman
Secretary	David B. Levine
Secretary-Elect	Theodore R. Waugh, Jr.
Treasurer	James H. Hardy
Past President	Paul R. Harrington
Directors	Gordon W.D. Armstrong R. Kirklin Ashley Wilton H. Bunch

10th Annual Meeting

Sept 10-12, 1975 – Louisville, KY, USA

President	Kenton D. Leatherman
President-Elect	Edward H. Simmons
Secretary	Theodore R. Waugh, Jr.
Treasurer	James H. Hardy
Past President	Robert B. Winter
Directors	R. Kirklin Ashley Wilton H. Bunch Ronald L. DeWald



11th Annual Meeting

Sept. 4-6, 1976 – Ottawa, ON, CANADA

President	Edward H. Simmons
President-Elect	Louis A. Goldstein
Secretary	Theodore R. Waugh, Jr.
Treasurer	James H. Hardy
Treasurer-Elect	Wilton H. Bunch
Past President	Kenton D. Leatherman
Directors	Ronald L. DeWald Robert B. Winter

12th Annual Meeting

Oct. 24-27, 1977 – HONG KONG

President	R. Kirklin Ashley
President (9/76-10/76)	Louis A. Goldstein
Secretary	Theodore R. Waugh, Jr.
Treasurer	Wilton H. Bunch
Past President	Edward H. Simmons
Directors	Jesse H. Dickson Kenton D. Leatherman Marr P. Mullen

13th Annual Meeting

Sept. 13-15, 1978 – Boston, MA, USA

President	R. Kirklin Ashley
President-Elect	David B. Levine
Secretary	Theodore R. Waugh, Jr.
Secretary-Elect	Allen S. Edmonson
Treasurer	Wilton H. Bunch
Past President	Edward H. Simmons
Directors	Marr P. Mullen Clyde L. Nash, Jr.

14th Annual Meeting

Sept. 11-14, 1979 – Seattle, WA, USA

President	David B. Levine
President-Elect	William J. Kane
Secretary	Allen S. Edmonson
Treasurer	Wilton H. Bunch
Past President	R. Kirklin Ashley
Directors	James E. Holmblad Donald A. Jones S. Henry LaRocca Clyde L. Nash, Jr.

15th Annual Meeting

Sept. 17-19, 1980 – Chicago, IL, USA

President	William J. Kane
President-Elect	Gordon W.D. Armstrong
Secretary	Allen S. Edmonson
Treasurer	Wilton H. Bunch
Treasurer-Elect	John C. Brown
Past President	David B. Levine
Directors	James E. Holmblad Donald A. Jones

16th Annual Meeting

Sept. 16-18, 1981 – Montreal, QC, CANADA

President	Gordon W.D. Armstrong
President-Elect	Theodore R. Waugh, Jr.
Secretary	Allen S. Edmonson
Treasurer	John C. Brown
Past President	William J. Kane
Directors	James E. Holmblad Gordon L. Engler David S. Bradford

17th Annual Meeting

Sept. 22-25, 1982 – Denver, CO, USA

President	Theodore R. Waugh, Jr.
President-Elect	Clyde L. Nash, Jr.
Secretary	Allen S. Edmonson
Secretary-Elect	Robert N. Hensinger
Treasurer	John C. Brown
Past President	Gordon W.D. Armstrong
Directors	Gordon L. Engler David S. Bradford Morris A. Duhaime Harold K. Dunn

18th Annual Meeting

Sept. 28-Oct. 1, 1983 – New Orleans, LA, USA

President	Clyde L. Nash, Jr.
President-Elect	David S. Bradford
Secretary	Robert N. Hensinger
Treasurer	John C. Brown
Past President	Theodore R. Waugh, Jr.
Directors	Morris A. Duhaime Harold K. Dunn Edgar G. Dawson John P. Kostuik

19th Annual Meeting

Sept. 19-22, 1984 – Orlando, FL, USA

President	David S. Bradford
President-Elect	Allen S. Edmonson
Secretary	Robert N. Hensinger
Treasurer	John C. Brown
Treasurer-Elect	Gordon L. Engler
Past President	Clyde L. Nash, Jr.
Directors	Edgar G. Dawson John P. Kostuik Thomas I. Lowry



20th Annual Meeting

Sept. 17-20, 1985 – San Diego, CA, USA

President	Allen S. Edmonson
President-Elect	Wilton H. Bunch
Secretary	Robert N. Hensinger
Treasurer	Gordon L. Engler
Past President	David S. Bradford
Directors	Thomas I. Lowry Marc A. Asher L. Ray Lawson Albert B. Schultz

21st Annual Meeting

Sept. 21-25, 1986 – Hamilton, BERMUDA

President	Wilton H. Bunch
President-Elect	John P. Kostuik
Secretary	Robert N. Hensinger
Secretary-Elect	William P. Bunnell
Treasurer	Gordon L. Engler
Past President	Allen S. Edmonson
Directors	Marc A. Asher L. Ray Lawson Robert Gillespie John E. Lonstein

22nd Annual Meeting

Sept. 15-19, 1987 – Vancouver, BC, CANADA

President	John P. Kostuik
President-Elect	Ronald L. DeWald
Secretary	William P. Bunnell
Treasurer	Gordon L. Engler
Past President	Wilton H. Bunch
Directors	Robert Gillespie Rae R. Jacobs John E. Lonstein Stuart L. Weinstein

23rd Annual Meeting

Sept. 21-25, 1988 – Baltimore, MD, USA

President	Ronald L. DeWald
President-Elect	Robert N. Hensinger
Secretary	William P. Bunnell
Treasurer	Gordon L. Engler
Treasurer-Elect	Edgar G. Dawson
Past President	John P. Kostuik
Directors	Ralph W. Coonrad Denis S. Drummond Rae R. Jacobs Stuart L. Weinstein

24th Annual Meeting

Sept. 17-22, 1989 – Amsterdam, NETHERLANDS

President	Robert N. Hensinger
President-Elect	Jesse H. Dickson
First Vice President	John E. Lonstein
Secretary	William P. Bunnell
Treasurer	Edgar G. Dawson
Past President	Ronald L. DeWald
Directors	Daniel R. Benson Ralph W. Coonrad Denis S. Drummond Thomas S. Renshaw

25th Annual Meeting

Sept. 23-27, 1990 – Honolulu, HI, USA

President	Jesse H. Dickson
President-Elect	John E. Lonstein
First Vice President	Daniel R. Benson
Secretary	William P. Bunnell
Secretary-Elect	Vernon T. Tolo
Treasurer	Edgar G. Dawson
Past President	Robert N. Hensinger
Directors	Robert W. Gaines, Jr. Thomas S. Renshaw Susan M. Swank Stephen J. Tredwell

26th Annual Meeting

Sept. 24-27, 1991 – Minneapolis, MN, USA

President	John E. Lonstein
President-Elect	Daniel R. Benson
First Vice President	John C. Brown
Secretary	Vernon T. Tolo
Treasurer	Edgar G. Dawson
Past President	Jesse H. Dickson
Directors	Alvin H. Crawford Robert W. Gaines, Jr. Stanley D. Gertzbein Stephen J. Tredwell

27th Annual Meeting

Sept. 23-26, 1992 – Kansas City, MO, USA

President	Daniel R. Benson
President-Elect	John C. Brown
First Vice President	Gordon L. Engler
Secretary	Vernon T. Tolo
Treasurer	Edgar G. Dawson
Treasurer-Elect	Courtney W. Brown
Past President	John E. Lonstein
Directors	Alvin H. Crawford Stanley D. Gertzbein Donald P.K. Chan Susan W. Swank



28th Annual Meeting

Sept. 18-23, 1993 – Dublin, IRELAND

President	John C. Brown
President-Elect	Gordon L. Engler
First Vice President	Edgar G. Dawson
Past President	Daniel R. Benson
Secretary	Vernon T. Tolo
Treasurer	Courtney W. Brown
Directors	Donald P.K. Chan Susan W. Swank Behrooz A. Akbarnia John A. Herring

29th Annual Meeting

Sept. 21-24, 1994 – Portland, OR, USA

President	Gordon L. Engler
President-Elect	Edgar G. Dawson
First Vice President	Vernon T. Tolo
Past President	John C. Brown
Secretary	Harry L. Shufflebarger
Treasurer	Courtney W. Brown
Directors	Behrooz A. Akbarnia John A. Herring William A. Carr Dennis R. Wenger

30th Annual Meeting

Sept. 13-16, 1995 – Asheville, NC, USA

President	Edgar G. Dawson
President-Elect	Vernon T. Tolo
First Vice President	Marc A. Asher
Past President	Gordon L. Engler
Secretary	Harry L. Shufflebarger
Treasurer	Courtney W. Brown
Directors	William A. Carr Dennis R. Wenger Thomas F. Kling, Jr. Jack K. Mayfield

31st Annual Meeting

Sept. 25-28, 1996 – Ottawa, ON, CANADA

President	Vernon T. Tolo
President-Elect	Marc A. Asher
First Vice President	Donald P.K. Chan
Past President	Edgar G. Dawson
Secretary	Harry L. Shufflebarger
Treasurer	Courtney W. Brown
Treasurer-Elect	William A. Carr
Directors	Thomas F. Kling, Jr. Jack K. Mayfield Keith H. Bridwell Thomas R. Haher

32nd Annual Meeting

Sept. 25-27, 1997 – St. Louis, MO, USA

President	Marc A. Asher
President-Elect	Donald P.K. Chan
First Vice President	Courtney W. Brown
Past President	Vernon T. Tolo
Secretary	Harry L. Shufflebarger
Secretary-Elect	Denis S. Drummond
Treasurer	William A. Carr
Directors	Keith H. Bridwell Thomas R. Haher R. Mervyn Letts Michael G. Neuwirth

33rd Annual Meeting

Sept. 16-20, 1998 – New York, NY, USA

President	Donald P.K. Chan
President-Elect	Courtney W. Brown
First Vice President	Harry L. Shufflebarger
Past President	Marc A. Asher
Secretary	Denis S. Drummond
Treasurer	William A. Carr
Directors	R. Mervyn Letts Michael G. Neuwirth John B. Emans James W. Ogilvie

34th Annual Meeting

Sept. 23-25, 1999 – San Diego, CA, USA

President	Courtney W. Brown
President-Elect	Harry L. Shufflebarger
First Vice President	Alvin H. Crawford
Past President	Donald P.K. Chan
Secretary	Denis S. Drummond
Treasurer	William A. Carr
Directors	John B. Emans James W. Ogilvie John V. Banta Thomas G. Lowe

35th Annual Meeting

Oct. 18-21, 2000 – Cairns, AUSTRALIA

President	Harry L. Shufflebarger
President-Elect	Alvin H. Crawford
First Vice President	Denis S. Drummond
Past President	Courtney W. Brown
Secretary	John B. Emans
Treasurer	William A. Carr
Treasurer-Elect	Behrooz A. Akbarnia
Directors	John V. Banta Thomas G. Lowe John P. Lubicky George H. Thompson



36th Annual Meeting

Sept. 19-22, 2001 – Cleveland, OH, USA

President	Alvin H. Crawford
President-Elect	Denis S. Drummond
First Vice President	Keith H. Bridwell
Past President	Harry L. Shufflebarger
Secretary	John B. Emans
Treasurer	Behrooz A. Akbarnia
Directors	John P. Lubicky George H. Thompson Stewart I. Bailey Thomas S. Whitecloud, III

37th Annual Meeting

Sept. 18-21, 2002 – Seattle, WA, USA

President	Denis S. Drummond
President-Elect	Keith H. Bridwell
First Vice President	James W. Ogilvie
Past President	Alvin H. Crawford
Secretary	John B. Emans
Treasurer	Behrooz A. Akbarnia
Directors	Stewart I. Bailey Thomas S. Whitecloud, III Randal R. Betz Howard A. King

38th Annual Meeting

Sept. 10-13, 2003 – Quebec City, CANADA

President	Keith H. Bridwell
President-Elect	James W. Ogilvie
First Vice President	Randal R. Betz
Past President	Denis S. Drummond
Secretary	John B. Emans
Secretary-Elect	Thomas R. Haher
Treasurer	Behrooz A. Akbarnia
Treasurer-Elect	Richard E. McCarthy
Directors	Howard A. King Hubert H.L. Labelle John P. Dormans David W. Polly, Jr.

39th Annual Meeting

Sept. 6-9, 2004 – Buenos Aires, ARGENTINA

President	James W. Ogilvie
President-Elect	Randal R. Betz
First Vice President	Behrooz A. Akbarnia
Past President	Keith H. Bridwell
Secretary	Thomas R. Haher
Treasurer	Richard E. McCarthy
Directors	John P. Dormans David W. Polly Oheneba Boachie-Adjei Michael A. Edgar

40th Annual Meeting

Oct. 27-30, 2005 – Miami, FL, USA

President	Randal R. Betz
President-Elect	Behrooz A. Akbarnia
Vice President	George H. Thompson
Past President	James W. Ogilvie
Secretary	Thomas R. Haher
Treasurer	Richard E. McCarthy
Directors	Oheneba Boachie-Adjei Michael A. Edgar Steven M. Mardjetko Mark Weidenbaum

41st Annual Meeting

Sept. 13-16, 2006 – Monterey, CA, USA

President	Behrooz A. Akbarnia
President-Elect	George H. Thompson
Vice President	Thomas G. Lowe
Secretary	Thomas R. Haher
Treasurer	Richard E. McCarthy
Past President	Randal R. Betz
Past President	James W. Ogilvie
Past President	Keith H. Bridwell
Director	Steven M. Mardjetko
Director	Mark Weidenbaum
Director	Paul D. Sponseller
Director	Nobumasa Suzuki

42nd Annual Meeting

Sept. 5-8, 2007 – Edinburgh, SCOTLAND

President	George H. Thompson
President-Elect	Oheneba Boachie-Adjei
Vice President	Richard E. McCarthy
Secretary	Thomas R. Haher
Treasurer	Steven M. Mardjetko
Secretary-Elect	David W. Polly, Jr.
Past President	Behrooz A. Akbarnia
Past President	Randal R. Betz
Past President	James W. Ogilvie
Director	Paul D. Sponseller
Director	Nobumasa Suzuki
Director	Lawrence G. Lenke
Director	B. Stephens Richards



BOARD OF DIRECTORS

George H. Thompson, President.....	2008
Oheneba Boachie-Adjei, President-Elect.....	2008
Richard E. McCarthy, Vice President.....	2008
David W. Polly, Jr., Secretary.....	2008
Steven M. Mardjetko, Treasurer.....	2008
Behrooz A. Akbarnia, Past President.....	2010
Randal R. Betz, Past President.....	2009
James W. Ogilvie, Past President.....	2008
Lawrence G. Lenke, Director.....	2008
B. Stephens Richards, Director.....	2008
Azmi Hamzaoglu, Director.....	2009
James W. Roach, Director.....	2009
John P. Dormans, Education Council Chair.....	2008
Peter O. Newton, Research Council Chair.....	2010

ADULT DEFORMITY COMMITTEE

Standing Committee – 2 per year, with 4 year terms

William C. Horton, Chair.....	2008
Keith H. Bridwell, Past Chair.....	2008
Kirkham B. Wood.....	2008
David F. Antezana (C).....	2008
Ronald A. Lehman (C).....	2008
Mark Weidenbaum, Chair Elect.....	2009
Frank J. Schwab.....	2010
Christopher I. Shaffrey.....	2010
Sigurd H. Berven.....	2011
Clifford B. Tribus.....	2011

Council: Research

Board Liaison: Oheneba Boachie-Adjei

Staff Liaison: Megan Kelley

ADVOCACY AND PUBLIC POLICY COMMITTEE

Standing Committee – 2 per year with 4 year terms

Bruce E. van Dam, Chair.....	2008
Robert M. Campbell, Past Chair.....	2008
Edward D. Simmons.....	2008
David W. Polly, BOS/COSS Liaison.....	2008
Michael D. Daubs (C).....	2008
Jeffrey S. Kanel.....	2009
Mark A. Lorenz, Chair Elect.....	2009
Daniel W. Green.....	2010
Marco Brayda-Bruno (I).....	2010
William C. Lauerma.....	2011
John P. Lubicky.....	2011

Joseph P. O'Brien, advisory

Stanley E. Sacks, advisory

Council: Governance

Board Liaison: David W. Polly

Staff Liaison: Megan Kelley

AWARDS & SCHOLARSHIP COMMITTEE

Standing Committee – 3 per year, with 3 year terms

Jay Shapiro, Chair.....	2008
Kenneth M.C. Cheung, Past Chair (& Research) ..	2008
Courtney W. Brown.....	2008
Hossein Mehdiian.....	2008
Munish C. Gupta (Global Outreach).....	2008
Paul D. Sponseller (Program).....	2008
Lori Ann Karol.....	2009
K. Daniel Riew, Chair Elect.....	2009
Barton L. Sachs.....	2009
Hilali H. Noordeen.....	2010
Jeffrey L. Stambough.....	2010
Dennis Crandall.....	2010

Council: Education

Board Liaison: George H. Thompson

Staff Liaison: Amy Miller

BYLAWS & POLICIES COMMITTEE

Standing Committee – 1 per year, with 4 year terms

Eric T. Jones, Chair.....	2008
Barney L. Freeman, Past Chair.....	2008
Suken A. Shah (C).....	2008
J. Abbott Byrd, Chair Elect.....	2009
Robert J. Huler.....	2010
Michael McMaster.....	2011

Council: Governance

Board Liaison: James W. Ogilvie

Staff Liaison: Amy Miller

CME COMMITTEE

Standing Committee – President-Elect, Vice President, Program, Education & Website Chairs and Chairs Elect, plus IMAST Chair

Oheneba Boachie-Adjei, Chair.....	2008
R. Jay Cummings (Education).....	2008
Lawrence G. Lenke (IMAST).....	2008
Paul D. Sponseller (Program).....	2008
Daniel J. Sucato (Website).....	2008
Andrew A. Merola (Website).....	2009
Richard E. McCarthy, Chair Elect.....	2009
Allen W. Carl (Education).....	2009
Peter O. Newton (Program).....	2009

Council: Education

Board Liaison: Oheneba Boachie-Adjei

Staff Liaison: Jenny Oliva



CODING COMMITTEE

Standing Committee – 1 per year, with 4 year terms

Richard J. Haynes, Chair	2008
R. Dale Blasier, Past Chair	2008
Evalina L. Burger	2008
Mark D. Rahm (C)	2008
James T. Bennett, Chair Elect	2009
Barton L. Sachs	2010
Jeffrey B. Neustadt	2011

Council: Governance
Board Liaison: George H. Thompson
Staff Liaison: Megan Kelley

EDUCATION COMMITTEE

Standing Committee – 2 per year, with 4 year terms

R. Jay Cummings, Chair	2008
Laurel C. Blakemore, Past Chair	2008
Reginald Q. Knight	2008
Paul D. Sponseller (Program)	2008
R. Shay Bess (C)	2008
Kuniyoshi Abumi	2009
Allen W. Carl, Chair Elect	2009
Lawrence L. Haber	2010
Joseph H. Perra	2010
Ahmet Alanay	2011
Kamal N. Ibrahim	2011

Council: Education
Board Liaison: Behrooz A. Akbarnia
Staff Liaison: Jenny Oliva

ENDOWMENT COMMITTEE

Standing Committee – 3 Past Presidents, plus 9 other members – 3 per year, with 3 year terms

Jeffery L. Stambough, Chair	2008
Howard S. An	2008
John P. Kostuik	2008
Vernon T. Tolo	2008
James W. Ogilvie, PP3	2008
Randal R. Betz, PP2	2009
Albert E. Sanders	2009
Daniel J. Sucato	2009
Behrooz A. Akbarnia, PP1	2010
Frances A. Farley	2010
Baron S. Lonner, Chair Elect	2010

Council: Finance
Board Liaison: Richard E. McCarthy
Staff Liaison: Amy Miller

ETHICS COMMITTEE

Standing Committee – 1 per year, with 4 year terms

Donald P.K. Chan (E), Chair	2008
Jose A. Herrera-Soto (C)	2008
Marc A. Asher, Chair Elect	2009
Dennis S. Drummond (E)	2010
Bettye A. Wright (E)	2011
Michael A. Edgar	2012

Council: Governance
Board Liaison: David W. Polly, Jr.
Staff Liaison: Kevin Szpara

EVIDENCE BASED MEDICINE COMMITTEE

Standing Committee – 3 appointed members, 3 year terms, plus chairs of Education, M&M, Patient Based Outcomes, Program and Research

Brian D. Snyder, Chair	2008
R. Jay Cummings (Education)	2008
William F. Donaldson III (M&M)	2008
Mark F. Abel (Outcomes)	2008
Paul D. Sponseller (Program)	2008
Kenneth M.C. Cheung (Research)	2008
David B. Cohen (C)	2008
Reginald Q. Knight, Chair Elect	2009
Peter O. Newton	2010

Council: Research
Board Liaison: George H. Thompson
Staff Liaison: Amy Miller

FELLOWSHIP COMMITTEE

Elected members – 1 per year, 4 year term

David S. Marks, Chair	2008
J. Abbott Byrd, Chair Elect	2009
Mark Weidenbaum	2010
Serena S. Hu	2011

Council: Governance
Board Liaison: Richard E. McCarthy
Staff Liaison: Nilda Toro

FINANCE COMMITTEE

Treasurer, Treasurer-Elect, Presidential Line

Steven M. Mardjetko, Chair	2011
George H. Thompson	2008
Oheneba Boachie-Adjei	2009
Richard E. McCarthy	2010
Tressa Goulding, Executive Director	Ad Hoc
Dan Nemeec, Accounting Director	Ad Hoc

Council: Finance
Board Liaison: Richard E. McCarthy
Staff Liaison: Tressa Goulding



GLOBAL OUTREACH COMMITTEE

Standing Committee – 3 per year, with 3 year terms

Munish C. Gupta, Chair	2008
Steven M. Mardjetko, Past Chair	2008
Ellen M. Raney	2008
Richard M. Schwend	2008
Michael J. Mendelow (C)	2008
Dilip K. Sengupta (C)	2008
Hooman M. Melamed (C)	2008
Charles T. Mehlman, Chair Elect	2009
Richard H. Gross	2009
Isador H. Lieberman	2009
Francisco Sanchez Perez-Grueso	2009
Linda P. d'Andrea	2010
Federico P. Girardi	2010
Kamal Ibrahim (Worldwide Course)	2010
Peter F. Sturm	2010

Council: Education

Board Liaison: Oheneba Boachie-Adjei

Staff Liaison: Amy Miller

GROWING SPINE COMMITTEE

Standing Committee – 3 per year, with 4 year terms

Muharrem Yazici, Chair	2008
John M. (Jack) Flynn, Past Chair	2008
Charles E. Johnston	2008
Paul D. Sponseller	2008
John A.I. Ferguson (C)	2008
Michael Ruf (C)	2008
Francisco S. Perez-Grueso, Chair Elect	2009
Richard E. McCarthy	2009
George H. Thompson	2009
Behrooz A. Akbarnia	2010
Alain Dimeglio (H)	2010
Vincent F.X. Deeney	2010
Laurel C. Blakemore	2011
Lawrence I. Karlin	2011
Carlos A. Tello	2011

Council: Research

Board Liaison: George H. Thompson

Staff Liaison: Kevin Szpara

HISTORICAL COMMITTEE

Standing Committee – Chaired by Historian, who is Board appointed for 3 year renewable term. Members: 1 per year, 3 year terms, plus PP3 (one year term)

Nathan H. Lebowhl, Historian	2008
James W. Ogilvie, PP3	2008
Robert W. Gaines	2008
John Tis (C)	2008
Behrooz A. Akbarnia	2009
Daniele A. Fabris-Monterumici (I)	2010
John J. Grayhack	2011

Council: Governance

Board Liaison: Behrooz A. Akbarnia

Staff Liaison: Kevin Szpara

IMAST COMMITTEE

Standing Committee – 1 per year, 4 year terms

Chair to serve a 4 year term, then 2 years as Past Chair

Chair Elect to serve a 2 year term

Lawrence G. Lenke, Chair	2008
Amir A. Mehbod (C)	2008
Stephen L. Ondra (C)	2008
Todd J. Albert, Chair Elect	2008
Azmi Hamzaoglu	2009
Timothy R. Kuklo	2010
B. Stephens Richards	2011

Council: Education

Board Liaison: Oheneba Boachie-Adjei

Staff Liaisons: Tressa Goulding, Megan Kelley

INDUSTRY RELATIONS COMMITTEE

Standing Committee – President, Treasurer, PPI, President-Elect,

Vice President, plus 3 appointed members with 3 year terms: PPI to serve as Chair

Behrooz A. Akbarnia, Chair	2008
Mark Weidenbaum	2008
George H. Thompson, Chair Elect	2009
John E. Lonstein	2009
Oheneba Boachie-Adjei	2010
J. Bradley Williamson (I)	2010
Steven M. Mardjetko	2011
Richard E. McCarthy	2011

Council: Governance

Board Liaison: Behrooz A. Akbarnia

Staff Liaison: Megan Kelley

LONG RANGE PLANNING COMMITTEE

Standing Committee of president, past presidents 1, 2 & 3, Chairs of IMAST, Global Outreach, Worldwide Course. PPI to Chair.

Behrooz A. Akbarnia, Chair	2008
Munish C. Gupta (Global Outreach)	2008
Kamal Ibrahim (Worldwide Course)	2008
James W. Ogilvie (PP3)	2008
Lawrence G. Lenke (IMAST)	2008
Randal R. Betz, Past Chair	2009
George H. Thompson, Chair Elect	2011

Council: Finance

Board Liaison: James W. Ogilvie

Staff Liaison: Tressa Goulding



MARKETING & PUBLIC RELATIONS COMMITTEE

Ad Hoc Committee (may decide to change to Standing) 7 members with one year terms

Alan Moskowitz, Chair	2008
Dennis G. Crandall, Co-Chair	2008
Paul A. Glazer	2008
Michael O. LaGrone	2008
Ian Bruce McPhee (I)	2008
Arya Nick Shamie (C)	2008

Council: Governance

Board Liaison: Steven M. Mardjetko

Staff Liaison: Megan Kelley

MORBIDITY & MORTALITY COMMITTEE

Standing Committee – 2 per year, 4 year terms

William F. Donaldson III, Chair	2008
Christopher I. Shaffrey, Past Chair	2008
Ram Mudiyaam	2008
Theodore J. Choma (C)	2008
Joseph H. Perra, Chair Elect	2009
Reinhard D. Zeller (I)	2009
D. Raymond Knapp	2010
Hilali H. Noordeen	2010
Sigurd H. Berven	2011
Michael J. Goytan	2011

Council: Research

Board Liaison: George H. Thompson

Staff Liaison: Kevin Szpara

NEWSLETTER COMMITTEE

Standing Committee – 1 per year, 3 year terms: Chair serves a 3 year renewable term as Newsletter Editor

Vicki Kalen, Chair & Editor	2010
Keith D. Luk (C)	2008
Alpasian Senkoylu (C)	2008
Mario Turi	2009
Kathy Blanke (A)	2010

Council: Governance

Board Liaison: Randal R. Betz

Staff Liaison: Kevin Szpara

NOMINATING COMMITTEE

Standing Committee – 1 year terms

Behrooz A. Akbarnia, Chair	2008
Timothy Kuklo	2008
Daniel Sucato	2008
Joseph Perra	2008
Charles Johnston	2008

Council: Reports to Board

Board Liaison: Behrooz A. Akbarnia

Staff Liaison: Tressa Goulding

NON-OPERATIVE MANAGEMENT COMMITTEE

Standing Committee – 2 per year, 3 year terms

Timothy A. Garvey, Chair	2008
John F. Sarwark, Past Chair	2008
John M. Flynn (PR)	2008
Timothy S. Oswald (C)	2008
Raymond D. Knapp, Jr, Chair Elect.	2009
Mario Turi	2009
Brian G. Smith	2010
Jeffrey D. Thomson	2010

Council: Research

Board Liaison: George H. Thompson

Staff Liaison: Jenny Oliva

PATIENT BASED OUTCOMES COMMITTEE

Standing Committee – 3 per year, 3 year terms

Mark F. Abel, Chair	2008
Lawrence I. Karlin, Past Chair	2008
T. Desmond Brown	2008
Phyllis d'Ambra (Assoc)	2008
Robert P. Huang (C)	2008
Vincent Arlet	2009
Douglas C. Burton, Chair Elect	2009
Frank J. Schwab	2009
Dale V. Hoekstra	2010
James V. Raso (Assoc)	2010
James O. Sanders	2010

Council: Research

Board Liaison: Behrooz A. Akbarnia

Staff Liaison: Kevin Szpara

PATIENT EDUCATION COMMITTEE

Standing Committee – 3 per year, 3 year terms

Linda P. d'Andrea, Chair	2008
Glen M. Ginsburg	2008
Bettye A. Wright (E)	2008
Eric H. Buchl (C)	2008
Daniel W. Green	2009
Scott D. Hodges	2009
John T. Killian, Chair Elect	2009
Ram Mudiyaam	2010
Viswas R. Talwaker	2010
Connie Poe-Kochert	2010

Joe P. O'Brien – Advisory

Stanley E. Sacks – Advisory

Council: Education

Board Liaison: James W. Ogilvie

Staff Liaison: Kevin Szpara



PREVALENCE & NATURAL HISTORY COMMITTEE

Mohammad Diab, Chair.....	2008
Yizhar Floman (I).....	2008
Glen M. Ginsburg.....	2008
Christopher L. Hamill.....	2008
Robert P. Huang (C).....	2008
Michael Jofe (C).....	2008
Nigel J. Price Co-Chair.....	2008

Council: Research

Board Liaison: Steven M. Mardjetko

Staff Liaison: Kevin Szpara

PROGRAM COMMITTEE

Standing Committee – 3 per year, 3 year terms, plus reviewers with one year terms

Paul D. Sponseller, Chair.....	2008
David L. Skaggs, Past Chair.....	2008
Sanford E. Emery.....	2008
Muharrem Yazici.....	2008
James T. Guille (C).....	2008
Lawrence G. Lenke (IMAST Chair).....	2008
Douglas C. Burton.....	2009
Peter O. Newton, Chair Elect.....	2009
Andrew G. King.....	2009
Todd J. Albert (IMAST Chair Elect).....	2009
Patrick J. Connolly.....	2010
Noriaka Kawakami, 2010 Co-Chair.....	2010
Michael J. Yaszemski, 2010 Co-Chair.....	2010

Reviewers:

Ahmet Alanay	Amir Mehbod (C)
Eric Buchl (C)	Charles T. Mehlman
Mohammad Diab	Yutaka Nohara (I)
Michael Daubs (C)	Stephen Ondra (C)
Federico Girardi	B. Stephens Richards
Azmi Hamzaoglu	Anthony Rinella
Timothy Kuklo	Michael Ruf (C)
Stanley Lee (C)	Vishwas Talwalker
Isadore H. Lieberman	Clifford Tribus
Carlos Tello	

Council: Education

Board Liaison: Richard E. McCarthy

Staff Liaison: Amy Miller

RESEARCH GRANT COMMITTEE

Standing Committee – 3 per year, 4 year terms

Kenneth M.C. Cheung, Chair.....	2008
Brian D. Snyder, Past Chair.....	2008
Howard S. An.....	2008
Jeffrey C. Wang.....	2008
Stefan Parent (C).....	2008
Nathan H. Lebowhl.....	2009
Marc J. Moreau.....	2009
Kit M. Song, Chair Elect.....	2009
Benjamin A. Alman.....	2010
Nancy Hadley Miller.....	2010
Cathleen L. Raggio.....	2010
Dilip K. Sengupta.....	2011
Peter P. Masso.....	2011
Matthew B. Dobbs.....	2011

Council: Research

Board Liaison: Steven M. Mardjetko

Staff Liaison: Amy Miller

SPINAL DEFORMITY CURRICULUM COMMITTEE

Ad Hoc Committee – 5 members with 1 year terms

James W. Ogilvie, Chair.....	2008
Denis S. Drummond, Co-Chair.....	2008
Todd J. Albert.....	2008
John P. Dormans.....	2008
Stephen L. Ondra (C).....	2008

Council: Education

Board Liaison: James W. Ogilvie

Staff Liaison: Jenny Oliva

SPINAL MONITORING COMMITTEE

Charles T. Price, Chair.....	2008
James R. Malcolm, Past Chair.....	2008
Siavash S. Haghghi.....	2008
Jeffrey H. Owen.....	2008

Council: Research

Board Liaison: Steven M. Mardjetko

Staff Liaison: Jenny Oliva

SRS / SPINE LIAISON COMMITTEE

Standing Committee – 2 per year, 3 year terms, with one being the next in line to serve as Program Chair; Committee should include past, present & upcoming chairs of the Program Committee

Keith H. Bridwell, Chair / Spine Editor.....	2008
David L. Skaggs (Program Past Chair).....	2008
Paul T. Rubery, Jr.....	2008
James Guille (C).....	2008
Paul D. Sponseller, Chair Elect.....	2009
Panagiotis Korovessis.....	2009
Peter O. Newton (Program Chair Elect).....	2010
Munish C. Gupta.....	2010

Council: Education

Board Liaison: Behrooz A. Akbarnia

Staff Liaison: Amy Miller



STUDY GROUPS TASK FORCE

Ad Hoc Task Force with one year renewable terms

Lawrence G. Lenke, Chair.....	2008
Oheneba Boachie-Adjei.....	2008
John F. (Jack) Flynn.....	2008
Peter O. Newton.....	2008

Council: None (Board of Directors)
Board Liaison: Behrooz A. Akbarnia
Staff Liaison: Megan Kelley

3D SPINAL CLASSIFICATION

Ad Hoc Committee with one year renewable terms

Lawrence G. Lenke, Chair.....	2008
Hubert Labelle, Co-Chair.....	2008
Carl Eric Aubin.....	2008
Roger P. Jackson.....	2008
Peter O. Newton.....	2008
Ian A.F. Stokes.....	2008

Ad Hoc Members

Mark F. Abel.....	2008
Kenneth M.C. Cheung.....	2008
Howard A. King.....	2008
Richard E. McCall.....	2008
Michael J. Mendelow (C).....	2008
Reinhard D. Zeller (I).....	2008

Council: Research
Board Liaison: Steven M. Mardjetko
Staff Liaison: Megan Kelley

WEBSITE COMMITTEE

Standing Committee – 2 per year, 4 year terms

Daniel J. Sucato, Chair.....	2008
John T. Smith, Past Chair.....	2008
Mohammad Diab.....	2008
Kent A. Reinker.....	2008
Ross Moquin (C).....	2008
Todd Milbrandt (C).....	2008
Neel Anand (C).....	2008
Linda P. d’Andrea (Patient Education).....	2008
Allen L. Carl.....	2009
Andrew A. Merola, Chair Elect.....	2009
Michael O. LaGrone.....	2009
John F. Sarwark.....	2010
Dale E. Rowe.....	2010
Michael F. O’Brien.....	2011
Kit M. Song.....	2011

Council: Education
Board Liaison: Randal R. Betz
Staff Liaison: Amy Miller

WORLDWIDE CONFERENCE COMMITTEE

Standing Committee –4 per year, with 4 year terms, plus Chairs of Education and Global Outreach Committees; Chair to serve a 4 year term, then 2 years as Past Chair; Chair elect to serve a 2 year term

Kamal N. Ibrahim, Chair.....	2010
Kuniyoshi Abumi.....	2008
Robert W. Gaines.....	2008
Scott D. Hodges.....	2008
Christopher L. Hamill.....	2008
R. Jay Cummings (Education).....	2008
Munish C. Gupta (Global Outreach).....	2008
Afshin Aminian (C).....	2008
Suken A. Shah (C).....	2008
Yutaka Hiraizumi.....	2009
Donald P.K. Chan.....	2009
John F. Sarwark.....	2009
Peter F. Sturm.....	2009
Norbert Passuti (I).....	2010
Khalil Kharrat.....	2010
Carlos Tello.....	2010
Ahmet Alanay.....	2011
William C. Horton.....	2011
Victor Rositto.....	2011
Charles E. Johnston II.....	2011

Council: Education
Board Liaison: Randal R. Betz
Staff Liaison: Megan Kelley

INTERNATIONAL ADVISORY BOARD

Azmi Hamzaoglu, Chair.....	2008
Oheneba Boachie-Adjei, Co- Chair.....	2008
Carlos Tello (The Americas).....	2008
Marinus de Kleuver (Europe).....	2008
Nobumasa Suzuki (Asia).....	2008
Kamal Ibrahim (Middle East/Africa).....	2008

Council: Governance
Board Liaison: Oheneba Boachie-Adjei
Staff Liaison: Kevin Szpara

BOS Representatives (formerly COMSS)

George H. Thompson.....	2008
David W. Polly.....	2008

COSS Representatives

David W. Polly.....	2008
James W. Ogilvie.....	2009

FOSA Representatives

Timothy R. Kuklo.....	March 2011
Laurel C. Blakemore.....	Feb. 07-Mar. 08

Hibbs Society Liaison

Robert W. Gaines.....	2008
-----------------------	------



**Education Council – John P. Dormans, Chair – 2008;
Steven D. Glassman, Chair-Elect**

Awards & Scholarship Jay Shapiro
CME Oheneba Boachie-Adjei
Education R. Jay Cummings
Global Outreach Munish C. Gupta
IMAST Lawrence G. Lenke
Patient Education Linda P. d'Andrea
Program Paul D. Sponseller
Spinal Deformity Curriculum James W. Ogilvie
Website Daniel J. Sucato
Worldwide Course Kamal N. Ibrahim
Staff Liaison: Jenny Oliva

Finance Council – Steven M. Mardjetko, Chair

Endowment Jeffrey L. Stambough
Finance Steven M. Mardjetko
Long Range Planning Behrooz A. Akbarnia
Staff Liaison: Tressa Goulding

Governance Council – David W. Polly, Jr., Chair

Advocacy & Public Policy Bruce E. van Dam
Bylaws & Policies Eric T. Jones
Coding Richard J. Haynes
Ethics Donald P.K. Chan
Fellowship David S. Marks
Historical Nathan H. Lebowhl
Marketing & Public Relations Alan Moskowitz
Newsletter Vicki Kalen
Spine Liaison Keith Bridwell
Staff Liaison: Tressa Goulding

Research Council – Peter O. Newton, Chair

Adult Deformity William C. Horton
Evidence Based Medicine Brian D. Snyder
Growing Spine Muharrem Yazici
Morbidity & Mortality William F. Donaldson II
Non-Operative Management Timothy A. Garvey
Patient Based Outcomes Mark F. Abel
Prevalence & Natural History Mohammad Diab
Research Grant Kenneth M.C. Cheung
Spinal Monitoring Charles T. Price
3D Spinal Classification Lawrence G. Lenke
Staff Liaison: Amy Miller

PREVIOUS SRS AWARD & RESEARCH GRANT RECIPIENTS



SCOLIOSIS RESEARCH SOCIETY



Exhibit Awards

- 1982 **Ronald L. DeWald, Mary Faut Rodts, James S. Fister**
The Management of Unstable Burst Fractures of the Thoracic and Lumbar Spine
- 1984 (Blount) **R. Mervyn Letts and G.J.Gouw**
Scoliosis in the Head Injured Child
- 1985 (Blount) **Kiyoshi Kaneda, Tomoyuki Hashimoto, Shigenobu Satoh, Kuniyoshi Abumi**
Late Progressive Neurologic Deficit Following Thoracolumbar Spine Fractures
- 1986 (Blount) **Greg Houghton, Anne McInerny, Tony Tew**
Compliance Monitoring System for Spinal Braces
- 1987 **Jeffrey H. Owen, Keith H. Bridwell**
Motor (MEPs) and Somatosensory Evoked Potentials (SEPs) in Animals and Humans: Sensitivity and Specificity
- 1991 **Ian A.F. Stokes, Mack Gardner-Morse, Jeffrey P. Laible**
The Biomechanics of Surgical Derotation
- 1992 **Tali Siegal, Tzony Siegal**
Neoplastic Spinal Cord Compression: Manipulation of Vasogenic Edema by Ketanserin, a 5-HT₂ Receptor Blocker
- 1993 **Kristian Høy, S.M. Jespersen, E.S. Hansen, K.Ø. Christensen, B.E. Lindblad, S.Z. He, C. Bungner**
Hemodynamics of the Spinal Cord, Cauda Equina, Nerve Roots and the Dural Sac During Exercise - An Experimental Study
- 1994 (Moe) **Kirkham B. Wood, Timothy A. Garvey, Cooper Gundry, Kenneth Heitoff**
Thoracic MRI Evaluation of Asymptomatic Individuals
- 1995 (Moe) **Michael P. Chapman, Christopher L. Hamill, Keith H. Bridwell, Lawrence G. Lenke, Kathy Blanke, Christy Baldus**
Can We Lordose the Spine with Zielke Instrumentation Anteriorly?
- 1996 (Moe) **Sakae Sato, Marc A. Asher**
Comparison of Lamina Hook to Pedicle Screw Anchors for Correction of Double Structural Adolescent Idiopathic Scoliosis
- 1997 (Moe) **Tatsuto Takeuchi, Kuniyoshi Abumi, Itaru Oda, Yasuhiro Shono, Kiyoshi Kaneda**
Biomechanical Evaluation of Thoracic Spinal Stability: A Significance of Costovertebral Joints in Providing Stability
- 1998 (Moe) **Itaru Oda, Bryan W. Cunningham, Charles J. Haggerty, Kiyoshi Kaneda, Paul C. McAfee**
An In-Vitro Study Investigating the Stability of Reconstruction Methods Following Total Spondylectomy
- 1999 Moe - Basic Science **Edward P. Southern, Howard S. An, Charles E. Edmiston, Jr., Larry Newman, Michael Goheen, Dawn Zuelke, Sharon Sinski, Gary Seabrook**
A Microbiology and Lint Study in the Orthopaedic Surgery Operating Room
- Goldstein Clinical **Christian Fras, Twee Do, Stephen Burke, Bernard Rawlins, Roger Widmann, Oheneba Boachie-Adjei**
Routine Preoperative MRI in Adolescent Idiopathic Scoliosis: A Prospective Study of 327 Patients
- 2000 Moe – Basic Science **R.K. Wilcox, T.O. Boerger, R.M. Hall, D.C. Barton, D.L. Limb, R.A. Dickson**
Canal Pressure Measurements and Video Recording of Thoracolumbar Burst Fractures
- Goldstein Clinical **Makoto Tokunaga, Shohei Minami, Hiroshi Kitahara, Yoshinori Nakata, Hideshige Moriya**
Neurologic Complications in Scoliotic Patients with Syringomyelia
- 2001 Moe – Basic Science **P.C. McAfee, B.W. Cunningham, A.E. Dmitriev, N. Shimamoto, J.C. Seftor, I.L. Fedder**
General Principles of Porous Ingrowth Total Disk Replacement Arthroplasty Compared to Diarthrodial Total Joint Arthroplasty. A Non-Human Primate Model – Part 1
- Goldstein Clinical **Mohammed J. Al-Sayyad, Charles T. Mehlman, Alvin H. Crawford**
Effectiveness of Spinal Release and Halo-Femoral Traction in the Management of Severe Spinal Deformity



- 2002 Moe – Basic Science **Andrew A. Merola, Michael F. O’Brien, Amit Lamba, Gregorio Chejfec, Thomas R. Haher, Andrew Castro, Franco Givna, Sameer Mathur, Mario Brkavic, David A.B. Smith, James M. Eule, N. Joseph Espot, Thomas G. Lowe, Thomas F. Dwyer**
Attenuation of Ciliary Neurotrophic Factor (CNTF) in Acute Spinal Cord Injury (ASCI) Treated with Intravenous Methylprednisolone (MP)
- Goldstein Clinical **Behrooz A. Akbarnia, David S. Marks, Oheneba Boachie-Adjei, Marc A. Asher, Alistair G. Thompson, Richard C. Rooney, Chatupon Chotigavanichaya**
Dual Rod Posterior Instrumentation Without Fusion for the Treatment of Progressive Early Onset Scoliosis: A Multicenter Study
- 2003 Moe – Basic Science **William W. Lu, Kenneth M.C. Cheung, Keith D.K. Luk, John C.Y. Leong**
A Novel Sr-HA Bioactive Bone Cement for Vertebroplasty
- Goldstein Clinical **Athanasios I. Tsirikos, Freeman Miller, Wei-Ning Chang, Kirk W. Dabney, Joseph Glutting**
Life Expectancy in Pediatric Patients with Cerebral Palsy and Neuromuscular Scoliosis who Underwent Spinal Fusion
- 2004 Moe – Basic Science **Vikas V. Patel, Li Zhao, Pamela Wong, Ben Bhupendra Pradhan, Linda Kanim, Hyun W. Bae, Rick B. Delamarter**
Controlling BMP-Simulated Bone Growth Using Fibrin Glue
- 2004 Goldstein Clinical **André van Ooij, F. Chumhur Oner, Ab J. Verbout**
Complications of Artificial Disc Replacement: A Report of 45 Patients with an Unconstrained Disc Prosthesis
- 2005 Goldstein Clinical **Gene Cheh, Lawrence G. Lenke, Keith H. Bridwell, YoungJung J. Kim**
“Decompression Alone vs. Decompression and Limited Fusion for the Treatment of Degenerative Lumbar Scoliosis”
- 2005 Moe – Basic Science **Cathy Xiao Xi Guo, Kenneth McCheung, Danny Chan, Michael Irwin**
“Comparison of the Effect of Non-Selective NSAID and Cyclooxygenase-2 (COX-2) Selective NSAID on Bone Formation – Implications for Spinal Fusion”
- 2006 Goldstein Clinical **Clayton L. Dean, Josue P. Gabriel, Michael J. Bolesta, Ezequiel Cassinelli, Henry H. Bohlman**
Degenerative Spondylolisthesis of the Cervical Spine. A Long Term Follow-up Study
- 2006 Moe – Basic Science **Nancy Hadley Miller, Beth Marosy, Marie Helene Roy-Gagnon, Kimberly F. Doheny, Elizabeth W. Pugh, Alexander F. Wilson, Cristina M. Justice**
Familial Idiopathic Scoliosis: Defining Genomic Loci on Chromosomes 9 and 16 Utilizing Custom SNP Panels
- 2007 Moe – Basic Science **Jonathan G. Schoenecker, Nicholas Mignemi, Heidi Hamm, Herbert Schwartz, Ginger Holt, Gregory Mencio**
Aprotinin Inhibits Bone Formation In Vitro
- Goldstein – Clinical **Mark J. Sokolowski, Timothy A. Garvey, John Perl, Amir A. Mehbod, Burak Akesen, Margaret S. Sokolowski, Ensor E. Transfeldt**
Prospective Study of Post-Operative Lumbar Epidural Hematoma: Does Size Really Matter?

Best Discussor

- 1984 Harold K. Dunn, MD
1985 Dennis R. Wenger, MD
1986 Vernon T. Tolo, MD
1988 Thomas F. Kling, Jr., MD
1989 J. Andy Sullivan, MD
1991 John E. Hall, MD
1992 Gordon L. Engler, MD

Hibbs Award for Best Basic Science Presentation

- 1980 **Kazuhiko Satomi, Jens Axelgaard**
Effects of Selective Cord Transections on Spinal Evoked Potentials
- 1981 **Ensor E. Transfeldt, Edward H. Simmons**
Functional and Pathological Biomechanics of the Spinal Cord: An In Vivo Study
John A. Herring
Early Complications of Segmental Spinal Instrumentation
- 1982 **R.G. Burwell, J.J. James, F. Johnson, J.K. Webb, Y.G. Wilson**
Standardized Trunk Asymmetry Scores: A New Method and a Study of Normality
Roger P. Jackson, E.J. Simmons, D. Stripinis
Structural Changes Correlating with Back Pain in Scoliosis
- 1983 **Robert Barrack**
Proprioception in Idiopathic Scoliosis
- 1984 **Cohen, Solomons, Lowe**
Altered Platelet Calmodulin Activity in Idiopathic Scoliosis
D. Hoppenfeld, Gross and Andrews
The Ankle Clonus Test
- 1985 **Thomas F. Kling, Jr, P.M. Spargo, Robert N. Hensinger, P.R. Knight III**
The Effect of Nitroglycerin Induced Hypotension With and Without Spine Distraction on Canine Spinal Cord Blood Flow
- 1986 **William C. Schrader, Daniel Bethem, Vladimir Scerbin**
The Chronic Local Effects of Sublaminar Wires - An Animal Model
- 1987 **Jeffrey H. Owen, John Laschinger, Keith Bridwell, Shelle Shimon, Carl Nielsen, Janet Dunlap**
Sensitivity and Specificity of Somatosensory and Neurogenic-Motor Evoked Potentials in Animals and Humans
- 1988 **Steve K. Salzman, A.A. Mendez, A.S. Fonseca, E.B. Ingersol, G.M. Freeman, I.H. Choi**
Effects of Anesthesia on Outcome After Experimental Spinal Trauma: Halothane has a Protective Effect
- 1989 **Rick B. Delamarter, Henry H. Bohlman, D. Bodner, C. Biro**
Urologic Function Following Experimental Cauda Equina Compression: Cystometrograms vs. Cortical Evoked Potentials
- 1990 **Steven K. Salzman, Michael A. Puniak, Zhong-jun Liu, Richard P. Maitland-Heriot, Gina M. Freeman, Cynthia A. Agresta, Laura Van Newkirk**
Pharmacological Treatment of Acute Spinal Trauma I: Mechanisms of Action of the Serotonin Antagonist Mianserin
- 1991 **Dale Dalenberg, Marc A. Asher, Gopal Jayaraman, Ralph Robinson**
The Effect of a Stiff Spinal Implant and Its Loosening on Bone Mineral Content in Canines
- 1992 **Sanford E. Emery, Mark S. Brazinski, Anuradah Koka, Jay S. Bensusan, Sharon Stevenson**
The Biological and Biomechanical Effects of Irradiation on Anterior Spinal Bone Grafts - A Canine Model
- 1993 **Stephen D. Cook, Thomas S. Whitecloud, Jeannette E. Dalton, D.C. Rueger**
In Vivo Evaluation of Recombinant Human Osteogenic Protein (rhOP-1) as a Bone Graft Substitute for Spine Fusions
- 1994 **Jeffrey H. Schimandle, Scott D. Boden, W.C. Hutton**
Experimental Spine Fusion with Recombinant Human Bone Morphogenetic Protein (rhBMP-2)
- 1995 **Douglas M. Petraco, Jeffrey M. Spivak, Joseph G. Cappadona, Frederick J. Kummer, Michael G. Neuwirth**
An Anatomic Evaluation of L5 Nerve Stretch in Spondylolisthesis Reduction
- 1996 **S.B. Tan, J.T.H. Chew, R. Fortune, H.H. Tan, K.P. Tan, R.T.H. Ng, I.C. Song**
Allograft Vertebral Disc Transplantation in a Porcine Model
- 1997 **Keith M. Bagnall, Cian O'Kelly, Marc Moreau, James Raso, Xiaoping Wang**
Scoliosis Development Following Pinealectomy in Young Chickens, Rats and Hamsters
- 1998 **John R. Dimar II, Steven Glassman, George Raque, Y. Ping Zhang, Christopher Shields**
The Influence of Canal Narrowing and Timing of Decompression on Neurological Recovery Following Spinal Cord Contusion in the Rat Model
- 1999 **Jeffrey C. Wang, Stephen Yoo, Linda E.A. Kanim, Paula L. McAllister, Scott D. Nelson, Edgar G. Dawson, Jay R. Lieberman**
Gene Therapy for Spinal Fusion: Transformation of Marrow Cells with an Adenoviral Vector to Produce BMP-2
- 2000 **K.D. Riew, J. Lou, N.M. Wright, S.-L. Cheng, T. Bae, L.V. Avioli**
Thoracoscopic Intradiscal Spine Fusion Using Gene Therapy



- 2001** **M. Darryl Antonacci, Manu Nothias, Catherine Humphreys, Richard Frisch, Marion Murray**
Axonal Regeneration Using Transplants of Genetically Engineered Fibroblasts in Spinal Cord Injury
- 2002** **Kohei Goshi, Oheneba Boachie-Adjei, Bernard A. Rawlins, Ronald G. Crystal, Chisa Hidaka**
Genetically Modified Marrow Cells Enhance Spine Fusion
- 2003** **M. Darryl Antonacci, Jean Nothias, Tom Parks, Richard Fritsch, Chris Cawley, Marion Murray**
Human Marrow Stromal Cell Transplants in a Collagen Matrix Support Axonal Regeneration of Descending Pathways Across Complete Spinal Cord Transections
- 2004** **William C. Horton, Chaiwat Kraiwattanapong, Tomoyuki Akamaru, Akihito Minamide, Moon-Soo Park, William Hutton**
The Role of the Sternum, Costosternal Articulations, Intervertebral Disc, and Facets in Thoracic Sagittal Plane Biomechanics and Deformity Correction: A Comparison of Three Different Sequences of Surgery
- 2005** **Brian K. Kwon, Jie Liu, Clarrie Lam, Loren W. Oschipok, Armin Blesch, Wolfram Tetzlaff**
“Brain Derived Neurotrophic Factor Gene Transfer with Adeno-Associated Viral and Lentiviral Vectors Prevents Rubrospinal Neuronal Atrophy and Stimulates Regeneration Associated Gene Expression after Acute Cervical Spinal Cord Injury”
- 2006** **Howard S. An, Kei Miyamoto, Jesse G. Kim, Nozomu Inoue, Koji Akeda, Gunnar Andersson, Koichi Masuda**
An Intradiscal Injection of Osteogenic Protein-1 Restores the Viscoelastic Properties of Degenerated Intervertebral Discs in the Rabbit Anular Puncture Model
- 2007** **Kenneth J. Hunt, John T. Braun, Bryt A. Christensen**
The Effect Of Two Clinically Relevant Fusionless Scoliosis Implant Strategies On The Health of the Intervertebral Disc

Hibbs Awards for Best Clinical Presentation

- 1981** **John A. Herring, Dennis R. Wenger**
Early Complications of Segmental Spinal Instrumentation
- 1982** **Roger P. Jackson, Edward H. Simmons, D. Stripinis**
Structural Changes Correlating with Back Pain in Scoliosis
- 1984** **Hoppenfeld, Gross and Andrews**
The Ankle Clonus Test
- 1985** **Bert Mandelbaum, Vernon Tolo, Paul McAfee, Peggy Buresh**
Nutritional Deficiencies After Staged Anterior and Posterior Spinal Surgery
- 1986** **Paul D. Sponseller, Mark S. Cohen, John E. Hall, Alf L. Nachemson**
Long-Term Follow-Up of Adult Scoliosis Treated Surgically
- 1987** **Christine S. O'Donnell, William P. Bunnell, Randal R. Betz, Cynthia R. Tipping**
Electrical Stimulation in the Treatment of Idiopathic Scoliosis
- 1988** **John E. Lonstein, Robert B. Winter**
Milwaukee Brace Treatment of Adolescent Idiopathic Scoliosis - Review of 939 Patients
- 1989** **J.P. Thompson, Ensor E. Transfeldt, David Bradford, Oheneba Boachi-Adjei**
Evaluation of Spinal Imbalance and Shoulder Elevation Following Cotrel-Dubousset Instrumentation with Special Reference to Uncoupling
- 1990** **David M. Apel, G. Marrero, W.D. Goldie, J. King, Vernon T. Tolo, George S. Bassett**
Avoiding Paraplegia During Anterior Spinal Surgery: The Role of SSEP Monitoring During Temporary Occlusion of Segmental Spinal Arteries
- 1991** **Lawrence G. Lenke, Keith H. Bridwell, Christy Baldus, Kathy Blanke**
Preventing Decompensation in King Type II and III Curves Treated with Cotrel-Dubousset Instrumentation (CDI): 24 to 64 Month Follow-Up
- 1992** **D. Holte, Robert Winter, John Lonstein, Francis Denis**
Hemivertebra Excision and Wedge Resection in the Surgical Treatment of Patients with Congenital Scoliosis
- 1992** **Shanti S. Upadhyay, P. Sell, B. Sell, M.J. Saji, E.K.W. Ho, J.Y.C. Leong**
Seventeen Year Prospective Study of Surgical Management of Tuberculosis of the Spine: A Controlled Trial Comparing Anterior Debridement with Hong Kong Radical Operation
- 1993** **Mark Goldberg, Nancy Mayo, Benoit Poitras, Susan Scott, James Hanley**
The Ste-Justine Adolescent Idiopathic Scoliosis (AIS) Cohort Study I & II: Description of the Cohort Health Outcomes and Back Pain
- 1994** **Thomas Maher, R. Zipnick, D. Manor, Andrew Merola, John Gorup, J. Dryer, R. Nucci, J. Orchowski, C. Kaufmann**
Meta-Analysis of Surgical Outcome in Scoliosis: A Thirty One Year Review of Eleven Thousand Patients

- 1995 **Howard H. Ginsburg, L. Goldstein, P. William Haake, Shannon Perkins, K. Gilbert**
Longitudinal Study of Back Pain in Postoperative Idiopathic Scoliosis: Long-Term Follow-Up, Phase IV
- 1996 **James O. Sanders, David G. Little, B. Stephens Richards**
Prediction of the Crankshaft Phenomenon by the Peak Growth Age
- 1997 **John P. Kostuik**
The Development of a Preoperative Scoring Assessment System of Metastatic Spine Disease
- 1998 **Stuart L. Weinstein, Lori Dolan, Kevin Spratt, Kirk Peterson, Mark Spoonamore**
Natural History of Adolescent Idiopathic Scoliosis: Back Pain at 50-Year Follow-Up
- 1999 **Marc A. Asher, Sue Min Lai, Douglas C. Burton**
Further Development and Validation of the SRS Outcomes Instrument
- Hiroshi Taneichi, Kiyoshi Kaneda, Kuniyoshi Abumi, Manabu Ito**
Radiological Differentiation Between Benign and Malignant Vertebral Body Collapse
- 2000 **R. Jhanjee, K. Wood, G. Buttermann, T. Garvey, R. Kane, V. Sechreist, A. Mehbod**
Operative Vs. Nonoperative Treatment of Thoracolumbar Burst Fractures without Neurological Deficit: A Randomized, Prospective Study
- 2001 – TIE **Aina J. Danielsson, I. Wiklund, K. Pehrsson, Alf L. Nachemson**
Health-Related Quality of Life in Patients with Adolescent Idiopathic Scoliosis – A Matched Follow-Up at Least Twenty Years After Treatment with Brace or Surgery
- Harry L. Shufflebarger, Cynthia Clark**
The Posterior Approach for Lumbar and Thoracolumbar Adolescent Idiopathic Curves: Posterior Shortening and Pedicle Screws
- 2002 **C. Barrios, C. Pérez-Encinas, J.I. Maruenda, P. Renovell, N. de Bernardo, L. García del Moral, J.A. Martín-Benlloch, M. Laguía**
Significant Ventilatory Functional Restriction in Adolescents with Mild or Moderate Scoliosis During Maximal Exercise Tolerance Test
- 2003 **Eric J. Wall, Donita Bylski-Austrow, Ronald Kolata, Alvin H. Crawford**
Endoscopic Mechanical Spinal Hemiepiphyodesis Modifies Spine Growth
- 2004 **Christopher Hulen, H. Temple, Allaaddin Mollobashy, Frank Eismont**
Oncological and Functional Outcome Following Sacrectomy for Sacral Tumors
- 2005 **Ilkka Helenius, Tommi Lamberg, Kalevi Österman, Dietrich Schlenzka, Timo Yrjönen, Seppo Seitsalo, Mikko Poussa, Ville Remes**
“Posterolateral, Anterior or Circumferential Fusion In-Situ for High-Grade Spondylolisthesis in Young Patients: A Long-Term Evaluation using SRS Questionnaire”
- 2006 **Joshua D. Auerbach, Daniel M. Schwartz, Denis S. Drummond, Kristofer J. Jones, John M. Flynn, Yaser El-Gazzar, Thomas McPartland, J. Andrew Bowe, Samuel Laufer, Peter D. Pizzutillo, J. Richard Bowen, John P. Dormans**
Detection Of Impending Neurologic Injury During Surgery For Adolescent Idiopathic Scoliosis: A Comparison Of Transcranial Motor And Somatosensory Evoked Potential Monitoring In 1121 Consecutive Cases
- 2007 **Lawrence G. Lenke; Brenda A. Sides; Linda Koester; Marsha Hensley; Kathy Blanke**
Posterior Vertebral Column Resection (VCR) for Severe Pediatric and Adult Spinal Deformity: Indications, Results, and Complications of 43 Consecutive Cases

Walter P. Blount Humanitarian Award

- 1987 Marc A. Asher, MD
- 1989 Howard and Barbara Schulman
- 1992 Laura Gowen
- 1996 David B. Levine, MD
- 1997 Albert E. Sanders, MD
- 1998 L. Ray Lawson, MD
- 2001 Charles F. Heinig, MD
- 2002 James E. Holmblad, MD
- 2006 Oheneba Boachie-Adjei, MD
- 2007 Professor John CY Leong



SRS Travelling Fellows

- 1970** John D. King, California
Jen Fang Wang, Taiwan
- 1971** Donald P.K. Chan, Vermont
Gourish R. Palekaar, India
- 1993** **Medtronic Sofamor Danek
Traveling Fellows**
Robert B. Winter, MD, Senior Fellow
George S. Bassett, MD, Junior Fellow
J. Kenneth Burkus, MD, Junior Fellow
Ensor E. Transfeldt, MD, Junior Fellow
- 1995** **Medtronic Sofamor Danek
Traveling Fellows**
John E. Hall, MD, Senior Fellow
Howard S. An, MD, Junior Fellow
Hubert H.L. Labelle, MD, Junior Fellow
Lawrence G. Lenke, MD, Junior Fellow
- 1997** **Medtronic Sofamor Danek
Traveling Fellows**
Ronald L. DeWald, MD, Senior Fellow
Vincent Arlet, MD, Junior Fellow
Allen L. Carl, MD, Junior Fellow
Michael F. O'Brien, MD, Junior Fellow
- 1999** **Medtronic Sofamor Danek
Traveling Fellows**
Clyde L. Nash, MD, Senior Fellow
Serena S. Hu, MD, Junior Fellow
Joseph Y. Margulies, MD, PhD, Junior Fellow
Rolando M. Puno, MD, Junior Fellow
Kirkham B. Wood, MD, Junior Fellow
- 2000** **DePuy AcroMed International Traveling Fellows**
Ufuk Aydinli, MD, Turkey
Henry F.H. Halm, MD, Germany
Yutaka Hiraizumi, MD, PhD, Japan

- 2001** **Medtronic Sofamor Danek Traveling Fellows**
John P. Kostuik, MD, Senior Fellow
Peter O. Newton, MD, Junior Fellow
Richard M. Schwend, MD, Junior Fellow
Edward P. Southern, MD, Junior Fellow
- 2002** **DePuy AcroMed International Traveling Fellows**
Bruce F. Hodgson, FRACS, New Zealand
Jin-Hyok Kim, MD, Korea
Muharrem Yazici, MD, Turkey
(Note: Tamás Illés, MD, Hungary, was originally selected but unable to participate)
- 2003** **Medtronic Sofamor Danek Traveling Fellows**
Courtney W. Brown, MD, Senior Fellow
Timothy R. Kuklo, MD, Junior Fellow
Daniel J. Sucato, MD, Junior Fellow
Alexander R. Vaccaro, MD, Junior Fellow
- 2004** **DePuy Spine International Traveling Fellows**
Ahmet Alanay, MD, Turkey
Kenneth M.C. Cheung, MD, Hong Kong
Ulf R. Liljenqvist, MD, Germany
- 2005** **Medtronic Sofamor Danek Traveling Fellows**
Donald P.K. Chan, MD, Senior Fellow
Matthew B. Dobbs, MD, Junior Fellow
Charles T. Mehlman, MD, Junior Fellow
Suken Shah, MD, Junior Fellow
- 2006** **DePuy Spine International Traveling Fellows**
Theodoros B. Grivas, MD, Greece
Ashok Johari, MD, India
Reinhard D. Zeller, MD, France
- 2007** **Medtronic Traveling Fellows**
James Ogilvie, MD, Senior Fellow
Youngjung Kim, MD, Junior Fellow
Praveen Mummaneni, MD, Junior Fellow
Jean Ouellet, MD, Junior Fellow
- 2008** **DePuy Spine International Traveling Fellows**
Kyu-Jung Cho, MD, South Korea
Kan Min, MD, Switzerland
Avraam Ploumis, MD, Greece

Research Grant Recipients

In the last ten years, SRS, in conjunction with OREF and the Cotrel Foundation have provided more than \$1.8 million for spinal deformity research projects. The following are previous SRS Research Grant recipients:

1998

Nancy Hadley Miller, MD

Genetic Analysis of Etiologic Factors of AIS
\$50,000 – 2 years

John A. Szivek, PhD

Monitoring Spinal Fusion in Scoliosis Patients: A Biomechanical & In Vivo Study
\$54,000 – 2 years

Jack Engsberg, PhD

Comparison of Outcome Measures in Adult Scoliosis Patients Undergoing an Extended Spinal Fusion to L5 or Sacrum or Revision of Previous Long Spinal Deformity Fusion
\$80,308 – 3 years

William A. Vannah

Longitudinal Study of Balance & Other Factors in AIS
\$10,887.50 – 2 years

1999

Jack C.Y. Cheng, MD

The Loss of Synchronous Coupling of Endochondral and Membranous Ossification in AIS: The Morphological and Biological Evidences
\$35,400 – 1 year

James O. Sanders, MD

A Determination of Maturity in Girls with Idiopathic Scoliosis: A Pilot Study
\$48,252 - 2 years

2000

Keith Bagnall, PhD

The Relationship Between Serum Melatonin & Growth Hormone in Pinealectomy Model
\$14,250 – 2 years

Oheneba Boachie-Adjei, MD w/ Dr. Raymond Clarke

Developmental Basis of the Klippel-Feil Syndrome
\$60,000 – 3 years

Frances Farley, MD

Prediction of Curve Progression in Congenital Scoliosis Using a Mouse Model
\$44,926 – 2 years

Carol A. Wise, PhD

Localization of a Gene for Susceptibility To Idiopathic Scoliosis
\$36,066.50 – 2 years

Nancy Hadley Miller, MD

Genetic Linkage of Familial Idiopathic Scoliosis – A Complex Orthopaedic Disorder
\$50,000 – 2 years

Thomas Lowe, MD

Platelet Calmodulin Levels in AIS: A Predictor of Curve Progression and Severity
\$42,070 – 2 years

2001

Jack C.Y. Cheng, MD

Relationship between Postural Balance, Somatosensory Evoked Potential and the Progression of Scoliotic Deformity in the AIS
\$70,800 – 2 years

2002

Carol Wise, PhD

Localization & Analysis of Candidate Genes of Idiopathic Scoliosis
\$36,666.50 – 2 years

2003

Jack. C.Y. Cheng, MD

Are VDR, Era and PTHR1 Genes Associated With The Occurrence as well As Abnormality In Bone Growth And Sexual Maturation In Adolescent Idiopathic Scoliosis
\$70,800 – 2 years

John Kostuik, MD

Adult Onset of Scoliosis: Relationship between Osteoporosis and Deformity
\$30,000 – 2 years

Matthew Dobbs, MD

Idiopathic Scoliosis: Gene Mapping Identification
\$47,177 – 2 years

2004

Philip Giampietro, MD, PhD

Mutation Analysis in Human Congenital Scoliosis and Vertebral Malformations
\$77,077 – 2 years

Carol Wise, PhD

Localization and Analysis of Candidate Genes for Idiopathic Scoliosis
\$50,000 – 2 years



Ralph Marcucio, PhD

A Comparison of the Expressions of Malatonin, Calmodulin and 5-HT4 in Paravertebral Muscle and Platelets of Patients with our without Adolescent Idiopathic Scoliosis
\$50,000 – 2 years

2005

Kenneth Cheung, MD

Surface Modification of Nitinol by Plasma Immersion ION Implantation
\$100,000 – 2 years

Robin Patel, MD

Biofilms and Spinal Instrumentation
\$99,850 – 2 years

Alf Nachemson, MD, PhD

A Continuation of the “SRS Study for Brace Treatment of Adolescent Idiopathic Scoliosis” – Follow-up of the Swedish Patients at Least 10 Years After Maturity
\$47,020 – 2 years

Brian Snyder, MD, PhD

How does VEPTR Affect Pulmonary Function: An In-vivo Assessment using the Rabbit Scoliosis Model
\$34,408 – 1 year

Stefan Parent, MD, PhD

Analysis of Local 3-D Measurements of the Curve as Predictive Factors for Curve Progression in AIS
\$25,000 – 1 year

Francis Shen, MD

Can We Eliminate the Need for Autologous Bone Graft Harvest? The Use of Multipotential Adipose-derived Stromal Cells in an Activated Matrix for Posterolateral Spinal Fusions
\$25,000 – 1 year

Andrew Merola, MD

Association between an Aggrecan Gene Polymorphism and AIS
\$10,000 – 1 year

Anthony Florschutz, MD

Experimental Scoliosis Using Vertebral Body Implanted Magnets in an Immature Goat Model
\$10,000 – 1 year

Stefan Parent, MD, PhD

Growth Modulation of the Chest Case in a Pre-Natal Ovine Model: A Preliminary Study
\$10,000 – 1 year

Andrew Mahar, MS

How Does Increasing Curve Magnitude in Scoliotic Deformity Affect the Biomechanics of the Spine with Implications Toward Curve Correction?
\$10,000 – 1 year

Donita Bylski-Austrow, PhD

Mechanobiology of Growth: In-Vivo Growth Plate Pressures
\$10,000 – 1 year

Felix Breden, BA, MSc, PhD

The Guppy ‘Curveback’ Mutant as a Model for Spinal Deformity
\$10,000 – 1 year

Jack C.Y. Cheng, MD

Abnormal Differential Longitudinal Growth of Vertebral Column and Spinal Cord in AIS – A Morphological and Functional Study
\$77,000

Brian K. Kwon, MD, PHD, FRCSC

Neuroprotection for Acute Spinal Cord Injury: The Preclinical Evaluation of Drugs That Are Currently Used in Human Non-Spinal Applications
\$24,881.60 – 2 years

2006

Carol Wise, PhD

Identification of Genetic Susceptibility in Idiopathic Scoliosis
\$19,000 – 2 years

Shane Burch, MD FRCSC

The Role of Hypoxic Stress on the Vertebral Growthplates of the Developing Spine and its Potential Role in Pathogenesis of Scoliosis
\$10,000 – 1 year

Vedat Deviren, MD

The Minimal Clinically Important Difference (MCID) for Spinal Disorders: Finding the Threshold of Clinically Significant Change
\$24,996 – 1 year

2007

Jeffrey Shilt, MD; Peter Apel, MD

Temporary Unilateral Paraspinal Muscle Paralysis on the Prevention and Progression of Scoliosis: Investigation in a Chicken Model
\$9,740 - 1 year

Mohammad Diab, MD

Comparison of Extended-Release Epidural Morphine, Patient-Controlled Epidural Analgesia and Patient-Controlled Intravenous Analgesia for Postoperative Pain after Posterior Spinal fusion in Adolescents
\$24,245 – 2 years

Frank Schwab, MD

Adult Deformity: Development of an Effective Treatment Algorithm Based upon Outcomes Analysis
\$50,000 – 2 years

John Lonstein, MD

Long-term Function Outcomes of Early Fusions for Congenital Scoliosis
\$75,450 – 2 years

Michael Vitale, MD

CT Analysis of Pedicle Screw Placement in Pediatric Patients
\$20,595 – 1 year

Vidyadhar Upasani, MD

The Effect of Increasing Construct Rigidity on Intervertebral
Disc Health: A Pilot Study in a Porcine Anterior Spinal
Growth Modulation Model
\$10,000– 1 year

Xudong Li, MD

Nucleus Pulposus Regeneration with Genetically Engineered
Fat-derived Stem Cells
\$50,000 – 2 years

Josh Auerbach, MD

An in vivo Porcine Animal Model to Detect Spinal Cord
Vascular Flow in Spinal Deformity Surgery using Transcranial
Motor Evoked Potential Monitoring
\$10,000 – 1 year

2008

Sigurd Berven, MD

Impact of Spinal Disorders on Health Related Quality of Life
\$5,000 – 1 year

Safdar Khan, MD

Utilizing a Novel MRI-based (Dense-FSE) Technique to
Characterize Spatial Strain Distributions in an Established
Model of Intervertebral Disc Degeneration: Implications for
Tissue Engineering
\$10,000 – 1 year

Hubert Labelle, MD

Towards a 3D Classification of Adolescent Idiopathic Scoliosis
\$49,600 – 2 years

SRS BYLAWS



SCOLIOSIS RESEARCH SOCIETY





**BYLAWS
OF
SCOLIOSIS RESEARCH SOCIETY
(AN ILLINOIS NOT-FOR-PROFIT CORPORATION)**

ARTICLE I: NAME

ARTICLE II: OBJECTIVES, PURPOSES AND POWERS

- Section 2.1 Objectives and Purposes
- Section 2.2 Powers
- Section 2.3 Prohibited Practices

ARTICLE III: OFFICES

- Section 3.1 Principal and Business Offices
- Section 3.2 Registered Agent
- Section 3.3 Records

ARTICLE IV: FELLOWSHIP

- Section 4.1 Identification of Fellow Classes
- Section 4.2 Candidate Fellowship
- Section 4.3 Active Fellowship
- Section 4.4 Inactive Fellowship
- Section 4.5 Associate Fellowship
- Section 4.6 Emeritus Fellowship
- Section 4.7 Honorary Fellowship
- Section 4.8 Annual Meeting
- Section 4.9 Special Meeting
- Section 4.10 Voting
- Section 4.11 Quorum
- Section 4.12 Notice of Meeting
- Section 4.13 Induction of New Fellows

ARTICLE V: MEMBER COVENANTS

- Section 5.1 Confidential Information
- Section 5.2 Conflicts of Interest/Disciplinary Process

ARTICLE VI: BOARD OF DIRECTORS

- Section 6.1 General Powers and Responsibilities
- Section 6.2 Number, Tenure and Qualification
- Section 6.3 Regular Meetings
- Section 6.4 Special Meetings
- Section 6.5 Notice of Meetings
- Section 6.6 Quorum
- Section 6.7 Manner of Acting
- Section 6.8 Officers of the Board of Directors
- Section 6.9 Information Action by Directors
- Section 6.10 Meetings by Electronic Means of Communication
- Section 6.11 Executive Committee

ARTICLE VII: OFFICERS

- Section 7.1 Officers/Eligibility
- Section 7.2 Election Procedure
- Section 7.3 President
- Section 7.4 President-Elect
- Section 7.5 Vice-President
- Section 7.6 Secretary
- Section 7.7 Secretary-Elect
- Section 7.8. Treasurer
- Section 7.9 Treasurer-Elect
- Section 7.10 Vacancies
- Section 7.11 Resignation/Removal

ARTICLE VIII: COUNCILS

ARTICLE IX: COMMITTEES

- Section 9.1 Classification and Organization
- Section 9.2 Education Committee
- Section 9.3 Fellowship Committee
- Section 9.4 Program Committee
- Section 9.5 Bylaws and Policies Committee
- Section 9.6 Nominating Committee

ARTICLE X: COMPENSATION

ARTICLE XI: AMENDMENTS

ARTICLE XII: DUES

- Section 12.1 Annual Dues
- Section 12.2 Exemption from Dues

ARTICLE XIII: RULES OF ORDER

ARTICLE XIV: DISSOLUTION

ARTICLE XV: CONTRACTS, CHECKS, DEPOSITS AND GIFTS

- Section 15.1 Contracts
- Section 15.2 Checks, Drafts, Etc.
- Section 15.3 Deposits
- Section 15.4 Gifts

ARTICLE XVI: BOOKS AND RECORDS

ARTICLE XVII: FISCAL YEAR

ARTICLE XVIII: SEAL

ARTICLE XIX: INDEMNIFICATION

ARTICLE XX: MISCELLANEOUS

- Section 20.1 Trademarks
- Section 20.2 Interpretation
- Section 20.3 Definition of "Code"
- Section 20.4 Headings
- Section 20.5 Executive Director



**BYLAWS
OF
SCOLIOSIS RESEARCH SOCIETY
(AN ILLINOIS NOT-FOR-PROFIT CORPORATION)**

**ARTICLE I
NAME**

The name of this corporation shall be the "Scoliosis Research Society" (hereinafter referred to as the "Society"). The Society is a nonstock, not-for-profit corporation organized under the Illinois Revised Statutes.

**ARTICLE II
OBJECTIVES, PURPOSES AND POWERS**

Section 2.1 Objectives and Purposes.

The Society has been organized, and shall at all times be operated, exclusively for charitable, educational and scientific purposes within the meaning of section 501(c)(3) of the Code (as defined in Section 20.3, below), which purposes shall include, but not be limited to, the fostering, promotion, support, augmentation, development and encouragement of (a) investigative knowledge of the causes, cures and prevention of Scoliosis and related spinal deformities; (b) standardization of medical terminology in Scoliosis and related spinal deformities; (c) basic research in the field of Scoliosis and related spinal deformities; (d) the teaching and education of the same by developing, publishing and copyrighting educational material and providing specialized training for orthopaedic surgeons, neurosurgeons, and other members of the medical profession; and (e) education of the public with respect to the recognition and prevention of Scoliosis and related spinal deformities.

Section 2.2 Powers.

The Society shall possess all powers which a corporation organized under the General Not-For-Profit Corporation Act of the State of Illinois, as the same from time to time may be amended shall possess; all powers which are not in conflict with said purposes; provided, however, the Society shall not engage in any business which would disqualify it from being exempt from taxation under Sections 501(a) or (c)(3) of the Code.

Section 2.3 Prohibited Practices.

Notwithstanding anything in these Bylaws or the Society's Articles of Incorporation to the contrary, the Society shall exercise only those powers or engage in or carry on only those activities permitted to be exercised, engaged in or carried on by an organization exempt from federal income tax under Sections 501(c)(3) and 509(a)(1) of the Code and by an organization contributions to which are deductible under Section 170(c)(2) of the Code. The Society shall not engage in any activities which would result in the imposition of federal tax under Sections 4941 through 4945, inclusive, of the Code. No part of the net earnings of the Society shall inure to the benefit of any private individual, except that the Society shall be authorized and empowered to pay reasonable compensation for services rendered and to make payments and distributions in furtherance of the exempt purposes set forth in Section 2.1 of these Bylaws. No substantial part of the activities of the Society shall consist of carrying on propaganda or otherwise attempting to influence legislation, except as otherwise provided in subsection 501(h) of the Code, and the Society shall not participate or intervene in, including the publication or distribution of statements, any political campaign on behalf of or in opposition to any candidate for public office. In the pursuit of its purposes and the exercise of its powers, the Society shall make its services and activities available to the community that it serves regardless of, and shall not discriminate on the basis of, race, color, gender, sexual orientation, creed, religion or national origin.

**ARTICLE II
OFFICES**

Section 3.1 Principal and Business Offices.

The Society may have such principal and other business offices as the Board of Directors may designate. The current principal offices are located at 555 East Wells Street, 11th Floor, Suite 1100, Milwaukee, Wisconsin 53202.

Section 3.2 Registered Agent.

The Society shall maintain a registered agent as required by the Illinois Revised Statutes whose address may be, but need not be, identical with the principal office of the Society. The name and address of the registered agent may be changed from time to time by the Board of Directors.

Section 3.3 Records.

The Board of Directors may keep the books of the Society in such place or places, including, without limitation, an authorized agent, as they may from time to time determine in accordance with the Illinois Revised Statutes.

**ARTICLE IV
CLASSES OF FELLOWSHIP**

Section 4.1 Identification of Fellow Classes

The Society shall have members, which shall hereinafter be referred to as "Fellows." There shall be six (6) classes of membership (such term herein after referred to as "Fellowship") in the Society, namely, Candidate, Active, Inactive, Associate, Emeritus, and Honorary. Any reference to Fellows in these Bylaws refers to all six (6) classes of Fellowship, unless otherwise specified. Only Active Fellows shall have the right to vote on matters submitted to a vote of the members of the Society, hold office or serve on the Board of Directors. Otherwise, Fellows of any class shall have the same rights and responsibilities including the right to attend meetings and serve on Committees or Councils. Fellowship status in any class shall be a privilege, not a right, and is dependent upon the applicant for any class of Fellowship demonstrating compliance with the requirements for such Fellowship as defined in the Bylaws and otherwise as determined by the Board of Directors of the Society.

The Board of Directors may from time to time, in its sole discretion, establish membership criteria, rules and procedures applicable to Fellowship in any class in order to implement and carry out the provisions of this Article IV, including, without limitation, specific membership criteria, requirements and procedures for application to Fellowship in any class, and procedures and requirements for transfer between such classes of Fellowship; provided, however, that no such criteria, rules or procedures shall be established which alter the membership criteria and/or classifications set forth in these Bylaws. All determinations whether an individual has met the requirements for or otherwise qualified for membership of any class shall be made by the Board of Directors in its sole discretion after receiving and taking into account the recommendation of the Fellowship Committee (as defined in Section 9.3, below).

Section 4.2 Candidate Fellowship

The following individuals shall be eligible to be Candidate Fellows of the Society: (a) orthopaedic surgeons and neurosurgeons in active clinical practice who have a demonstrated interest and involvement in, and commitment to, the field of Scoliosis and related spinal deformities; and (b) scientists in a field related to Scoliosis and/or related spinal deformities who have a demonstrated interest and involvement in, and commitment to, scientific research and investigation in the field of Scoliosis and/or related spinal deformities. A Candidate Fellow shall be eligible to be considered for Active Fellow status after five (5) years of membership as a Candidate Fellow in good standing.

Section 4.3 Active Fellowship

Individuals who have been Candidate Fellows in good standing for five (5) years shall be eligible to become Active Fellows of the Society upon application made by such individual.

Section 4.4 Inactive Fellowship

Any Active Fellow who has become disabled by sickness or accident or otherwise becomes incapacitated for a period of more than fifteen (15) consecutive calendar months and who is unable to engage in his or her normal professional activities that give rise to his or her eligibility for Active Fellow status may apply to the Board of Directors for a transference to Inactive Fellow status. Individuals whose applications for Inactive Fellow status are approved shall be Inactive Fellows, in which event any rights and privileges accorded to any such individual as Active Fellow shall be suspended for such period as such individual is an Inactive Fellow. An individual who is an Inactive Fellow may apply to the Board of Directors for resumption of Active Fellow status as the case may be, once such individual resumes his or her normal professional activities which qualified him or her as an Active Fellow.

Section 4.5 Associate Fellowship

Individuals engaged in professional, scientific or academic activities and/or allied health specialties who:

- (a) have a demonstrated interest and involvement in, and commitment to, the field of Scoliosis and related spinal deformities but who are not otherwise eligible for Candidate Fellow or Active Fellow status; or
- (b) are eligible for Candidate Fellow or Active Fellow status but do not desire to become, Candidate Fellows or Active Fellows shall be eligible to be Associate Fellows of the Society.

Section 4.6 Emeritus Fellowship

An Active Fellow or Associate Fellow who has retired from the active conduct of his or her profession or vocation regardless of age or who has otherwise reached the age of sixty-five (65) shall be eligible to apply to the Board of Directors for a transfer to Emeritus Fellowship status. Membership dues shall be waived for Emeritus Fellows.



Section 4.7 Honorary Fellowship

Honorary Fellowship may be conferred, upon the recommendation of the Fellowship Committee and approval by the Board of Directors by a two-thirds (2/3) vote thereof, upon an individual who has contributed significantly to, or is otherwise preeminent in, the field of Scoliosis and/or related spinal deformities. Honorary Fellows shall not be required to pay dues. Honorary Fellows may be issued a certificate, in the discretion of the Board of Directors, signifying their admission as Honorary Fellows.

Section 4.8 Annual Meeting.

The annual meeting of the Society shall be held at such time and place each year as may be determined by the Board of Directors from time to time (which time and place shall be specified in a notice of meeting), in order to elect new directors and officers, conduct such scientific sessions and discussions as the Board of Directors may determine and transact such other business as shall come before such meeting.

Section 4.9 Special Meetings.

Special meetings of the members may be called for any purpose by (a) the President; (b) the Board of Directors by majority vote thereof; or (c) the written petition of five percent (5%) of the number of Active Fellows delivered to the Secretary of the Society.

Section 4.10 Voting.

Each Active Fellow in good standing, and only Active Fellows in good standing, shall be entitled to vote in person on all matters to be voted on by members of the Society, including, without limitation, electing directors and officers of the Society as provided herein. Any matter to be decided by a vote of the members of the Society shall, except as otherwise provided in the Illinois Revised Statutes or as expressly provided herein, be decided by a majority of Active Fellows voting in person at a duly held meeting of Active Fellows at which a quorum is present. Cumulative voting or placing all votes for a particular candidate or a particular issue is prohibited. Whenever within these Bylaws an individual is specified as an Ex-Officio member of a board or committee, said Ex-Officio member shall not have the right to vote as such unless otherwise expressly provided in these Bylaws.

Section 4.11 Quorum.

The presence in person of not less than twenty percent (20%) of the total number of Active Fellows shall constitute a quorum for the transaction of business at any annual or special meeting of Active Fellows of the Society. If a quorum is not present at any such meeting, a majority of the Active Fellows present thereat may adjourn the meeting from time to time, without further notice. The Active Fellows present in person at a duly organized meeting at which a quorum is present may continue to transact business until adjournment, notwithstanding the withdrawal during the meeting of that number of Active Fellows whose absence would cause less than a quorum.

Section 4.12 Notice of Meetings.

Written notice stating the place (which may be within or without the state of Illinois), day and time of any meeting of Active Fellows (including, without limitation, any annual meeting) shall be signed by the President or Secretary of the Society and shall be delivered either personally or by first class United States mail, electronic mail or facsimile, to each member entitled to vote at such meeting, not less than thirty (30) days nor more than sixty (60) days before the date of such meeting. In case of a special meeting or when otherwise required by Illinois Revised Statutes or by these Bylaws, such notice shall also include the purpose or purposes for which the meeting is called. In the case of a special meeting, no business other than that specified in the notice of such meeting shall be transacted at any such meeting. If mailed, the notice of meeting shall be deemed to be delivered when deposited in the United States mail addressed to the member at his or her address as it appears on the records of the Society, with postage thereon prepaid. If such notice is given by electronic mail or facsimile, such notice shall be deemed delivered upon receipt by the sender of confirmation of successful transmission of such notice to the member at his or her electronic mail address or facsimile telephone number, as the case may be.

Section 4.13 Induction of New Fellows

Induction of new Fellows of any class shall take place at each annual meeting.

**ARTICLE V
MEMBER COVENANTS**

Section 5.1 Confidential Information.

Members, directors, officers, committee members and staff of the Society shall abide by such confidentiality policies relating to confidential information of the Society as the Board of Directors may establish from time to time.

Section 5.2 Conflicts of Interest/Disciplinary Process.

The Board of Directors may establish from time to time such rules or policies with respect to the ethical conduct of its members, including without limitation, procedures and policies for dealing with conflicts of interest and the discipline of its members in the event of a breach of any rules or policies of the Society.

**ARTICLE VI
BOARD OF DIRECTORS**

Section 6.1 General Powers and Responsibilities

The Board of Directors shall have full responsibility for the management, direction and control of the business, policies and affairs of the Society, subject only to the limitations set forth in these Articles of Incorporation, these Bylaws, or by applicable law.

Section 6.2 Number, Tenure and Qualification

The Board of Directors shall, except as otherwise provided in this Section, consist of twelve (12) members and shall be composed of (a) the President, the President-Elect, the Vice President, the Secretary and the Treasurer; (b) the three most immediate Past Presidents; and (c) four (4) at-large directors. In years when there is a Treasurer-Elect and/or Secretary-Elect, as more fully described below, said officers shall also be directors and the number of directors comprising the Board of Directors shall be expanded accordingly. The President, President-Elect, Vice-President, Secretary, Treasurer, Treasurer-Elect and Secretary-Elect shall, by virtue of their positions as such, automatically be members of the Board of Directors for so long as they hold their respective offices. The above-referenced immediate Past-Presidents shall serve on the Board of Directors for terms of three (3) years each immediately after the completion of their respective terms as President, which terms shall not be renewable. At-large directors shall serve for terms of two (2) years, which terms shall be non-renewable. The terms of at-large directors shall be staggered so that, as nearly as possible, the terms of one-half of the at-large directors then in office expire each year. Only Active Fellows of the Society in good standing shall be eligible to be directors of the Society. At-large directors shall be nominated and elected in accordance with, and as part of, the procedure for electing officers of the Society as set forth in Section 7.2, below.

Section 6.3 Regular Meetings

Regular Meetings of the Board of Directors shall be held prior to or after but in conjunction with each annual meeting of the Society and/or at such other times as the President may designate for the transaction of such business that may come before the meeting. The Board of Directors may provide by resolution the time and place, either within or without the State of Illinois, for the holding of additional regular meetings of the Board of Directors without other notice than such resolution.

Section 6.4 Special Meetings

Special Meetings of the Board of Directors may be called by or at the request of the President or any two (2) other directors by delivering such request in writing to the Secretary, designating the time and place, either within or without of the State of Illinois, for such meeting to be held and stating the purpose for such meeting or the items to be considered. In the event the Secretary fails, neglects or refuses to distribute proper notice of such requested special meeting, the persons requesting the meeting may schedule or convene such meeting by proper notice to all directors then in office.

Section 6.5 Notice of Meetings

Notice of any Special Meeting of the Board of Directors shall be given at least 48 hours previous thereto by written notice delivered personally or sent by United States mail, electronic mail or facsimile to each director at his address as shown on the records of the Society. If mailed, such notice shall be deemed to be delivered when deposited in the United States mail in a sealed envelope so addressed with postage thereon prepaid. If notice is given by electronic mail or facsimile, such notice shall be deemed delivered upon receipt by the sender of confirmation of successful transmission of such notice to the director at his or her electronic mail address or facsimile telephone number, as the case may be. Any director may waive notice of any meeting. The attendance of a director at any meeting shall constitute a waiver of notice of such meeting, except where a director attends a meeting for the express purpose of objecting to the transaction of any business because the meeting is not lawfully called or convened. Neither the business to be transacted at, nor the purpose of, any regular or special meeting of the Board of Directors need be specified in the notice or waiver of notice of such meeting, unless specifically required by law or by these Bylaws.



Section 6.6 Quorum

A majority of the number of directors in office shall constitute a quorum for the transaction of business at any meeting of the Board of Directors. If the number of directors necessary to constitute a quorum shall fail to attend at the time and place fixed for any regular or special meeting of the Board of Directors, the directors in attendance may adjourn from time to time without notice or other announcement at the meeting until the requisite number of directors to constitute a quorum shall attend.

Section 6.7 Manner of Acting

The act of a majority of the number of directors present at a meeting at which a quorum is present shall be the act of the Board of Directors, except where otherwise provided by applicable law, the Articles of Incorporation of the Society, or by these Bylaws.

Section 6.8 Officers of the Board of Directors

The President of the Society shall serve as Chairman of the Board of Directors. The Secretary of the Society shall serve as the Secretary of the Board of Directors.

Section 6.9 Informal Action by Directors

Unless specifically prohibited by the Articles of Incorporation or by the Bylaws, any action required to be taken at a meeting of the Board of Directors, or any other action which may be taken at a meeting of the Board of Directors, may be taken without a meeting if a consent in writing, setting forth the action to be taken, shall be signed by all Directors entitled to vote with respect to the subject matter thereof. Any such consent signed by all directors shall have the same effect as a unanimous vote of the Board of Directors.

Section 6.10 Meetings by Electronic Means of Communication.

Notwithstanding any place set forth in the notice for a meeting of the Board of Directors, any director may participate in such meeting by, or through the use of, any means of communication by which (a) all participants may simultaneously hear each other, such as by conference telephone; or (b) all communication is immediately transmitted to each participant, and each participant can immediately send messages to all other participants. Before the commencement of any business at a meeting at which any director participates by electronic means, all participating directors shall be informed that a meeting is taking place at which official business may be transacted.

Section 6.11 Executive Committee.

There shall be established and maintained an Executive Committee which shall have and may exercise, when the Board of Directors is not in session, the powers of the Board of Directors in the management of the affairs of the Society, except action in respect to election or removal of officers and directors or the filling of vacancies in the Board of Directors or committees created pursuant to this Bylaw, or acts contrary to prior action adopted by the Board of Directors in proper session. The Executive Committee shall consist of the following individuals: the President, the Immediate Past-President, the President-Elect, the Vice President, the Secretary, the Treasurer and, when in office, the Secretary-Elect and the Treasurer-Elect. All members of the Executive Committee shall have voting rights thereon. The Executive Committee may meet from time to time between meetings of the Board of Directors at the discretion of the President and shall be authorized to conduct such business of the Society as may be necessary, subject to the Board of Directors' general direction and the obligation to report to the full Board of Directors. Notwithstanding the foregoing provision, the Executive Committee shall not be authorized to take any of the following actions on behalf of the Board of Directors: (a) elect directors or officers; (b) hire or terminate the executive director, if any; (c) amend these Bylaws; (d) dissolve the Society; or (e) authorize or contract any loan or indebtedness on behalf of the Society other than in accordance with these Bylaws. Meetings of the Executive Committee may be called by the President and shall be called upon written petition of two (2) other members of the Executive Committee. Notice of the time and place of each Executive Committee meeting shall be given in writing to each member of the committee not less than twenty-four (24) hours before such meeting. At any meeting of the Executive Committee, a majority of the number of Executive Committee members then in office shall constitute a quorum for the transaction of any business. The act of the majority of the Executive Committee members present at a meeting at which a quorum is present shall be the act of the Executive Committee.

Section 6.12 Director Vacancies

In case of any vacancy in a directorship for any reason, including, without limitation, the death, resignation or removal, before the expiration of the term of such directorship, the Nominating committee shall, as soon as practicable after such vacancy occurs, recommend to the Board of directors for its approval a qualified individual to fill such a vacancy. The Board of Directors shall as soon as practicable after such recommendation act on such approval. If such recommended individual is so approved, he or she shall serve for the unexpired portion of the term of the vacant directorship.

Section 6.13 Resignation/Removal of Directors

Any director may resign from the Board of directors at any time by giving written notice to the President. Any director may be removed from the Board of Directors with or without cause by the affirmative vote of at least two-thirds (2/3) of the Active Members present at a duly held meeting thereof.

ARTICLE VII OFFICERS

Section 7.1 Officers/Eligibility

The officers of the Society shall be as follows: President, President-Elect, Vice-President, Secretary, Secretary-Elect, Treasurer, and Treasurer-Elect. The President, President-Elect, Vice President, Secretary-Elect and Treasurer-Elect shall each serve for terms of one (1) year, which terms shall be non renewable, except as provided in Section 7.10 below. The Secretary and Treasurer shall, except as provided in Section 7.10 below, each serve for terms of four (4) years, which terms shall be non renewable (subject, however, to the proviso that individuals having previously served as Secretary and Treasurer respectively, shall be subject to returning to office as more fully described in Section 7.10, below, in the event of a vacancy in such office created by an immediate successor). The terms of the Secretary and Treasurer shall be staggered so that such terms alternatively expire every two (2) years. The President-Elect, the Vice President, the Secretary-Elect and the Treasurer-Elect shall each automatically succeed to the office of President, President-Elect, Secretary or Treasurer, as the case may be, upon the expiration of the term of the individual then serving in such office. Only Active Fellows who are then serving or who have previously served as at-large directors shall be eligible to be nominated as Vice President, Treasurer-Elect or Secretary-Elect.

Section 7.2 Election Procedure

At least one hundred twenty (120) days before each annual meeting of the Society, the Nominating Committee shall prepare, and submit to the Board of Directors, a list consisting of one individual recommended for each of the following offices: Vice-President, two (2) at-large directors and one (1) member of the Fellowship Committee. In the year immediately preceding any year in which the term of office of the Secretary or the Treasurer is to expire, the Nominating Committee shall also select one individual that it recommends for nomination to the office of Secretary-Elect or Treasurer-Elect, as the case may be. The Secretary of the Society shall promptly deliver a copy of such list of recommended nominations to any Active Member if request for same is submitted by such Active Member to the Secretary. Candidates for the positions to which they were nominated shall be elected upon receiving a majority of the votes cast by Active Fellows at such annual meeting. The term of office for those individuals elected to a position at an annual meeting shall commence as of the close of such meeting.

Section 7.3 President

The President shall be the principal executive officer of the Society and shall, subject to the direction and control of the Board of Directors, supervise and be in charge of all the business affairs of the Society. The President shall preside at all general meetings of the Society and of the Board of Directors. The President may sign, with the Secretary or any other proper officer of the corporation authorized by the Board of Directors, any deeds, mortgages, bonds, contracts or other instruments which the Board of Directors has authorized to be executed, except in cases where the signing and execution thereof shall be expressly delegated to the Board of Directors or by these Bylaws with the approval of the Board of Directors and shall be Ex-Officio member of all Committees except the Fellowship and Nominating Committees. The President may fill any vacancies between annual meetings subject to the approval of the Board of Directors unless such vacancies are to be filled as otherwise specified. The President is authorized to act in the event of any contingency or emergency not covered by the Bylaws. The President shall, in general, perform all duties incident to the office of President and such other duties as may be prescribed by the Board of Directors from time to time. The President shall preside at all meetings of the Board of Directors and shall, except as otherwise provided under applicable law or these Bylaws, be responsible for scheduling all meetings of the Board of Directors and to determine the order of business to be conducted at meetings of the Board of Directors. The President shall serve for one (1) year term of office, except in circumstances outlined in Section 7.10.

Section 7.4 President-Elect

The President-Elect shall assume the duties of the President in the absence of the President or in the event of his/her death, inability or refusal to act and when so acting shall have the powers of and be subject to all the restrictions upon the President. The President-Elect shall perform such other duties and have such other powers as the Board of Directors may from time to time prescribe. In addition, the President-Elect shall, as the President-Elect of the Society, carry out such duties in such capacity as the President or the Board of Directors may from time to time determine. The President-Elect shall be an Ex-Officio member of all committees except the Fellowship and Nominating Committees. The President-Elect shall automatically succeed to the office of President at the close of the annual meeting at which the current President's term expires, or as otherwise provided in Section 7.10.



Section 7.5 Vice-President

The Vice President shall assume the duties of the President-Elect in the absence of the President-Elect and in the event of his or her death or inability or refusal to act, and when so acting, shall have all the powers of and be subject to all of the restrictions upon the President-Elect. The Vice President shall also assume the duties of President in the absence of both the President and the President-Elect and in the event of death or inability or refusal to act of both of them, and when so acting the Vice President shall have all of the powers of and be subject to all of the restrictions upon the President. The Vice President shall perform such other duties and have such other powers as the Board of Directors may from time to time prescribe. The Vice President shall be ex-officio member of all committees except the Fellowship and Nominating Committees. The Vice President shall automatically succeed to the office of President-Elect at the close of the annual meeting at which the current President-Elect's term expires, or as otherwise provided in Section 7.10 below.

Section 7.6 Secretary

The Secretary or its designee shall record the minutes of the meetings of the Society and of the Board of Directors and the Executive Committee; undertake to ensure that all notices of meetings are duly given in accordance with the provisions of these Bylaws or as required by applicable law; be custodian of the corporate records of the Society; and perform all duties incident to the office of Secretary. The Secretary shall be an Ex-Officio member of all committees except the Fellowship and Nominating Committees. The Secretary shall maintain a register of the post office address and electronic mail address of each Fellow of any class, which information shall be furnished to the Secretary by such Fellows. The Secretary shall maintain the correspondence of the Society and a record of the names of the Fellows, guests and visitors in attendance at any meeting of the Society.

Section 7.7 Secretary-Elect

The Secretary-Elect shall assume the duties of the Secretary in the absence of the Secretary or in the event of his or her death, inability or refusal to act. The Secretary-Elect shall perform the duties of the Secretary and when so acting shall have the power of and be subject to all the restrictions upon the Secretary. The Secretary-Elect shall automatically succeed to the office of Secretary at the close of the annual meeting at which the then-current Secretary's term of office expires, or as otherwise provided in Section 7.10 below. The Secretary-Elect shall perform such other duties as from time to time may be assigned to him or her by the President or the Board of Directors.

Section 7.8 Treasurer

The Treasurer shall be in charge and have custody of and be responsible for any and all funds, securities and other valuable assets of the Society and other assets of the Society and shall, at the request of the Board of Directors or as otherwise required by applicable law, post a bond at the expense of the Society for the faithful discharge of his or her duties in such sum and with such surety or sureties as the Board of Directors shall determine. The Treasurer shall oversee accurate accounts of the receipts and disbursements of the Board of Directors in books belonging to it. He or she shall ensure that all monies and other valuable effects are deposited in the name and to the credit of the Board of Directors in such accounts and in such depositories as may be designated by the Board of Directors. He or she shall check monthly the disbursements of funds of the Board of Directors in accordance with authority of the Board of Directors. The Treasurer shall render to the President and the Board of Directors whenever requested or otherwise required, a written detailed account of the transactions and of the financial condition of the Society, including a statement of all its assets, liabilities, and financial transactions. He or she shall perform such other duties as the Board of Directors, through the President, direct, and such other duties as usually pertain to the office of Treasurer. The Treasurer shall be relieved of all responsibility for any securities or monies or the disbursement thereof committed by the Board of Directors to the custody of any other person or the Society, or the supervision of which is delegated by the Board of Directors to any other officer, agent or employee, or for the performance of any other duties of the Treasurer delegated by the Board of Directors to any other officer, agent or employee, and he or she shall not be responsible for any actions of any other officer, agent or employee of the Board of Directors. The Treasurer shall be an Ex-Officio member of all committees except the Membership and Nominating Committees.

Section 7.9 Treasurer-Elect

The Treasurer-Elect shall assume the duties of the Treasurer in the absence of the Treasurer or in the event of his or her death, inability or refusal to act and when so acting shall have the power of and be subject to all restrictions upon the Treasurer. The Treasurer-Elect shall automatically succeed to the office of Treasurer at the close of the annual meeting at which the then-current Treasurer's term of office expires or as otherwise provided in Section 7.10 below. The Treasurer-Elect shall perform such other duties as from time to time may be assigned to him or her by the President or the Board of Directors.

Section 7.10 Vacancies

In the event of the President's death, resignation or removal while in office, the President-Elect shall succeed to the office of President for the remainder of such term and shall continue to serve as President for the immediately succeeding one-year term. In such event, the Vice President shall succeed to the office of President-Elect serving the remainder of such term and shall continue as President-Elect for the immediately succeeding one year term.

In the event of the President-Elect's death, resignation or removal while in office, the Vice President shall succeed to the office of President-Elect for the remainder of such term and shall continue to serve in such office for the immediately succeeding one-year term. The current President shall finish his/her term and will be asked to serve the term originally designated for the President-Elect.

In the event that the Vice President ceases to serve in such office for any reason during his or her term, including, without limitation, by reason of death, resignation or succession to fill a vacancy of the President-Elect as described above, the Board of Directors may (taking into account any recommendations of the Nominating Committee as described in section 9.6 below) appoint a new Vice President to serve the remainder of that term who then becomes President-Elect at the Annual Meeting. In the event the Board of Directors does not appoint a qualified individual to replace the Vice President, a new Vice President shall be elected at the next annual meeting at which officers are elected in accordance with the procedures applicable to the election of officers generally.

In the event of the Secretary's death, resignation or removal while in office with less than six(6) months remaining before the expiration of the term, the immediate past Secretary will be asked to serve the balance of that term and one more additional year. The Secretary-Elect shall then succeed to the office of Secretary for the term for which he or she was originally slated. If the remaining term is greater than six months, then the Secretary-Elect will succeed to become Secretary as originally intended, and the additional year of service by the past Secretary will not be necessary.

In the event of the Secretary-Elect's death, resignation or removal while in office, the Board of Directors shall fill such vacancy as soon as practicable for the unexpired portion of that term and potentially one more year. The Secretary-Elect then becomes Secretary.

In the event of the Treasurer's death, resignation or removal while in office, the immediate past Treasurer will be asked to serve the balance of that term and then one additional year, if the remaining term is less than six months. If the remaining term is greater than six months, the one additional year will not be necessary. The Treasurer -Elect then succeeds to the office of Treasurer considering the above. Following succession of the Treasurer-Elect to the Treasurer, a new Treasurer-Elect is appointed by the Board of Directors as soon as practicable for the same time period.

In the event of the Treasurer-Elect's death, resignation or removal while in office, The Board of Directors will appoint a new Treasurer-Elect for the balance of that term and potentially one more year. This Treasurer-Elect will then become the Treasurer.

In the event of an At-Large Director's death, resignation or removal while in office, The Board of Directors will appoint a new Director in the appropriate category for the balance of that term.

Section 7.11 Resignation/Removal

Any officer may resign from such office at any time by giving written notice to the Secretary of the Society. Any officer may be removed from such office with or without cause by the affirmative vote of at least two-thirds (2/3) vote of the Active Fellows present at a meeting thereof.

ARTICLE VIII COUNCILS

The Society shall establish and maintain four (4) Councils, namely, the Education Council, the Research Council, the Governance Council and the Finance Council, which Councils shall oversee the functions and operations of those committees placed under their respective jurisdiction from time to time by the President with the approval of the Board of Directors. Councils shall function in the same manner and be subject to the same procedures and restrictions as committees of the Society and as may be otherwise determined by the Board of Directors from time to time. The membership of each such Council shall be comprised of the chairpersons of the committees under the jurisdiction of such Council and the President, with the approval of the Board of Directors, shall appoint a chairperson for each such Council from among such Members. The Board of Directors may, at any time, by resolution, create, combine, consolidate and/or terminate any Council and change the composition, terms of membership and any other attribute or aspect of any Council as it deems appropriate in its discretion.



ARTICLE IX COMMITTEES

Section 9.1 Classification and Organization.

There shall be established and maintained the following Standing Committees of the Society:

- (a) Education Committee;
- (b) Fellowship Committee;
- (c) Program Committee;
- (d) Bylaws and Policies Committee; and
- (e) Nominating Committee.

The President, with the approval of the Board of Directors, may from time to time designate other committees (including standing committees in addition to those described above, ad hoc committees and committees existing and operating under any Council), subcommittees, working groups and task forces. All Standing Committees and other committees, subcommittees, working groups and task forces (collectively referred to for purposes of this Article IX as "Committees") shall have the powers and duties as hereinafter set forth and/or other powers and duties delegated or assigned by the President, with the approval of the Board of Directors and shall make regular reports to President and the Board of Directors. All Committee chairpersons shall be appointed by the President, with the approval of the Board of Directors, except as otherwise provided in these Bylaws. Except for the Nominating Committee and the Fellowship Committee and as otherwise provided in these Bylaws, the President, with the approval of the Board of Directors, may determine the number of members to serve on each Committee and the eligibility requirements for same. Members of any such Committee shall be appointed by the President for such terms and on such terms as the President may determine from time to time, with the approval of the Board of Directors. The President, with the approval of the Board of Directors, shall establish such procedures for each Committee as he or she may determine in his or her discretion, with the approval of the Board of Directors. The Board of Directors may, at any time, by resolution, create, combine, consolidate or terminate any Committee (other than a Standing Committee described in subs. (a) through (e), above) as it deems appropriate in its discretion.

Section 9.2 Education Committee

The Education Committee shall be primarily responsible for the education of, dissemination of new information to, and public relations to promote a better understanding of Scoliosis and related spinal deformities including but not limited to availability of treatments and early symptoms of Scoliosis and related spinal deformities.

Section 9.3 Fellowship Committee

The Fellowship Committee shall be responsible for verifying the professional credentials and qualifications of the applicant for Fellowship in any class. All completed applications, except those for Honorary Fellowship, shall be forwarded by the Secretary of the Society to the Fellowship Committee. The Fellowship Committee shall conduct such investigation, personal interviews, or inquiries it deems necessary in order to determine the qualifications of an applicant for Fellowship in any class.

Section 9.4 Program Committee

The Program Committee shall be responsible for the initiation, organization, implementation and conduct of the annual meeting of the Society. The Program Committee shall be responsible to review all papers, exhibits and audiovisual materials to be used in connection with any program or event held in connection with any annual meeting of the Society, subject to such procedures as the Program Committee and the Board of Directors may establish from time to time.

Section 9.5 Bylaws and Policies Committee

The Bylaws and Policies Committee shall be responsible for considering matters relating to the content of the Articles of Incorporation, the Bylaws and the policies and procedures of the Society, including amendments thereto, and to advise and make recommendations to the Board of Directors with respect to same.

Section 9.6 Nominating Committee

The Nominating Committee shall consist of five (5) Active Fellows, the Chairman of which shall be appointed by the President with the approval of the Board of Directors. The four (4) additional members shall be Active Members elected at each annual meeting of the Society by a majority of the Active Members present at such meeting. The term of each member of the Nominating Committee shall be one year, no Fellow may serve two (2) consecutive terms on the Nominating Committee. The Nominating Committee shall present to the Board of Directors a list of nominees as described in Section 7.2 and otherwise provide recommendations to the Board of Directors with respect to the filling of vacancies in any office or on the Board of Directors.

**ARTICLE X
COMPENSATION**

No director, officer, Council or Committee member or any other private individual shall receive at any time any of the net earnings or pecuniary profit from the operations of the Society; provided that this provision shall not prevent the payment to any such person of such reasonable compensation for services rendered to or for the Society in effecting any of its purposes. No such person or persons shall be entitled to share in the distribution of any of the corporate assets upon the dissolution of the Society. Notwithstanding the foregoing, no director, officer or Council or Committee member shall receive compensation from the Society for serving in such capacity; provided, however, the Society may reimburse expenses of such persons in attending meetings and conducting other activities on behalf of the Society. Upon such dissolution or winding up of the affairs of the Society, whether voluntary or involuntary, the assets of the Society, remaining in the hands of the Board of Directors after all debts have been satisfied shall be distributed, transferred, conveyed, delivered, and paid over exclusively to charitable and/or educational organizations which would then qualify under the provisions of Section 501(c)(3) of the Internal Revenue Code and its Regulations as they now exist or as they may hereafter be amended.

**ARTICLE XI
AMENDMENTS**

Amendments to these Bylaws or to the Articles of Incorporation of the Bylaws may be proposed by the Executive Committee, the Board of Directors on its own motion or the written petition of at least four (4) Active Fellows. Any such proposal must be submitted to the Secretary of the Corporation not less than ninety (90) days before an annual meeting of the Society in order to be eligible for consideration of approval at such annual meeting. Such proposed amendment, once submitted to the Secretary, shall be submitted to the Bylaws and Policies Committee for review and consideration, which Committee shall then make a recommendation with respect to same to the Board of Directors. The Board of Directors shall then make a determination regarding whether to submit such proposed amendment to a vote of the Active Fellows. Any proposed amendment submitted to the Secretary for consideration at least ninety (90) days before an annual meeting of the Active Fellows of the Society which the Board of Directors has determined to be submitted to a vote of the Active fellows as described above shall be submitted to the Active Fellows at least 30 days prior to the Annual Meeting at which they will be voted on.

Any such proposed amendment submitted to the Secretary less than ninety (90) days before such annual meeting which the Board of Directors has determined to be submitted to a vote of the Active Fellows shall be eligible to be considered for approval by the Active Fellows at the next subsequent annual meeting or at the discretion of the Board of Directors at a special meeting of the Active Fellows of the Society. The Secretary shall include a copy of the proposed amendment with the notice of the meeting at which such proposed amendment is to be considered for approval, together with a statement that the Board of Directors recommends such amendment for adoption. Any amendment to these Bylaws or the Articles of Incorporation of the Society shall require approval of the Active Fellows by at least a two-thirds (2/3) majority of the Active Fellows present in person at a duly held meeting at which a quorum is present.

**ARTICLE XII
DUES**

Section 12.1 Annual Dues

Annual Dues, in amounts to be determined by the Board of Directors, shall be paid by Candidate Fellows, Active Fellows and Associate Fellows in accordance with such procedures as the Board of Directors may from time to time establish.

Section 12.2 Exemption from Dues

The Board of Directors may, in its discretion, exempt a Fellow of any class from dues for good cause in any particular instance.

**ARTICLE XIII
RULES OF ORDER**

Except to the extent otherwise provided in these Bylaws, all meetings of the Society, the Board of Directors, the Councils or any Committee (as that term is defined in Section 9.1, above) shall, as and when determined by the presiding officer of such body, be governed by the parliamentary rules and usages set forth in the most current edition of Robert's Rules of Order.



ARTICLE XIV DISSOLUTION

The Board of Directors shall, after paying or making provisions for the payment of the Society's liabilities, if any, distribute the Society's net assets, to such Society(s), association(s), fund(s), and/or foundation(s) engaged in activities substantially similar to those of the Society as are designated by the Executive Committee and in such proportions as are determined thereby, subject to any order of court as provided by law, for charitable, educational or scientific purposes within the meaning of section 501(c)(3) of the Code. Notwithstanding any of the foregoing provisions of this Article, the distribution of any assets of the Society in liquidation shall be made in accordance with Illinois Revised Statutes.

ARTICLE XV CONTRACTS, CHECKS, DEPOSITS AND GIFTS

Section 15.1 Contracts

The Board of Directors may authorize any officers, agent or agents of the Society, in addition to the officers so authorized by these Bylaws, to enter into any contract or execute and deliver any instrument in the name of and on behalf of the Society and such authority may be general or confined to specific instances.

Section 15.2 Checks, Drafts, Etc.

All checks, drafts, or other orders for the payment of money notes or other evidence of indebtedness issued to the name of the Society, shall be signed by such officer or officers, agent or agents of the Society and in such manner as shall be determined by action of the Board of Directors.

Section 15.3 Deposits

All funds of the Society shall be deposited to the credit of the Society in banks, trust companies, or other depositories as the Board of Directors may select.

Section 15.4 Gifts

The Board of Directors may accept on behalf of the Society any contribution, gift, bequest or devise for the general purposes or for any special purpose of the Society.

ARTICLE XVI BOOKS AND RECORDS

The Society shall keep and maintain correct and complete books and records of account and shall also keep minutes of the proceedings of any meeting of the Active Members (including any business session), the Board of Directors and any Council or Committees, and shall keep and maintain at the principal office of the Society a record of the names and addresses of Fellows of any class.

ARTICLE XVII FISCAL YEAR

The fiscal year of the Society shall be as determined by the Board of Directors from time to time.

ARTICLE XVIII SEAL

The Society shall have no seal.

**ARTICLE XIX
INDEMNIFICATION**

The Society shall, to the fullest extent provided by applicable law, indemnify every director, officer or Committee (as that term is defined in Section 9.1, above) or Council chair or member, and his or her heirs, executors and administrators who was or is a party or is threatened to be made a party to any threatened, pending or completed action, suit or proceeding, whether civil, criminal, administrative or investigative (other than an action by or in the right of the Society) by reason of the fact that he or she is or was a director, officer, employee or agent of the Society, or is or was serving at the request of the Society, partnership, joint venture, trust or other enterprise against expenses (including attorney's fees), judgements, fines and amounts paid in settlement actually and reasonably incurred by him or her in connection with such action, suit or proceeding if he or she acted in good faith and in a manner he or she reasonably believed to be in or not opposed to the best interests of the Society, and, with respect to any criminal action or proceeding, had no reasonable cause to believe his or her conduct was unlawful. The termination of any action, suit or proceeding by judgement, order, settlement conviction, or upon a plea of nolo contendere or its equivalent, shall not of itself, create a presumption that the person did not act in good faith and in a manner which he/she reasonably believed to be in or not opposed to the best interests of the Society, and with respect to any criminal action or proceeding, had no reasonable cause to believe that his or her conduct was unlawful.

**ARTICLE XX
MISCELLANEOUS**

Section 20.1 Trademarks.

No member may use the Society's name or trademarks for personal, commercial purposes or funding purposes without prior approval of the Board of Directors.

Section 20.2 Interpretation.

In interpreting these Bylaws, whenever the context so requires, (a) the singular shall include the plural and the plural shall include the singular, and (b) any gender shall include all genders.

Section 20.3 Definition of "Code."

All references in these Bylaws to sections of the "Code" shall be considered references to the Internal Revenue Code of 1986, as from time to time amended, and to the corresponding provisions subsequently enacted.

Section 20.4 Headings. T

he headings in these Bylaws are intended for convenience only and should not affect the meaning or interpretation hereof.

Section 20.5 Executive Director.

An Executive Director may be employed directly or by contract by the Board of Directors. The Executive Director shall have general charge of the day-to-day operations and management of the Society. The Executive Director may sign in the name of or on behalf of the Society any contract or agreement authorized by the Board of Directors and shall do and perform such additional duties as may be assigned by the Board of Directors and/or otherwise expressed in a management agreement.

Approved September 6, 2007

GEORGRAPHICAL FELLOWSHIP LIST



SCOLIOSIS RESEARCH SOCIETY



Alabama

BUNCH, Wilton H., Birmingham (EMER)
CONKLIN, Michael Joseph, Birmingham (CAND)
DEINLEIN, Donald A., Birmingham (ACTI)
DEMPSEY, Thomas R., Mobile (ACTI)
DOYLE, John Scott, Birmingham (CAND)
GILBERT, Shawn R., Birmingham (CAND)
HANNON, Kenneth M., Mobile (EMER)
KHOURY, Joseph G., Birmingham (CAND)
KILLIAN, John T., Birmingham (ACTI)
MAYBERRY, Sharon Kay, Birmingham (CAND)
NIMITYONGSKUL, Prasit, Mobile (ACTI)
RANDALL, Fay M., Homewood (EMER)
WEST, James L., Mobile (ACTI)

Alaska

EULE, James M., Anchorage (ACTI)

Argentina

BERSUSKY, Ernesto, Buenos Aires (ACTI)
LEA PLAZA, Carlos A., Salta Capital (EMER)
MAENZA, Ruben Alberto, Buenos Aires (CAND)
PREVIGLIANO, Hugo I., Buenos Aires (EMER)
REINA, Enrique G., Buenos Aires (EMER)
ROSITTO, Victor, Buenos Aires (ACTI)
TELLO, Carlos A., Buenos Aires (ACTI)

Arizona

BRATT, Hank D., Tucson (EMER)
CRANDALL, Dennis G., Mesa (ACTI)
FERGUSON, Ronney L., Pinetop (ACTI)
GINSBURG, Howard H., Phoenix (ACTI)
HAYNES, Richard J., Phoenix (EMER)
HUANG, Robert Po-Chen, Mesa (CAND)
JEONG, Gerard, Tucson (CAND)
KALEN, Vicki, Tucson (ACTI)
KOSTUIK, John P., Phoenix (ACTI)
MARKS, Michelle Claire, Tucson (ASSO)
MAYFIELD, Jack K., Phoenix (EMER)
PALMER, Paul E., Phoenix (EMER)
SHINDELL, Richard L., Phoenix (ACTI)
STEVENS, William R., Phoenix (ACTI)
VINCENT, Kent, Tucson (CAND)

Arkansas

BLASIER, R. Dale, Little Rock (ACTI)
MCCARTHY, Richard E., Little Rock (ACTI)
SAER, Edward H., Little Rock (ACTI)
SCHOCK, Charles C., Little Rock (EMER)

Australia

ASKIN, Geoffrey N., Brisbane (ACTI)
CREE, Andrew K., Sydney (ACTI)
CROCK, Henry V., Toorak (HONO)
LABROM, Robert D., Brisbane (CAND)

MCPHEE, Ian Bruce, Brisbane (EMER)
STEPHEN, John P H, Randwick (EMER)
TAYLOR, T. K. F., St. Leonards (EMER)
TORODE, Ian P., North Melbourne (ASSO)

Austria

BAUER, Rudolf, Mils (EMER)
BEHENSKY, Hannes, Innsbruck (ASSO)
KRISMER, Martin, Grinzens (ACTI)

Belgium

FABRY, Guy M., Pellenberg (EMER)

Brazil

AVANZI, Osmar, Sao Paulo (ACTI)
FERRARETTO, Ivan, Sao Paulo (EMER)
PEDRAS, Claudio V., Rio de Janeiro (EMER)

California

AKBARNIA, Behrooz A., La Jolla (ACTI)
AMINIAN, Afshin, Orange (CAND)
ANAND, Neel, Los Angeles (CAND)
BAGHERI, Ramin, La Jolla (CAND)
BENSON, Daniel R., Sacramento (ACTI)
BERNSTEIN, Robert M., Los Angeles (ACTI)
BERNSTEIN, Saul M., Van Nuys (EMER)
BERVEN, Sigurd H., San Francisco (ACTI)
BHATIA, Nitin, Orange (CAND)
BLACKMAN, Ronald G., Oakland (EMER)
BONNETT, Charles A., Fountain Valley (EMER)
BOOTH, Kevin C., Pleasanton (ACTI)
BOWEN, Richard E., Los Angeles (ACTI)
BRADFORD, David S., San Francisco (EMER)
BROOKS, H. Leon, Beverly Hills (EMER)
BROWN, John Carlisle, Newport Beach (EMER)
BUNNELL, William P., Loma Linda (ACTI)
CAILLIET, Rene, Pacific Palisades (EMER)
CHENG, Ivan, Stanford (CAND)
COE, Jeffrey Dean, Campbell (ACTI)
CORNWALL, G. Bryan, San Diego (ASSO)
D'AMBRA, Phyllis, Los Angeles (ASSO)
DEVIREN, Vedat, San Francisco (CAND)
DIAB, Mohammad, San Francisco (ACTI)
EARLY, Sean D., Santa Barbara (ACTI)
ELLIOTT, Michael J., Madera (ACTI)
ENGLER, Gordon L., Pasadena (EMER)
FARNSWORTH, Christine L., San Diego (CAND)
FLIPPIN, Michael, San Diego (CAND)
FOUNTAIN, Steven S., Laquinta (EMER)
GANOCY, T. Kent, Los Angeles (CAND)
GARDNER, Vance O., Orange (ACTI)
GRAY, John M., Santa Rosa (ACTI)
GUPTA, Munish Chandra, Sacramento (ACTI)
HAGHIGHI, Siavash S., San Diego (ACTI)
HERRON, Larry D., San Luis Obispo (ACTI)



HSU, John D., Downey (EMER)
HU, Serena S., San Francisco (ACTI)
HUNT, Gabriel E., Los Angeles (CAND)
HUNT, Leonel A., Los Angeles (CAND)
JAVIDAN, Nosrat, Newbury Park (ACTI)
JOHNSON, J. Patrick, Los Angeles (CAND)
KAGER, Amy N., San Diego (ASSO)
KAHMANN, Richard D., Santa Barbara (ACTI)
KANEL, Jeffrey S., San Jose (ACTI)
KIM, Choll W., San Diego (CAND)
KINCHEN, Melanie B., Whittier (CAND)
KING, John D., Tarzana (EMER)
KOSTIAL, Patricia N., La Jolla (ASSO)
KULA, Thomas A., Los Gatos (ACTI)
LAURYSEN, Carl, Beverly Hills (CAND)
LERMAN, Joel A., Sacramento (ACTI)
LETTICE, John J., Los Gatos (ACTI)
MAHAR, Andrew Todd, San Diego (ASSO)
MARRERO, Gilbert, Temecula (EMER)
MATTHEWS, Donald K., Granite Bay (CAND)
MELAMED, Hooman M., Marina Del Rey (CAND)
MERMER, Matthew J., Roseville (CAND)
MIRALIAKBAR, Hamid, Los Angeles (CAND)
MONTESANO, Pasquale X., Roseville (ACTI)
MUBARAK, Scott J., San Diego (ACTI)
MUDIYAM, Ram, Fountain Valley (ACTI)
MUMMANENI, Praveen V., San Francisco (CAND)
NEUBUERGER, Christopher O., Sacramento (ASSO)
NEWTON, Peter O., San Diego (ACTI)
PASHMAN, Robert S., Los Angeles (ACTI)
PAWELEK, Jeff, San Diego (ASSO)
PERRY, Jacquelin, Downey (HONO)
PICETTI, George D., Sacramento (ACTI)
POPEJOY, Debra, Los Gatos (CAND)
PURCELL, Graham A., Studio City (EMER)
RAISZADEH, Kamshad, La Jolla (ACTI)
REGAN, John J., Beverly Hills (ACTI)
ROBERTO, Rolando F., Sacramento (ACTI)
ROTH, Kenneth Raymond, Poway (EMER)
SCADUTO, Anthony A., Los Angeles (CAND)
SCHNEIDERMAN, Gary A., Sacramento (ACTI)
SCHOPLER, Steven A., Bakersfield (ACTI)
SHAMIE, Arya Nick, Los Angeles (CAND)
SHIVELY, James L., Oakland (ACTI)
SHOOK, James E., Redlands (ACTI)
SIAMBANES, David, Riverside (CAND)
SILVA, Fernando Emilio, Irvine (CAND)
SKAGGS, David L., Los Angeles (ACTI)
SLABAUGH, Peter B., Piedmont (ACTI)
SUN, Edward C., Burlingame (CAND)
SWANK, Susan M., Torrance (EMER)
TOLO, Vernon T., Los Angeles (ACTI)
TSOU, Paul M., Santa Monica (ACTI)
VAN DAM, Bruce E., La Jolla (ACTI)

WANG, Jeffrey C., Santa Monica (ACTI)
WATKINS, Robert G., Marina Del Rey (CAND)
WENGER, Dennis R., San Diego (ACTI)
WHIFFEN, John R., Malibu (EMER)
YASZAY, Burt, San Diego (CAND)

Canada

ALMAN, Benjamin A., Toronto (ACTI)
ARMSTRONG, Gordon W. D., Ottawa (EMER)
ASHWORTH, M. Anthony, Kingston (EMER)
AUBIN, Carl-Eric, Montreal (ACTI)
BAILEY, Stewart I., London (EMER)
DANSEREAU, Jean, Montreal (ACTI)
DUHAIME, Morris A., Montreal (EMER)
EDWARDS, Glen E., Calgary (EMER)
EL-HAWARY, Ron, Halifax (CAND)
GOYTAN, Michael J., Winnipeg (ACTI)
GURR, Kevin R., Denfield (ACTI)
HEDDEN, Douglas M., Edmonton (ACTI)
HOWARD, Andrew, Toronto (CAND)
JARVIS, James G., Ottawa (ACTI)
KUNKEL, Melvin G., Victoria (EMER)
LABELLE, Hubert, Montreal (ACTI)
LETOURNEAU, Ernest G., Ottawa (HONO)
LETTS, R. Mervyn, Ottawa (EMER)
LEWIS, Stephen J., Toronto (ACTI)
MAC-THIONG, Jean-Marc, Montreal (CAND)
MOREAU, Marc J., Edmonton (ACTI)
OUELLET, Jean A., Montreal (ACTI)
PARENT, Stefan, Saint-Lambert (CAND)
POITRAS, Benoit P., Montreal (ACTI)
RASO, V. James, Edmonton (ASSO)
REILLY, Christopher W., Vancouver (CAND)
RIVARD, Charles H., Montreal (ACTI)
TREDWELL, Stephen J., Vancouver (EMER)
VIVIANI, Guillermo R., Hamilton (EMER)
ZELLER, Reinhard D., Toronto (ACTI)

Colorado

AGARWALA, Amit O., Golden (CAND)
BENEFIELD, Elise M., Aurora (ASSO)
BESS, R. Shay, Lone Tree (CAND)
BROWN, Courtney W., Golden (ACTI)
BURGER, Evalina L., Aurora (ACTI)
DONALDSON, David H., Golden (EMER)
DWYER, Anthony P., Denver (EMER)
ERICKSON, Mark A., Aurora (ACTI)
GEBHARD, James S., Grand Junction (ACTI)
JAMRICH, Eric R., Lone Tree (ACTI)
KUMAR, Anant, Lone Tree (CAND)
MILLER, Nancy Hadley, Aurora (ACTI)
MUFF, Barbara J., Golden (ASSO)
ODOM, John A., Lone Tree (EMER)
PATEL, Vikas V., Aurora (CAND)

STANLEY, Scott K., Lone Tree (CAND)
VAN BUSKIRK, Cathleen S., Boulder (ACTI)
WONG, Douglas C., Golden (ACTI)

Connecticut

BANTA, John V., West Hartford (EMER)
GRAUER, Jonathan N., New Haven (CAND)
PAONESSA, Kenneth J., North Franklin (ACTI)
SIMON, Scott L., Stamford (CAND)
SMITH, Brian G., New Haven (ACTI)
THOMSON, Jeffrey D., Hartford (ACTI)
WIJESEKERA, Shirvinda, New Haven (CAND)

Delaware

GABOS, Peter G., Wilmington (CAND)
JAYAKUMAR, Shanmuga, Wilmington (EMER)
MILLER, Freeman, Wilmington (ACTI)
SHAH, Suken A., Wilmington (ACTI)

District of Columbia

BLAKEMORE, Laurel C., Washington (ACTI)
LAUERMAN, William C., Washington (ACTI)

Egypt

EL HAWARY, Youssry M.K., Cairo (ACTI)
EL MILIGUI, Yasser Hassan Samir, Geiza, (CAND)
ELSEBAIE, Hazem B., Giza (CAND)
KOPTAN, Wael, Geiza (CAND)
MOSSAAD, Mohammed Mostafa, Helmeit Al Zaytoon (CAND)

Finland

SCHLENZKA, Dietrich K A, Helsinki (ASSO)
YRJONEN, Timo A., Helsinki (ASSO)

Florida

ASHBERG, Lyall, Melbourne (CAND)
BURKE, Stephen W., Tavernier (EMER)
CAWLEY, Toni, Cutler Bay (ASSO)
CLARK-SHUFFLEBARGER, Cynthia, Coral Gables (ASSO)
CRONEN, Geoffrey Alan, Tampa (CAND)
CUMMINGS, R. Jay, Jacksonville (ACTI)
DAVIS, Gerald L., Naples (EMER)
EISMONT, Frank J., Miami (ACTI)
ENGUIDANOS, Stephen T., Niceville (CAND)
FLYNN, Joseph C., Orlando (EMER)
GILLINGHAM, Bruce L., Portsmouth (ACTI)
GROGAN, Dennis P., Tampa (ACTI)
HARDY, James H., Fort Myers (EMER)
HEPLER, Matthew D., Vero Beach (ACTI)
HERRERA-SOTO, Jose A., Orlando (CAND)
HYNES, Richard A., Melbourne (ACTI)
JOFE, Michael, Hollywood (ACTI)
KAMBACH, Brandon J., Jacksonville (CAND)
KEIM, Hugo A., Odessa (EMER)
KELLER, Paul M., Melbourne (ACTI)

KNAPP, Dennis Raymond, Orlando (ACTI)
LEBWOHL, Nathan H., Miami (ACTI)
LIEBERMAN, Isador H., Weston (ACTI)
LOVELESS, Eric A., Jacksonville (CAND)
MANZANARES, James B.Sandoval, Naples (CAND)
MASON, Dan E., Tampa (ACTI)
MCBRIDE, G. Grady, Winter Park (ACTI)
MCCOLLOUGH, Newton C., Longboat Key (EMER)
MORENO, Anthony P., Safety Harbor (ACTI)
NEUSTADT, Jeffrey B., Saint Petersburg (ACTI)
O'BRIEN, Michael F., Miami (ACTI)
PHILLIPS, Jonathan H., Orlando (ACTI)
PRICE, Charles T., Orlando (ACTI)
RIDDICK, Max F., Winter Springs (EMER)
SACKS, Janice T., Boca Raton (HONO)
SACKS, Stanley E., Boca Raton (HONO)
SHUFFLEBARGER, Harry L., Miami (ACTI)
SILVERMAN, Barry J., Aventura (EMER)
TALL, Reginald L., Winter Park (ACTI)
WEISS, Leonard S., Wellington (EMER)
WESTPHAL, Reinhard A W, Marco Island (EMER)
WINGO, Charles H., Tallahassee (ACTI)

France

CHAROSKY, Sebastien, Berk Sur Mer (CAND)
CHOPIN, Daniel Henri, Berck Sur Mer (ACTI)
COTREL, Yves, Paris (HONO)
DIMEGLIO, Alain, Giraud (HONO)
DUBOUSSET, Jean, Paris (EMER)
LE HUEC, Jean-Charles, Bordeaux (CAND)
PASSUTI, Norbert, Nantes (ACTI)
PICAULT, Charles, Lyon (EMER)
ROUSSOULY, Pierre, Lyon (CAND)
VITAL, Jean Marc, Bordeaux Cedex (CAND)

Georgia

BAILEY, Thomas E., Augusta (ACTI)
BURKUS, John Kenneth, Columbus (ACTI)
FACKLER, Carl D., Atlanta (EMER)
HORTON, William C., Atlanta (ACTI)
JAMES, Stephen B., Cumming (ACTI)
LOVELL, Wood W., Saint Simons Island (EMER)
MALCOLM, James R., Marietta (ACTI)
MEEHAN, Peter L., Roswell (ACTI)
OSWALD, Timothy Stephen, Atlanta (CAND)
SCHMITT, E. William, Atlanta (EMER)
SCHMITZ, Michael L., Atlanta (CAND)
WHITESIDES, Thomas E., Atlanta (EMER)

Germany

BIEDERMANN, Lutz, VS-Schwenningen (ASSO)
HALM, Henry F.H., Neustadt (ACTI)
HARMS, Jurgen, Karlsbad (HONO)
LETKO, Lynn Juliana, Karlsbad (CAND)
LILJENQVIST, Ulf R., Münster (ASSO)



NIEMEYER, Thomas, Tubingen (CAND)
RUF, Michael, Suhl (CAND)
SPRINGORUM, Hans-Werner, Bad Mergentheim (ASSO)
ZIELKE, Klaus, Bad Wildungen (EMER)

Greece

GRIVAS, Theodoros B., Athens (ACTI)
KOROVESSIS, Panagiotis, Patras (ACTI)
PLOUMIS, Avraam, Thessaloniki (CAND)
SMYRNIS, Panayotis, Athens (EMER)
SOUCACOS, Panayotis K., Vrillisia Athens (ASSO)
SOUCACOS, Panayotis N., Athens (EMER)

Hawaii

JONES, Donald A., Honolulu (EMER)
RANEY, Ellen M., Honolulu (ACTI)
RAY, R. Charles, Waikoloa (EMER)

Hong Kong

CHENG, Jack C.Y., Shatin (ASSO)
CHEUNG, Kenneth M C, Hong Kong (ACTI)
LEONG, John C Y, Homantin (EMER)
LUK, Keith D K, Hong Kong (ASSO)
WONG, Yat Wa, Hong Kong (CAND)
YAU, Arthur, Hong Kong (EMER)

Hungary

ILLES, Tamas, Pecs (ACTI)

Idaho

FLOYD, Charles Timothy, Boise (CAND)
KING, Howard A., Boise (ACTI)
MONTALBANO, Paul J., Boise (CAND)
SHEA, Kevin G., Boise (ACTI)
VERSKA, Joseph M., Meridian (ACTI)

Illinois

AN, Howard S., Chicago (ACTI)
BERGIN, Christopher, Glenview (ACTI)
BERNSTEIN, Avi J., Park Ridge (ACTI)
BUECHE, Matthew J., Naperville (ACTI)
DEWALD, Christopher J., Chicago (ACTI)
DEWALD, Ronald L., Lake Forest (EMER)
FISK, John R., Springfield (EMER)
GABRIEL, Keith R., Springfield (CAND)
GANJU, Aruna, Chicago (CAND)
GAVIN, Thomas M., Burr Ridge (ASSO)
GRAYHACK, John G., Chicago (ACTI)
GUPTA, Purnendu, Chicago (ACTI)
HAMMERBERG, Kim W., Chicago (ACTI)
HARLEY, Kathleen M., Chicago (ASSO)
HARMS, James J., Urbana (ACTI)
IBRAHIM, Kamal N., Oakbrook Terrace (ACTI)
KARAIKOVIC, Eldin E., Chicago (ACTI)
KING, Erik C.B., Chicago (CAND)
KOLAVO, Jerome L., Warrenville (ACTI)

KOSKI, Tyler, Chicago (CAND)
KOZINSKI, Angela, Chicago Heights (ASSO)
LORENZ, Mark A., Hinsdale (ACTI)
MARDJETKO, Steven M., Morton Grove (ACTI)
MEKHAIL, Anis, Palos Heights (CAND)
MIZ, George S., Oak Lawn (ACTI)
MULCONREY, Daniel S., Peoria (CAND)
NOCKELS, Russ P., Maywood (CAND)
ONDRA, Stephen L., Chicago (CAND)
PHILLIPS, Frank M., Chicago (CAND)
RINELLA, Anthony S., Maywood (ACTI)
RODTS, Mary Faut, Chicago (ASSO)
ROH, Michael S., Rockford (ACTI)
SALEHI, Sean, Maywood (CAND)
SARWARK, John F., Chicago (ACTI)
SCHAFER, Michael F., Chicago (EMER)
SOKOLOWSKI, Mark J., Oak Park (CAND)
SPENCER, David L., Park Ridge (EMER)
STURM, Peter F., Chicago (ACTI)
SWEET, Fred A., Rockford (ACTI)
ZINDRICK, Michael R., Hinsdale (ACTI)

India

BASU, Saumyajit, Kolkata (CAND)
JOHARI, Ashok, Mahim (ACTI)
RAJASEKARAN, S., Coimbatore (CAND)
VOLETI, Surya Prakash Rao, Abids Hyderabad (CAND)

Indiana

COSCIA, Michael F., Indianapolis (ACTI)
DIETZ, John W., Indianapolis (ACTI)
GORUP, John M., Lafayette (ACTI)
HARDACKER, James W., Carmel (ACTI)
HOFFMAN, Gregory A., Fort Wayne (ACTI)
HULER, Robert J., Indianapolis (ACTI)
KLING, Thomas F., Indianapolis (EMER)
LINDSETH, Richard E., Indianapolis (EMER)
LODER, Randall T., Indianapolis (ACTI)
LUBICKY, John P., Indianapolis (ACTI)
RAHN, Kevin A., Fort Wayne (ASSO)
RAPP, George F., Indianapolis (EMER)
RIINA, Joseph, Indianapolis (ACTI)
SASSO, Rick C., Indianapolis (ACTI)
SCHWARTZ, David G., Indianapolis (CAND)
SHEPHERD, Elian M., Merrillville (ACTI)
TRAMMELL, Terry R., Pittsboro (ACTI)

Iowa

CHAPMAN, Michael Paul, Dubuque (ACTI)
DOLAN, Lori, Iowa City (ASSO)
PONSETI, Ignacio V., Iowa City (EMER)
WEINSTEIN, Stuart L., Iowa City (ACTI)

Iran

GANJAVIAN, Mohammad S., Tehran (ACTI)
HABIBOLLAH ZADEH, Parviz, Teran (CAND)
SADAT, Seyed Mir Mostafa, Tehran (ACTI)

Ireland

DOWLING, Frank, Dublin (ASSO)
MCMANUS, Frank, Dublin (EMER)

Israel

FLOMAN, Yizhar, Tel Aviv (EMER)
OVADIA, Dror, Tel Aviv (ACTI)
SIEGAL, Tzony, Tel Aviv (EMER)

Italy

BALSANO, Massimo, Schio (CAND)
BASSANI, Roberto, Pavia (CAND)
BRAYDA-BRUNO, Marco, Milano (ACTI)
DI SILVESTRE, Mario, Bologna (CAND)
FABRIS-MONTERUMICI, Daniele A., Padova (ACTI)
LOGROSCINO, Carlo A., Roma (ASSO)
MARCHETTI, Pier Giorgio, Bologna (EMER)
MURA, Pierpaolo, Quarto Sant Elena (CAND)
PARISINI, Patrizio, Bologna (ACTI)
PONTE, Alberto, Roma (ACTI)
SICCARDI, Gianluigi Luigi, Finale Ligure (ACTI)

Japan

ABUMI, Kuniyoshi, Sapporo (ACTI)
AOKI, Haruhito, Kawasaki (ACTI)
ASAZUMA, Takashi, Tokorozawa (CAND)
HASEGAWA, Kazuhiro, Niigata (CAND)
HASEGAWA, Kyoichi, Toyohira-ku Sapporo (CAND)
HIRAIZUMI, Yutaka, Tokyo (ACTI)
INOUE, Masatoshi, Narashino (CAND)
KANEDA, Kiyoshi, Shiroishi-ku, Sapporo (EMER)
KAWAKAMI, Noriaki, Nagoya (ACTI)
KITAHARA, Hiroshi, Narashino (ASSO)
KUMANO, Kiyoshi, Kawasaki (EMER)
MACHIDA, Masafumi, Tokyo (ACTI)
MARUYAMA, Toru, Kawagoe, Saitama (CAND)
MATSUMOTO, Manabu, Ono (ASSO)
MOCHIDA, Joji, Isehara (ACTI)
NAKAKOHJI, Taku, Tokyo (ACTI)
NAKANO, Noboru, Sapporo (EMER)
NAKATA, Yoshinori, Chiba (ACTI)
NOHARA, Yutaka, Tokyo (ACTI)
OHKI, Isao, Ibaraki-Ken (EMER)
ONOMURA, Toshinobu, Hyogo (EMER)
SASAO, Yutaka, Kawasaki (CAND)
SATAKE, Kotaro, Hamamatsu (CAND)
SHIBA, Ritsu, Shizuoka City (ASSO)
SHIMIZU, Katsuji, Gifu (CAND)
SUZUKI, Nobumasa, Tokyo (ACTI)
TAKEMITSU, Yoshiharu, Oita (EMER)

TAKESHITA, Katsushi, Bunkyo-ku (CAND)
TANEICHI, Hiroshi, Shimotsugagun (CAND)
TSUJI, Taichi, Nagoya, Aichi (CAND)
UNO, Koki, Kobe (CAND)
WATANABE, Kei, Niigata (CAND)
WATANABE, Kota, Tokyo (CAND)
YAMAMOTO, Hiroshi, Nankoku, Kochi (EMER)

Kansas

ADLER, Federico, Shawnee Mission (EMER)
ASHER, Marc A., Kansas City (EMER)
BERNHARDT, Mark, Leawood (ACTI)
BURTON, Douglas C., Kansas City (ACTI)
MOSKOWITZ, Alan, Wichita (ACTI)
WHITAKER, Camden, Wichita (CAND)

Kentucky

CAMPBELL, Mitchell J., Louisville (ACTI)
DIMAR, John R., Louisville (ACTI)
DJURASOVICH, Mladen, Louisville (CAND)
GLASSMAN, Steven D., Louisville (ACTI)
HOLT, Richard T., Louisville (ACTI)
IWINSKI, Henry J., Lexington (ACTI)
JOHNSON, John R., Louisville (ACTI)
MAJD, Mohammad E., Louisville (ACTI)
MILBRANDT, Todd, Lexington (CAND)
PUNO, Rolando M., Louisville (ACTI)
STEVENS, David B., Lexington (EMER)
TALWALKAR, Vishwas R., Lexington (ACTI)
TYLKOWSKI, Chester M., Lexington (ACTI)
VAUGHAN, John J., Lexington (ACTI)

Lebanon

KHARRAT, Khalil, Beirut (ACTI)

Louisiana

ASHMAN, Richard B., New Orleans (ASSO)
BENNETT, James T., New Orleans (ACTI)
DEAN, A. Edward, Shreveport (EMER)
ISAZA, Jorge E., Baton Rouge (ACTI)
KING, Andrew G., New Orleans (ACTI)
MCCALL, Richard E., Shreveport (ACTI)
RICCIARDI, James E., New Orleans (ACTI)

Maine

ANSON, Philip S., Falmouth (CAND)
KELLER, Robert B., Scarborough (EMER)
ROBERTS, John M., Blue Hill (EMER)
TURI, Mario, Rockport (ACTI)

Malaysia

SINGH, Harwant, Kajang (ACTI)

Maryland

AIN, Michael C., Baltimore (ACTI)
ANTONIADES, Spiro B., Baltimore (ACTI)



ASDOURIAN, Paul L., Baltimore (ACTI)
COHEN, David B., Hunt Valley (CAND)
CUNNINGHAM, Bryan W., Towson (ACTI)
EDWARDS, Charles C., Baltimore (ACTI)
EDWARDS, Charles Cannon, Baltimore (ACTI)
GELB, Daniel E., Timonium (ACTI)
GOKASLAN, Ziya, Baltimore (CAND)
KEBAISH, Khaled, Baltimore (CAND)
LEHMAN, Ronald A., Potomac (CAND)
LEVINE, Alan Marc, Baltimore (ACTI)
MCAFEE, Paul C., Sparks (ACTI)
MCDONNELL, Edmond J., Phoenix (EMER)
OWEN, Jeffrey H., Cockeysville (ACTI)
RILEY, Lee H., Baltimore (ACTI)
ROSNER, Michael, Silver Spring (CAND)
SANCHEZ, Alvaro A., Colesville (EMER)
SPONSELLER, Paul D., Baltimore (ACTI)
TIS, John, Olney (CAND)
TORTOLANI, P. Justin, Towson (CAND)

Massachusetts

ALBRIGHT, Maurice, Boston (CAND)
BRAUN, Stuart V., Boston (CAND)
BROWN, Desmond T., Boston (ACTI)
CONNOLLY, Patrick J., Worcester (ACTI)
EMANS, John B., Boston (ACTI)
GLAZER, Paul A., Chestnut Hill (ACTI)
HALL, John E., Brookline (EMER)
HEDEQUIST, Daniel J., Boston (ACTI)
HRESKO, Michael Timothy, Boston (ACTI)
KARLIN, Lawrence I., Boston (ACTI)
LAPP, Mark A., Lowell (ASSO)
MASSO, Peter D., Springfield (ACTI)
MILLIS, Michael B., Boston (ACTI)
O'BRIEN, Joseph P., Stoughton (HONO)
PARAZIN, Stephen J., Chestnut Hill (CAND)
RAND, Frank F., Boston (ACTI)
SNYDER, Brian D., Boston (ACTI)
WHITE, Augustus A., Boston (EMER)
WOOD, Kirkham B., Boston (ACTI)
WRIGHT, Alexander M., Chestnut Hill (EMER)
ZIMBLER, Seymour, Boston (EMER)

Mexico

CARDOSO, Alfredo, Coyoacan (ASSO)
MONTALVO, Francisco, Mexico DF (ASSO)
ORELLANA RETA, Carlos A., Mexico City (ASSO)
PEON-VIDALES, Hector, Mexico City (EMER)

Michigan

CAIRD, Michelle S., Ann Arbor (CAND)
CALDER, Howard B., Ann Arbor (CAND)
FARLEY, Frances A., Ann Arbor (ACTI)
GEIGER, Douglas Farrell, Ypsilanti (ACTI)
HENSINGER, Robert N., Ann Arbor (EMER)

JONES, Eric T., Detroit (ACTI)
KASTEN, Michael D., Kalamazoo (ACTI)
LA MARCA, Frank, Ann Arbor (CAND)
LAMONT, Richard L., Novi (EMER)
LEE, Stanley S., Jackson (CAND)
MAYER, Philip J., Plymouth (ACTI)
MENDELOW, Michael J., Novi (ACTI)
MONTGOMERY, David M., Royal Oak (ACTI)
MORRISON, Daniel L., Garden City (ASSO)
REYNOLDS, Richard A K, Detroit (ACTI)
ROTH, Herbert J., Troy (ACTI)
ROWE, Dale E., Kalamazoo (ACTI)
SONGER, Matthew N., Marquette (ACTI)
SOUTHERN, Edward P., Marquette (ACTI)
VANDERHAVE, Kelly, Ann Arbor (CAND)
WRIGHT, Bettye A., Rochester (EMER)
YASSIR, Walid K., Detroit (CAND)

Minnesota

BARTIE, Bruce J., Stillwater (ACTI)
BUTTERMANN, Glenn Robin, Mahtomedi (ACTI)
CARLSON, J. Martin, Blaine (ASSO)
DEKUTOSKI, Mark B., Rochester (ACTI)
DENIS, Francis, Minneapolis (ACTI)
DYKES, Daryll C., Minneapolis (CAND)
GARVEY, Timothy A., Minneapolis (ACTI)
HSU, Brian, Minneapolis (CAND)
HUDDLESTON, Paul M., Rochester (CAND)
KANE, William J., Minneapolis (EMER)
KETTLESON, David N., Crosslake (EMER)
KLASSEN, Rudolph A., Rochester (EMER)
KOOP, Steven E., St Paul (ACTI)
LONSTEIN, John E., Minneapolis (ACTI)
LUEDTKE, Lael M., Saint Paul (CAND)
MEHBOD, Amir A., Minneapolis (CAND)
MOON, Wendy, Rochester (ASSO)
NOVACHECK, Tom F., St Paul (ACTI)
PERRA, Joseph H., Minneapolis (ACTI)
PETERSON, Hamlet A., Rochester (EMER)
POLLY, David W., Minneapolis (ACTI)
ROSE, Peter S., Rochester (CAND)
SCHWENDER, James D., Edina (ACTI)
SHAUGHNESSY, William J., Rochester (ACTI)
SINICROPI, Stefano M., Stillwater (CAND)
SMITH, Michael D., Edina (ACTI)
STANS, Anthony A., Rochester (ACTI)
SURATWALA, Sanjeev, Minneapolis (CAND)
SWANSON, Andrew Nicholas, Mankato (CAND)
TRANSFELDT, Ensor E., Minneapolis (ACTI)
WINTER, Robert B., St Paul (EMER)
YASZEMSKI, Michael J., Rochester (ACTI)

Mississippi

HABER, Lawrence L., Jackson (ACTI)
WEIERMAN, Robert J., Gulfport (EMER)

Missouri

ALANDER, Dirk H., Saint Louis (ACTI)
BASSETT, George S., St. Louis (ACTI)
BLANKE, Kathy M., St Louis (ASSO)
BRIDWELL, Keith H., St Louis (ACTI)
BUCHOWSKI, Jacob M., Saint Louis (CAND)
CHOMA, Theodore J., Columbia (ACTI)
DOBBS, Matthew Barrett, St. Louis (ACTI)
EBELKE, David K., N Kansas City (ACTI)
GAINES, Robert W., Columbia (ACTI)
JACKSON, Roger P., North Kansas City (ACTI)
KUKLO, Timothy R., Saint Louis (ACTI)
LENKE, Lawrence G., St. Louis (ACTI)
LUHMANN, Scott John, Saint Louis (CAND)
PLACE, Howard M., St Louis (ACTI)
POURQUIE, Olivier, Kansas City (ASSO)
PRICE, Nigel J., Kansas City (ACTI)
RIEW, K. Daniel, Saint Louis (ACTI)
SCHWEND, Richard M., Kansas City (ACTI)

Nebraska

FULLER, Jonathan E., Omaha (ACTI)
GINSBURG, Glen M., Omaha (ACTI)
HASLEY, Brian P., Omaha (CAND)
LONGLEY, Michael C., Omaha (ACTI)
MCCLELLAN, John W., Omaha (ACTI)
WOODWARD, H. Randal, Omaha (ACTI)

Netherlands

BEEN, Henk D., Amsterdam (ASSO)
DE GRUIJTER, A. J., Alkmaar (ASSO)
DE KLEUVER, Marinus, Nijmegen (ACTI)
GEUKERS, Charles W G M, Nuenen (ASSO)
PAVLOV, Paul W., Nijmegen (ACTI)
SLOT, Gerard H., Nijmegen (EMER)
VAN LOON, Piet J M, Arnhem (ASSO)
VAN OOIJ, Andre, Maastricht (ASSO)
VERAART, Ben E., Hilversum (EMER)

Nevada

BARRY, Mark A., Las Vegas (CAND)
CAMP, Jonathan F., Las Vegas (ACTI)
MCNULTY, Patrick S., Las Vegas (ACTI)

New Hampshire

CLARK, Davis W., Concord (EMER)
SENGUPTA, Dilip K., Lebanon (ACTI)
WAUGH, Theodore R., Lebanon (EMER)
WEINSTEIN, James N., Lebanon (ACTI)

New Jersey

ANTONACCI, M. Darryl, Lawrenceville (ACTI)
BOWE, John Andrew, East Brunswick (CAND)
CARUSO, Steven A., Newark (ASSO)
CLEMENTS, David H., Camden (ACTI)
EMAMI, Arash, Wayne (ACTI)
FERNAND, Robert, Wayne (ACTI)
HARROP, James S., Moorestown (CAND)
HEARY, Robert F., Newark (CAND)
HWANG, Ki Soo, Wayne (CAND)
JACOBS, George B., South Hackensack (EMER)
RIEGER, Mark A., Cedar Knolls (ACTI)
SABHARWAL, Sanjeev, Newark (ACTI)

New Mexico

BOSCH, Patrick, Albuquerque (CAND)
EBERLE, Charles F., Albuquerque (EMER)
ELLIS, Oren H., Santa Fe (EMER)
HOEKSTRA, Dale V., Albuquerque (ACTI)
SHERMAN, Frederick C., Albuquerque (EMER)

New York

ALBANESE, Stephen A., Syracuse (ACTI)
ALONGI, Paul Robert, Melville (ACTI)
ANGEVINE, Peter D., New York (CAND)
BENDO, John A., New York (ACTI)
BITAN, Fabien D., New York (ACTI)
BLANCO, John S., New York (ACTI)
BOACHIE-ADJEL, Oheneba, New York (ACTI)
CALANCIE, Blair, Syracuse (ASSO)
CAMMISA, Frank P., New York (ACTI)
CARL, Allen L., Albany (ACTI)
CARRION, Wesley V., Stony Brook (ACTI)
CASDEN, Andrew M., New York (ACTI)
CUNNINGHAM, Matthew E., New York (CAND)
DEVANNY, John R., Rochester (EMER)
ERRICO, Thomas J., New York (ACTI)
FARCY, Jean-Pierre C., New York (ACTI)
FELDMAN, David S., New York (ACTI)
FREDRICKSON, Bruce E., Manlius (EMER)
GIRARDI, Federico P., New York (ACTI)
GOLDSTEIN, Jeffrey A., New York (CAND)
GREEN, Daniel W., New York (ACTI)
HAAKE, P. William, Scottsville (EMER)
HAHER, Thomas R., Syracuse (ACTI)
HAMILL, Christopher L., Buffalo (ACTI)
HOLMBLAD, James E., Schenectady (EMER)
HOPPFELD, Stanley, Scarsdale (EMER)
HUCKELL, Cameron B., Buffalo (ACTI)
JACKMAN, Kenneth V., Rochester (EMER)
KIM, Yongjung J., New York (CAND)
KUFLIK, Paul L., New York (ACTI)
LABIAK, John J., Smithtown (ACTI)
LEVINE, David B., Pine Plains (EMER)



LONNER, Baron S., New York (ACTI)
MARGULIES, Joseph Y., Pleasantville (ACTI)
MCCANCE, Sean E., New York (ACTI)
MERMELSTEIN, Laurence E., Commack (CAND)
MEROLA, Andrew A., New York (ACTI)
MOLINARI, Robert W., Rochester (ACTI)
MOQUIN, Ross, Syracuse (CAND)
MOSKOVICH, Ronald, New York (ACTI)
MOULTON, Andrew W., Hawthorne (CAND)
NEUWIRTH, Michael G., New York (ACTI)
OLAVERRI, Juan Carlos Rodriguez, Brooklyn (CAND)
O'LEARY, Patrick F., New York (ACTI)
OLSEWSKI, John M., Bronx (ACTI)
RAGGIO, Cathleen L., New York (ACTI)
RAWLINS, Bernard A., New York (ACTI)
RECHTINE, Glenn R., Rochester (ACTI)
ROYE, David Price, New York (ACTI)
RUBERY, Paul T., Rochester (ACTI)
SANDERS, James O., Rochester (ACTI)
SCHWAB, Frank J., New York (ACTI)
SIMMONS, Edward D., Buffalo (ACTI)
SIMMONS, Edward H., Buffalo (EMER)
SPIRA, Irvin A. S., Great Neck (ACTI)
SPIVAK, Jeffrey M., New York (ACTI)
STIEBER, Jonathan R., New York (CAND)
TADDONIO, Rudolph F., White Plains (ACTI)
TEBOR, Gary B., Rochester (ACTI)
ULIN, Richard I., New York (EMER)
VARMA, Vikas V., New York (CAND)
VITALE, Michael G., New York (CAND)
WALLACH, David M., East Setauket (CAND)
WEIDENBAUM, Mark, New York (ACTI)
WIDMANN, Roger F., New York (ACTI)
WOLPIN, Martin E., Brooklyn (EMER)
YUAN, Hansen A., Syracuse (EMER)

New Zealand

BARNES, Michael J., Auckland (ACTI)
FERGUSON, John A I, Auckland (CAND)
HODGSON, Bruce F., Dunedin (ACTI)
NICHOLSON, O. Ross, Auckland (EMER)

North Carolina

BRIGHAM, Craig D., Charlotte (ACTI)
CAUDLE, Robert J., Raleigh (ACTI)
CHEWNING, Samuel J., Statesville (ACTI)
COONRAD, Ralph W., Durham (EMER)
DARDEN, Bruce V., Charlotte (ACTI)
DEROSA, G. Paul, Chapel Hill (EMER)
FITCH, Robert D., Durham (ACTI)
GEISSELE, Alfred E., Hickory (ACTI)
GOOCH, Hubert Lee, Statesville (CAND)
HARDAKER, William T., Durham (ACTI)
HEY, Lloyd A., Raleigh (CAND)

MCGOWEN, Timothy W., Winston Salem (ACTI)
MINCHEW, Joe T., Durham (ACTI)
MURREY, Daniel Beasley, Charlotte (CAND)
NASCA, Richard J., Wilmington (EMER)
SHILT, Jeffrey Scott, Winston Salem (CAND)
SUH, Paul B., Chapel Hill (ACTI)
WATTENBARGER, John Michael, Charlotte (ACTI)

Ohio

ALBERT, Michael C., Dayton (ACTI)
ARMSTRONG, Douglas G., Cleveland (ACTI)
BETHEM, Daniel, Akron (EMER)
BYLSKI-AUSTROW, Donita I., Cincinnati (CAND)
CRAWFORD, Alvin H., Cincinnati (ACTI)
DO, Twee Thi, Cincinnati (CAND)
DURRANI, Abubakar A., Cincinnati (CAND)
FUREY, Christopher G., Cleveland (CAND)
GOODWIN, Ryan C., Cleveland (CAND)
KAHN, Alfred, Cincinnati (ACTI)
KUNTZ, Charles D., Cincinnati (CAND)
LEHNER, James T., Dayton (ACTI)
MEHLMAN, Charles T., Cincinnati (ACTI)
MILLER, Scot D., Akron (ACTI)
NASH, Clyde Lester, Gates Mills (EMER)
PEELLE, Michael W., Beavercreek (CAND)
PERLMAN, Aaron W., Cincinnati (EMER)
POE-KOCHERT, Connie, Cleveland (ASSO)
ROHMILLER, Michael T., Cincinnati (CAND)
SON-HING, Jochen P., Cleveland (CAND)
STAMBOUGH, Jeffery L., Cincinnati (ACTI)
SWANK, Michael L., Cincinnati (ASSO)
THOMPSON, George H., Cleveland (ACTI)
WALL, Eric J., Cincinnati (ACTI)
WILHAM, Marianne R., Cleveland (EMER)

Oklahoma

DAVEY, Joseph P., Oklahoma City (CAND)
DEVLIN, Vincent J., Oklahoma City (CAND)
GROSS, Worth Miller, Tulsa (EMER)
HERNDON, William A., Edmond (ACTI)
L'HEUREUX, E. Alexander, Edmond (ACTI)
PHILLIPS, Preston J., Tulsa (ACTI)
PUFFINBARGER, William Ray, Oklahoma City (CAND)
WIENECKE, Robert, Oklahoma City (CAND)
WRIGHT, Michael H., Oklahoma City (ACTI)

Oregon

ANTEZANA, David Fernando, Portland (CAND)
CARR, William A., West Linn (EMER)
D'AMATO, Charles R., Portland (ACTI)
HALSEY, Matthew F., Portland (CAND)
HART, Robert A., Portland (CAND)
KEENEN, Timothy L., Tualatin (ACTI)
KRAJBICH, J. Ivan, Portland (ACTI)

Panama

DUBOIS, Alfredo, Panama City (EMER)

Pennsylvania

ALBERT, Todd J., Philadelphia (ACTI)
BALDERSTON, Richard A., Philadelphia (ACTI)
BETZ, Randal R., Philadelphia (ACTI)
CAHILL, Patrick, Philadelphia (CAND)
D'ANDREA, Linda P., Pottstown (ACTI)
DEENEY, Vincent F X, Pittsburgh (ACTI)
DONALDSON, III, William F., Pittsburgh (ACTI)
DORMANS, John P., Philadelphia (ACTI)
DRUMMOND, Denis S., Philadelphia (EMER)
ECKER, Malcolm L., Philadelphia (EMER)
FLYNN, John M., Philadelphia (ACTI)
FRAS, Christian I., Broomall (CAND)
GUILLE, James T., Pottstown (CAND)
HARRISON, C. Scott, Mechanicsburg (EMER)
HERMAN, Martin J., Philadelphia (CAND)
HESS, W. Fred, Danville (ACTI)
HSU, Victor W., Willow Grove (CAND)
KRAUS, David R., Pittsburgh (ACTI)
MACEWEN, G. Dean, Philadelphia (EMER)
MENDELSON, Stephen A., Pittsburgh (ACTI)
MORELAND, Morey S., Pittsburgh (EMER)
PIZZUTILLO, Peter D., Philadelphia (ACTI)
RATLIFF, John Kevin, Philadelphia (CAND)
RICHMAN, Jory D., Pittsburgh (ACTI)
SAMDANI, Amer, Philadelphia (CAND)
SCHWARTZ, Daniel M., Springfield (CAND)
SCOLES, Peter V., Philadelphia (EMER)
SEGAL, Lee S., Hershey (ACTI)
SPIEGEL, David A., Philadelphia (CAND)
STEEL, Howard H., Villanova (EMER)
STONE, Charles S., Pittsburgh (EMER)
VACCARO, Alexander R., Philadelphia (ACTI)
WARD, W. Timothy, Pittsburgh (ACTI)

Peoples Republic of China

FUNG, Kwai-Yau, Shatin (ASSO)
LI, Ming, Shanghai (CAND)
WANG, Yan, Beijing (CAND)
YONG, Qiu, Nanjing (CAND)
ZHANG, Xuesong, Beijing (CAND)
ZHANG, Yonggang, Beijing (CAND)
ZOU, Dewei, Beijing (CAND)

Poland

ZARZYCKI, Daniel, Zakopane (EMER)

Puerto Rico

FLYNN, John M., San Juan (ACTI)
RAMIREZ-LLUCH, Norman F., Mayaguez (CAND)

Rhode Island

EBERSON, Craig P., Providence (CAND)
SEAVOR, Nancy-Jane, Cranston (EMER)

Saudi Arabia

FALLATAH, Salah, Jeddah (CAND)

Singapore

CHACHA, Pesi B., Singapore (EMER)
DARUWALLA, Jimmy S., Singapore (EMER)
TAN, Chong-Tien, Singapore (ACTI)
WONG, Hee-Kit, Singapore (ACTI)

South Africa

DUNN, Robert, Tokai (ASSO)

South Carolina

BROWN, Lawrence P., Greenville (EMER)
GRIFFIN, Paul P., Greenville (EMER)
GROSS, Richard H., Charleston (ACTI)
LOCKE, Mark D., Columbia (CAND)
MOONEY, James F., Charleston (ACTI)
MORRISSY, Raymond T., Sheldon (EMER)
PIEHL, Frederick C., Columbia (CAND)
RENSHAW, Thomas S., Hilton Head Island (EMER)
SAMBERG, L. Carl, Hilton Head Island (EMER)
STANITSKI, Carl L., Kiawah Island (EMER)
STASIKELIS, Peter J., Greenville (ACTI)
STRAYER, Luther M., Hilton Head Island (EMER)

South Korea

CHEH, Gene, Seoul (CAND)
CHO, Jae-Lim, Seoul (ACTI)
CHO, Kyu-Jung, Incheon (CAND)
CHUNG, Jae-Yoon, Kwangju (CAND)
JEONG, Soon-Taek, Jinju (ACTI)
KIM, Eung-Ha, Seoul (ACTI)
KIM, Hak-Sun, Kangnam-ku, Kang-Nam (CAND)
KIM, Jin-Hyok, Seoul (ASSO)
KIM, Ki-Tack, Seoul (ASSO)
LEE, Chong-Suh, Seoul (ACTI)
LEE, Choon-Ki, Seoul (ACTI)
LEE, Choon-Sung, Seoul (ASSO)
LEE, Ji-Ho, Seoul (ASSO)
LEE, Jin-Young, Seoul (ASSO)
LEE, Sang-Min, Goyang-si (ASSO)
MIN, Hak-Jin, Seoul (ACTI)
PARK, Weon Wook, Nam-gu (ACTI)
RHA, Jong-Deuk, Seoul (ASSO)
RHIM, Seung-Chul, Seoul (CAND)
SHIN, Byung-Joon, Seoul (ASSO)
SUK, Se-Il, Seoul (ACTI)



Spain

BAGO, Juan, Barcelona (CAND)
BAS, Teresa, Valencia (CAND)
IZQUIERDO, Enrique, Madrid (CAND)
MHAIDL, Hani, Las Palmas (CAND)
PELLISE, Ferran, Barcelona (CAND)
PEREZ-GRUESO, Francisco Javier Sanchez, Madrid (ACTI)
SACRAMENTO DOMINGUEZ, Maria Cristina, Santa Cruz De Tenerife (CAND)
VENTURA, Norberto, Barcelona (CAND)
VILLANUEVA, Carlos, Barcelona (ACTI)

Sweden

NORDWALL, Anders, Goteborg (EMER)
OHLIN, Acke, Malmo (ACTI)

Switzerland

AEBI, Max, Berne (ASSO)
GROB, Dieter, Zurich (ACTI)
HENKE, Gunther, Flugbrunnen-Bolligen (EMER)
MARCHESI, Dante, Lausanne (ASSO)
MIN, Kan, Zurich (CAND)
SCHEIER, Heiner, Zurich (EMER)

Taiwan

CHEN, Po-Quang, Taipei (EMER)
HUANG, Tsung-Jen, Chia-Yi (ACTI)

Tennessee

BROADSTONE, Paul A., Chattanooga (ACTI)
BROWN, Hugh P., Chattanooga (EMER)
EDMONSON, Allen S., Memphis (EMER)
FREEMAN, Barney L., Collierville (ACTI)
GAINES, Donald L., Brentwood (EMER)
GLATTES, R. Chris, Nashville (CAND)
GREEN, Neil E., Nashville (EMER)
HODGES, Scott D., Chattanooga (ACTI)
LINVILLE, Douglas A., Memphis (ACTI)
MADIGAN, Robert R., Knoxville (ACTI)
MAGUIRE, James Kimbro, Knoxville (ACTI)
MENCIO, Gregory A., Nashville (ACTI)
OSBORN, James M., Chattanooga (ACTI)
SAWYER, Jeffrey R., Germantown (CAND)
SCHNUEERER, Anthony P., Collierville (ASSO)
VANDENBRINK, Keith D., Roan Mountain (EMER)
WALLACE, Sidney L., Knoxville (EMER)
WARNER, William C., Germantown (ACTI)

Texas

BOLESTA, Michael J., Dallas (ACTI)
BROCK, Gary T., Houston (ACTI)
BUCHL, Eric H., Plano (CAND)
CALLEWART, Craig C., Dallas (ACTI)
CAMPBELL, Robert M., San Antonio (ACTI)
CARMODY, Cameron N., Plano (CAND)

COMSTOCK, Christopher P., Corpus Christi (ACTI)
DICKSON, Jesse H., Horseshoe Bay (EMER)
ERWIN, Wendell D., Houston (EMER)
ESSES, Stephen I., Houston (ACTI)
FRANCIS, William R., Houston (ACTI)
GECK, Matthew, Austin (ACTI)
GLEDHILL, Robert B., San Antonio (EMER)
GRAY, David Wayne, Fort Worth (CAND)
HERRING, John A (Tony), Dallas (ACTI)
HOSTIN, Richard, Plano (CAND)
JOHNSTON, Charles E., Dallas (ACTI)
JOSHI, Ajeya P., San Antonio (CAND)
KAROL, Lori Ann, Dallas (ACTI)
KATZ, Donald E., Dallas (ASSO)
LAGRONE, Michael O., Amarillo (ACTI)
LAWSON, L. Ray, Dallas (EMER)
LOWENSTEIN, Jason E., Austin (CAND)
LOWRY, Thomas I., Austin (EMER)
MARCO, Rex Alexander Wong, Bellaire (ACTI)
NELSON, Page W., Pearland (EMER)
PHILLIPS, William A., Houston (ACTI)
PRINCE, Michelle M., Austin (CAND)
RAHM, Mark D., Temple (CAND)
RATHJEN, Karl E., Dallas (ACTI)
REINKER, Kent A., San Antonio (ACTI)
RICHARDS, B. Stephens, Dallas (ACTI)
ROONEY, Richard C., El Paso (CAND)
SACHS, Barton L., Plano (ACTI)
SANDERS, Albert E., San Antonio (ACTI)
SCHROEDER, F. William, Bastrop (EMER)
SHAPIRO, Jay, Austin (ACTI)
SHELOKOV, Alexis P., Plano (ACTI)
SIMMONS, James W., San Antonio (ACTI)
STANLEY, Earl Austin, San Antonio (ACTI)
SUCATO, Daniel J., Dallas (ACTI)
VON RUEDEN, Kurt W., Austin (ACTI)
WARMAN, Jeffrey R., San Antonio (ACTI)
WILLIAMS, John J., Austin (ACTI)
WISE, Carol A., Dallas (ASSO)
ZHANG, Hong, Dallas (ASSO)

Thailand

CHOTIGAVANICH, Charoen, Bangkok (ACTI)
THANAPIPATSIRI, Surin, Bangkok (ASSO)

Turkey

ACAROGLU, Emre R., Kavaklidere (ACTI)
AKESEN, Burak, Kosuyolu/Istanbul (CAND)
ALANAY, Ahmet, Ankara (ACTI)
AYDINLI, Ufuk, Bursa (ACTI)
BENLI, I. Teoman, Beysukent (CAND)
BERK, R. Haluk, Izmir (ACTI)
HAMZAOGLU, Azmi, Caglayan-Istanbul (ACTI)
SENKOYLU, Alpaslan, Ankara (CAND)
SURAT, Adil, Ankara (EMER)

TALU, Ufuk, Topkapi (ACTI)
TEZEREN, S. Gunduz, Sivas (CAND)
YAZICI, Muharrem, Ankara (ACTI)

United Kingdom

CRAIG, James B., Brockworth (ASSO)
DOVE, John, Argyll (EMER)
EDGAR, Michael A., London (EMER)
GARDNER, Alan David H, Dansbury (EMER)
HARDING, Ian J., Bristol (CAND)
JACKSON, Robert K., Lymington Hants (EMER)
MARKS, David S., Northfield (ACTI)
MCMASTER, Michael John, Edinburgh Scotland (EMER)
MEHDIAN, Hossein, Nottingham (ACTI)
MEHTA, Min H., Twickenham (EMER)
MOLLOY, Sean, Gerrards Cross (CAND)
NELSON, Ian W., Bristol (CAND)
NOORDEEN, Hilali H., London (ACTI)
THOMPSON, Alistair Graham, Edgbaston (EMER)
TSIRIKOS, Athanasios Thanos, Edinburgh Scotland (ASSO)
WEBB, John K., Nottingham (EMER)
WILLIAMSON, J. Bradley, Salford (ACTI)
WYNNE-DAVIES, Ruth, Oxford (HONO)

Uruguay

NIN VIVO, Estaban, Montevideo (EMER)

Utah

DAUBS, Michael D., Salt Lake City (CAND)
DUNN, Harold K., Salt Lake City (EMER)
HOOLEY, Eric W., Logan (CAND)
OGILVIE, James W., Salt Lake City (ACTI)
ROACH, James W., Salt Lake City (ACTI)
SANTORA, Stephen D., Salt Lake City (ACTI)
SMITH, John T., Salt Lake City (ACTI)

Vermont

AMES, S. Elizabeth, Burlington (CAND)
ARONSSON, David D., Burlington (ACTI)
BRAUN, John T., Burlington (ACTI)
MOLLOY, Maureen K., Shelburne (EMER)
STOKES, Ian A. F., Burlington (ACTI)

Vietnam

THANH, Vo Van, Ho Chi Minh City (CAND)

Virginia

ABEL, Mark F., Charlottesville (ACTI)
ARLET, Vincent, Charlottesville (ACTI)
BYRD, J. Abbott, Virginia Beach (ACTI)
CARDELIA, J. Marc, Norfolk (CAND)
CHAN, Donald P. K., Charlottesville (EMER)
FIORE, Steven M., Richmond (ACTI)
GRUBB, Stephen A., Christiansburg (ACTI)
HEINIG, Charles F., Ware Neck (EMER)
NOGI, Jay, Glen Allen (EMER)

SHAFFREY, Christopher I., Charlottesville (ACTI)
SHEN, Francis H., Charlottesville (CAND)
SHIRLEY, Eric D., Portsmouth (CAND)
STIKELEATHER, Luke, Fairfax (ASSO)

Washington

BADGER, Virginia M., Lacey (EMER)
FLORENCE, Robert W., Tacoma (EMER)
GUSTAFSON, Robert K., Olympia (EMER)
HANSCOM, David A., Seattle (CAND)
HURLEY, John H., Spokane (EMER)
KNIGHT, Reginald Quentin, Kirkland (ACTI)
KRENGEL, Walter F., Bellevue (ACTI)
LAURNEN, Edwin L., Bellevue (EMER)
MULLEN, Marr P., Mercer Island (EMER)
OSEBOLD, William R., Spokane (ACTI)
ROH, Jeffrey S., Kirkland (CAND)
SONG, Kit M., Seattle (ACTI)
TUPPER, James W., Seattle (EMER)
WAGNER, Theodore A., Seattle (ACTI)
WHITE, Klane M., Seattle (CAND)

West Virginia

EMERY, Sanford E., Morgantown (ACTI)
FRANCE, John C., Morgantown (ACTI)

Wisconsin

CAIN, James E., Mequon (ACTI)
DELAHUNT, Stephen P., Milwaukee (EMER)
FLATLEY, Thomas J., Milwaukee (EMER)
HUIZENGA, Bernard A., Palmyra (EMER)
JACOBSEN, Finn Stig, Marshfield (ACTI)
MAJOR, Michael R., Milwaukee (EMER)
MANN, David C., Madison (ACTI)
NOONAN, Kenneth J., Madison (ACTI)
TASSONE, J. Channing, Milwaukee (CAND)
THOMETZ, John G., Wauwatosa (ACTI)
TRIBUS, Clifford B., Madison (ACTI)
ZUEGE, Robert C., Milwaukee (EMER)

Wyoming

BECK, Joshua, Jackson (CAND)
RITTERBUSCH, John F., Sheridan (ACTI)

PARTICIPANTS LIST



SCOLIOSIS RESEARCH SOCIETY





Abel, Mark	230	Betz, Randal	56, 65, 67, 71, 72, 123, 131, 141, 146, 150, 151, 179, 221, 230, 233, 240, 247
Acaroglu, Emre	127	Bilsky, Mark	92, 94
Agrawal, Kshitij.....	234	Blamoutier, Arnaud	250, 256
Ahier, Janet.....	260	Blanke, Kathy	266
Akbarnia, Behrooz.....	69, 70, 120, 163, 183, 207, 217, 219, 241	Boachie-Adjei, Oheneba.....	57, 69, 78, 120, 132, 161, 163, 164, 207, 230
Akel, Ibrahim	127	Boland, Patrick.....	92, 94
Alanay, Ahmet	127	Bonete, Daniel	181
Alvarez, Ignacio.....	87	Borkhuu, Battugs	195
Amaral, Terry.....	134, 180, 216	Borowski, Andrzej.....	195
Antonacci, M. Darryl.....	131, 221, 233	Bowen, Richard.....	154, 157
Arino, Vincent.....	181	Boyd, Erin.....	81
Arlet, Vincent	225	Boyd, Michael.....	115
Arriaga, Francisco	181	Bradford, David.....	75, 81
Asghar, JahanGir	72, 131, 221, 233, 241	Brandt, Jason	214
Asher, Marc.....	217, 241	Braun, John	59
Aubin, Carl-Eric	147, 186, 215	Bridwell, Keith.....	58
Auerbach, Joshua	95, 130	Bridwell, Keith.....	62, 64, 74, 78, 79, 80, 82, 83, 95, 97, 111, 117, 132, 138, 140, 155, 159, 161, 164, 165, 166, 168, 169, 170, 171, 175, 190, 214, 220, 231, 232, 253, 255, 257
Aydogan, Mehmet.....	66	Brodke, Darrel	121
Ayham, Selim.....	258	Brown, Courtney	88
Azeddine, Bouziane	133	Bruce, Brandon.....	196
Bacon, Sarah	260	Bruce, Robert.....	194
Badura, Jeffrey.....	125	Buchowski, Jacob	82, 159, 161, 171
Bae, Hyun	125	Burch, Shane.....	188
Bagnall, Keith.....	133	Burgos, Jesus.....	87
Bakaloudis, Georgios	102	Burke, Stephen	57
Baldassarri, Stephen	124	Burton, Douglas	68, 120, 163, 207
Baldus, Christine	95, 111, 155, 165, 169	Cachon, Thibault	126
Bansal, Supriya	124	Cahill, Patrick.....	98, 131, 221, 233
Bapat, Mihir.....	89	Caird, Michelle.....	267
Barrios, Carlos.....	87	Cameron, Danielle.....	71
Bas, Paloma	181	Campbell, Robert.....	71
Bas, Theresa	181	Canale, Sarah	69
Bastrom, Tracey.....	65, 67, 141, 146, 150, 151, 209, 228, 240, 261	Canavese, Bartolomeo	218
Beausejour, Marie	187	Canavese, Federico	218
Beckstead, Jason.....	154, 157	Cardoso, Mario.....	106, 128, 259
Bedigrew, Katherine	232	Carlson, Brandon.....	68
Belanger, Lise	115	Carpio, Nelly	181
Belessine, Larissa.....	206	Casey, Adrian	139
Belkoff, Stephen.....	104	Cavalli, Fabio	218
Berenholtz, Sean	156	Celerin, Lubica.....	178
Beria, Jasmine.....	92	Chafetz, Ross	72
Bernardo, Arlene	115	Chambers, Reid.....	200, 202
Berthonnaud, Eric	88, 118, 248	Chan, Chun wai.....	242
Berven, Sigurd.....	75, 80, 81, 83, 168, 188		
Bess, R. Shay	69, 120, 163, 207		



43rd Annual Meeting & Course

Reaching New Heights in 2008!

Chan, Donna	115	DeWald, Christopher	165
Charosky, Sebastien.....	118, 248	Dhall, Sanjay.....	90
Chau, Edouard.....	192	Di Silvestre, Mario.....	102
Chaudhary, Kshitij.....	89	Diab, Mohammad	140, 145, 153, 199, 210, 229, 264
Cheh, Gene	170, 239	Dimeglio, Alain	218
Chen, Tina.....	183	Dmitriev, Anton.....	106, 128
Cheng, Jack	60, 148, 226, 238, 242, 262	Dohzono, Sho.....	174
Chettier, Rakesh	59, 61	Domenech, Pedro.....	87
Chikuda, Hirotaka	135	Dorman, Todd.....	156
Cho, Kyu-Jung	76	Dormans, John	70, 95, 140, 145
Chopin, Daniel.....	118, 248	Drummond, Denis	65
Chow, Daniel	148	Durrani, Salim	188
Christensen, Christen	128	Dvorak, Marcel	115
Chu, Winnie	226	Dykes, Daryll.....	113, 227
Chung, Rack-Yong.....	76	Eagan, Michael.....	154, 157
Clasey, Jody	191	Edwards, Charles.....	80, 165, 168
Clement, Jean-Luc	192	Eichhorn, Torsten	85
Clements, David	65, 67, 131, 141, 150, 221, 233, 240	El Miligui, Yasser	63
Clowyd, Jordan	75	ELMiligui, Yasser	244
Cohen, David.....	156, 245	Elsebaie, Hazem	63, 69, 183, 219, 244
Cooper, Patrick.....	106	Emans, John	70, 71, 140, 145, 183, 217, 264
Cowgill, Ian.....	266	Enercan, Meric.....	66
Cramer, Dennis	224	Entezari, Vahid.....	124
Crandall, Dennis	103	Erickson, Mark	140
Crawford, Alvin	67, 141, 146, 150, 151, 179, 183, 230, 247	Erkan, Serkan.....	113, 227, 237
Crawford, Marc	260	Escriba, Ismael	181
Crippa, Grasiela	206	Estelita, Carlos.....	206
Cunningham, Matthew.....	120	Estreicher, Michael	130
Czerwein, John	134, 180, 216	Farcy, Jean-Pierre	173, 175, 212
Dabke, Harshad	100, 119, 198	Farley, Frances.....	267
Dabney, Kirk.....	195	Farmery, Andrew.....	249
d'Andrea, Linda	72, 179, 209	Farnsworth, Christine	200, 202
Danielsson, Aina	142	Faulkner, Nathan	91
Darbee, Joan.....	191	Ferguson, John.....	239
Darras, Basil.....	99	Festen, Dederieke	109
Daubs, Michael.....	121, 170, 239	Firkins, Paul.....	200
de Guise, Jacques	86	Fischer, Charles	115
de Klerk, Luuk	109	Fischer, Itzhak	123
De La Rubia, Javier	181	Flynn, Jennifer.....	58, 159, 171
de Lind van Wijngaarden, Roderick.....	109	Flynn, John	71, 141, 230
Dear, Jameson	263	Fong Hui, Celine Fan	242
Debnath, Ujjwal.....	100, 119, 198	Forcier, Martin	187
Defino, Helton	206	Franco, Anita.....	133
Demirkiran, Gokhan.....	127	Freedman, Brett.....	129
Denis, Francis.....	113, 227	Freeman, Brian	100
Deviren, Vedat.....	75, 81, 188	Fu, Eric	167

Fu, Kai-Ming	83	Hayward, Melissa	124
Gambassi, Melanie	180	Helenius, Ilkka	108
Gardner, Stephen	154, 157	Helgeson, Melvin	106, 128, 259
Garg, Sumeet	214	Hensley, Marsha	64
Garrett-Mayer, Elizabeth	156	Henson, MeLeah	222
Garvery, Timothy	113	Hepler, Matthew	101
Gaughan, John	72	Herrero, Carlos	206
Geck, Matthew	190	Hevia, Eduardo	87
Gene Man, Chi Wai	226, 238, 262	Hill, Douglas	143
Gholve, Purushottam	265	Hilton, Joan	111
Giffin, Mitch	115	Hoakazemi, A.S.	100
Gill, Norman	259	Hokken-Koelega, Anita	109
Giuffrida, Michael	124	Hong, Eui Pyo	122
Glassman, Steven	80, 83, 111, 165, 166, 168, 175	Hori, Satoshi	139
Glattes, R. Chris	68	Horton, William	80, 83, 111, 129, 165, 166, 168
Gok, Beril	258	Hosalkar, Harish	265
Gokaslan, Ziya	93, 258	Hosogane, Naobumi	132
Gonzales, Ricardo	245	Hostin, Richard	120, 163, 207
Good, Christopher	74, 97, 159, 169, 171, 253, 255	Hsieh, Patrick	93, 182
Gournay, Jose	126	Hsu, Brian	113, 227, 237
Green, Daniel	57	Hu, Serena	75, 81, 88, 166, 188
Grewal, Harsh	72	Hu, Yun Yu	242
Griffith, Terri	263	Hung, Vivian	60, 226, 238
Grimard, Guy	133	Hutton, William	129
Guigui, Pierre	250, 256	Hwang, Dae-Woo	246
Guille, James	179, 209	Inui, Yoshihiro	201
Gupta, Munish	120, 163, 207, 230	Ito, Yasuo	114
Gutierrez, Pedro	87	Iwinski, Henry	191, 196
Ha, Kee-Yong	76	Jackson, Andrew	124
Haid, Regis	90	Jackson, Roger	147, 186, 215
Hamasaki, Takahiko	129	Jagannathan, Jay	225
Hamill, Christopher	80, 83, 164, 168	Jalanko, Tuomas	108
Hammerberg, Kim	98	Jayakumar, Prakash	139
Hamzaoglu, Azmi	66	Jensen, Rubens	85
Hanover, Andrew	92, 94	Johnson, Phillip	68
Harding, Ian	118, 248	Johnston, Charles	137, 140, 145, 199, 210
Harimaya, Katsumi	79, 117, 220, 257	Jolivet, Erwan	126
Harms, Jürgen	85, 230	Joncas, Julie	187
Harrast, John	165	Kadakia, Rishi	219
Harrison, David	139	Kajino, Tomomichi	158
Harshavardhana, Nanjundappa	89, 100, 119, 198	Kamerlink, Jonathan	189
Hart, Robert	163, 207	Karlin, Lawrence	69, 183, 219
Hasserijs, Ralph	142	Kawade, Manish	234
Hawkinson, Nicola	173, 212	Kawakami, Noriaki	73
Hawthorne, Dana	190	Kean, Kristin	130, 228
Hayashi, Katsushiro	186	Kebaish, Khaled	104, 112, 156, 245



43rd Annual Meeting & Course

Reaching New Heights in 2008!

Keeler, Kathryn	58, 97, 138, 169, 214, 231, 253, 255	Li, Guoan.....	167
Khan, Shahid.....	219	Lieberman, Isador.....	208
Kim, Hyung-Suk	76	Lis, Eric.....	94
Kim, JinHwan	129	Littleton, Aaron.....	195
Kim, Jin-Soo.....	246	Liu, Jie.....	116
Kim, Ki-Tack	246	Liu, XueCheng.....	197
Kim, Yongjung.....	78, 132, 161, 164, 170, 171	Lolli, Francesco.....	102
Kim, Young Woo.....	239	Lonner, Baron.....	65, 130, 141, 146, 150, 151, 179, 228, 230, 247
Kim, Youngbae	78, 132, 161, 164, 239	Lonstein, John.....	113
Kirby, Cassie.....	144	Lou, Edmond	143
Klatt, Joshua	91	Lowe, Thomas	56, 65, 141, 146, 165
Koester, Linda	64, 79, 82, 117, 169, 190, 220, 257	Lubicky, John.....	252
Koptan, Wael.....	63, 244	Luhmann, Scott	62, 97, 107, 138, 159, 232
Koski, Tyler	182, 251	Macagno, Angel	151, 190, 230
Kostial, Patricia.....	183, 217, 219	Mac-Thiong, Jean-Marc	86
Kostuik, John.....	156, 245	Maeda, Takeshi.....	82
Kuklo, Timothy	105, 128, 138, 140, 145, 153, 159, 199, 210, 229, 232, 264, 266	Maeno, Takafumi	174
Kummer, Frederick.....	189	Mahar, Andrew.....	202
Kuntz, Charles.....	224	Maher, Colby	224
Kwok, Hoi-kei.....	148	Mahood, James.....	143
Kwok, Rachel.....	60	Manna, Barbara.....	68
Kwon, Brian.....	115, 116	Marawar, Satyajit.....	89
Labelle, Hubert.....	86, 88, 133, 147, 186, 187, 215	Marcucio, Ralph.....	127
Lacroix, Ginette	133	Mardjetko, Steven	165
Lafage, Virginie.....	163, 173, 175, 207, 212	Marks, David.....	70, 183, 219
Laheri, Vinod	89	Marks, Michelle.....	67, 141, 150, 151, 240
Lam, Tsz-ping	148	Martus, Jeffrey	263
LaMotta, Ivan	104	Maruenda, Jose	87
Larouche, Ginette.....	133	Maruyama, Toru.....	135
Laufer, Ilya.....	92, 94	Marx, Jeffrey	116
Lautenschlager, Eugene	101	Matsuda, Hideki.....	174
Lawhorne, Thomas	57, 78	Matsumura, Akira.....	174
Lee, Jae	116	McCall, Richard	211
Lee, June Kyu	122	McCarthy, James.....	221
Lee, Jung-Hee.....	246	McCarthy, Kathryn	222
Lee, Kwong Man	60, 226, 238, 242, 262	McCarthy, Richard	107, 140, 183, 217, 219, 222, 241
Lee, Michael.....	98	McClelland, Walter	194
Lee, Sang-Hun.....	246	McClendon, Jamal	105
Lehman, Ronald	106, 128, 231, 239, 259	McClung, Anna	137, 152, 185, 193
Lenke, Lawrence.....	56, 58, 62, 64, 65, 74, 78, 79, 95, 97, 107, 117, 132, 138, 140, 141, 145, 146, 147, 153, 155, 159, 161, 164, 165, 169, 170, 171, 186, 190, 199, 210, 214, 215, 220, 229, 231, 232, 239, 247, 253, 255, 257, 259, 264, 266	McCullough, Frances.....	107, 241
Letko, Lynn	150, 179, 230	McCutcheon, Brandon.....	266
Lewis, Stephen	260	McGirt, Matthew	93
Li, Gang.....	167	Megumi, Naoatsu	201
		Mehbod, Amir.....	84, 113, 227, 237
		Mehdian, Hossein	100, 119, 198, 223
		Mehlman, Charles.....	144



Mehta, Hemal.....	124	Okada, Yoshiyuki.....	201
Merk, Harry.....	85	Okubadejo, Gbolahan.....	155
Metkar, Umesh.....	89	O'Leary, Patrick.....	64, 74, 159, 169, 171, 253, 255, 257
Meyer, Laura.....	138, 232	Ondra, Stephen.....	80, 83, 105, 165, 168, 182, 251
Mezentsev, Andriy.....	213	Ono, Takashi.....	135
Milbrandt, Todd.....	191, 196	O'Shaughnessy, Brian.....	105, 182, 251
Miller, Freeman.....	195	Oswald, Timothy.....	194
Mintz, Douglas.....	57	Otten, Barto.....	109
Mishiro, Takuya.....	79, 117, 257	Ouellet, Jean.....	133
Miyamoto, Hiroshi.....	201	Ozturk, Cagatay.....	66
Miyasaka, Kazuyoshi.....	73	Pan, Wei min.....	242
Mohamed, Ahmed.....	112	Paquette, Scott.....	115
Mok, James.....	75, 188	Parent, Eric.....	143
Monson, David.....	194	Parent, Stefan.....	133, 187
Moreau, Alain.....	133	Parisini, Patrizio.....	102
Moreau, Marc.....	143	Passias, Peter.....	167
Moridaira, Hiroshi.....	158	Passuti, Norbert.....	250, 256
Moscardo, Federico.....	181	Pateder, Dhruv.....	245
Moser, Richard.....	259	Patel, Alpesh.....	121
Mroz, Thomas.....	208	Patel, Ashish.....	163, 173, 175, 207, 212
Mulcahey, Mary Jane.....	72	Patel, Nipun.....	124
Mulconrey, Daniel.....	255	Patel, Vikas.....	125
Mummaneni, Praveen.....	90	Paul, Courtney.....	123
Nachemson, Alf.....	142	Paulino, Carl.....	110
Nakamura, Hiraki.....	174	Pawelek, Jeff.....	65, 146, 186, 247, 261
Nakamura, Kozo.....	135	Payo, Jorge.....	235
Nakashita, Ken.....	243	Pekmezci, Murat.....	81
Nasr, Fadi.....	251	Peltonen, Jari.....	108
Nelson, Clarke.....	93, 258	Perl, John.....	237
Nelson, Lesa.....	59, 61	Perra, Joseph.....	113
Neuhuber, Birgit.....	123	Petcharaporn, Maty.....	209
Newton, Peter.....	56, 65, 67, 141, 146, 147, 150, 151, 179, 186, 200, 202, 209, 215, 230, 240, 247, 261	Petrenko, Dmytro.....	213
Ng, Bobby.....	60, 148, 226, 238, 262	Pettigrew, David.....	224
Nnadi, Colin.....	139	Peultier, Bertrand.....	126
Nohara, Ayato.....	73	Pham, Julius.....	156
Nohara, Yutaka.....	158	Pichelmann, Mark.....	74, 159, 169, 253, 255
Nomoto, Tomohisa.....	243	Pinto, Manual.....	113
Nurenberg, Pamela.....	185, 193	Piper, Samantha.....	188
Nydick, Jason.....	233	Pittioni, Eugenio.....	218
O'Brien, Joseph.....	104	Piza, Gabriel.....	87
O'Brien, Michael.....	67, 150, 151, 190, 230	Poe-Kochert, Connie.....	69, 136, 183, 217
Oda, Hiromi.....	243	Poitras, Benoit.....	133
Odent, Thierry.....	126	Polly, David.....	165
Ogilvie, James.....	59, 61	Potzman, Jennifer.....	136
Ohara, Tetsuya.....	73	Poussa, Mikko.....	108
Ohlin, Acke.....	142	Pradhan, Ben.....	125



43rd Annual Meeting & Course

Reaching New Heights in 2008!

Pronovost, Peter	156	Schwender, James.....	113
Qin, Ling	60, 226, 242	Sciubba, Daniel	93, 131, 221, 258
Qiu, Yong.....	226, 238, 262	Segal, Lee	267
Qui, Xing.....	149	Seim, Howard.....	125
Quirno, Martin.....	110, 189	Sengupta, Dilip	223
Ramirez-Garnica, Gabriela	178	Shaffrey, Christopher.....	80, 83, 111, 120, 163, 165, 166, 168, 207, 225
Ranade, Ashish.....	72	Shah, Suken.....	69, 70, 151, 178, 195, 230, 241
Raptis, Dimitri.....	139	Shainline, Michael.....	80, 111, 140, 145, 168, 175
Raso, Jim.....	143	Shanti, Nael.....	110
Rathjen, Karl	263	Shapiro, Frederic	99, 184
Rawlins, Bernard.....	57	Sharan, Alok.....	134
Recarte, Enrique	87	Sharan, Alok.....	180, 216
Remes, Ville.....	108	Shelokov, Alexis.....	120, 163, 207
Revella, Jan.....	103	Shirado, Osamu	243
Ricchetti, Eric.....	265	Shoda, Naoki.....	135
Richards, B. Stephens.....	95, 140, 145, 199, 210, 229, 264	Shufflebarger, Harry.....	150, 151, 190, 230
Riew, Daniel.....	128, 159	Shuler, Michael	194
Rinella, Anthony	190	Shum, Lai-fong.....	148
Riquelme-Garcia, Oscar.....	87	Sides, Brenda.....	64, 74, 79, 97, 117, 190, 214, 220, 231, 253, 255, 257
Rivard, Charles-Hilarie	133	Siemionow, Krzysztof	208
Roach, James	91	Sing, Sai-wing	148
Robinson, Malaya.....	112	Skaggs, David.....	69, 70, 183, 217, 241
Roig, Monica	181	Skolasky, Richard	112
Romppe, Pierre.....	133	Slivka, Michael.....	202
Rosa, Adalberto.....	206	Smith, Jason.....	75
Rose, Peter.....	92, 94	Smith, John, T.	71
Rosner, Michael.....	105, 106, 259	Smith, Justin	83
Roussouly, Pierre.....	88, 118, 248	Smith-Berry, Therese	61
Roy, Josee.....	116	Snyder, Brian	124
Roy-Beaudry, Marjolaine.....	187	Song, Ho sup.....	122
Ruf, Michael	85	Son-Hing, Jochen.....	136, 220
Salari, Pooria	219, 241	Spivak, Jeffrey.....	110, 189
Samdani, Amer.....	72, 123, 131, 221, 233	Sponseller, Paul.....	67, 69, 70, 217, 219, 230
Sampera, Ignasi.....	87	Srivastava, Sudhir	234
Sanchez Perez-Grueso, Francisco.....	217, 219, 235, 241	St. Hilaire, Tricia	71
Sanders, James.....	140, 145, 149, 153	Stammers, Anthea.....	115, 116
Sangole, Archana	147	Stanton, Robert.....	178
Sanz, Jaime	181	Stauff, Michael	267
Sanz, Miguel.....	181	Stokes, Ian	147, 149, 186, 215
Sarwahi, Vishal	134, 180, 216	Street, John.....	115
Sarwark, John	140, 252	Study Group, Harms.....	56, 65, 67, 131, 141, 146, 151, 221, 233, 240, 247
Scaduto, Anthony.....	154, 157	Study Group, International Spine	120
Schlechter, John.....	56, 247	Study Group, Growing Spine	69, 70, 183, 219, 241
Schootman, Mario	97		
Schwab, Frank.....	83, 111, 120, 163, 165, 166, 168, 173, 175, 207, 212, 220		



Study Group, Chest Wall Spine Deformity.....	71	Vare, Bruno	192
Study Group, Spinal Deformity.....	140, 145, 153, 199, 210, 229, 252, 264, 266	Vialle, Raphael	118, 248
Sturm, Peter	98	Viguier, Eric.....	126
Sucato, Daniel	137, 140, 145, 152, 153, 185, 193, 199, 210, 222, 229, 252, 264	Vogel, Lawrence.....	98
Suda, Kota	158	Volpatti, Donatella.....	218
Sugimoto, Y.....	114	Voros, Gabor.....	104
Suk, Kyung-Soo	246	Walick, Kristina	137
Suk, Se-Il	76	Walker, Janet.....	196
Suzuki, Akinobu.....	174	Walker, Matthew.....	101, 149
Swamy, Ganesh.....	81	Wang, Wei Jun.....	226, 262
Tadokoro, Ko.....	201	Wang, Zhi	86
Taichi, Tsuji	73	Ward, Kenneth.....	59, 61
Takahashi, Keisuke.....	243	Warnick, Drew.....	98
Takaoka, Kunio	174	Watanabe, Kei.....	239
Takayama, Kazushi.....	174	Webb, John	100, 119, 198, 223
Takeshita, Katsushi.....	135	Widmann, Roger.....	57
Talwalkar, Vishwas.....	191, 196	Wijkstrom, Martin.....	194
Taneichi, Hiroshi	158	Will, Ryan	149
Tang, Nelson	60	Wilson-MacDonald, James.....	249
Tantorski, Mark.....	233	Winter, Robert.....	84, 113
Taylor, Ben.....	139	Wolinsky, Jean-Paul	93, 258
Tebi, Sina.....	219	Wollowick, Adam.....	134, 180, 216
Teli, Marco.....	66	Won, Man-Hee	76
Terai, Hidetomi.....	174	Wong, Daniel.....	143
Tetzlaff, Wolfgram.....	115	Wong, Man-sang.....	148
Tezer, Mehmet.....	66	Wood, Kirkham	120, 167
Thometz, John	197	Wootten, David.....	111
Thompson, George.....	69, 70, 136, 183, 217, 219, 241	Wu, Chunhui.....	227, 237
Thornhill, Beverly.....	134, 180, 216	Xu, Risheng.....	93
Tomlinson, Tucker.....	202	Yamada, Yoshiya	94
Tompkins, Bryan	152	Yamashita, Takayuki.....	208
Topp, Raymond.....	84	Yang, Jun-Young	122
Toth, Jeffrey.....	125	Yang, Justin.....	217
Transfeldt, Ensor.....	84, 113, 227, 237	Yang, Wei Jun	238
Tripi, Paul.....	136	Yaszay, Burt	56, 228, 261
Tsujio, Tadao	174	Yazici, Muhareem.....	183, 217, 241
Tsutsui, Shunji.....	202, 261	Ye, Gang.....	178
Turgeon, Isabelle	133	Yeung, Hiu Yan.....	60, 226, 238, 262
Turner, Joseph.....	222	Ying, Jun	144
Turner, Simon	125	Yoon, Seung Hwan.....	200
Umedaly, Ahmed.....	115	Zaarour, Christian.....	260
Uno, Koki	201	Zebala, Lukas.....	95, 111
Upasani, Vidyadhar.....	56, 65, 146, 186, 200, 202, 247	Zhang, Hong	185, 193, 222
Vallade, Marie-Jose.....	192	Zimmerman, Ryan	112
Vanderhave, Kelly.....	267	Zurakowski, David.....	99



43rd Annual Meeting & Course

Reaching New Heights in 2008!

SCOLIOSIS RESEARCH SOCIETY

MEMBERS CHANGE OF ADDRESS FORM

399



Member Change of Address Form

Scoliosis Research Society 43rd Annual Meeting & Course

**Grand America Hotel
Salt Lake City, Utah, USA
September 10 - 13, 2008**

David W. Polly, Jr., MD. Secretary
Scoliosis Research Society
555 East Wells Street, Suite 1100
Milwaukee, WI 53202-3823
Fax: 1-414-276-3349
E-mail: info@srs.org

Dear Dr. Polly:

Please change the listing of my name and address to read as follows:

Name: _____

Office Address: _____

City: _____ State: _____ Zip: _____

Country: _____

Telephone Number: _____ Fax Number: _____

E-Mail Address: _____

Spouse's Name _____

43rd Annual Meeting & Course

Reaching New Heights in 2008!



THE SCOLIOSIS RESEARCH SOCIETY

PRESENTS

IMAST

The 16th International Meeting on Advanced Spine Techniques

JULY 15-18, 2009 • HOFBURG CONGRESS CENTER • VIENNA, AUSTRIA



Registration & Abstract Submission Open: **November 1, 2008** Abstract Submission Deadline: **February 1, 2009**
Registration Deadline: **June 15, 2009**

Scoliosis Research Society

555 E. Wells Street, Suite 1100 Milwaukee, WI 53202 USA p. 1-414-289-9107 f. 1-414-276-3349 e. info@srs.org www.srs.org



MEETING AT A GLANCE

Monday, September 8, 2008

7:00 am – 5:00 pm Board of Directors Meeting Riviera

Tuesday, September 9, 2008

7:00 am – 5:00 pm SRS Committee Meetings Belvedere, Embassy, Fontainebleau, Hermitage, Sussex, Tuscany, Vienna
 2:00 – 6:00 pm Poster Set-Up Grand Ballroom Reception
 2:00 – 6:00 pm Registration Open Murano
 7:00 – 10:00 pm SRS Leadership Dinner (by invitation only) Depart 6:30 pm at 600 South Porte Cochere—Grand America Hotel

Wednesday, September 10, 2008

6:30 am – 5:00 pm Registration Open Murano
 6:30 am – 5:00 pm Internet Café Open Murano
 6:30 am – 5:00 pm Member Hospitality Open Envoy
 6:30 am – 5:00 pm Poster & E-Poster Exhibits Grand Ballroom Reception
 7:30 – 11:30 am Pre-Meeting Course: Osteobiologics Grand Ballroom
 8:00 am – 12:00 pm Tour: Historic City Depart at 600 South Porte Cochere—Grand America Hotel
 11:30 am – 12:30 pm Pre-Meeting Course Lunch Center Courtyard
 11:30 am – 12:30 pm Educational Symposium
 Understanding the SRS Roadmap to Financial Success Imperial Ballroom A
 12:30 – 5:30 pm Pre-Meeting Course: Hibbs Society Meeting Grand Ballroom
 1:30 – 4:30 pm Tour: Shaking the Family Tree Depart Grand America Lobby
 7:00 – 8:00 pm Opening Ceremonies Grand Ballroom
 8:00 – 9:30 pm Welcome Reception Center Courtyard

Thursday, September 11, 2008

6:30 am – 4:00 pm Registration Open Murano
 6:30 am – 4:00 pm Internet Café Open Murano
 6:30 am – 4:00 pm Member Hospitality Open Envoy
 6:30 am – 4:00 pm Poster & E-Poster Exhibits Grand Ballroom Reception
 6:30 – 7:40 am Members Business Meeting Imperial Ballroom A
 6:30 – 7:40 am Non-Members Continental Breakfast Grand Ballroom Reception
 7:00 – 10:00 am Accompanying Persons Hospitality Room Savoy
 7:55 am – 12:11 pm Scientific Program Grand Ballroom
 12:30 pm Sports: Edgar Dawson Memorial Golf Tournament Depart at 600 South Porte Cochere—Grand America Hotel
 12:30 – 5:30 pm Tour: Hike the Hills of Park City Depart at 600 South Porte Cochere—Grand America Hotel
 12:30 – 5:30 pm Tour: Rails to Trails Depart at 600 South Porte Cochere—Grand America Hotel
 12:30 – 6:00 pm Tour: Fly Fishing Depart at 600 South Porte Cochere—Grand America Hotel
 1:00 – 4:00 pm Instructional Course Lectures *ticket required*
 • Experimental Background of Growth Modulation on the Treatment of Growing Spine Deformities Grand Ballroom
 • 3D Scoliosis Evaluation and Classification Imperial Ballroom A
 • AAOS Communication Skills Savoy
 1:30 – 4:30 pm Tour: Shaking the Family Tree Tour Depart Grand America Lobby
 1:30 – 4:30 pm Tour: Doubles Tennis Tournament Depart at 600 South Porte Cochere—Grand America Hotel
 1:30 – 5:30 pm Tour: Historic City Tour Depart at 600 South Porte Cochere—Grand America Hotel
 1:30 – 5:30 pm Tour: Red Butte Garden and This Is The Place Heritage Park Depart at 600 South Porte Cochere—Grand America Hotel
 5:30 – 9:30 pm Tour: Supper & Song Depart at 600 South Porte Cochere—Grand America Hotel

Friday, September 12, 2008

6:30 am – 5:15 pm Registration Open Murano
 6:30 am – 5:15 pm Internet Café Open Murano
 6:30 am – 5:15 pm Member Hospitality Open Envoy
 6:30 am – 5:15 pm Poster & E-Poster Exhibits Grand Ballroom Reception
 6:30 – 7:40 am Members Business Meeting Imperial Ballroom A
 6:30 – 7:40 am Non-Members Continental Breakfast Grand Ballroom Reception
 7:00 – 10:00 am Accompanying Persons Hospitality Room Savoy
 7:55 am – 5:05 pm Scientific Program Grand Ballroom
 9:00 am – 2:00 pm Tour: Thanksgiving Point & Gardner Village Depart at 600 South Porte Cochere—Grand America Hotel
 12:23 – 1:20 pm Lunch Center Courtyard
 12:23 – 1:20 pm Educational Symposium
 Global Outreach Program: Tuberculosis –Infections of the Spine Imperial Ballroom A
 1:30 – 5:30 pm Tour: Violins & Chocolate Depart at 600 South Porte Cochere—Grand America Hotel
 7:00 – 10:00 pm Farewell Reception Clark Planetarium & IMAX®
 Depart at 6:30 pm from 600 South Porte Cochere—Grand America Hotel

Saturday, September 13, 2008

6:30 am – 1:00 pm Registration Open Grand Ballroom Conference Registration
 6:30 am – 1:00 pm Internet Café Open Grand Ballroom Conference Registration
 6:30 am – 1:00 pm Members Hospitality Envoy
 6:30 am – 1:00 pm Poster & E-Poster Exhibits Grand Ballroom Reception
 6:30 – 7:40 am Members Business Meeting Imperial Ballroom A
 6:30 – 7:40 am Non-Members Continental Breakfast Grand Ballroom Reception
 7:00 – 10:00 am Accompanying Persons Hospitality Room Savoy
 7:55 am – 12:47 pm Scientific Program Grand Ballroom
 8:45 am – 12:45 pm Red Butte Garden and This Is The Place Heritage Park Depart at 600 South Porte Cochere—Grand America Hotel
 12:47 pm Meeting Adjourns
 1:00 – 5:00 pm Board of Directors Meeting Audubon



43rd Annual Meeting & Course • September 10-13, 2008 • Salt Lake City, Utah, USA